

10mm/mV

10mm/mV

II

II

III

aVR

aVL

aVF

V1

V2

V3

SYNC

SYNC

SYNC

10mm/mV

ID : 1827

HR : 96 bpm

R-R : 624 ms

P-R : 153 ms

QT/QTc : 343/434 ms

P/QRS/T : 22/8/46 ms

RV5/SV1 : 0.49/0.61/0 mV

RV5+SV1 : 1.100 mV

Name: *Anu Khandal: 3007*

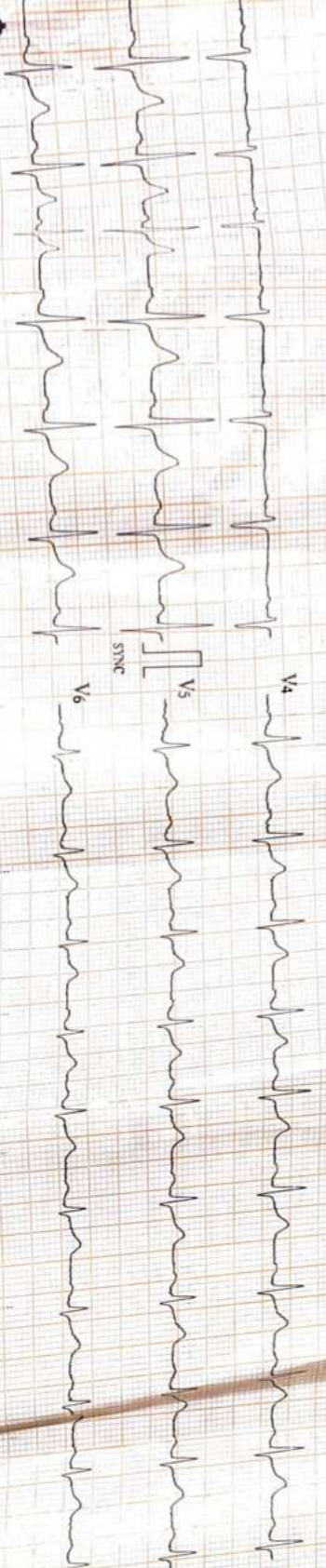
Sex : *F*

Age : *36y/10*

*Date - 12/01/23*

\_\_\_\_ Sinus Rhythm  
\_\_\_\_ Marked Counter Clockwise  
\_\_\_\_ Mild Left Axis Deviation

Unconfirmed report Verified by:





**OPD PRESCRIPTION**

MR.NO	: 26981	Date&Time	: 16/08/2023 11.00 AM
Name	: Mrs. ANU KHANDELWAL	Sex	: Female
Doctor Name	: Dr. HARSH VARDHAN SINGH	Age	: 36Years 5Months 7Days
Speciality	: ENT	Mobile No	: 9887152903
Address	: 15, NEW FIRENDS COLONY, JAIPUR ROAD WARD NO 27, ALWAR, Alwar, Rajasthan	Panel	: MEDIWHEEL FOC

BP 130/80 mmHg  
SpO2 - 98%  
PR - 84 bpm

H/O Tracheostomy - July (2012, 2010) ENT  
for long term intubation requirement.

ENT Complaints as of Now:  
Regular Health check

ENT - Ears - Polymicrobial: good hygiene

Neck -  
Mildly inflamed throat  
slightly dilated tracheostomy stoma.

Nasal air entry healthy.

Adv:

- ↳ Counselled.
- ↳ Steam inhalation daily -
- ↳ No PI in fit forms ENT side.
- ↳ No active infections required from ENT side.

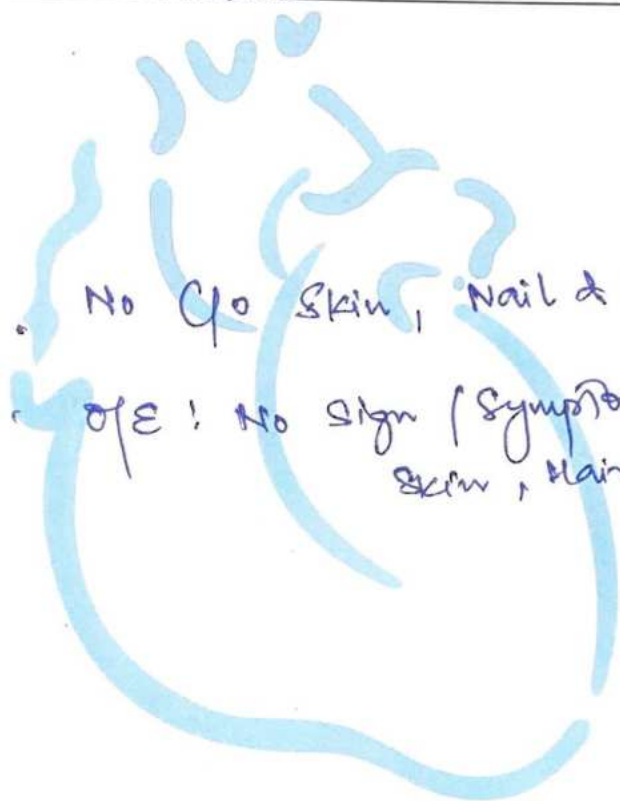
*Harsh Vardhan Singh*



**OPD PRESCRIPTION**

MR.NO	: 26981	Date&Time	: 16/08/2023 11.02 AM
Name	: Mrs. ANU KHANDELWAL	Sex	: Female
Doctor Name	: Dr. POOJA BAINS	Age	: 36Years 5Months 7Days
Speciality	: DERMATOLOGIST	Mobile No	: 9887152903
Address	: 15, NEW FIRENDS COLONY, JAIPUR ROAD WARD NO 27, ALWAR, Alwar, Rajasthan	Panel	: MEDIWHEEL FOC

BR/30180  
wt  
SP2 98.1  
PR- 84 blmt



No Qo skin, Nail & hair related disorders  
O/E: No sign / symptoms related to  
skin, hair & nail disorders

→  
16/8/23  
MD (DVL)



**OPD PRESCRIPTION**

MR.NO	: 26981	Date&Time	: 16/08/2023 11.06 AM
Name	: Mrs. ANU KHANDELWAL	Sex	: Female
Doctor Name	: Dr. SAURAV GULATI	Age	: 36Years 5Months 7Days
Speciality	: MEDICINE	Mobile No	: 9887152903
Address	: 15, NEW FIRENDS COLONY, JAIPUR ROAD WARD NO 27, ALWAR, Alwar, Alwar, Rajasthan	Panel	: MEDIWHEEL FOC

BP 130/40 mmHg  
SpO2 - 98%  
PR - 84 bpm  
TSH → 1.89  
B. Sugar → 83  
Hb - 11.4  
LFT? WNL  
KFT? WNL  
Lipid Profile - WNL  
2D Echo - 60% LVEF  
USG W/M - WNL

K/d/o HTN X 9 months  
(on Irregular medicine)  
Came for Routine checkup  
Patient has ADHD - Physically Intolerant

Have some  
Breathing issue → (use BIPAP overnight)  
Conscious/Alert. CG - SpO2  
PR - 80  
Chest B/LA2  
Adm.

- ① T. Amiloron 2.5mg OD to be continued
- ② Salt Restriction

Refers  
(Pulmonology Consult)  
Dr. Salite Raza

16/8/23

## DEPARTMENT OF RADIOLOGY

Patient Name	Mrs. ANU KHANDELWAL	Billed Date	: 16/08/2023	9.32 AM
Reg No	26981	Reported Date	: 16/08/2023	
Age/Sex	36 Years 5 Months 3Days / Female	Req. No.	: 23042902	
Type	OPD	Consultant Doctor	: Dr. CONSULTANT	

### USG WHOLE ABDOMEN

**LIVER** : The liver is normal in size, shape and echotexture. No evidence of any focal lesion. IHBR is not dilated.

**GALL BLADDER**: The gall bladder is not visualized (Post operative status). The common bile duct is normal.

**SPLEEN** :The spleen is normal in size and shape. Its echotexture is homogeneous. No evidence of focal lesion is noted.

**PANCREAS** :The pancreas is normal in size, shape, contours and echotexture.

**BILATERAL KIDNEYS** : The bilateral kidneys are normal in size and echotexture. Cortico-medullary differentiation is maintained. There is no evidence of obvious calculus or hydronephrosis seen. **Mild bilateral pelvi-calyceal fullness seen (due to overdistended UB).**

**URINARY BLADDER** :The urinary bladder is over distended. Wall thickness within normal limits. No evidence of calculus is seen. No evidence of mass or diverticulum is noted.


**UTERUS**: The uterus is normal in size, shape and echopattern. Endometrium echo is normal in thickness.

**BILATERAL OVARIES** are normal in size and echotexture. No adnexal mass lesion seen.

No free fluid is seen in peritoneal cavity.

No evidence of obvious retroperitoneal or mesentric lymphadenopathy is seen.

**IMPRESSION: USG WHOLE ABDOMEN REVEALS Mild bilateral pelvi-calyceal fullness (due to overdistended UB).**

  
DR BINOD KR CHAUDHARY  
MBBS, MD  
CONSULTANT RADIOLOGIST

(This is only professional opinion and not the diagnosis, Please correlate clinically)

J-Block, Sector-10, Near Court, Faridabad - 121004, Haryana

Tel.: 0129-4200000 E-mail : parkfaridabad@gmail.com

PARK GROUP OF HOSPITALS : West Delhi • South Delhi • Gurgaon • Karnal • Panipat • Hodal • Ambala • Behror

the health care providers

the health care providers



**DEPARTMENT OF PATHOLOGY**

Patient Name : Mrs. ANU KHANDELWAL  
MR No : 26981  
Age/Sex : 36 Years 5 Months 3 Days / Female  
Type : OPD  
TPA/Corporate : MEDIWHEEL

Bill Date : 12/08/2023  
Reporting Date : 13/08/2023  
Sample ID : 31660  
Bill/Req. No. : 23042902  
Ref Doctor : Dr.CONSULTANT

Test	Result	Bio. Ref. Interval	Units
<b>THYROID PROFILE</b>			
TRI-iodothyronine (T3)	0.84	0.60 - 1.81	ng/ml
Thyroxine (T4)	5.3	5.01 - 12.45	µg/dL
Thyroid Stimulating Hormone	1.89	0.5-5.50	µIU/ml

\*\*\*\*\* END OF THE REPORT \*\*\*\*\*

OUT SOURCE  
PARK HOSPITAL  
GGN



Sample no.

Dr. VAISHALI YADAV    Dr. REETU JADHAV    Dr. PARDIP KUMAR    S.C. GAUR  
CONS. PATHOLOGIST    CONS. PATHOLOGIST    MICROBIOLOGIST & ICO    LAB INCHARGE    USER NM    SEHDEV

(This is only professional opinion and not the diagnosis, Please correlate clinically)

J-Block, Sector-10, Near Court, Faridabad - 121004, Haryana  
Tel.: 0129-4200000 E-mail : parkfaridabad@gmail.com

**PARK GROUP OF HOSPITALS : West Delhi • South Delhi • Gurgaon • Karnal • Panipat • Hodal • Ambala • Behror**



**DEPARTMENT OF PATHOLOGY**


Patient Name : Mrs. ANU KHANDELWAL  
MR No : 26981  
Age/Sex : 36 Years 5 Months 3 Days / Female  
Type : OPD  
TPA/Corporate : MEDIWHEEL  
Bill Date : 12/08/2023  
Reporting Date : 12/08/2023  
Sample ID : 31660  
Bill/Req. No. : 23042902  
Ref Doctor : Dr. CONSULTANT

Test	Result	Bio. Ref. Interval	Units
------	--------	--------------------	-------

**BLOOD GROUPING AND RH FACTOR**

BLOOD GROUP	" B " RH NEGATIVE		
-------------	-------------------	--	--

\*\*\*\*\* END OF THE REPORT \*\*\*\*\*



Sample no.

Dr. VAISHALI YADAV    Dr. REETU JADHAV    Dr. PARDIP KUMAR    S.C. GAUR  
CONS. PATHOLOGIST    CONS. PATHOLOGIST    MICROBIOLOGIST & ICO    LAB INCHARGE    USER NM    PRIYANKA

(This is only professional opinion and not the diagnosis, Please correlate clinically)

J-Block, Sector-10, Near Court, Faridabad - 121004, Haryana

Tel.: 0129-4200000 E-mail : parkfaridabad@gmail.com

PARK GROUP OF HOSPITALS : West Delhi • South Delhi • Gurgaon • Karnal • Panipat • Hodal • Ambala • Behror

the health care providers

the health care providers





**DEPARTMENT OF PATHOLOGY**

Patient Name : Mrs. ANU KHANDELWAL  
MR No : 26981  
Age/Sex : 36 Years 5 Months 3 Days / Female  
Type : OPD  
TPA/Corporate : MEDIWHEEL

Bill Date : 12/08/2023  
Reporting Date : 12/08/2023  
Sample ID : 31660  
Bill/Req. No. : 23042902  
Ref Doctor : Dr.CONULTANT

Test	Result	Bio. Ref. Interval	Units
<b>BLOOD SUGAR 2 HR. PP</b>			
BLOOD SUGAR P.P.	83.19	80 - 150	mg/dl

\*\*\*\*\* END OF THE REPORT \*\*\*\*\*



Sample no.

Dr. VAISHALI YADAV    Dr.REETU JADHAV    Dr. PARDIP KUMAR    S.C.GAUR  
CONS.PATHOLOGIST    CONS.PATHOLOGIST    MICROBIOLOGIST & ICO    LAB INCHARGE    USER NM    PRIYANKA

(This is only professional opinion and not the diagnosis, Please correlate clinically)

J-Block, Sector-10, Near Court, Faridabad - 121004, Haryana  
Tel.: 0129-4200000 E-mail : parkfaridabad@gmail.com



**DEPARTMENT OF PATHOLOGY**

Patient Name : Mrs. ANU KHANDELWAL  
 MR No : 26981 Bill Date : 12/08/2023  
 Age/Sex : 36 Years 5 Months 3 Days / Female Reporting Date : 12/08/2023  
 Type : OPD Sample ID : 31660  
 TPA/Corporate : MEDIWHEEL Bill/Req. No. : 23042902  
 Ref Doctor : Dr.CONULTANT

Test	Result	Bio. Ref. Interval	Units
<b>URINE ROUTINE AND MICROSCOPY</b>			
<b>PHYSICAL CHARACTERSTICS</b>			
QUANTITY	40.0 ML	5 - 100	ML
COLOUR	Pale Yellow		
TURBIDITY	Turbid	clear	
SPECIFIC GRAVITY	1.010	1.003 - 1.030	
PH	7.0	Acidic	
<b>CHEMICAL EXAMINATION-1</b>			
URINE PROTEIN	NIL	NIL	
GLUCOSE	NIL	NIL	
<b>MICRO.EXAMINATION</b>			
PUS CELL	1 - 2/HPF		CELLS/HPF
RED BLOOD CELLS	Nil	0-2	CELLS/HPF
EPITHELIAL CELLS	6-8/HPF	0-5	CELLS/HPF
CASTS	NIL	NIL	CELLS/HPF
CRYSTALS	NIL	NIL	CELLS/HPF
OTHER	NIL		

\*\*\*\*\* END OF THE REPORT \*\*\*\*\*



Sample no.

Dr. VAISHALI YADAV    Dr.REETU JADHAV    Dr. PARDIP KUMAR    S.C.GAUR  
 CONS.PATHOLOGIST    CONS.PATHOLOGIST    MICROBIOLOGIST & ICO    LAB INCHARGE    USER NM    PRIYANKA

(This is only professional opinion and not the diagnosis, Please correlate clinically)

J-Block, Sector-10, Near Court, Faridabad - 121004, Haryana  
 Tel.: 0129-4200000 E-mail : parkfaridabad@gmail.com



## DEPARTMENT OF PATHOLOGY

Patient Name : Mrs. ANU KHANDELWAL  
 MR No : 26981  
 Age/Sex : 36 Years 5 Months 3 Days / Female  
 Type : OPD  
 TPA/Corporate : MEDIWHEEL

Bill Date : 12/08/2023  
 Reporting Date : 12/08/2023  
 Sample ID : 31660  
 Bill/Req. No. : 23042902  
 Ref Doctor : Dr.CONSULTANT

Test	Result	Bio. Ref. Interval	Units
<b>CBC</b>			
HAEMOGLOBIN	<b>11.4 L</b>	12 - 15	gm/dL
PACKED CELL VOLUME	35.0	35.0 - 50.0	%
RED BLOOD CELL COUNT	3.77	3.5 - 5.5	millions/ $\mu$ L
MEAN CORPUSCULAR VOLUME	92.9	83 - 101	fL
MEAN CORPUSCULAR HAEMOGLOBIN	30.2	27 - 31	pg
MEAN CORPUSCULAR HB CONC	<b>32.6 L</b>	33 - 37	g/dl
RDW	12.4	11.6 - 14.5	%
TOTAL LEUCOCYTE COUNT	5990	4000-11000	/ $\mu$ L
<b>DIFFERENTIAL COUNT</b>			
NEUTROPHILS	70	40.0 - 80.0	%
LYMPHOCYTES	25	20 - 40	%
MONOCYTES	04	2.0 - 10.0	%
EOSINOPHILS	01	0.0 - 5.0	%
BASOPHILS	00	0.0 - 2.0	%
PLATELET COUNT	2.73	1.50 - 4.50	lac/cumm

\*\*\*\*\* END OF THE REPORT \*\*\*\*\*



Sample no.

Dr. VAISHALI YADAV    Dr. REETU JADHAV    Dr. PARDIP KUMAR    S.C. GAUR  
 CONS.PATHOLOGIST    CONS.PATHOLOGIST    MICROBIOLOGIST & ICO    LAB INCHARGE    USER NM    PRIYANKA

(This is only professional opinion and not the diagnosis, Please correlate clinically)

J-Block, Sector-10, Near Court, Faridabad - 121004, Haryana

Tel.: 0129-4200000 E-mail : parkfaridabad@gmail.com

PARK GROUP OF HOSPITALS : West Delhi • South Delhi • Gurgaon • Karnal • Panipat • Hodal • Ambala • Behror



**DEPARTMENT OF PATHOLOGY**

Patient Name : Mrs. ANU KHANDELWAL  
 MR No : 26981 Bill Date : 12/08/2023  
 Age/Sex : 36 Years 5 Months 3 Days / Female Reporting Date : 12/08/2023  
 Type : OPD Sample ID : 31660  
 TPA/Corporate : MEDIWHEEL Bill/Req. No. : 23042902  
 Ref Doctor : Dr.CONSULTANT

Test	Result	Bio. Ref. Interval	Units
<b>LFT (LIVER FUNCTION TEST)</b>			
<b>LFT</b>			
TOTAL BILIRUBIN	0.4	0 - 1.2	mg/dL
DIRECT BILIRUBIN	0.2	0 - 0.4	mg/dL
INDIRECT BILIRUBIN	0.2	0.10 - 0.6	mg/dL
SGOT (AST)	20	0 - 45	U/L
SGPT (ALT)	18	0 - 45	U/L
ALKALINE PHOSPHATASE	104.8	30 - 170	IU/L
TOTAL PROTEIN	6.5	6.4 - 8.0	g/dL
ALBUMIN	3.8	3.3 - 5.5	g/dL
GLOBULIN	2.7	2.3 - 4.5	g/dL
A/G RATIO	1.41	1.1 - 2.2	

\*\*\*\*\* END OF THE REPORT \*\*\*\*\*



Sample no.

Dr. VAISHALI YADAV Dr.REETU JADHAV Dr. PARDIP KUMAR S.C.GAUR  
 CONS.PATHOLOGIST CONS.PATHOLOGIST MICROBIOLOGIST & ICO LAB INCHARGE USER NAME PRIYANKA

(This is only professional opinion and not the diagnosis, Please correlate clinically)

J-Block, Sector-10, Near Court, Faridabad - 121004, Haryana

Tel.: 0129-4200000 E-mail : parkfaridabad@gmail.com

PARK GROUP OF HOSPITALS : West Delhi • South Delhi • Gurgaon • Karnal • Panipat • Hodal • Ambala • Behror



**DEPARTMENT OF PATHOLOGY**

Patient Name : Mrs. ANU KHANDELWAL  
MR No : 26981  
Age/Sex : 36 Years 5 Months 3 Days / Female  
Type : OPD  
TPA/Corporate : MEDIWHEEL

Bill Date : 12/08/2023  
Reporting Date : 12/08/2023  
Sample ID : 31660  
Bill/Req. No. : 23042902  
Ref Doctor : Dr. CONSULTANT

Test	Result	Bio. Ref. Interval	Units
<b>KFT (RENAL PROFILE)</b>			
<b>KFT</b>			
SERUM UREA	15.0	10 - 45	mg/dL
SERUM CREATININE	0.50	0.4 - 1.4	mg/dL
SERUM URIC ACID	3.53	2.5 - 7.0	mg/dL
SERUM SODIUM	138	136 - 148	mmol/L
SERUM POTASSIUM	4.6	3.5 - 5.5	mmol/L
CHLORIDE	100.0	96 - 106	mmol/L

\*\*\*\*\* END OF THE REPORT \*\*\*\*\*



Sample no.

Dr. VAISHALI YADAV    Dr. REETU JADHAV    Dr. PARDIP KUMAR    S.C. GAUR  
CONS. PATHOLOGIST    CONS. PATHOLOGIST    MICROBIOLOGIST & ICO    LAB INCHARGE    USER NM    PRIYANKA

(This is only professional opinion and not the diagnosis, Please correlate clinically)

J-Block, Sector-10, Near Court, Faridabad - 121004, Haryana

Tel.: 0129-4200000 E-mail : parkfaridabad@gmail.com

PARK GROUP OF HOSPITALS : West Delhi • South Delhi • Gurgaon • Karnal • Panipat • Hodal • Ambala • Behror



**DEPARTMENT OF PATHOLOGY**

Patient Name : Mrs. ANU KHANDELWAL  
 MR No : 26981 Bill Date : 12/08/2023  
 Age/Sex : 36 Years 5 Months 3 Days / Female Reporting Date : 12/08/2023  
 Type : OPD Sample ID : 31660  
 TPA/Corporate : MEDIWHEEL Bill/Req. No. : 23042902  
 Ref Doctor : Dr.CONSULTANT

Test	Result	Bio. Ref. Interval	Units
<b>LIPID PROFILE</b>			
TOTAL CHOLESTEROL	181.93	120.0 - 200.0	mg/dL
SERUM TRIGLYCERIDES	75.26	40.0 - 160.0	mg/dl
HDL-CHOLESTEROL	51.90	30 - 70	mg/dl
VLDL CHOLESTEROL	15.05	6 - 32	mg/dL
LDL	114.98	50 - 135	mg/dl
LDL CHOLESTEROL/HDL RATIO	2.22	1.0 - 3.0	mg/dL
TOTAL CHOLESTEROL/HDL RATIO	3.51	2.0 - 5.0	mg/dl

\*\*\*\*\* END OF THE REPORT \*\*\*\*\*



Sample no.

Dr. VAISHALI YADAV    Dr.REETU JADHAV    Dr. PARDIP KUMAR    S.C.GAUR  
 CONS.PATHOLOGIST    CONS.PATHOLOGIST    MICROBIOLOGIST & ICO    LAB INCHARGE    USER NM    PRIYANKA

(This is only professional opinion and not the diagnosis, Please correlate clinically)

J-Block, Sector-10, Near Court, Faridabad - 121004, Haryana

Tel.: 0129-4200000 E-mail : parkfaridabad@gmail.com

**PARK GROUP OF HOSPITALS : West Delhi • South Delhi • Gurgaon • Karnal • Panipat • Hodal • Ambala • Behror**



**DEPARTMENT OF PATHOLOGY**

**Patient Name** : Mrs. ANU KHANDELWAL  
**MR No** : 26981  
**Age/Sex** : 36 Years 5 Months 3 Days / Female  
**Type** : OPD  
**TPA/Corporate** : MEDIWHEEL

**Bill Date** : 12/08/2023  
**Reporting Date** : 12/08/2023  
**Sample ID** : 31660  
**Bill/Req. No.** : 23042902  
**Ref Doctor** : Dr.CONSULTANT

Test	Result	Bio. Ref. Interval	Units
<b>BLOOD SUGAR FASTING</b>			
PLASMA GLUCOSE FASTING	79.02	60 - 110	mg/dl

\*\*\*\*\* END OF THE REPORT \*\*\*\*\*



Sample no.

Dr. VAISHALI YADAV    Dr. REETU JADHAV    Dr. PARDIP KUMAR    S.C. GAUR  
 CONS.PATHOLOGIST    CONS.PATHOLOGIST    MICROBIOLOGIST & ICO    LAB INCHARGE    USER NM    PRIYANKA

(This is only professional opinion and not the diagnosis, Please correlate clinically)

J-Block, Sector-10, Near Court, Faridabad - 121004, Haryana  
 Tel.: 0129-4200000 E-mail : parkfaridabad@gmail.com

**PARK GROUP OF HOSPITALS** : West Delhi • South Delhi • Gurgaon • Karnal • Panipat • Hodal • Ambala • Behror



# ECHO REPORT

Name of the patient: MRS. ANUKHANDELWAL Age: 36 Sex:  Male  Female

UHID No: 26981 IPD No: 23042902 Date: 12-8-2023

Refer By Doctor: DR. RAKESH ARORA

LVEF% 60%

**2D ECHO**

> Mitral Value Normal Pulmonary Value NI Pulm  
 > Artery NI  
 > Aortic avive NI Tricuspid valve NI

**2D RWMA**

> NO RWMA (Regional wall motion abnormality) at rest

**COLD DOPPLER**

> NO Significant Vavular stenosis / Regurgiation

**COMMENTS AND SUMMARY**

> All cardiac chambers of NO size and shape NO dilatation or hypertrophy.  
 > NO RWMA (Regional wall motion abnormality) at rest  
 > NO Cloth / Vegetation/ pericardial effusion  
 > LV 60% Systolic function  
 > NO Significant Vavular stenosis / Regurgiation

**Final Impression**

> EF at Rest 60%

**COMMENTS**

2DECHO & Color Doppler study  
WHL

**Consultant Cardiology**  
Doctor Name : Dr.  
Date :

Dr. Rakesh Kumar Arora  
MBBS, MD (Cardiology)  
Reg. No. 400436292  
Consultant Cardiology  
Park Hospital, Fardabad  
Version No: 1.1

Signature :  
Time :