



भारत सरकार

GOVERNMENT OF INDIA



अशिश मनु व्यास  
Ashish Manu Vyas

जन्म वर्ष / Year of Birth : 1972  
पुरुष / Male



8702 5010 2625

आधार — सामान्य माणसाचा अधिकार

*Ashish*

SUBURBAN ENTERPRISES (INDIA) PVT. LTD.  
102-104, Eastern Castle,  
Opp. Gerosson Sports Club,  
Link Road, Malad (W), Mumbai - 400 064.

CID#	: 2200870443	SID#	: 177804619125
Name	: MR.VYAS ASHISH MANU	Registered	: 08-Jan-2022 / 09:03
Age / Gender	: 49 Years/Male	Collected	: 08-Jan-2022 / 09:03
Consulting Dr.	: -	Reported	: 08-Jan-2022 / 11:56
Reg.Location	: Malad West (Main Centre)	Printed	: 09-Jan-2022 / 09:45

## PHYSICAL EXAMINATIONS REPORT

### History and Complaints:

Nil

### EXAMINATION FINDINGS:

<b>Height (cms):</b>	174 cms	<b>Weight (kg):</b>	85 kgs
<b>Temp (0c):</b>	Afebrile	<b>Skin:</b>	Normal
<b>Blood Pressure (mm/hg):</b>	128 / 80 mm of Hg	<b>Nails:</b>	Normal
<b>Pulse:</b>	92 / min	<b>Lymph Node:</b>	Normal

### Systems

**Cardiovascular:** Normal  
**Respiratory:** Normal  
**Genitourinary:** Normal  
**GI System:** Normal  
**CNS:** Normal

**IMPRESSION:** *Mild anemia*

**ADVICE:** *Further inv and tx of anemia.*

### CHIEF COMPLAINTS:

- 1) **Hypertension:** No
- 2) **IHD** No

**ADDRESS:** 2<sup>nd</sup> Floor, Aston, Sundervan Complex, Above Mercedes Showroom, Andheri West - 400053

**HEALTHLINE - MUMBAI:** 022-6170-0000 | **OTHER CITIES:** 1800-266-4343

**For Feedback -** customerservice@suburbandiagnosics.com | **www.suburbandiagnosics.com**

CID#	: 2200870443	SN#	: 177804619125
Name	: MR.VYAS ASHISH MANU	Registered	: 08-Jan-2022 / 09:03
Age / Gender	: 49 Years/Male	Collected	: 08-Jan-2022 / 09:03
Consulting Dr.	: -	Reported	: 08-Jan-2022 / 11:56
Reg.Location	: Malad West (Main Centre)	Printed	: 09-Jan-2022 / 09:45

- 3) Arrhythmia No
- 4) Diabetes Mellitus No
- 5) Tuberculosis No
- 6) Asthama No
- 7) Pulmonary Disease No
- 8) Thyroid/ Endocrine disorders No
- 9) Nervous disorders Bipolar disorder since 2013.
- 10) GI system No
- 11) Genital urinary disorder No
- 12) Rheumatic joint diseases or symptoms No
- 13) Blood disease or disorder No
- 14) Cancer/lump growth/cyst No
- 15) Congenital disease No
- 16) Surgeries Abscess on right ankle operated in 2016.Right knee ACL repair in 2018.Appendicectomy at the age of 18.
- 17) Musculoskeletal System No

**PERSONAL HISTORY:**

- 1) Alcohol No
- 2) Smoking No
- 3) Diet Veg
- 4) Medication Diva OD 1g

\*\*\* End Of Report \*\*\*



**DR. SONALI HONRAO**  
MD (G.MED)  
CONSULTING PHYSICIAN  
REG. NO.2001/04/1632

**Dr.Sonali Honrao**  
MD physician  
Sr. Manager-Medical Services  
(Cardiology)

**SUBURBAN DIAGNOSTICS (INDIA) PVT. LTD.**  
102-104, Bhamburda Castle,  
Opp. Garagade Sports Club,  
Link Road, Malad (W), Mumbai - 400 064.

**ADDRESS:** 2<sup>nd</sup> Floor, Aston, Sundervan Complex, Above Mercedes Showroom, Andheri West - 400053

**HEALTHLINE - MUMBAI:** 022-6170-0000 | **OTHER CITIES:** 1800-266-4343

**For Feedback -** customerservice@suburbandiagnosics.com | [www.suburbandiagnosics.com](http://www.suburbandiagnosics.com)



Use a QR Code Scanner Application To Scan the Code

CID : 2200870443
Name : Mr VYAS ASHISH MANU
Age / Sex : 49 Years/Male
Ref. Dr :
Reg. Location : Malad West Main Centre

Reg. Date : 08-Jan-2022 / 09:47
Report Date : 08-Jan-2022 / 10:01

USG WHOLE ABDOMEN

LIVER:

The liver is normal in size (13.6 cm), shape and smooth margins. It shows normal parenchymal echo pattern. The intra hepatic biliary and portal radical appear normal. No evidence of any intra hepatic cystic or solid lesion seen. The main portal vein and CBD appears normal.

GALL BLADDER:

The gall bladder is physiologically distended and appears normal. No evidence of gall stones or mass lesions seen

PANCREAS:

The pancreas head and partial body is visualized and appears normal. No evidence of solid or cystic mass lesion. Rest of the pancreas is obscured due to bowel gas shadow.

KIDNEYS:

Both the kidneys are normal in size, shape and echotexture. No evidence of any calculus, hydronephrosis or mass lesion seen. Right kidney measures 11.7 x 4.4 cm. Left kidney measures 11.2 x 3.1 cm.

SPLEEN:

The spleen is normal in size (11.0 cm), and echotexture. No evidence of focal lesion is noted. There is no evidence of any lymphadenopathy or ascites.

URINARY BLADDER:

The urinary bladder is well distended and reveal no intraluminal abnormality.

PROSTATE:

The prostate is normal in size and volume is 22.0 cc.

IMPRESSION:

No significant abnormality is seen.

Suggestion :- Clinicopathological correlation.

Note : Investigations have their limitations. Solitary radiological investigations never confirm the final diagnosis. They only help in diagnosing the disease in correlation to clinical symptoms and other related tests. USG is known to have inter-observer variations. Further / Follow-up imaging may be needed in some case for confirmation of findings. Patient has been explained in detail about the USG findings including its limitations and need for further imaging if clinically indicated. Please interpret accordingly. All the possible precaution have been taken under covid-19 pandemic.

-----End of Report-----

Handwritten signature of Dr. Vivek Singh

Dr. Vivek Singh
MD Radiodiagnosis
Reg No: 2013/03/0388

Click here to view images http://202.143.96.162/Suburban/Viewer?ViewerType=3&AccessionNo=2200870443



**CID** : 2200870443  
**Name** : Mr VYAS ASHISH MANU  
**Age / Sex** : 49 Years/Male  
**Ref. Dr** :  
**Reg. Location** : Malad West Main Centre

**Reg. Date** : 08-Jan-2022 / 09:29  
**Reported** : 08-Jan-2022 / 12:57

**X-RAY CHEST PA VIEW**

Both lung fields are clear.

Both costo-phrenic angles are clear.

The cardiac size and shape are within normal limits.

The domes of diaphragm are normal in position and outlines.

The skeleton under review appears normal.

**IMPRESSION:**

**NO SIGNIFICANT ABNORMALITY IS DETECTED.**

**TO BE CORRELATED CLINICALLY.**

Note: Investigations have their limitations. Solitary radiological investigations never confirm the final diagnosis. They only help in diagnosing the disease in correlation to clinical symptoms and other related tests. X-rays are known to have inter-observer variations. Further / Follow-up imaging may be needed in some case for confirmation of findings. Please interpret accordingly.

-----End of Report-----

**Dr. Vivek Singh**  
**MD Radiodiagnosis**  
**Reg No: 2013/03/0388**

Click here to view images <http://202.143.96.162/Suburban/Viewer?ViewerType=3&AccessionNo=2022010809042675>

Date:- 8/10/2022  
Name:- Ashish Vyas

CID: 57007/0443  
Sex / Age: M / 49 Yrs

## EYE CHECK UP

Chief complaints: Nil

Systemic Diseases: Nil

Past history: Nil

Unaided Vision: —

Aided Vision: 80-6/5      50-2/6

Refraction: —

(Right Eye)

(Left Eye)

	Sph	Cyl	Axis	Vn	Sph	Cyl	Axis	Vn
Distance								
Near								

Colour Vision: Normal / Abnormal colour Blindness

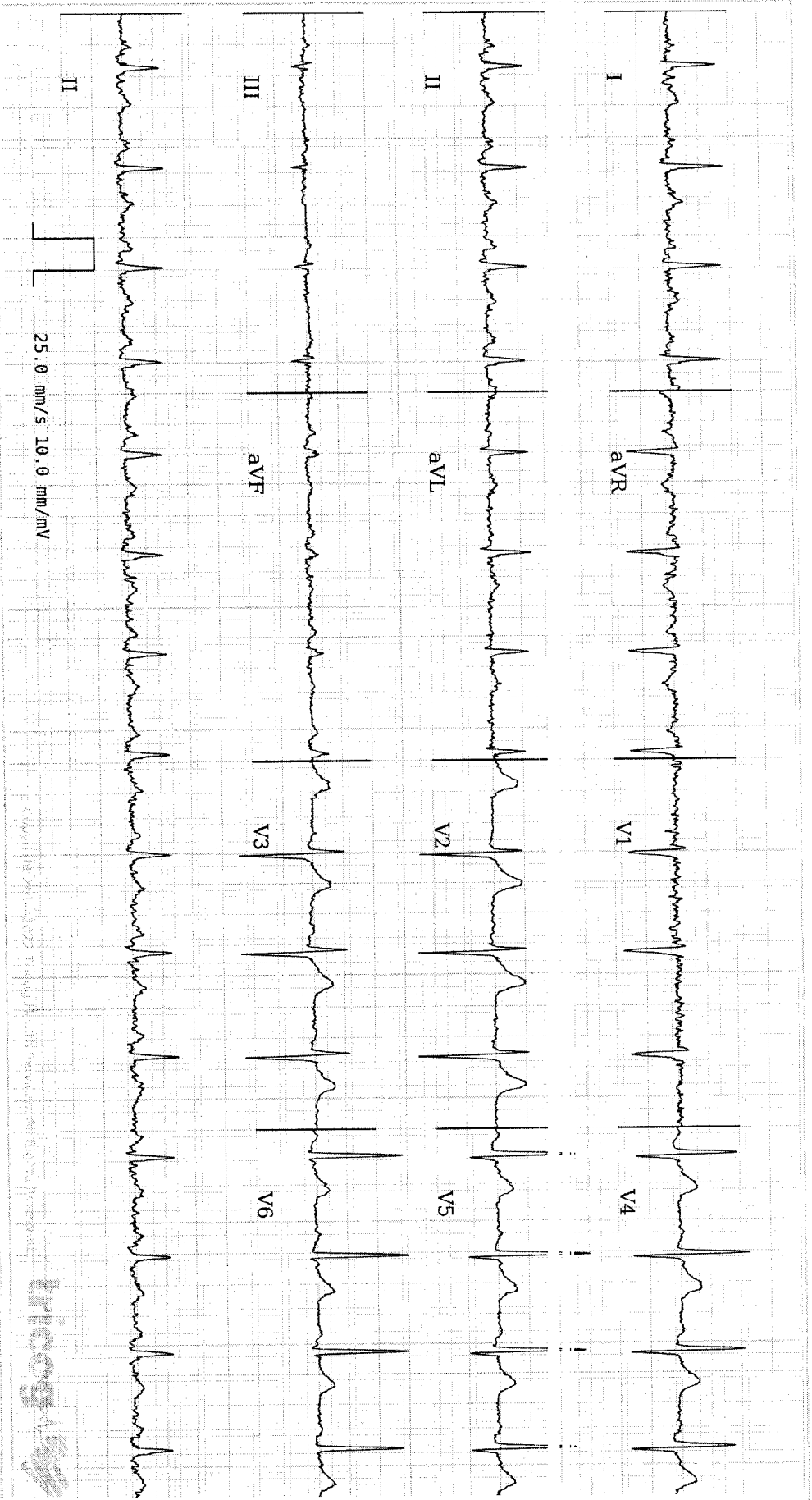
Remark: —

SUBURBAN DIAGNOSTICS PRIVATE LIMITED  
 2nd Floor, Aston, Sundervan Complex, Above Mercedes Showroom, Andheri West - 400053  
 HEALTHLINE - MUMBAI: 022-6170-0000 | OTHER CITIES: 1800-266-4343  
 For Feedback - customerservice@suburbandiagnostics.com | www.suburbandiagnostics.com

ADDRESS: 2<sup>nd</sup> Floor, Aston, Sundervan Complex, Above Mercedes Showroom, Andheri West - 400053

HEALTHLINE - MUMBAI: 022-6170-0000 | OTHER CITIES: 1800-266-4343

For Feedback - customerservice@suburbandiagnostics.com | www.suburbandiagnostics.com



Age **49** 3 15  
 years months days

Gender **Male**

Heart Rate **94 bpm**

Patient Vitals

Weight: **85 kg**

Height: **174 cm**

Pulse: **92 bpm**

SpO2: **NA**

Resp: **NA**

Others:

**Measurements**

QS RD: **80 ms**

QT: **350 ms**

QTc: **437 ms**

PR: **136 ms**

P-R-T: **52° 21° 29°**

REPORTED BY

*[Signature]*

**DR SONALI HONRAO**  
 MD (General Medicine)  
 Physician

2001/04/1882

**ECG Within Normal Limits: Sinus Rhythm, Normal Axis. Please correlate clinically.**

Disclaimer: 1) Analysis in this report is based on ECG alone and should be used as an adjunct to clinical history, symptoms, and results of other invasive and non-invasive tests and must be interpreted by a qualified physician. 2) Patient vitals are as entered by the clinician and not derived from the ECG.