



Manavata

Pathology & Microbiology Laboratory

Dr. Kailash B. Wagh

M.D. Microbiology D.C.P
Reg No. 2001/07/2704

REG NO. : 07-2023-OPD / 17
NAME : Mrs. MUSKAN KUMARI
REF BY : Dr. Sunil Suryavanshi (Insurance)
M.D.

AGE : 23 Years
SEX : Female
DATE : 29-Jul-2023

LOCATION :

HAEMOGRAM

<u>TESTS</u>	<u>RESULTS</u>	<u>UNIT</u>	<u>REFERENCE RANGE</u>
Haemoglobin	: 12.1	g/dl	11 - 18
WBC COUNT			
Total WBC Count	: 7800	/cmm	4000 - 11000
DIFFERENTIAL COUNT			
Neutrophil	: 68	%	40 - 74
Lymphocyte	: 25	%	15 - 45
Eosinophil	: 03	%	0 - 7
Monocyte	: 04	%	1 - 10
Basophil	: 00	%	0 - 1
RBC INDICES			
Hct	: 36.2	%	33 - 60
R.B.C. count	: 5.86	mil./cmm.	4.0 - 6.0
Mcv	: 92.0	fL	76 - 94
Mch	: 32.8	pg	25 - 33
Mchc	: 33.7	%	32 - 38
PLATELETS INDICES			
Plt Count	: 326000	/cmm	150000 - 450000
RBC Morphology	: Normocytic Normocytic		
WBC Studies	: Normal Morphology		
Platelet	: Adequate		
ESR	: 10	mm/hr	00 - 20

THANKS FOR REFERRAL



KBW
Dr. Kailash B. Wagh
MD (Micro) DCP

Dr. Kailash B. Wagh
M.D. Microbiology D.C.P.
Reg. No. 2001/07/2704

98 Jilha Peth, Kantal Sabhagruh Road, Near Barde Medical, Jalgaon-425001
☎ 0257-2970978, 2225322 ☑ 9405887735



Scanned with OKEN Scanner



Manavata

Pathology & Microbiology Laboratory

Dr. Kailash B. Wagh

M.D. Microbiology D.C.P

Reg No. 2001/07/2704

REG NO. : 07-2023-OPD / 17
NAME : Mrs. MUSKAN KUMARI
REF BY : Dr . Sunil Suryavanshi (Insurance)
M.D.

AGE : 23 Years

SEX : Female

DATE : 29-Jul-2023

LOCATION :

BLOOD GROUP


BLOOD GROUP : "AB" Rh Positive

NOTE : Grouping and cross matching is compulsory before blood transfusion, as errors can occur due to irregular antibodies.

K.B.W.
Dr. Kailash B. Wagh
MD (Micro) DCP

THANKS FOR REFERRAL

Dr. Kailash B. Wagh
M.D. Microbiology D.C.P
Reg. No. 2001/07/2704



98 Jilha Peth, Kantai Sabhagruh Road, Near Barde Medical, Jalgaon- 425001

0257-2970978, 2225322 9405887735



Scanned with OKEN Scanner



Manavata

Pathology & Microbiology Laboratory

Dr. Kailash B. Wagh

M.D. Microbiology D.C.P
Reg No. 2001/07/2704

REG NO : 07-2023-OPD / 17
NAME : Mrs. MUSKAN KUMARI
REF BY : Dr. Sunil Suryavanshi (Insurance)
M.D.

AGE : 23 Years
SEX : Female
DATE : 29-Jul-2023

LOCATION :

HbA1C

<u>TESTS</u>	<u>RESULTS</u>	<u>UNIT</u>
HbA1C	: 4.8	%

AVERAGE BLOOD SUGAR (ABG)	: 91	mg/dl
---------------------------	------	-------


Reference Range :

Below 6.0% - Normal Value
6.0% - 7.0% - Good Control
7.0% - 8.0% - Fair Control
8.0% - 10% - Unsatisfactory Control
Above 10% - Poor Control

Method : Fully Automated H.P.L.C. using Blorad Variant II Turbo, NGSP Certified.

Please correlate with clinical conditions.

THANKS FOR REFERRAL


Dr. Kailash B. Wagh

MD (Micro) DCP

Dr. Kailash B. Wagh

M.D. Microbiology D.C.P.

Reg. No. 2001/07/2704



98 Jilha Peth, Kantai Sabhagruh Road, Near Barde Medical, Jalgaon- 425001

0257-2970978, 2225322 9405887735



Scanned with OKEN Scanner



Manavata

Pathology & Microbiology Laboratory

Dr. Kailash B. Wagh

M.D. Microbiology D.C.P

Reg No. 2001/07/2704

REG NO. : 07-2023-OPD / 17
NAME : Mrs. MUSKAN KUMARI
REF BY : Dr. Sunil Suryavanshi (Insurance)
M.D.

AGE : 23 Years

SEX : Female

DATE : 29-Jul-2023

LOCATION :

BLOOD SUGAR FASTING & POST-PRANDIAL

<u>TESTS</u>	<u>RESULTS</u>	<u>UNIT</u>	<u>REFERENCE RANGE</u>
BLOOD SUGAR FASTING	: 76	mg/dl	70 - 110
URINE SUGAR FASTING	: Nil		
BLOOD SUGAR PP	: 102	mg/dl	70 - 140
URINE SUGAR PP	: Nil		

LIVER FUNCTION TEST

<u>TESTS</u>	<u>RESULTS</u>	<u>UNIT</u>	<u>REFERENCE RANGE</u>
BILIRUBIN- TOTAL	: 0.89	mg/dl	0 - 1.0
BILIRUBIN- DIRECT	: 0.25	mg/dl	0 - 0.3
BILIRUBIN- INDIRECT	: 0.64	mg/dl	0.1 - 1.0
SGPT	: 24	IU/L	0 - 40
SGOT	: 35	IU/L	0 - 45
ALKALINE PHOSPHATASE	: 268	IU/L	25 - 350
TOTAL PROTIEN	: 7.25	gm/dl	6 - 8
ALBUMIN	: 4.58	gm/dl	3.5 - 5
GLOBULIN	: 2.67	gm/dl	2 - 3.5
A/G Ratio	: 2.01		2 - 2.5
GGTP	: 19	IU/l	0 - 25

Dr. Kailash B. Wagh

MD (Micro) DCP

Dr. Kailash B. Wagh

M.D. Microbiology D.C.P.

Reg. No. 2001/07/2704



THANKS FOR REFERRAL

98 Jilha Peth, Kantai Sabhagruh Road, Near Barde Medical, Jalgaon- 425001

0257-2970978, 2225322 9405887735



Scanned with OKEN Scanner



Manavata

Pathology & Microbiology Laboratory

Dr. Kailash B. Wagh

M.D. Microbiology D.C.P
Reg No. 2001/07/2704

REG NO. : 07-2023-OPD / 17
NAME : Mrs. MUSKAN KUMARI
REF BY : Dr. Sunil Suryavanshi (Insurance)
M.D.

AGE : 23 Years
SEX : Female
DATE : 29-Jul-2023

LOCATION :

RENAL FUNCTION TEST

<u>TESTS</u>	<u>RESULTS</u>	<u>UNIT</u>	<u>REFERENCE RANGE</u>
BLOOD UREA NITROGEN	: 12	mg/dl	5 - 21
CREATININE	: 0.79	mg/dl	0.7 - 1.4
URIC ACID	: 5.86	mg/dl	2.6 - 6.0

LIPID PROFILE

<u>TESTS</u>	<u>RESULTS</u>	<u>UNIT</u>	<u>REFERENCE RANGE</u>
TOTAL CHOLESTEROL	: 199	mg/dl	140 - 250
TRIGLYCERIDES	: 79	mg/dl	40 - 140
HDL- CHOLESTEROL	: 49.75	mg/dl	32 - 90
LDL- CHOLESTEROL	: 133.45	mg/dl	80 - 150
VLDL-CHOLESTEROL	: 15.8	mg/dl	10 - 35
TOTAL CHO/HDL RATIO	: 4		0 - 5.1
LDL/HDL RATIO	: 2.68	mg/dl	0 - 3.5
NON HDL CHOLESTEROL	: 149.25	mg/dl	0 - 160

THANKS FOR REFERRAL

KBW
Dr. Kailash B. Wagh
MD (Micro) DCP

Dr. Kailash B. Wagh
M.D. Microbiology D.C.P.
Reg. No. 2001/07/2704



9 98 Jilha Peth, Kantai Sabhagruh Road, Near Barde Medical, Jalgaon- 425001

☎ 0257-2970978, 2225322 ☎ 9405887735



Scanned with OKEN Scanner



Manavata

Pathology & Microbiology Laboratory

Dr. Kailash B. Wagh

M.D. Microbiology D.C.P
Reg No. 2001/07/2704

REG NO. : 07-2023-OPD / 17
NAME : Mrs. MUSKAN KUMARI
REF BY : Dr. Sunil Suryavanshi (Insurance)
M.D.

AGE : 23 Years
SEX : Female
DATE : 29-Jul-2023

LOCATION :

THYROID TEST

<u>TESTS</u>	<u>RESULTS</u>	<u>UNIT</u>	<u>REFERENCE RANGE</u>
T3	: 121	ng/ml	87 - 178
T4	: 7.93	µg/dl	6.06 - 12.23
ULTRA TSH	: 2.40	µIU/ml	0.34 - 5.6

NOTE

: Test Done On Fully Automated Mindray CL 900i Hormone Assay BY CLIA

THANKS FOR REFERRAL

K.B.W.
Dr. Kailash B. Wagh
MD (Micro) DCP

Dr. Kailash B. Wagh
M.D. Microbiology D.C.P.
Reg. No. 2001/07/2704



98 Jilha Peth, Kantai Sabhagruh Road, Near Barde Medical, Jalgaon- 425001
☎ 0257-2970978, 2225322 ☎ 9405887735



Scanned with OKEN Scanner



Manavata

Pathology & Microbiology Laboratory

Dr. Kailash B. Wagh

M.D. Microbiology D.C.P

Reg No. 2001/07/2704

REG NO. : 07-2023-OPD / 17
NAME : Mrs. MUSKAN KUMARI
REF BY : Dr. Sunil Suryavanshi (Insurance)
M.D.

AGE : 23 Years

SEX : Female

DATE : 29-Jul-2023

LOCATION :

URINE ANALYSIS REPORT

<u>TESTS</u>	<u>RESULTS</u>	<u>UNIT</u>	<u>REFERENCE RANGE</u>
PHYSICAL EXAMINATION			
QUANTITY	: 10 ml		
COLOUR	: Pale Yellow		
APPEARANCE	: Clear		
DEPOSITS	: Absent		
SPECIFIC GRAVITY	: 1.021		1.002 - 1.030
REACTION (PH)	: Acidic		
CHEMICAL EXAMINATION			
PROTEINS	: Absent		
SUGAR	: Absent		
KETONE	: Absent		
BILE SALTS/BILE PIGMENTS	: Absent		
MICROSCOPIC EXAMINATION			
RBC	: Absent	/hpf	
PUS CELLS	: 2-3	/hpf	
EPITHELIAL CELLS	: Few	/hpf	
CASTS	: Absent		
CRYSTALS	: Absent		
AMORPHOUS DEPOSITS	: Absent		

K.B.W.
Dr. Kailash B. Wagh
MD (Micro) DCP

THANKS FOR REFERRAL

Dr. Kailash B. Wagh
M.D. Microbiology D.C.P.
Reg. No. 2001/07/2704



98 Jilha Peth, Kantai Sabhagruh Road, Near Barde Medical, Jalgaon- 425001

☎ 0257-2970978, 2225322 ☐ 9405887735



Scanned with OKEN Scanner

सुजय हॉस्पिटल व मॅटर्निटी होम

अतिवक्षता विभाग

डॉ.सौ. जयश्री सुर्यवंशी
एम.डी.
(स्त्रीरोग व प्रसूतीशास्त्र तज्ञ)
रजि.नं. ३७१२

डॉ.सुनिल सुर्यवंशी
एम.डी.(मेडीसीन) पुणे
कन्सल्टिंग फिजिशियन हृदयरोग व मधुमेह तज्ञ
रजि.नं. ७४६११

भेन टेलिफोन एक्सचेंज समोर, पारिक पार्क, नविन बस स्टॅन्डच्या मागे,
जळगांव. फोन : (०२५७) २२२७८२१

Rx Apollo clinic दि. 29/07/2023

Murkan kumar

• Dietic Advice :

Low fat, low carbohydrate, high

• Protein intake

• ECG Exam - Normal

• Ophthalmology Exam - Normal intake
spectacles.

BMI :- 27.


Dr. Sunil Suryawanshi
M.D. (Medicine)
Reg. No. 2223


CERTIFICATE OF MEDICAL FITNESS

This is to certify that I have conducted the clinical examination

of Muskan Kumari on 29/07/2023

After reviewing the medical history and on clinical examination it has been found that he/she is

	Tick
<ul style="list-style-type: none"> • Medically fit 	✓
<ul style="list-style-type: none"> • Fit with restrictions/recommendations <p>Though following restrictions have been revealed, in my opinion, these are not impediments to the job.</p> <p>1..... —</p> <p>2..... —</p> <p>3..... —</p> <p>However the employee should follow the advice/medication that has been communicated to him/her.</p> <p>Review after _____</p>	—
<ul style="list-style-type: none"> • Currently Unfit. Review after _____ recommended 	—
<ul style="list-style-type: none"> • Unfit 	—

Dr. 
 Medical Officer
 The Apollo Clinic, (Location)

Dr. Sunil Suryawanshi
M.D.(Medicine)
Reg.No.2223

This certificate is not meant for medico-legal purposes

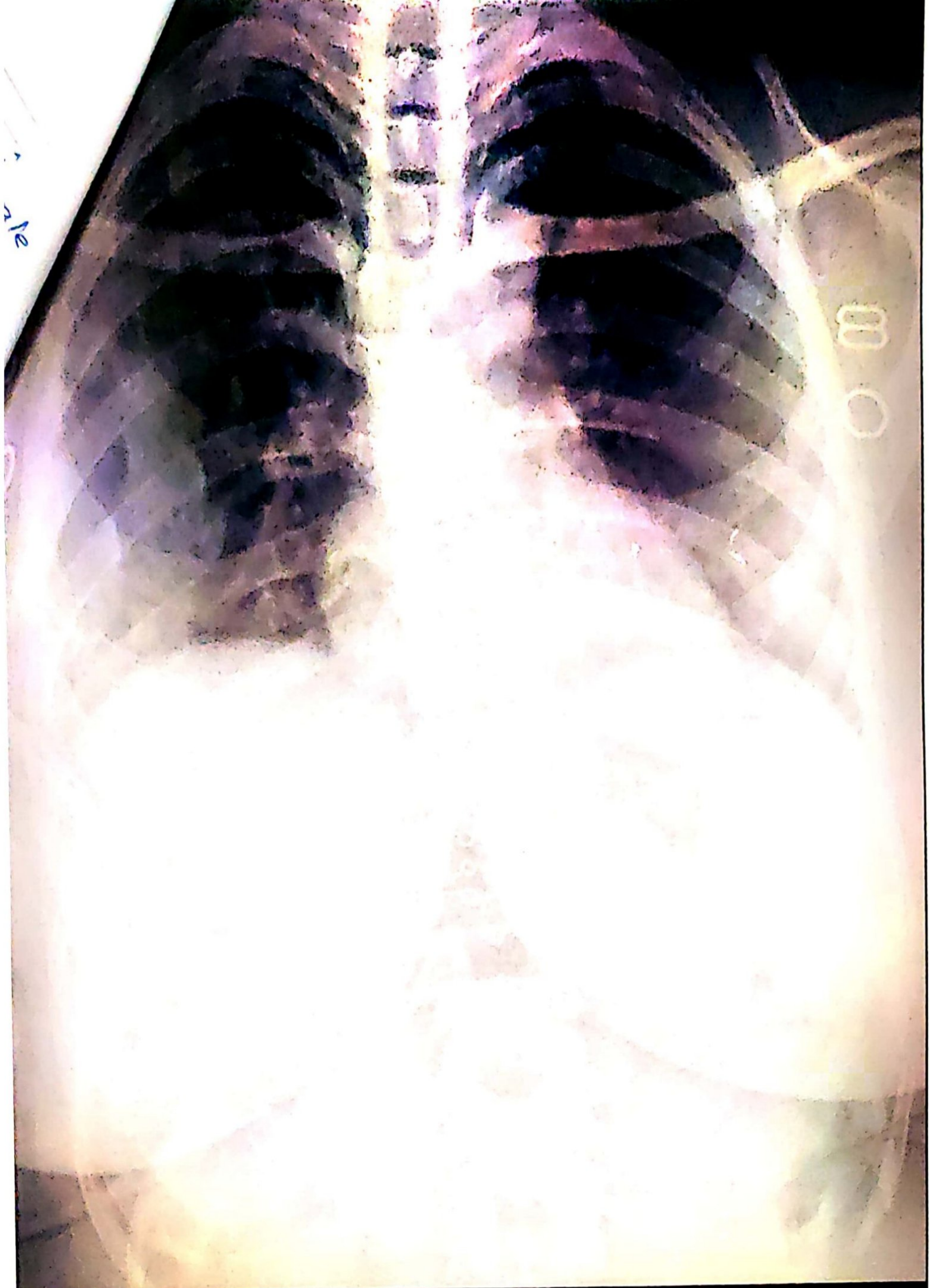
MER- MEDICAL EXAMINATION REPORT

Date of Examination	29/07/2023	
NAME	Muskan Kumari	
AGE	23	Gender Female
HEIGHT(cm)	142	WEIGHT (kg) 54
B.P.	120/80	
ECG	✓	
X Ray	✓	
Vision Checkup	Color Vision : normal/normal Far Vision Ratio : 6/6 / 6/6 Near Vision Ratio : normal/normal	
Present Ailments	no any	
Details of Past ailments (If Any)	no any	
Comments / Advice : She /He is Physically Fit	Yes (Fit)	
BMI \Rightarrow 27		

Handwritten notes or stamps, partially illegible.

Signature with Stamp of Medical Examiner

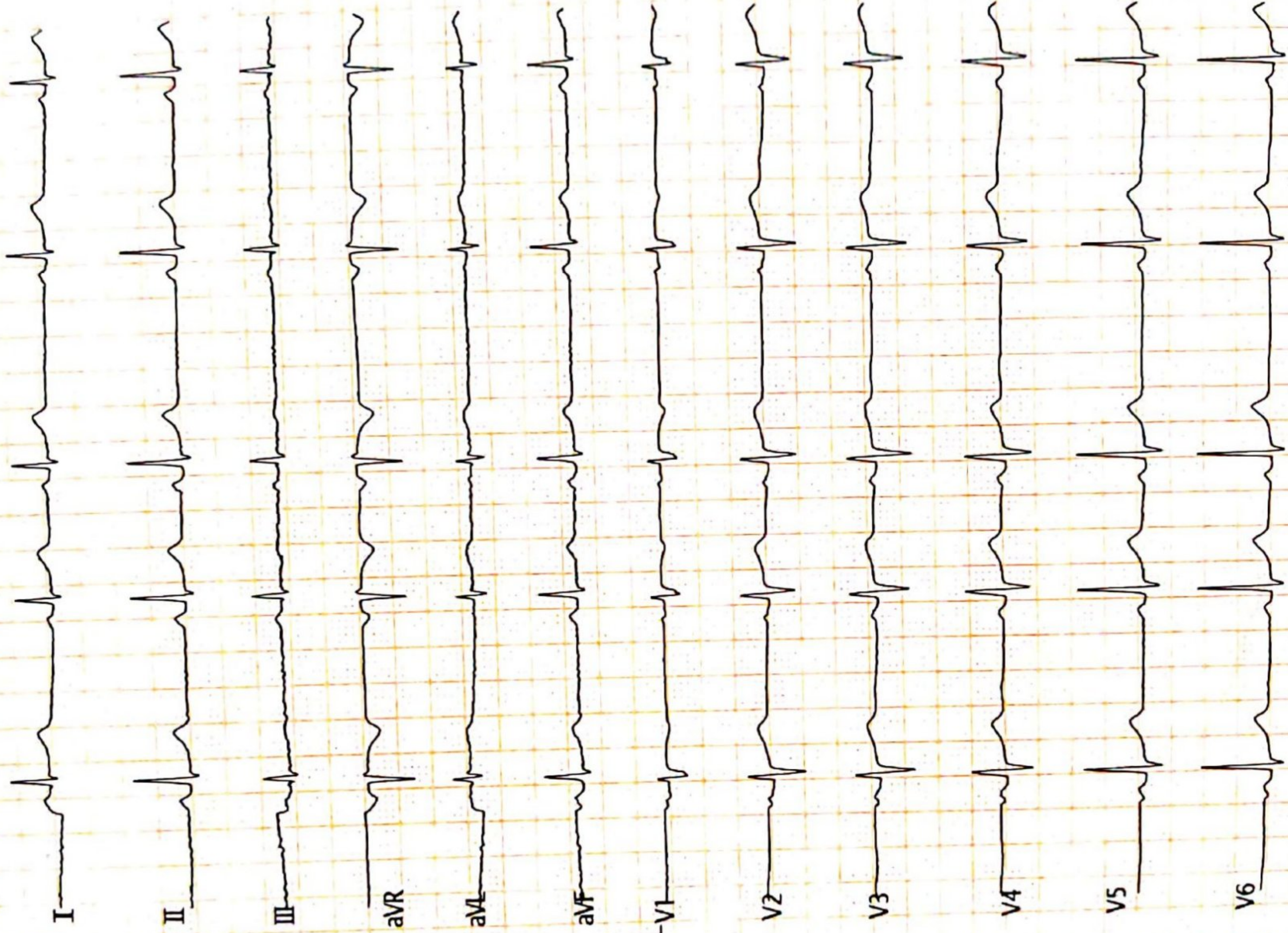
Dr. Sunil Suryawanshi
M.D.(Medicine)
Reg.No.2223



MUSKAN KUMARI 23Y 297202304 CHEST PA 29-Jul-23

SUJAY HOSPITAL AND MATERNITY HOME, JALGAON

10mm/mV



Vent. Rate(BPM): 66

PR Int.(ms): 135

P/QRS/T Int.(ms): 96 103 183

QT/QTc Int.(ms): 395 421

P/QRS/T Axis(Deg.): 64 57 37

RV1/SV5 Amp.(mV): 0.17 0.20

RV5/SV1 Amp.(mV): 0.95 0.24

Technician: V2.35

ECG Abnormal

800 Normal Sinus Rhythm

84 PAC Trigeminy

Abnormal ECG

Normal

[Handwritten Signature]

Dr. Sunil Suryawanshi
M.D. (Medicine)
Reg.No.2223

ST LEVEL(mV)

I	II	III	aVR	aVL	aVF
+0.01	+0.01	+0.00	-0.01	+0.00	+0.00
V1	V2	V3	V4	V5	V6
+0.02	+0.06	+0.05	+0.03	+0.02	+0.01

Muskan Kumari



जयश्री सुर्यवंशी

डॉ. सुनिल सुर्यवंशी

प्रसूतीशास्त्र तज्ञ
3712

एम.डी. (मेडीसीन) पुणे
कन्सल्टिंग फिजिशियन
रजि.नं. 2223

पता : मेन टेलिफोन एक्सचेंज समोर, पारिख
पार्क जवळ, नविन बस स्टॅन्डच्या मागे,
जळगांव. फोन : (0257) 2227821

सुविधा : • एक्स-रे • सोनोग्राफी • इकोकार्डिओग्राफी • सुसज्ज ऑपरेशन थिएटर • कॉम्प्युटाईज्ड इ.सी.जी. • स्ट्रेस टेस्ट • पल्मोनरी फंक्शन टेस्ट

Rx

दि / / 20

2D – Echocardiograph

Name – MUSKAN KUMARI

Age- 23 Yrs FEMALE

Date – 29/07/2023

IMPRESSION –

NORMAL SIZE CARDIAC CHAMBERS.

STRUCTURALLY NORMAL CARDIAC VALVES

NORMAL LV SYSTOLIC FUNCTION , EF-60 %.

NORMAL LV DIASTOLIC FUNCTION .

NO RWMA.

NO CLOTS OR VEGETATION.

IAS AND IVS INTACT.

NORMAL PERICARDIUM

Dr Sunil Suryawanshi

M D medicine.

Dr. Sunil Suryawanshi

M.D.(Medicine)

Reg.No.2223

परत येतांना कागद सोबत आणावा.

Cardiac Func. Exam.

<M mode LV Function>

	Pombo	Teichholz
EDV	69ml	74ml
ESV	20ml	28ml
SV	49ml	47ml
CO	3.53l/m	3.37l/m
EF	70.4%	62.5%
FS	33.3%	
HR	72BPM	

	Diastole	Systole
LVID	41mm	27mm
IVS	7mm	10mm
LVPW	7mm	11mm

<LA/AO>	Diastole	Systole
LA Diam		25mm
AO Diam	25mm	
AV Diam		17mm

LADs/AODd	1.01	AVA
-----------	------	-----

<Mitral Valve>

C-E amp	9mm	C-A amp	5mm
E-F slope	102mm/s	EPSS	8mm

E/A	1.67
MVA	

<Aortic Stenosis Flow Doppler>

Peak V	103.2cm/s	Mean V	66.2cm/s
VTI	20.7cm	VTI (LVOT)	
LVOT		CSA (LVOT)	

AVA		AVA	
Peak PG	4.3mmHg	Mean PG	2.0mmHg

<Trans Mitral Flow Doppler>

Peak E	76.5cm/s	Adur	
Peak A	40.9cm/s		
PVAdur			
VTI			
DecT		P1/2T	76ms

MVA(P1/2T)	2.91cm ²	MVA	
E/A	1.87		
PVAdur-Adur			

<Pulmonary Stenosis Flow Doppler>

Peak V	94.3cm/s	Mean V	66.8cm/s
Peak PG	3.6mmHg	Mean PG	1.9mmHg

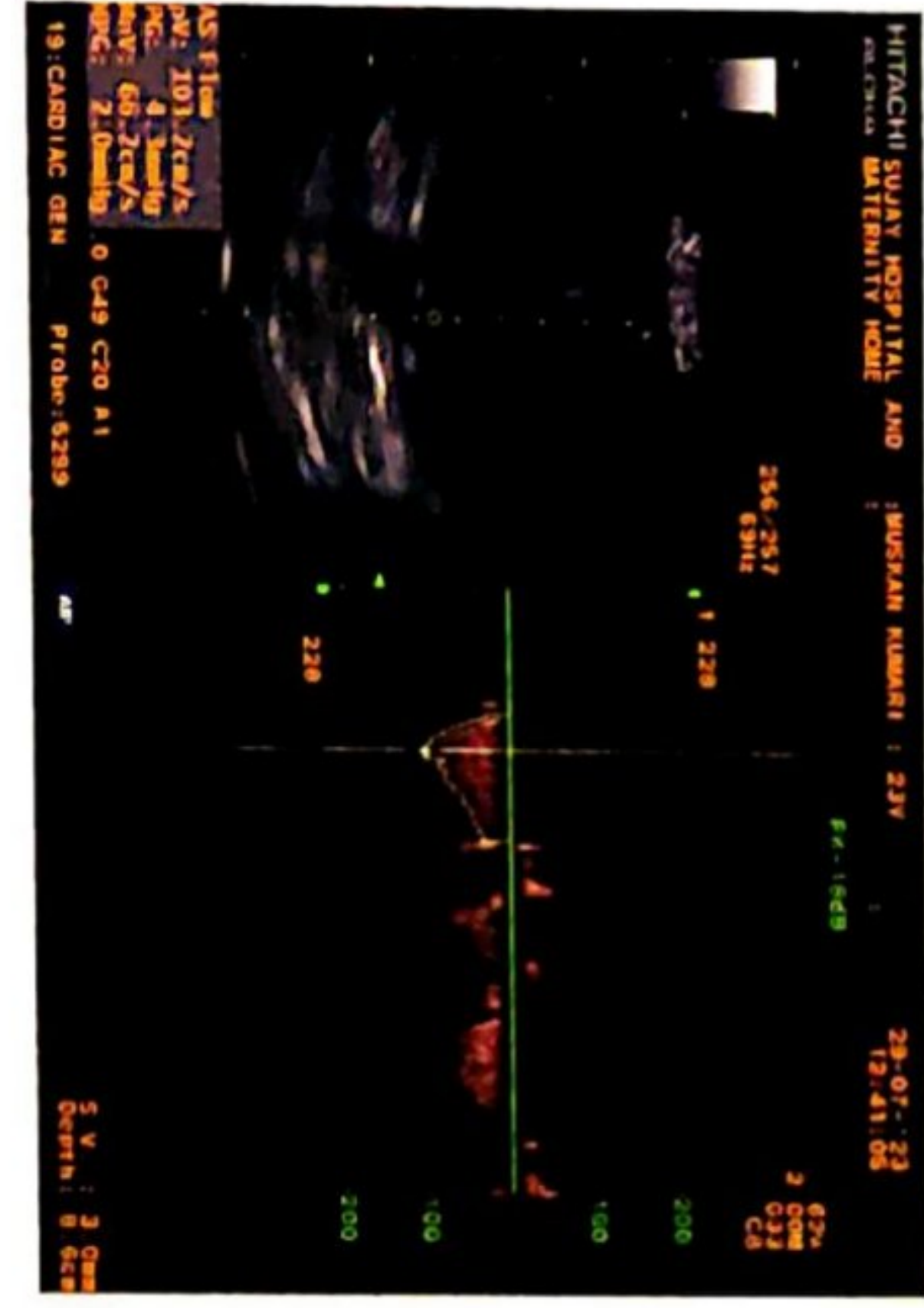
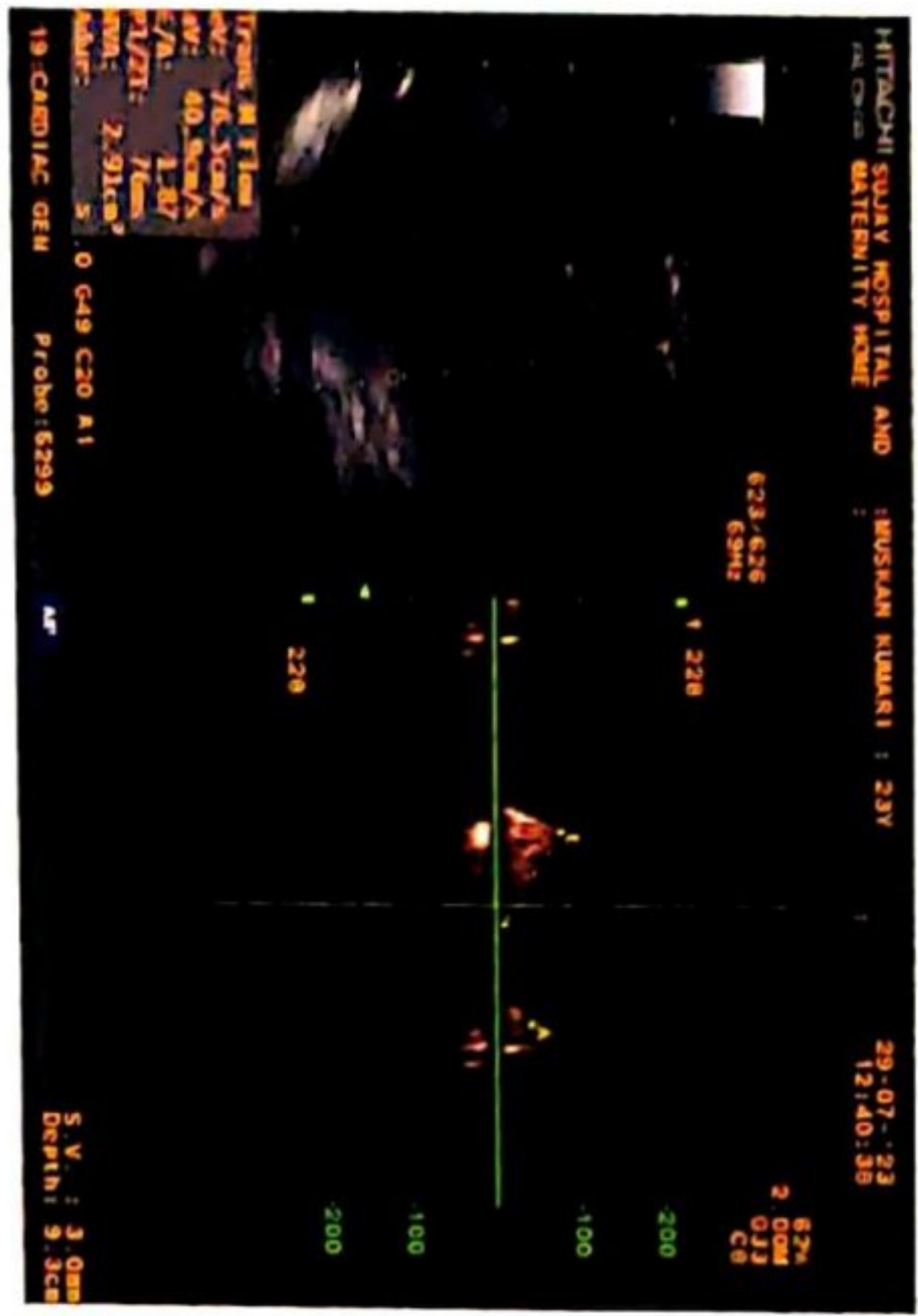
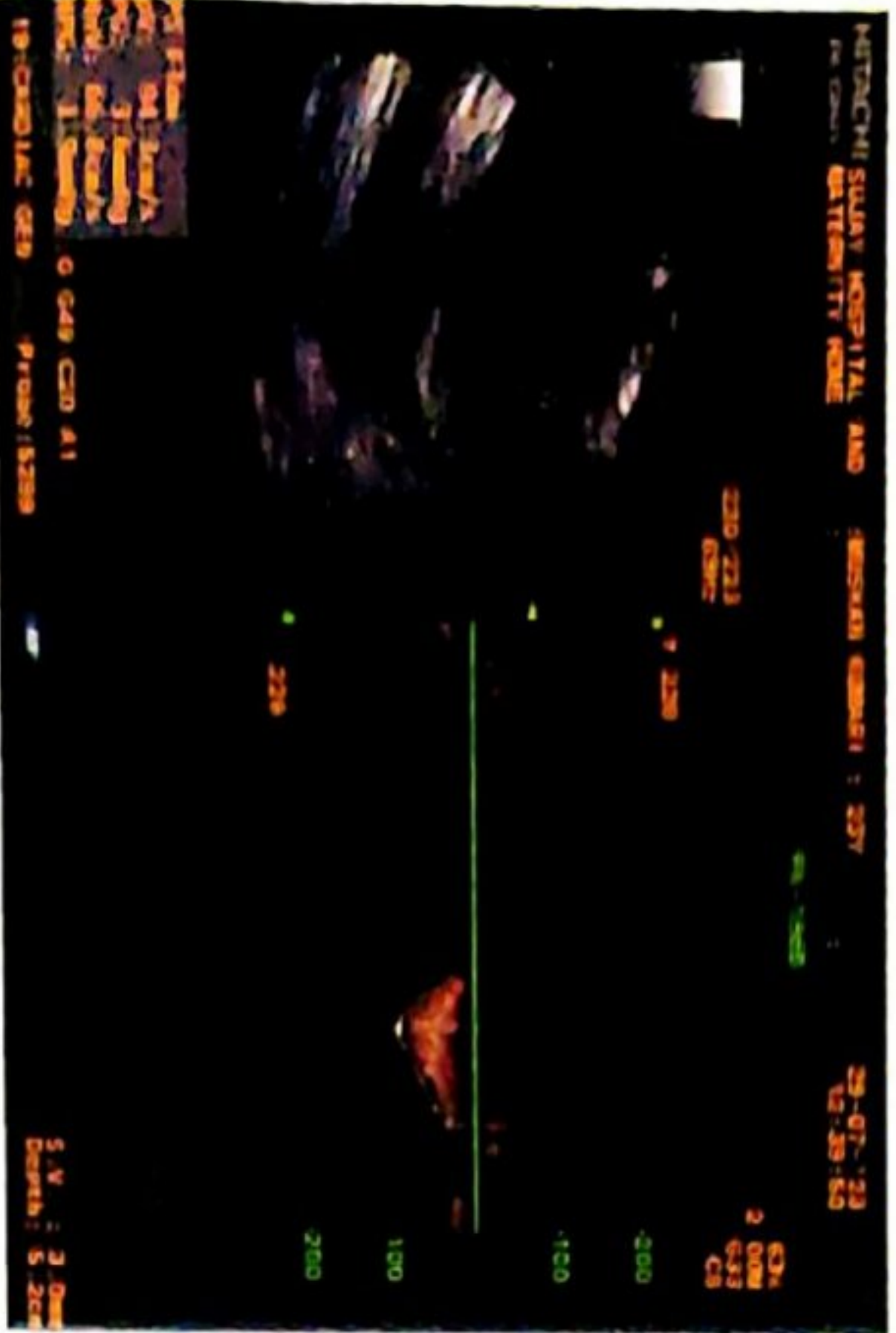
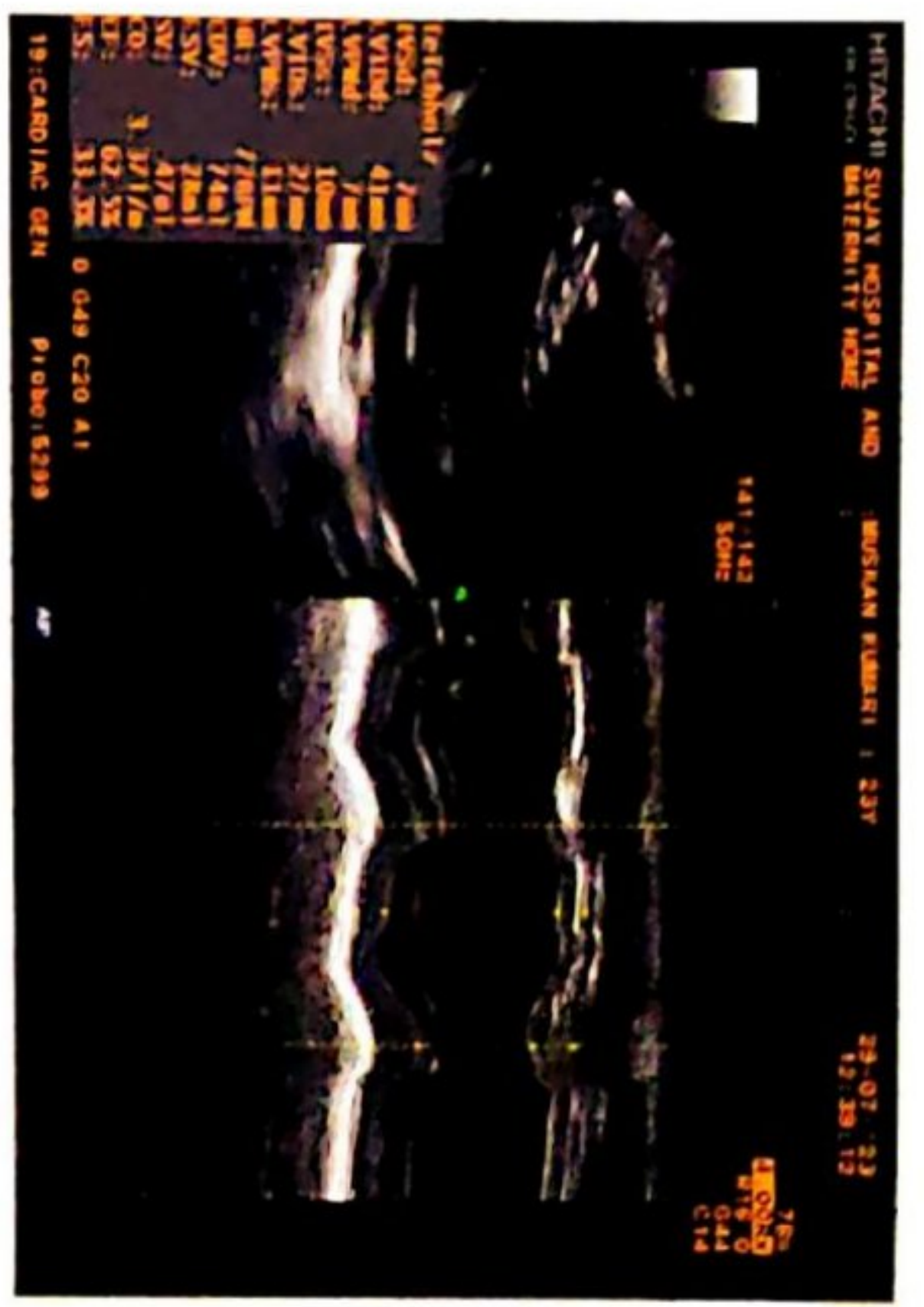
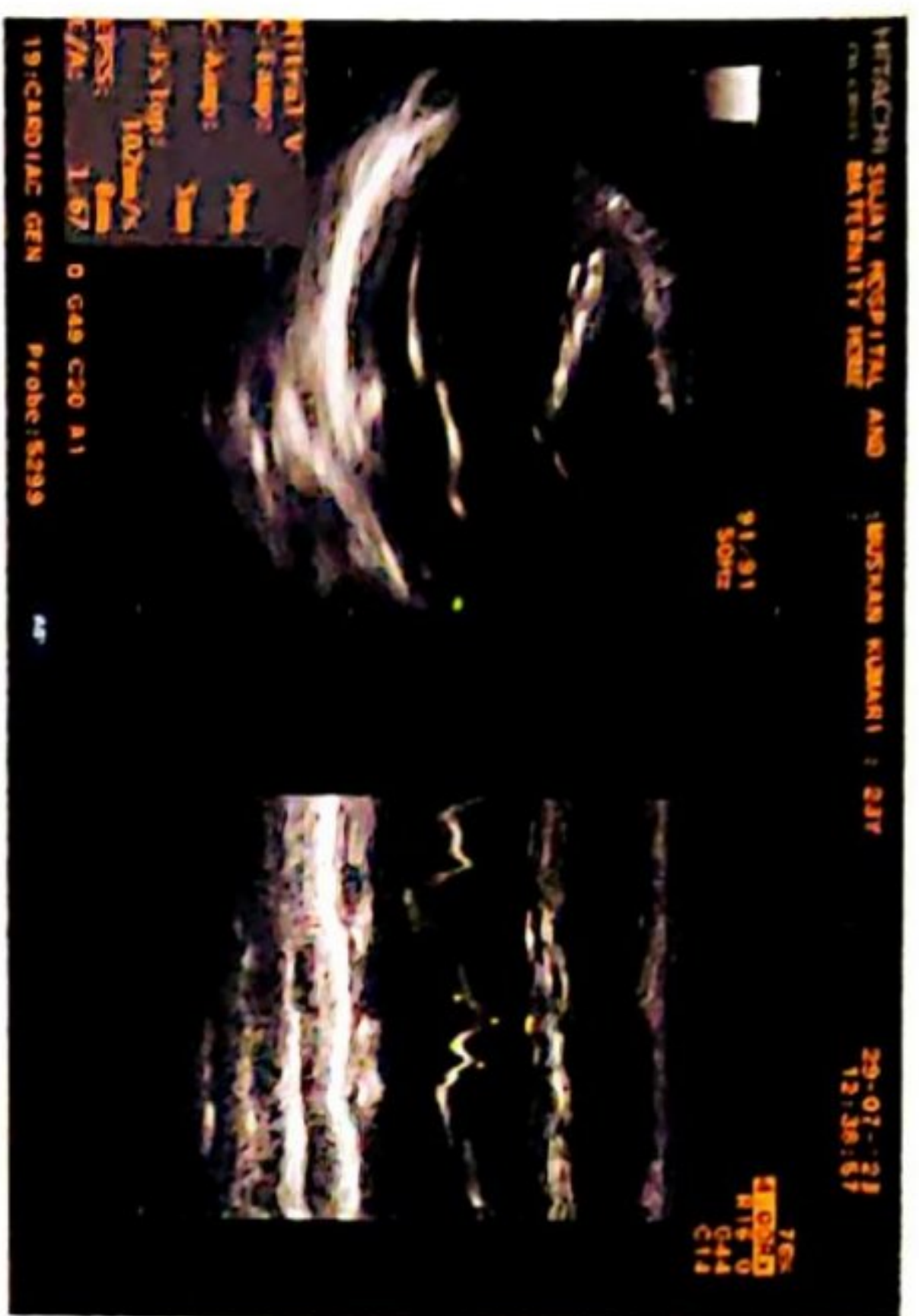
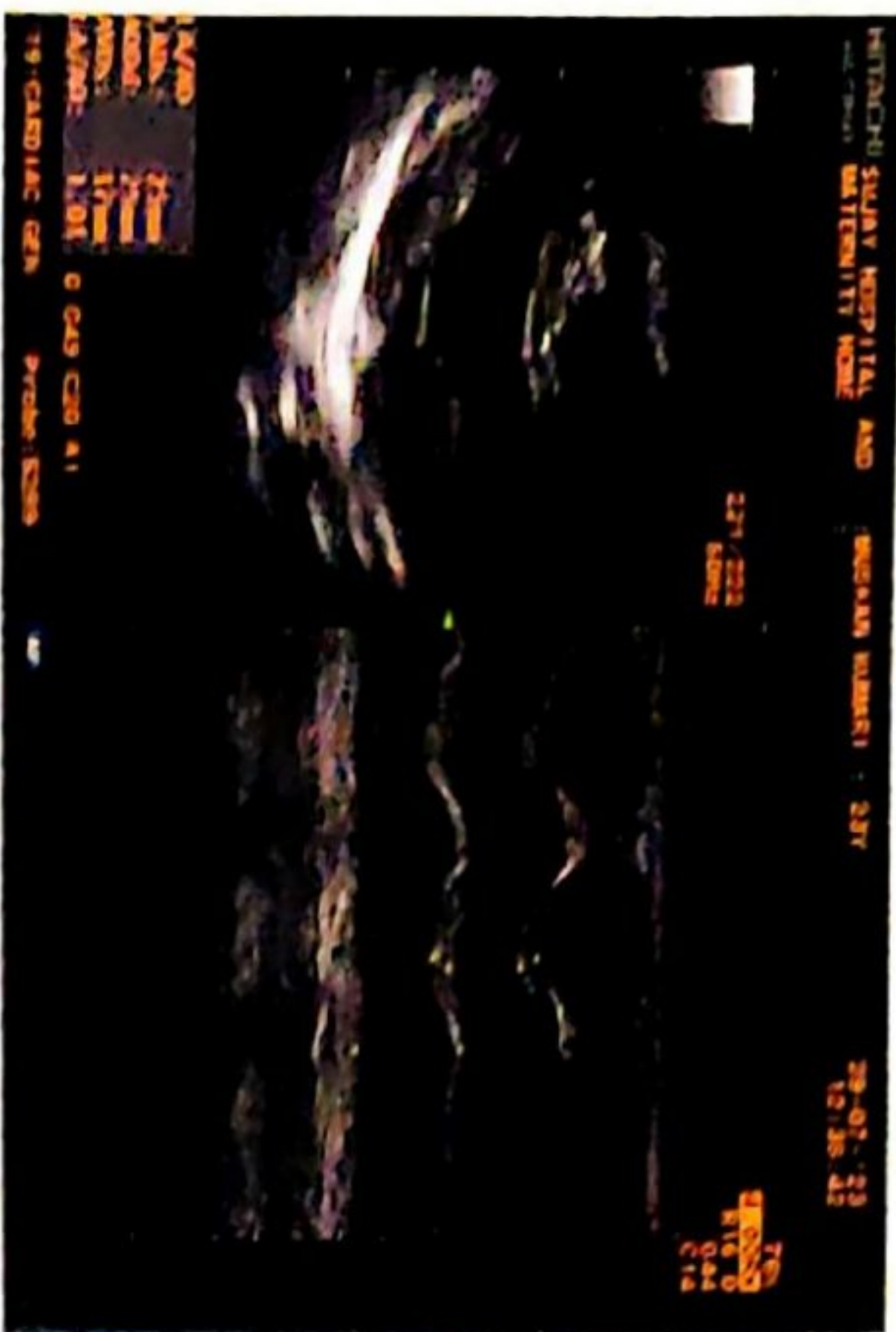
<Tricuspid Stenosis Flow Doppler>

Peak V	67.6cm/s	Mean V	47.4cm/s
P1/2T	24ms		
Peak PG	1.8mmHg	Mean PG	1.0mmHg

<Comments>

Physician's SIGNATURE :

[Signature]
Dr. Sunil Suryawanshi
 M.D. (Medicine)
 Reg.No.2223



डॉ. सुर्यवंशी

डॉ. सुनिल सुर्यवंशी

प्रसूतीशास्त्र तज्ञ
3712

एम.डी.(मेडीसीन) पुणे
कन्सल्टिंग फिजिशियन
रजि.नं. 2223

पता : मेन टेलिफोन एक्सचेंज समोर, पारिख
पार्क जवळ, नविन बरा स्टॅन्डच्या मागे,
जळगांव. फोन : (0257) 2227821

सुविधा : • एक्स-रे • सोनोग्राफी • इकोकार्डिओग्राफी • सुसज्ज ऑपरेशन थिएटर • कॉम्प्युटराईज्ड इ.सी.जी. • स्ट्रेस टेस्ट • पल्मोनरी फंक्शन टेस्ट

Rx

दि / / २०

X-RAY CHEST PA VIEW

NAME- MUSKAN KUMARI

AGE- 23 YRS / MALE DATE- 29.07.23

SOFT TISSUE AND SKELETON NORMAL.

NORMAL CARDIAC SIZE .

BOTH HILA ARTE NORMAL IN SIZE AND HAVE EQUAL DENSITY.

NORMAL BRONCHOVASCULAR MARKINGS .


COSTOPHRENIC AND CARDIOPHRENIC ANGLES ARE CLEAR.

THE DOMES OF DIAPHRAGMS ARE NORMAL IN POSITION AND SHOW SMOOTH OUTLINE.

THE PLURAL SPACES ARE NORMAL.

IMPRESSION –

NORMAL XRAY CHEST


Dr. Sunil Suryawanshi
M.D.(Medicine)
Reg.No.2223

परत येतांना कागद सोबत आणावा.



SAGAR IMAGING CENTRE

• Whole body sonography • Colour doppler • Digital X-ray

54-B, Onkar Nagar, Near Parikhpark, Jalgaon - 425001. Phone : 0257-2237634, e-mail : drchetanjj@rediffmail.com

DR. CHETAN S. KAKLIYA

M.B.B.S., D.M.R.D. (Sion Hospital, Mumbai University)

• Ex-Consultant Radiologist In Asian Heart Hospital (Mumbai)

• Ex - Radiologist Wockhardt Hospital (Mulund)

Name	: MUSKAN KUMARI	Date	: 29-07-2023
Ref By	: SUJAY HOSPITAL	Age/Sex	: - / Female

SONOGRAPHY OF ABDOMEN AND PELVIS

The liver is normal in size and show a well defined echogenic lesion measures 29 x 22 mm in right lobe (segment VIII). No evidence of calcification or significant vascularity. The portal vein appears normal.

The gall bladder is physiologically distended. No evidence of calculus, wall thickening or mass lesion.

The common bile duct is normal in caliber. No evidence of calculus is noted in common bile duct.

The pancreas is normal in size, shape and echotexture. No focal lesion is noted.

The spleen is normal in size and shape. No evidence of focal lesion is noted.

There is no evidence of enlarged coeliac, mesentric, portal pre or para aortic lymph nodes. No vascular mass lesion. No evidence of ascitis or pleural effusion.

Both kidneys are normal in size and echotexture. No evidence of calculus, hydronephrosis or cortical scarring.

Right kidney measures - 10.2 x 4.2 cms.

Left kidney measures - 9.8 x 4.4 cms.

The urinary bladder is well distended. No evidence of calculus, wall thickening or mass lesion.

Uterus is normal size and no focal lesion is noted.

The endometrium is well defined and appears normal.

Both adnexa are clear. Both ovaries are normal and show small follicles

No evidence of free fluid or mass in pouch of Douglas.

IMPRESSION:

No significant abnormality is noted.

Liver show a well defined echogenic lesion measures 29 x 22 mm in right lobe (segment VIII)....may be haemangioma / focal fat deposition etc.

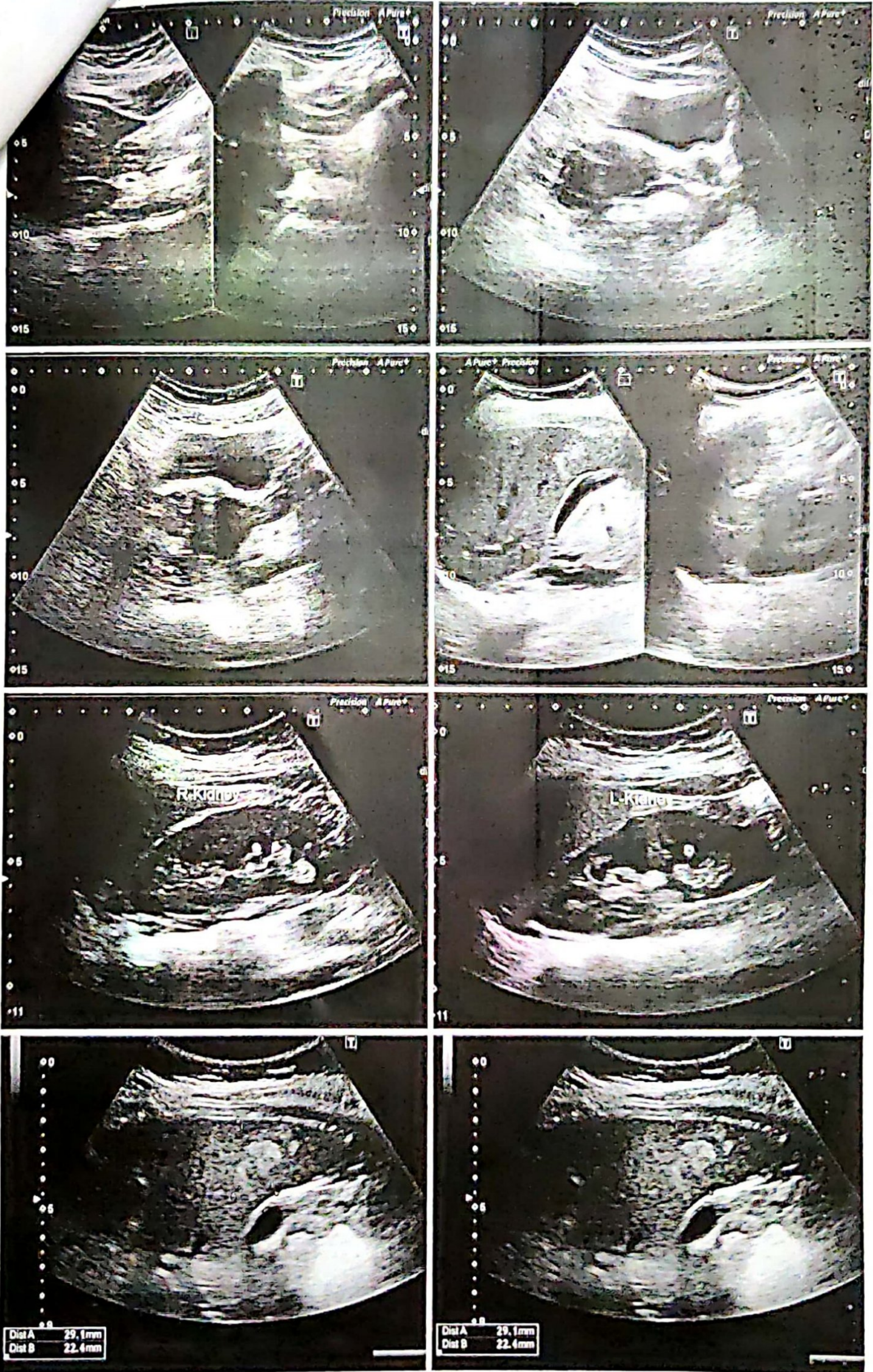
REPORT WITH THANKS.

Clinico pathological correlation is suggested.


DR.CHETAN KAKLIYA



Scanned with OKEN Scanner





सत्यमेव जयते

भारत सरकार

GOVERNMENT OF INDIA



मुस्कान कुमारी

Muskan Kumari


जन्म तिथि/DOB: 20/04/2000

महिला/ FEMALE



8130 9233 4266



 **GPS Map Camera**



Jalgaon, Maharashtra, India
2H48+HHJ, Onkar Nagar, Jaikisan Wadi, Jalgaon, Maharashtra
425001, India
Lat 21.006511°
Long 75.566658°
29/07/23 11:22 AM GMT +05:30