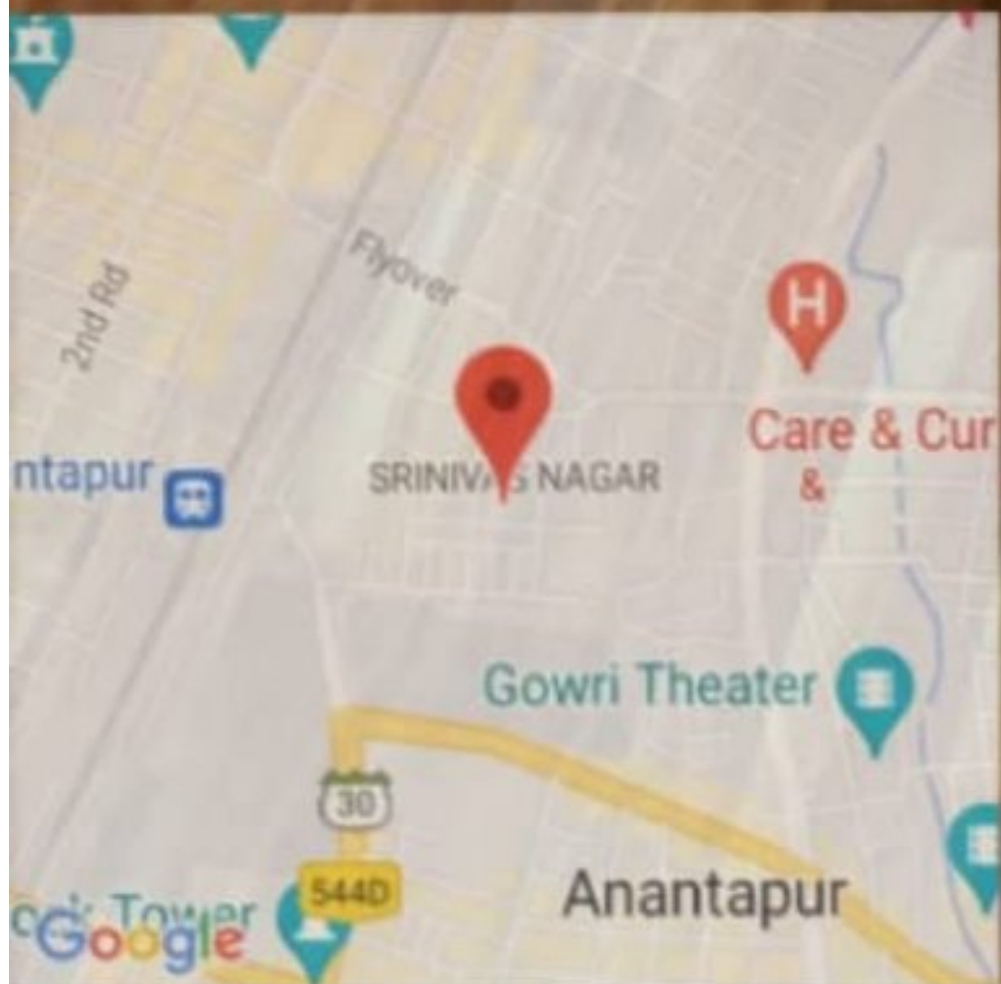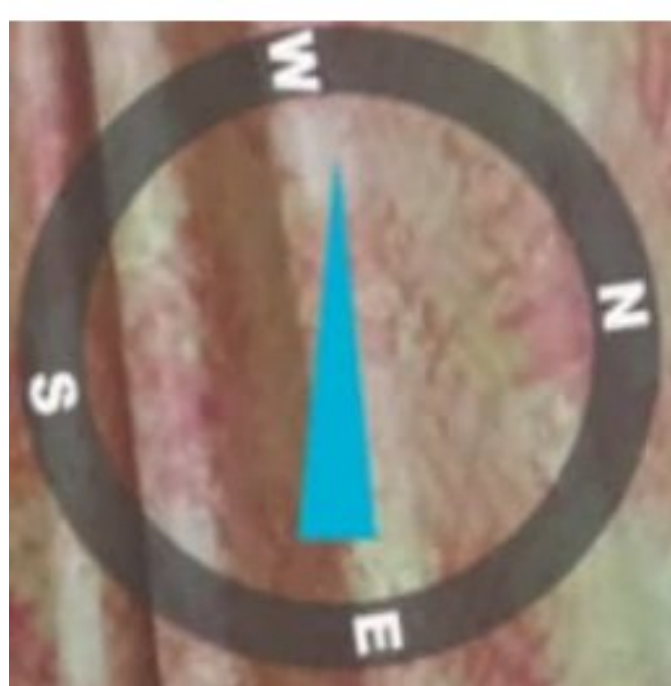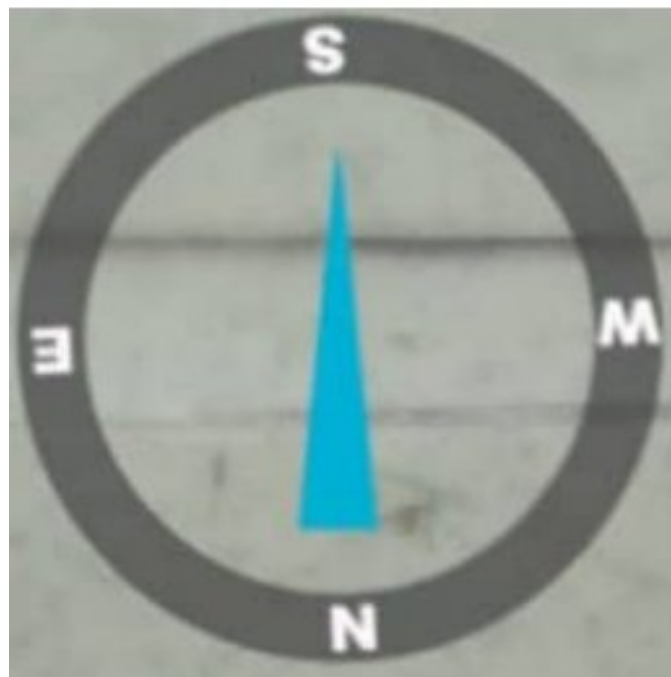


Feb 12, 2023 6:58:17 AM
278° W
Srinivas Nagar
Anantapur
Andhra Pradesh
Altitude:259.1m



भारत सरकार
Government of India



Issue Date: 20/10/2011




Vangala Nageswara Reddy

DOB: 06/06/1989

Male

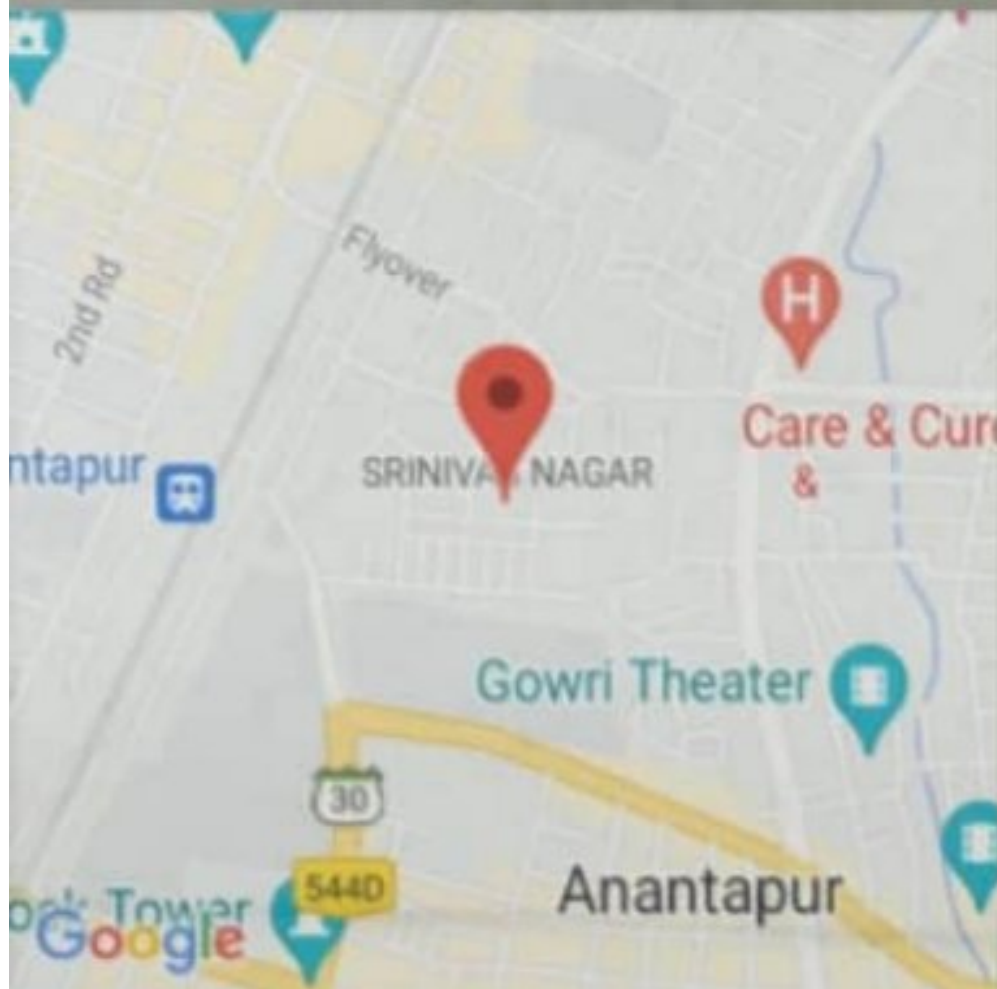


4840 1757 0436



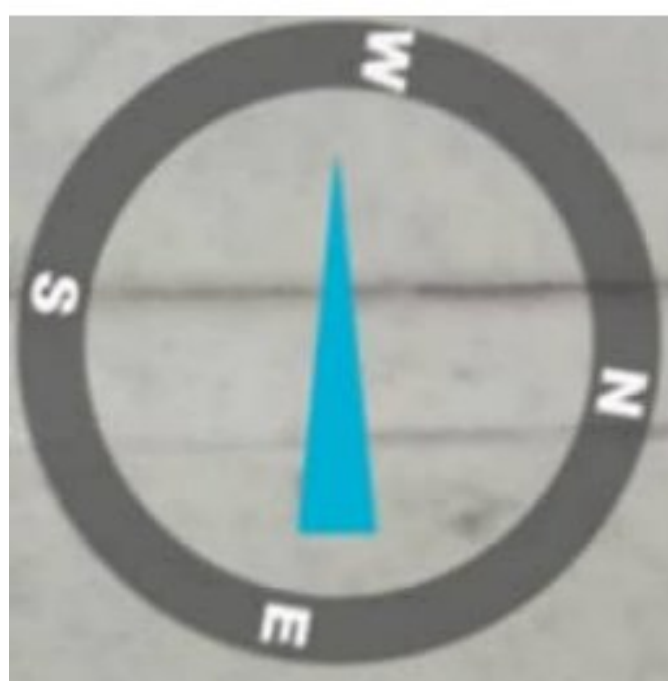
4840 1757 0436



मेरा आधार, मेरी पहचान



Feb 12, 2023 6:55:13 AM
178° S


Srinivas Nagar
Anantapur
Andhra Pradesh
Altitude: 259.1m






 भारतीय विशिष्ट पहचान प्राधिकरण
Unique Identification Authority of India 

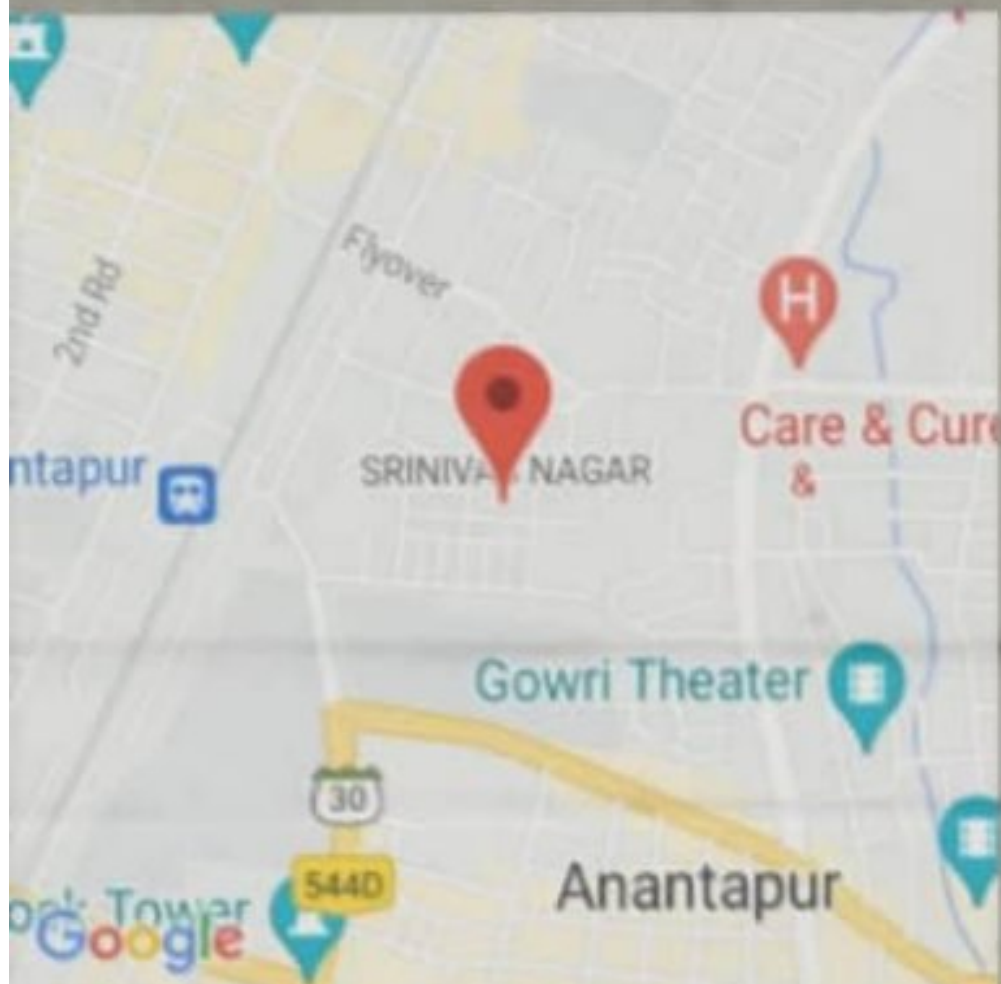
Print Date: 14/09/2021

Address: S/O V Ramana Reddy, 2/6,
donkavedhi main road, Peddamudium,
Cuddapah, Andhra Pradesh, 516434



4840 1757 0436

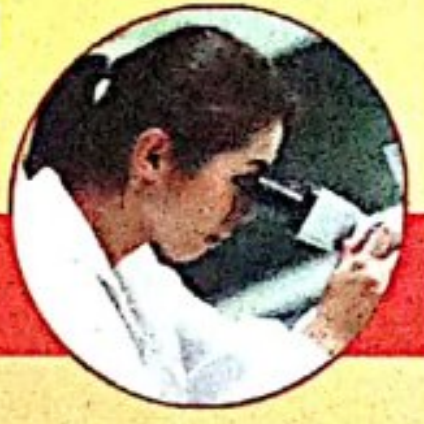 1947  help@uidai.gov.in  www.uidai.gov.in



Feb 12, 2023 6:55:44 AM
264° W
Srinivas Nagar
Anantapur
Andhra Pradesh
Altitude:259.1m



AMRUTHA SAI DIAGNOSTIC CENTRE



Cell : 868 898 4900, 9966 77 4621

email : amruthasailab@gmail.com

ISO.9001 : 2015 Certificate Number : Q91864141412

Name :- Mr V Nageswara Reddy

Age/Sex :- 33 y/male

Date :- 12-02-2023

Ref.by :- Mediwheel (BOB)

ID.No:- D1/2023, BOBE29100002, PKG-100000227, BC-59570

EMPLOYEE MEDICAL CHEK UP FORM

Physical Examination :-

Height :- 167 cms.

Weight :- 72 kgs.

Abdomen (CMS) :- 92 cms

Chest Expir(CMS):- 80

Chest Insp(CMS) : 85

Body mass index(BMI) :- 25.8

Pulse Rate :- 74 minute. (Regular / Abnormal)

Skin :- Normal

Open Lesions :- Nil

Oral Hygeine : Healthy

Complaints if Any :- Nil

Family History :- Nil

Complaints if Any :- Nil

Systemic Examination (Abnormality - if Yes Please Explain) :-

CVS - Yes / No

CNS - Yes/ No

Gi Tract - Yes/No

Abdomen - Yes/ No

Respiratory Tract - Yes/ No

Personal History :-

Smoking :- Yes/No

Alcohol sim :- Yes/No

Diabetes :- Yes/No

Allergy :- Yes/No

Since 10 years occasionally 9 and

BP :- 130/80 mm/hg

Nails :- Normal

INVESTIGATIONS : (N= Normal, R= See Report)

Complete Blood Picture With ESR = Normal

Complete Urine Examination = Normal

FBS, PLBS = Normal

Colour Vision = Normal

USG = Normal

Chest X-Ray = Normal

* ECG = Normal

* LFT = Normal

* LIPID = Normal

* Eye&ENT Examination = Normal

* 2D ECHO = Normal

* Stool R/E = Normal

Diagnosis (If Any) :- Nil

RECOMMENDATIONS / IMPRESION :- Nil

V. Nageswara
PHYSICIAN SIGNATURE
Dr. V. Nageswara
M.B.B.S,FCGP.
PHYSICIAN & SURGEON
Regd.No. 88543
Authorised Doctor,
For State Bank of India
ANANTAPUR.

Under AP Govt. Regd. Diagnostic Centre R.No.98/2012-2013

Genuineness is our gene



AMRUTHA SAI DIAGNOSTIC CENTRE



Cell : 868 898 4900, 9966 77 4621

email : amruthasailab@gmail.com

ISO.9001 : 2015 Certificate Number : Q91864141412

Patient Name : Mr V Nageswara Reddy

Sex : male

Age : 33 Yrs

Id.No : D1/23

Bill Date : 12-02-2023

Report Date : 12-02-2023

Ref. by : BOB Health Check Up

Address : A T P

LAB REPORT

Blood For :-

Parameter	Findings	Reference Range
Complete Haemogram (CBP) :-		
Haemoglobin % (C M G)	: 13.2 gm %	M : 12.0 - 17.0 gm %
Total WBC Count	: 8900 ce/cu mm	A : 4000 - 11000 ce/cu mm
Differential WBC Count	: Neutrophils - 65 % Lymphocytes - 30% Eosinophils - 04 % Monocytes - 01 %	45 - 65 % 25 - 45 % 01 - 06 % 02 - 08 %
E S R (Westergren Method)	: 21 mm/ 1 hr	M : 01 - 15 mm/1 hr
RBC Count	: 4.6 mill/cu mm	M : 4.5 - 6.5 mill/cu mm
Platelet Count	: 2.3 Lach/cu mm	1.5 - 4.0 Lach/cu mm
Packed Cell Volume (PCV)	: 42.3 %	M : 40 - 54 %
Mean Corpuscular Volume (MCV)	: 89.2 fl	82 - 92 fl
Mean Corpuscular Haemoglobin (MCH)	: 29.4 pg	27 - 32 pg
Mean Corpuscular Haemoglobin Concentration (MCHC)	: 32.9 %	32 - 36 %
Blood Group & Rh Type	:- "A" Positive(+Ve)	

TEST NAME	METHOD	VALUE	UNITS
GLYCOSYLATED HAEMOGLOBIN (Hb A1 c) %	TURBIDOMETRY	5.42	%

Reference Range :-

BELOW 6.0 %	- NORMAL VALUE
6.0 % - 7.0 %	- GOOD CONTROL
7.0 % - 8.0 %	- FAIR CONTROL
8.0 % - 10.0 %	- UNSATISFACTORY CONTROL
ABOVE 10.0 %	- POOR CONTROL

@ Suggested clinical Correlation, If there is need, kindly discuss.

S. Vijaya Lakshmi
LAB INCHARGE
S. Vijaya Lakshmi
M.Sc (Biochemistry)

Under AP Govt. Regd. Diagnostic Centre R.No.98/2012-2013

Genuineness is our gene

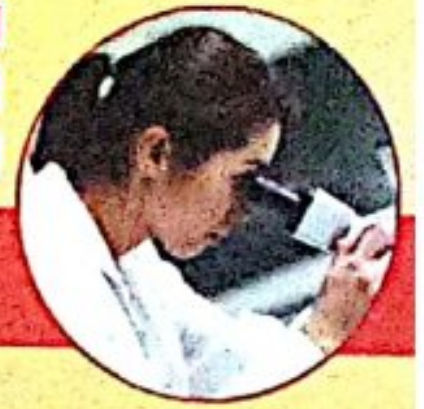

AMRUTHA SAI DIAGNOSTIC CENTRE

Cell : 868 898 4900, 9966 77 4621

email : amruthasailab@gmail.com

ISO.9001 : 2015 Certificate Number : Q91864141412



Patient Name : Mr V Nageswara Reddy

Sex : male

Age : 33 Yrs

Id.No : D1/23

Bill Date : 12-02-2023

Report Date : 12-02-2023

Ref. by : BOB Health Check Up

Address : A T P

LAB REPORT

Blood For :-

Parameter	Findings	Reference Range
LIPID PROFILE :-		
Cholesterol Total	: 201 mg/dl	150 - 260 mg/dl
H D L Cholesterol	: 43 mg/dl	M : 35 - 55 mg/dl
L D L Cholesterol	: 112 mg/dl	66 - 178 mg/dl
V L D L Cholesterol	: 36 mg/dl	5 - 40 mg/dl
Triglycerides	: 192 mg/dl	36 - 165 mg/dl
CHOL : HDL Chole	: 4.2 : 1	3.0 - 5.0 : 1
Fasting Blood Sugar	: 91 mg/dl	65 - 110 mg/dl
Post Prandial Blood Sugar	: 132 mg/dl	80 - 160 mg/dl
Renal Function Test (RFT) :-		
B U N	: 13 mg/dl	7 - 18 mg/dl
Serum Creatinine	: 1.1 mg/dl	0.7 - 1.4 mg/dl
Serum Uric Acid	: 4.2 mg/dl	3.0 - 5.7 mg/dl
Serum Calcium	: 9.6 mg/dl	8.7 - 10.4 mg/d
LIVER FUNCTION TEST (LFT) :-		
Bilirubin Total	: 0.7 mg/dl	0.1 - 1.0 mg/dl
Bilirubin Direct	: 0.15 mg/dl	0.0 - 0.25 mg/dl
Bilirubin Indirect	: 0.5 mg/dl	0.2 - 0.8 mg/dl
Total Proteins	: 6.5 gm/dl	6.0 - 8.0 gm/dl
Albumin	: 3.9 gm/dl	3.7 - 5.3 gm/dl
Globulins	: 2.6 gm/dl	2.5 - 4.5 gm/dl
S G O T (A S T)	: 36 IU/L	Upto - 40 IU/L
S G P T (A L T)	: 42 IU/L	Upto - 47 IU/L
Alkaline Phosphatase (ALP)	: 172 IU/L	A : 100 - 290 IU/L
Gamma Glutamyl Transferase (GGT)	: 32 IU/L	M : Upto - 50 IU/L

@ Suggested clinical Correlation, If there is need, kindly discuss.

S. Vijaya Lakshmi
S. Vijaya Lakshmi

Under AP Govt. Regd. Diagnostic Centre R.No.98/2012-2013

Genuineness is our gene



AMRUTHA SAI DIAGNOSTIC CENTRE



Cell : 868 898 4900, 9966 77 4621

email : amruthasailab@gmail.com

ISO.9001 : 2015 Certificate Number : Q91864141412

Patient Name : Mr V Nageswara Reddy

Sex : male

Age : 33 Yrs

Id.No : D1/23

Bill Date : 12-02-2023

Report Date : 12-02-2023

Ref. by : BOB Health Check Up

Address : A T P

LAB REPORT

Complete Urine Analysis(C U A) :-

Physical Examination :-

Colour : Pale Yellow
Reaction : Acidic
Sp.Gravity : 1.010

Transparency : Clear
Sediment : NIL
pH : 6.5

Chemical Examination :-

Sugar : Absent
Bile Salts : Absent
Urobilinogen : Normal
Blood : Absent

Proteins : Traces
Bile Pigments : Absent
Ketone Bodies : Negative

Microscopic Examination :-

Pus Cells : 6 - 8 /hpf
RBC's : Absent
Crystals : Absent
Bacteria : Absent

E.P.Cells : 3 - 4 /HPF
Casts : Absent
Deposits : Absent

STOOL COMPLETE EXAMINATION

Colour : Yellow
Consistency : Solid
Mucus : Absent

MICROSCOPY:

Trophozoites : Absent
Ova / EGGs : Absent
Pus Cells : 1 - 2 / hpf
Fat Globuls : Present (++)
Parasites : Absent

Macriophages : Absent
Cysts : Absent
RBC : Absent
Veg.Cells/Fibres : Present (+)
Others : Small Bacilli Seen /hpf

@ Suggested clinical Correlation, If there is need, kindly discuss.

S. Vijaya Lakshmi
LAB INCHARGE
S. Vijaya Lakshmi
M.Sc (Biochemistry)

Note:- Amrutha Sai Diagnostic Centre . (Fully Automated A/C Laboratory)

***** Since - 25 Years *****

Opp.Balaji Kalyana Mantapam, Near RTC Bus Stand, Reliance Mart Road,
Srenivasa Nagar, ANANTHAPURAM. CELL - 86 88 984900.

Under AP Govt. Regd. Diagnostic Centre R.No.98/2012-2013

Genuineness is our gene

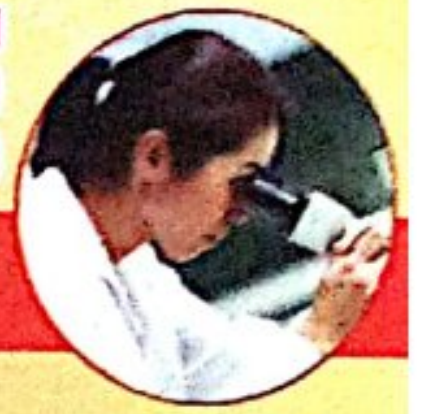

AMRUTHA SAI DIAGNOSTIC CENTRE

Cell : 868 898 4900, 9966 77 4621

email : amruthasailab@gmail.com

ISO.9001 : 2015 Certificate Number : Q91864141412



Patient Name : Mr V Nageswara Reddy

Sex : male

Age : 33 Yrs

Id.No : D1/23

Bill Date : 12-02-2023

Report Date : 12-02-2023

Ref. by : BOB Health Check Up

Address : A T P

XRAY-CHEST (PA) VIEW

- Trachea is central
- Both th lung fields appear normal.
- Hilar shadows are with in normal limits.
- Pulmonary vasculatures are normal.
- Cardia is normal in size.
- Both domes of the diaphragm are smooth.
- Both costophrenic recesses are clear.
- Visualized bones and soft tissue shows appear normal.

IMPRESSION :- NORMAL X-RAY.

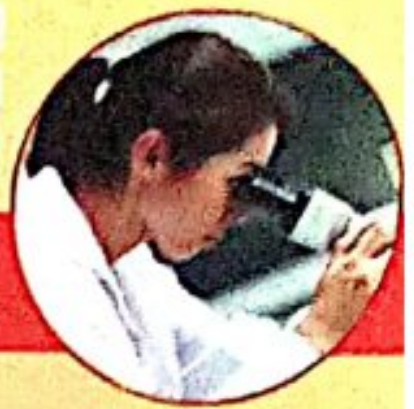K. Rani
Dr. K. RADHA RANI, MD
Specialist in Ultr- Sound
Radio Diagnosis & C.T. Scan
Asst. Civil Surgeon
Medical College &
General Hospital
ANANTAPUR

Under AP Govt. Regd. Diagnostic Centre R.No.98/2012-2013

Genuineness is our gene



AMRUTHA SAI DIAGNOSTIC CENTRE



Cell : 868 898 4900, 9966 77 4621

email : amruthasailab@gmail.com

ISO.9001 : 2015 Certificate Number : Q91864141412

Name	: Mr. V Nageswara Rao	COMP0125	:
Age/Gender	: 33 Yrs / M	Vial ID	: 240124
Ref. Dr.	: Self	Collected On	: 12-Feb-2023 07:00 AM
Req No.	: SMN2311676	Registered On	: 13-Feb-2023 07:00 AM
Sample Type	: Serum	Reported On	: 01-Feb-2023 12:00 PM
Client Name	: AMRUTHA SAI DIAGNOSTICS-CMLAPF10	Client Code	: CMLAPF10

IMMUNOASSAY THYROID PANEL-II

Test Name	Observed Values	Units	Biological Reference Intervals
* TOTAL TRIIODOTHYRONINE (T3) Method:ECLIA	1.05	ng/mL	0.82 - 2.0
* TOTAL THYROXINE (T4) Method:ECLI	9.54	ug/dl	5.1 - 14.1
* THYROID STIMULATING HORMONE (TSH) Method:ECLIA	2.91	μIU/mL	Adult : 0.35 – 5.5 pediatric range: Birth – 4 days:1.0-39 2- 20 Weeks: 1.7- 9.1 20 weeks- 20 yrs:0.7-6.4

INTERPRETATION::

The determination of T3 is utilized in the diagnosis of T3hyperthyroidism,the detection of early stages of hyperthyroidism and for indicating a diagnosis of thyrotoxicosis factitia

The determination of T4 can be utilized for the following indications: the detection of hyperthyroidism, the detection of primary and secondary hypothyroidism, and the monitoring of TSH-suppression therapy.

The determination of TSH serves as the initial test in thyroid diagnostics.Even very slight changes in the concentrations of the free thyroid hormones bring about much greater opposite changes in the TSH level. Accordingly,TSH is a very sensitive and specific parameter for assessing thyroid function and is particularly suitable for early detection or exclusion of disorders in the central regulating circuit between the hypothalamus, pituitary and thyroid.

U Mehatha.M.Sc
BIOCHEMIST

Dr.Tamkinath Fatima,MD
CONSULTANT BIOCHEMIST

Please Corelate With Clinical Findings If Necessary Discuss. This is an Electronically Authenticated Report

Page 1 of 1



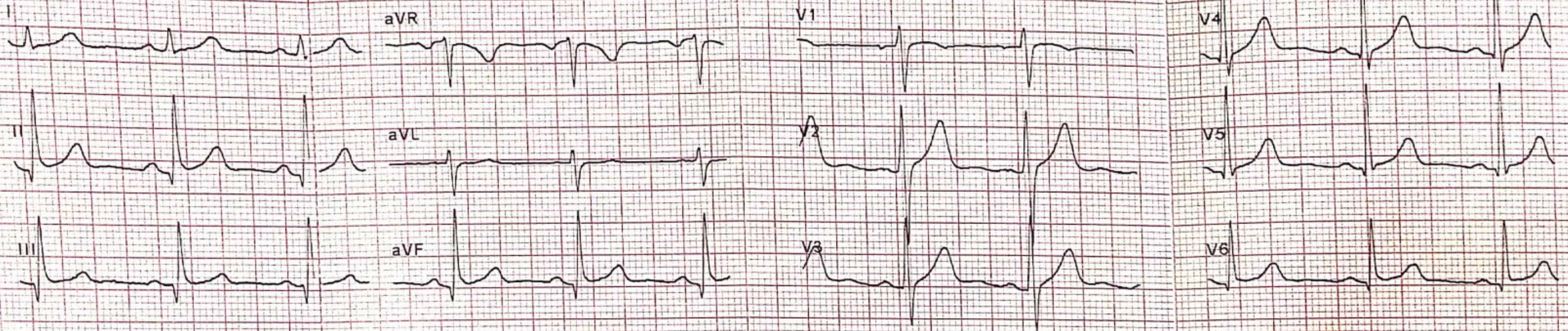
Under AP Govt. Regd. Diagnostic Centre R.No.98/2012-2013

Genuineness is our gene

Scanned with CamScanner

HR 73 /bpm

12.02.2023 06:55:42



25 mm/s, 10 mm/mV

LP 25 Hz, AC 50 Hz

Sequential

AT-1 G2 (1070.006301). 1.2.1

SCHILLER Part No.2.157044M © 0123

SCHILLER Part No.2.157044M © 0123 S.BB

SCHILLER Part No.2.157044M © 0123

SCHILLER Part No.2.157044M © 0123 S.BB

12.02.2023 06:55:42

Otherwise normal ECG

Sinus rhythm
Normal electrical axis
Nonspecific ST abnormality (elevation)

Unconfirmed report

Mr. V. Nagarajendra Reddy

38/Hele

Date 12/01/23

Mr. of SSOA

HR 73/bpm

RR 827 ms
P 118 ms
PR 160 ms
QRS 100 ms
QT 388 ms
QTc 427 ms (Bazett)
Sokolow 2.91 mV
Cornell 0.96 mV
Lewis -0.88 mV
Romhilt 1

P axis 51°
QRS axis 72°
T axis 51°

[Signature]
Dr. V. Narayanappa,

M.B.B.S, FCGP,
PHYSICIAN & SURGEON
Regd. No. 88543
Authorised Doctor,
For State Bank of India,
ANANTAPUR.

12.02.2023 06:55:42

Name

Patient ID

Date of Birth

Gender

Pacemaker

Height cm

Weight kg

BP mmHg

Medication

Remark

AT-1 G2 (1070.006301). 1.2.1

SCHILLER Part No.2.157044M CE 0123

SCHILLER Part No.2.157044M CE 0123 S.BB

SCHILLER Part No.2.157044M CE 0123

SCHILLER Part No.2.157044M CE 0123 S.BB



2D ECHOCARDIOGRAM- COLOUR DOPPLER STUDY

NAME:-MR.V.NAGESWARA REDDY	AGE/GENDER:33Y/MALE	DATE:12/02/2023
REFERED BY:-	MRNO:-	OP/IP NO:-
ECHO DONE BY:- DR.R.KATYAYINI	S.NO:-	TAPE NO:-

MITRAL VALVE :- NORMAL
 AORTIC VALVE :- NORMAL
 TRICUSPID VALVE :- NORMAL
 PULMONARY VALVE :- NORMAL
 RIGHT ATRIUM :- NORMAL
 RIGHT VENTRICLE :- NORMAL
 LEFT ATRIUM :-3.5cm
 LEFT VENTRICLE :-NO RWMA

*EDD :- 4.5 cm IVSD :- 1.1 cm EF:- 62 %
 *ESD :- 3.0 cm PWD :- 1.1 cm FS:- 33 %
 *EDV :- MI ESV :- MI EF:- %

IAS :- INTACT
 IVS :- INTACT
 AORTA :-2.8cm
 PULMONARY ARTERY :- NORMAL
 PERICARDIUM :-NORMAL
 INTRACARDIAC MASSES :-NO
 IVS/SVC/CS :- NORMAL
 PULMONARY VEINS :- NORMAL
 OTHERS :- NORMAL

COLOUR FLOW MAPPING & DOPPLER

MR:-1+ AR:-NO TR:- 1+ PR:- NO

DOPPLER
 MITRAL :- E= 0.5m/sec A= 0.8m/sec EDT= 211 ms
 TDI :- E/E'- A':-
 AORTA :- VMAX = 1.1 m/sec
 PULMONARY :- VMAX = 1.0 m/sec
 TRICUSPID :- RVSP 20 mmHg
 OTHERS :-

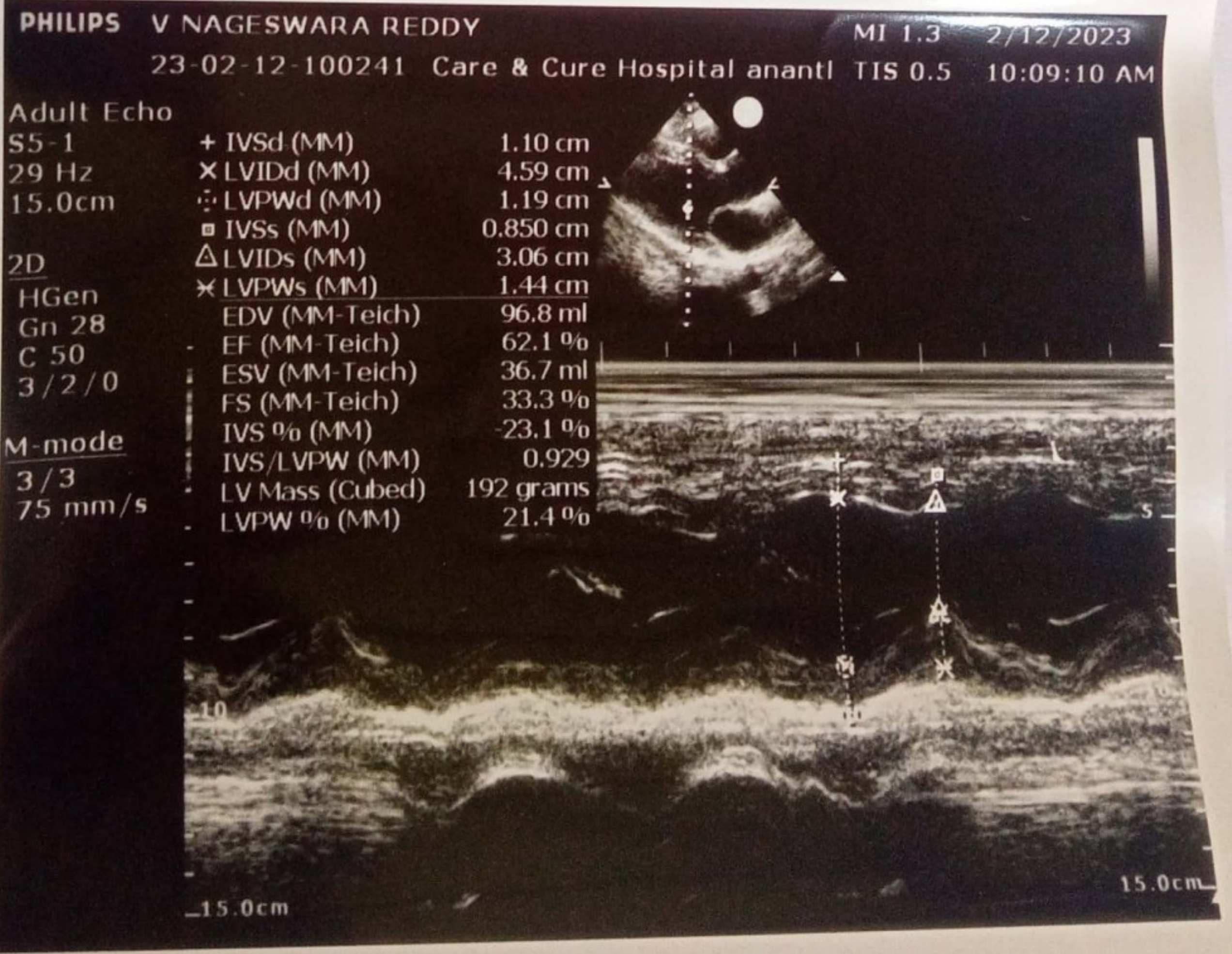
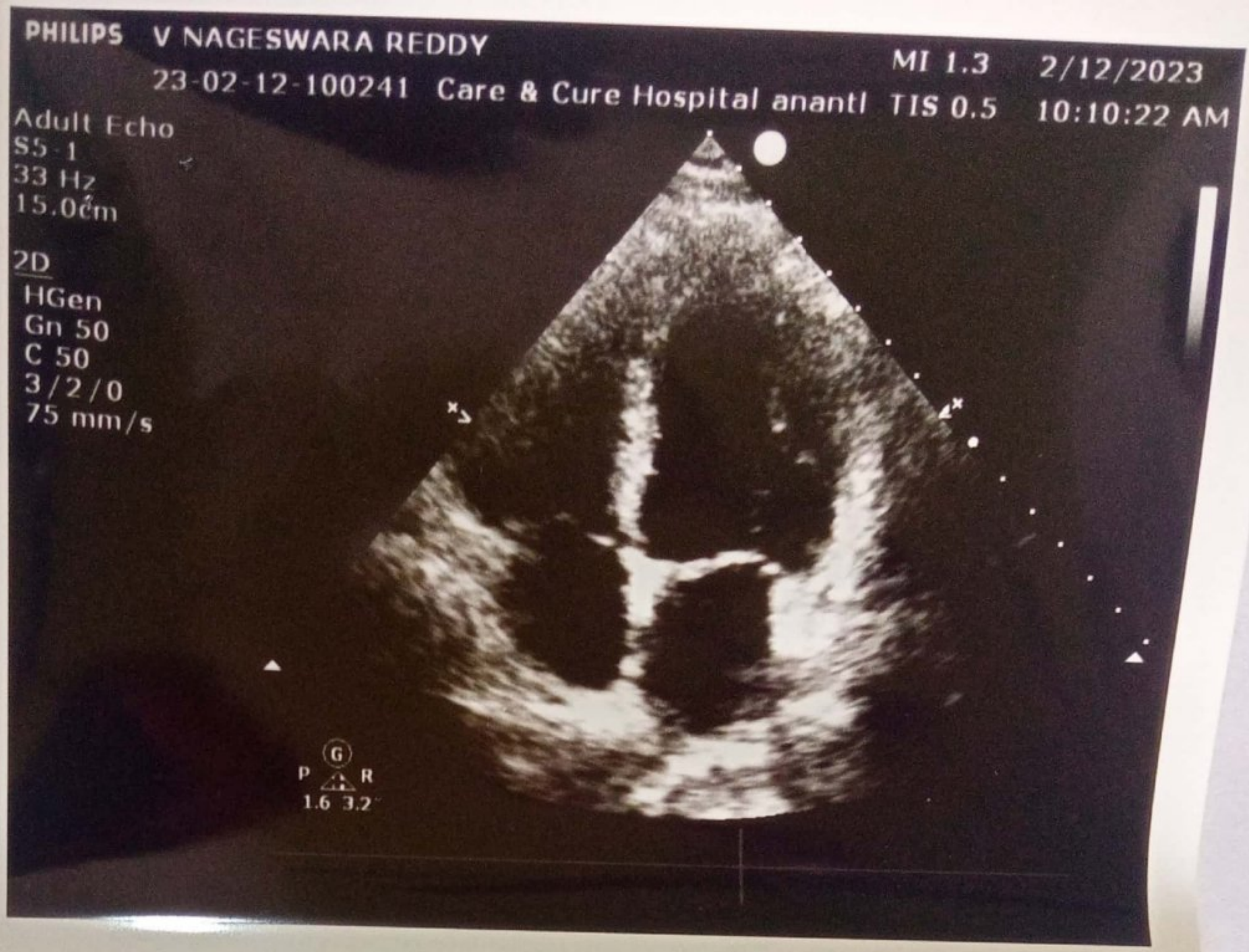ECHO DIAGNOSIS

- 1 NORMAL SIZED CARDIAC CHAMBERS
- 2 NO LV RWMA
- 3 TRVIAL MR/TR
- 4 NORMAL LV/RV FUNCTION (EF:-62%)
- 5 NO PERICARDIAL EFFUSION
- 6 NO CLOT & NO VEGITATION,NO PAH

Katyayini
 Dr. KATYAYINI, MD.DNB
 Consultant Interventional Cardiologist
Dr. R. KATYAYINI
 MBBS., MD(Gen Med), DrNB(Cardiology)
 Consultant Interventional Cardiologist
 APMC Reg.No:77567
 CONSULTANT CARDIOLOGIST

#13-2-392-4, Care & Cure Circle, NTR Marg, Near RTC Bus-Stand, Ananthapuramu - 515001.

Ph:08554 - 220555, 278999 Cell: 74166 84286, e-mail: careandcureatp@gmail.com website:www.careandcurehospitals.com



1st Cross, Sai Nagar,
Near Surya Nagar Bus Stop,
ANANTAPURAMU - 515001.
Contact : +91 79893 30974



VASUNDHARA
DIAGNOSTICS
FETAL MEDICINE CENTRE

Patient Name : Mr. V.Nageswar Reddy

Patient Id : 230212-016 Gender/Age : Male / 33 Year

Referred By : Amrutha Sai diagnostic center

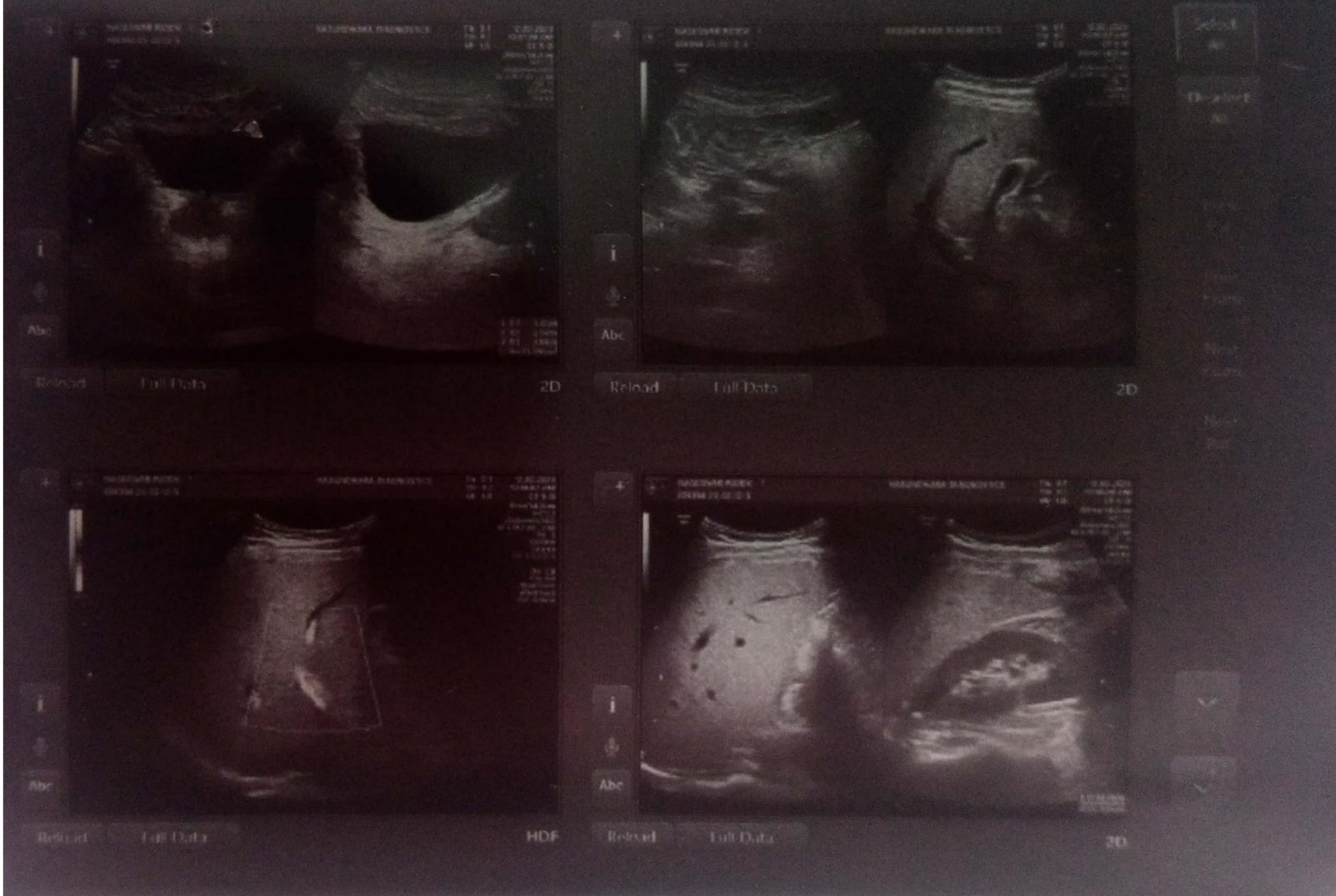
Reg Date : 12-02-2023

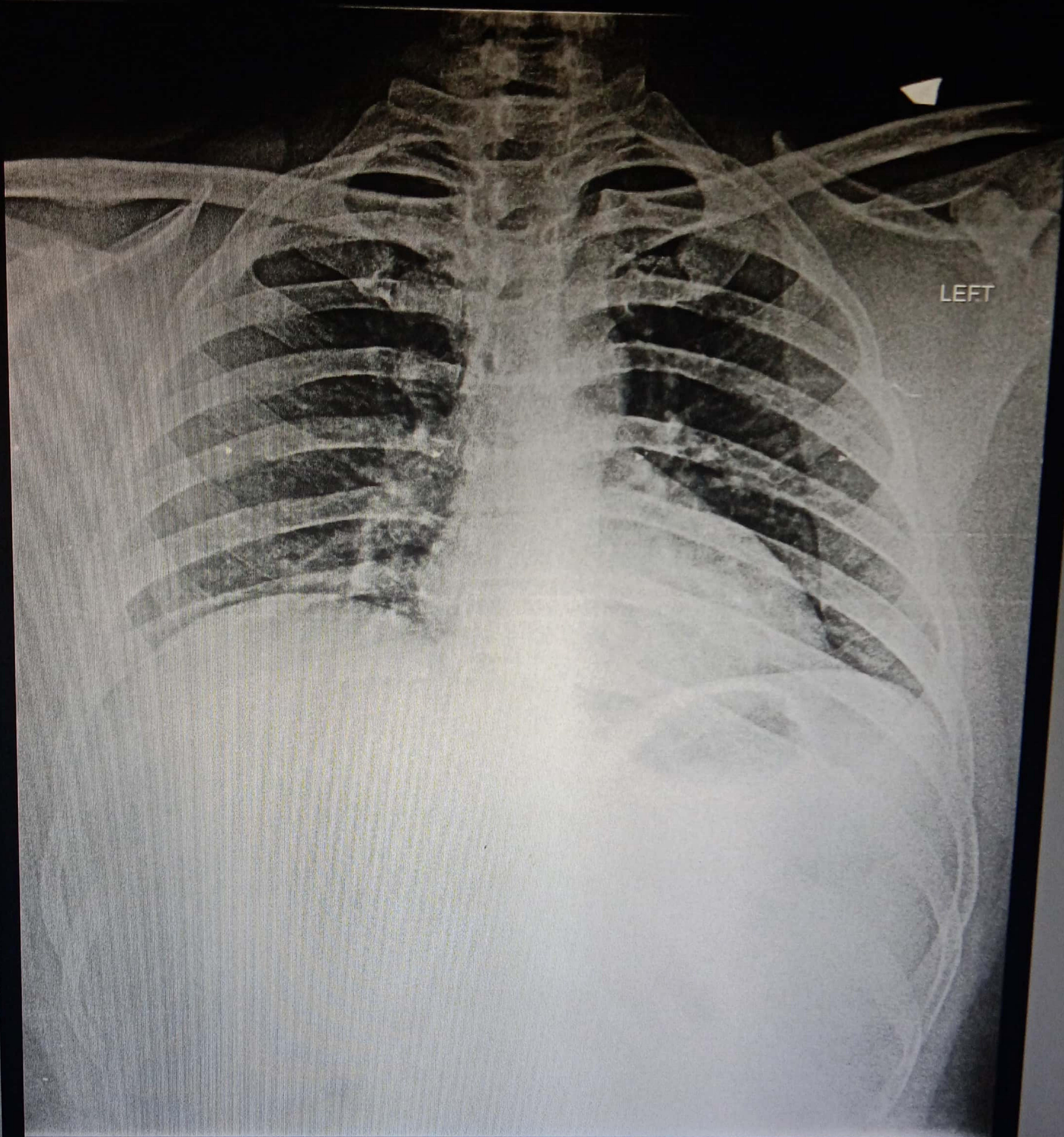
ULTRASONOGRAPHY OF WHOLE ABDOMEN

- Liver** : Normal in size(13.3) with **Increased** echotexture.
No focal lesions or dilated biliary radicles.
No IHBD / CBD dilatation. Portal vein is normal.
- Gall bladder** : Contracted . No calculi . No wall thickening.
- CBD** : Normal in course and calibre .Lumen echo free.
- Portal vein** : Normal in size and course. Lumen echo free .
- Spleen** : Normal in size(9.3cm) with normal echotexture. No focal lesions.
- Pancreas** : Head, body, visualized parts of tail are normal. No focal lesions
or peripancreatic collections are seen.
- Kidneys** : Right kidney: 9 x 4.1 cm Left kidney: 9.8 x 4.4 cm.
Normal in size, shape and echotexture.Corticomedullary junction made out.
Renal cortical thickness measuring 16 mm on right side and 18.3 mm on left side
No calculi or hydronephrosis on both sides.
- Urinary bladder** : Well distended. No calculi are seen.No wall thickening seen.
- Prostate** : Normal in size and echotexture.Volume measuring 13cc
- Others** : No evidence of ascites. Appendix not seen due to bowel gas.
No evidence of lymph node enlargement. No obvious inflammed bowel seen
- Impression** : **Grade I fatty liver**

Dr.N.Vasundhara
MD Radiology
Consultant in fetal medicine

For clinical correlation please...





V NAGESWARA RAO 33Y 02 CHEST PA 12/02/2023 12:36 PM MED WHEEL HEALTH
AMRUTHA SAI DIAGNOSTIC CENTRER, OPP. BALAJI KALYANAMANDAPAM, SRINIVASA NAGAR, ANANTAPUR, 8688984900