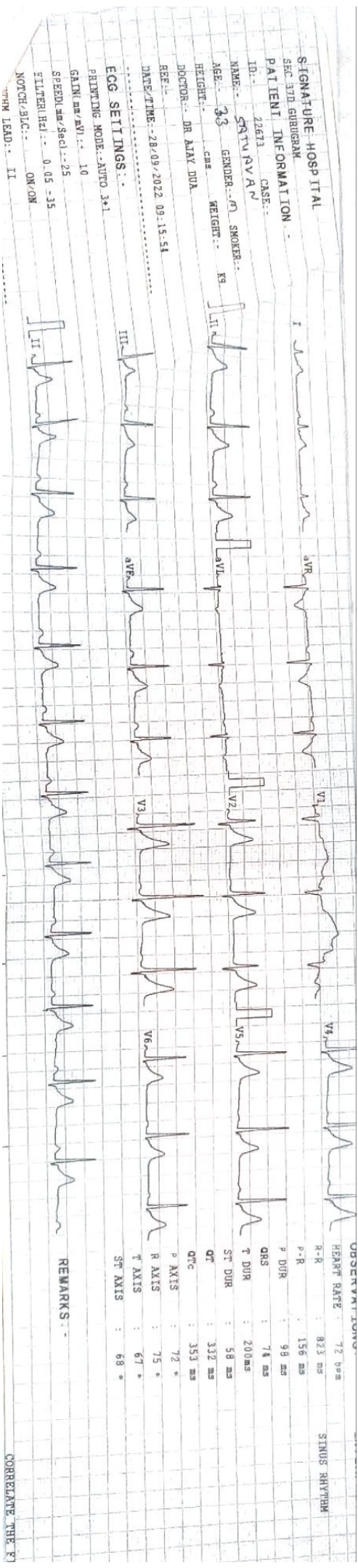

SIGNATURE: HOSPITAL  
 SEC 3RD GIBBERAM

PATIENT INFORMATION

ID: 22673 CASE: 59749VAM

NAME: 33 GENDER: M SMOKER: K3

AGE: 33 CM WEIGHT: K3

HEIGHT: DR ALY DIA

DATE/TIME: 28/09/2022 09:15:54

ECG SETTINGS: PRINTING MODE: AUTO 3\*1

GAIN: mV: 10

SPEED: mm/sec: 25

FILTER: Hz: 0.05 - 35

NOTCH/BLC: ON/OFF

FORM LEAD: II

OBSERVATIONS

HEART RATE: 72 bpm

R-R: 823 ms

P-R: 156 ms

P-DUR: 98 ms

QRS: 74 ms

T-DUR: 200ms

ST-DUR: 58 ms

QT: 332 ms

QTc: 353 ms

P-AXIS: 72°

R-AXIS: 75°

T-AXIS: 67°

ST-AXIS: 68°

STND RHYTHM

REMARKS:

CORRELATE THE F

Satyavan 83yr/M  
routine eye check-up  
Nhsystemic illness

O/E in b/l, N3 Colour Vn - N3D

Antecy - R/L Ltz congestion +  
papillae +

Ant (N)

Ad

(1) old PTDLO → x R/E  
x 3 weeks

(2) old 0.5% cme (Refresh Tears  
As tear)

- PPU 505 → R/E

Wf  
28/9/22  
Consultant  
Department of Ophthalmology  
SIGNATURE HOSPITAL



(This is only professional opinion and not the diagnosis. Please correlate clinically)

Sector 37-D, BTP, Dwarka Express Way, Gurugram, Hry.,

Ph.: 0124-6034444, 8526000000, E-mail : signaturehospital@gmail.com, Web.: www.thesignaturehealthcare.com

PARK GROUP OF HOSPITAL : ★ West Delhi ★ South Delhi ★ Gurugram ★ Faridabad ★ Panipat ★ Karnal

Patient Name : Mr. SATYAVAN	UHID : 15003
Age / Gender : 33 Years 9 Months 26Days / Male	IPNO :
Referred By : Dr. CMO	Registered : 28/09/2022/ 9.09 AM
Req.No : 22227782	Sample Collection Dt & Tm : 28/09/2022/ 10.46 AM
Sample ID : 2237322	Sample Receiving Dt & Tm : 28/09/2022/ 10:47 AM
Patient Type : OPD	Report Released on : 28/09/2022/ 11.45 AM
Bed No :	

**HEMATOLOGY**

**Complete Blood Count -CBC(HB\TLC\PCV\RBC\Platelet)**


TEST NAME	RESULT	UNITS	REFERENCE INTERVAL	BIOLOGICAL SPECIMEN TYPE
TEST METHOD				
Hemoglobin (Hb) (Colorimetry)	15.5	gm/dl	13.5 - 18.0	WHOLE BLOOD
TLC (Electrical Impedence)	6100	cell/cumm	4500 - 11000	EDTA WHOLE
<b>DIFFERENTIAL COUNT</b>				
Neutrophils (Flow Cytometry)	65	%	40 - 75	EDTA WHOLE
Lymphocytes (Flow Cytometry)	30	%	20 - 45	EDTA WHOLE
Monocytes (Flow Cytometry)	03	%	1 - 10	EDTA WHOLE
Eosinophil (Flow Cytometry)	02	%	1 - 6	EDTA WHOLE
Basophil	00	%	0 - 1	
RBC (Electrical Impedence)	5.5	millions/cumm	4.7 - 6.1	EDTA WHOLE

-\*\*\*\* End of Report \*\*\*\*-

Lab Technician

Dr.NishaTiwari  
(MD.Microbiology)

  
 Dr. Neha Gupta  
 MBBS,MD(Pathology)  
 (Consultant Pathologist)

  
 Dr. Shreya Pradhan  
 MBBS,MD(Microbiology)  
 (Consultant Microbiologist)

Page 1 of 2

(This is only professional opinion and not the diagnosis. Please correlate clinically)

Sector 37-D, BPTP, Dwarka Express Way, Gurugram, Hry.,

Ph.: 0124-6034444, 8526000000, E-mail : signaturehospital@gmail.com, Web.: www.thesignaturehealthcare.com

**PARK GROUP OF HOSPITAL : ★ West Delhi ★ South Delhi ★ Gurugram ★ Faridabad ★ Panipat ★ Karnal**

Patient Name : Mr. SATYAVAN	UHID : 15003
Age / Gender : 33 Years 9 Months 26Days / Male	IPNO :
Referred By : Dr. CMO	Registered : 28/09/2022/ 9.09 AM
Req.No : 22227782	Sample Collection Dt & Tm : 28/09/2022/ 10.46 AM
Sample ID : 2237322	Sample Receiving Dt & Tm : 28/09/2022/ 10:47 AM
Patient Type : OPD	Report Released on : 28/09/2022 / 12.20 PM
Bed No :	

**BIOCHEMISTRY**

**Blood Sugar Fasting**

TEST NAME	RESULT	UNITS	BIOLOGICAL REFERENCE INTERVAL	BIOLOGICAL SPECIMEN TYPE
TEST METHOD				
BLOOD SUGAR FASTING (God- Trinders)	95	mg/dl	75 - 115	Flouride Plasma

Increased In:

- Diabetes Mellitus
- Stress ( e.g, emotion, burns, shock, anesthesia)
- Acute Pancreatitis
- Chronic Pancreatitis
- Wernicke encephalopathy ( Vitamin B1 deficiency)
- Effect of drugs (e.g. corticosterogens, alcohol, phenytoin, thiazides)

Decreased in :


- Pancreatitis disorders
- Extrapancreatic tumors
- Endocrine disorders
- Malnutrition
- Hypothalamic lesions
- Alcoholism
- Endocrine Disorders

\*\*\*\* End of Report \*\*\*\*

Lab Technician

Dr.NishaTiwari  
(MD.Microbiology)

  
 Dr. Neha Gupta  
 MBBS,MD(Pathology)  
 (Consultant Pathologist)

  
 Dr. Shreya Pradhan  
 MBBS,MD(Microbiology)  
 (Consultant Microbiologist)

(This is only professional opinion and not the diagnosis. Please correlate clinically)

Sector 37-D, BPTP, Dwarka Express Way, Gurugram, Hry.,

Ph.: 0124-6034444, 8526000000, E-mail : signaturehospital@gmail.com, Web.: www.thesignaturehealthcare.com

**PARK GROUP OF HOSPITAL : ★ West Delhi ★ South Delhi ★ Gurugram ★ Faridabad ★ Panipat ★ Karnal**

Patient Name : Mr. SATYAVAN	UHID : 15003
Age / Gender : 33 Years 9 Months 26Days / Male	IPNO :
Referred By : Dr. CMO	Registered : 28/09/2022/ 9.09 AM
Req.No : 22227782	Sample Collection Dt & Tm : 28/09/2022/ 10.46 AM
Sample ID : 2237322	Sample Receiving Dt & Tm : 28/09/2022/ 10:47 AM
Patient Type : OPD	Report Released on : 29/09/2022/ 4.36 PM
Bed No :	

**SEROLOGY/IMMUNOLOGY**

**Thyroid Profile**

TEST NAME	RESULT	UNITS	BIOLOGICAL REFERENCE INTERVAL	SPECIMEN TYPE
TEST METHOD				
Triiodothyronine (T3)	0.97	ng/ml	0.60 - 1.81	SERUM
Thyroxine (T4) CLIA	6.5	ug/dL	5.01 - 12.45	
TSH ( Thyroid Stimulating Hormone ) CLIA	3.82	uIU/ml	0.55 - 5.55	


**Remarks :**


(1) 4.2 to 15 IU/mL - Correlate clinically as physiological and other factors may falsely elevate TSH level. (2) TSH Values may be transiently altered because of non thyroidal illness. (3) Some drugs may decrease TSH values, e.g., L-dopa, Glucocorticoids. (4) Some drugs may increase TSH values, e.g., Iodine, Lithium, Amiodarone. Abbreviations.

-\*\*\*\* End of Report \*\*\*\*-

Lab Technician

  
 Dr. Nisha Tiwari  
 (MD. Microbiology)

  
 Dr. Neha Gupta  
 MBBS, MD(Pathology)  
 (Consultant Pathologist)

  
 Dr. Shreya Pradhan  
 MBBS, MD(Microbiology)  
 (Consultant Microbiologist)

Page 1 of 1

(This is only professional opinion and not the diagnosis. Please correlate clinically)

Sector 37-D, BPTP, Dwarka Express Way, Gurugram, Hry.,

Ph.: 0124-6034444, 8526000000, E-mail : signaturehospital@gmail.com, Web.: www.thesignaturehealthcare.com

**PARK GROUP OF HOSPITAL : ★ West Delhi ★ South Delhi ★ Gurugram ★ Faridabad ★ Panipat ★ Karnal**

Patient Name : Mr. SATYAVAN	UHID : 15003
Age / Gender : 33 Years 9 Months 26Days / Male	IPNO :
Referred By : Dr. CMO	Registered : 28/09/2022/ 9.09 AM
Req.No : 22227782	Sample Collection Dt & Tm : 28/09/2022/ 10.46 AM
Sample ID : 2237322	Sample Receiving Dt & Tm : 28/09/2022/ 10:47 AM
Patient Type : OPD	Report Released on : 28/09/2022/ 12.21 PM
Bed No :	

**BIOCHEMISTRY**

**Lipid Profile**


TEST NAME	RESULT	UNITS	BIOLOGICAL REFERENCE INTERVAL	SPECIMEN TYPE
TEST METHOD				
<b>LIPID PROFILE</b>				
CHOLESTROL (CHOD-TRINDER)	181	mg/dl	00 - 200	SERUM
TRIGLYCERIDES (GPO-Trinders)	97	mg/dl	35 - 170	SERUM
HDL- CHOL (Direct Method/ Enzymatic Colorometric)	40	mg/dl	40 - 60	SERUM
VLDL-CHOL CALCULATED	19.4	mg/dl	10 - 40	
LDL-CHOLESTROL	121.6	mg/dl	0 - 130	
LDL/HDL RATIO	<b>3.04</b>		0-3	
CHOLESTROL/HDL RATIO	<b>4.53</b>			

-\*\*\*\* End of Report \*\*\*\*-

Lab Technician

Dr.NishaTiwari  
(MD.Microbiology)

  
 Dr. Neha Gupta  
 MBBS,MD(Pathology)  
 (Consultant Pathologist)

  
 Dr. Shreya Pradhan  
 MBBS,MD(Microbiology)  
 (Consultant Microbiologist)

Page 1 of 2

(This is only professional opinion and not the diagnosis. Please correlate clinically)

Sector 37-D, BPTP, Dwarka Express Way, Gurugram, Hry.,

Ph.: 0124-6034444, 8526000000, E-mail : signaturehospital@gmail.com, Web.: www.thesignaturehealthcare.com

**PARK GROUP OF HOSPITAL : ★ West Delhi ★ South Delhi ★ Gurugram ★ Faridabad ★ Panipat ★ Karnal**

Patient Name : Mr. SATYAVAN	UHID : 15003
Age / Gender : 33 Years 9 Months 26Days / Male	IPNO :
Referred By : Dr. CMO	Registered : 28/09/2022/ 9.09 AM
Req.No : 22227782	Sample Collection Dt & Tm : 28/09/2022/ 10.46 AM
Sample ID : 2237322	Sample Receiving Dt & Tm : 28/09/2022/ 10:47 AM
Patient Type : OPD	Report Released on : 28/09/2022/ 12.22 PM
Bed No :	

**BIOCHEMISTRY**

**Liver Function Test Profile**


TEST NAME	RESULT	UNITS	BIOLOGICAL REFERENCE INTERVAL	SPECIMEN TYPE
TEST METHOD				
<b><u>BILIRUBIN TOTAL AND DIRECT</u></b>				
BILIRUBIN TOTAL (Diazonium Salt)	1.0	mg/dl	0.1 - 1.2	SERUM
BILIRUBIN DIRECT (Diazonium Salt)	0.3	mg/dl	00 - 0.3	SERUM
BILIRUBIN INDIRECT (CALCULATED)	0.7	md/dl	0 - 0.9	
SGOT/AST (UV-KINETIC)	21	U/I	0 - 45	SERUM
SGPT/ALT (UV-KINETIC)	20	U/I	0 - 45	SERUM
ALKALINE PHOSPHATASE (ALP) (Kinetic)	65	U/I	41 - 137	SERUM

-\*\*\*\* End of Report \*\*\*\*-

Lab Technician

Dr.NishaTiwari  
(MD.Microbiology)

  
 Dr. Neha Gupta  
 MBBS,MD(Pathology)  
 (Consultant Pathologist)

  
 Dr. Shreya Pradhan  
 MBBS,MD(Microbiology)  
 (Consultant Microbiologist)

Page 1 of 2

(This is only professional opinion and not the diagnosis. Please correlate clinically)

Sector 37-D, BPTP, Dwarka Express Way, Gurugram, Hry.,

Ph.: 0124-6034444, 8526000000, E-mail : signaturehospital@gmail.com, Web.: www.thesignaturehealthcare.com

PARK GROUP OF HOSPITAL : ★ West Delhi ★ South Delhi ★ Gurugram ★ Faridabad ★ Panipat ★ Karnal

Patient Name : Mr. SATYAVAN	UHID : 15003
Age / Gender : 33 Years 9 Months 26Days / Male	IPNO :
Referred By : Dr. CMO	Registered : 28/09/2022/ 9.09 AM
Req.No : 22227782	Sample Collection Dt & Tm : 28/09/2022/ 10.46 AM
Sample ID : 2237322	Sample Receiving Dt & Tm : 28/09/2022/ 10:47 AM
Patient Type : OPD	Report Released on : 28/09/2022/ 12.22 PM
Bed No :	

**BIOCHEMISTRY**


**PROTEINS**


TOTAL PROTEIN (Biuret)	6.7	g/dl	6.0 - 8.3	SERUM
ALBUMIN (BCG- DYE)	4.5	g/dl	3.2 - 5.0	SERUM
GLOBULIN Calculated	2.2	gm/dl	1.5 - 3.6	
A/G RATIO Calculated	2.05		0.9 - 2.0	

-\*\*\*\* End of Report \*\*\*\*-

Lab Technician

Dr.NishaTiwari  
(MD.Microbiology)

  
Dr. Neha Gupta  
MBBS,MD(Pathology)  
(Consultant Pathologist)

  
Dr. Shreya Pradhan  
MBBS,MD(Microbiology)  
(Consultant Microbiologist)

Page 2 of 2

(This is only professional opinion and not the diagnosis. Please correlate clinically)

Sector 37-D, BPTP, Dwarka Express Way, Gurugram, Hry.,

Ph.: 0124-6034444, 8526000000, E-mail : signaturehospital@gmail.com, Web.: www.thesignaturehealthcare.com

**PARK GROUP OF HOSPITAL** : ★ West Delhi ★ South Delhi ★ Gurugram ★ Faridabad ★ Panipat ★ Karnal



Patient Name : Mr. SATYAVAN	UHID : 15003
Age / Gender : 33 Years 9 Months 26Days / Male	IPNO :
Referred By : Dr. CMO	Registered : 28/09/2022/ 9.09 AM
Req.No : 22227782	Sample Collection Dt & Tm : 28/09/2022/ 10.46 AM
Sample ID : 2237322	Sample Receiving Dt & Tm : 28/09/2022/ 10:47 AM
Patient Type : OPD	Report Released on : 28/09/2022/ 12.22 PM
Bed No :	

**BIOCHEMISTRY**

**Renal Profile**


TEST NAME	RESULT	UNITS	REFERENCE INTERVAL	BIOLOGICAL SPECIMEN TYPE
TEST METHOD				
BLOOD UREA (Urease UV/GLDH)	19	mg/dl	13 - 45	SERUM
SERUM CREATININE (Jaffe Rate)	0.8	mg/dl	0.6 - 1.4	SERUM
URIC ACID (Enzymatic/Uricase)	4.8	mg/dl	3.6 - 7.2	SERUM
<b>ELECTROLYTES</b>				
SODIUM (ISE-Indirect)	148	mmol/L	132 - 150	SERUM
POTASSIUM (ISE-Indirect)	4.6	mmol/L	3.5 - 5.5	SERUM

-\*\*\*\* End of Report \*\*\*\*-

Lab Technician

Dr.NishaTiwari  
(MD.Microbiology)

  
 Dr. Neha Gupta  
 MBBS,MD(Pathology)  
 (Consultant Pathologist)

  
 Dr. Shreya Pradhan  
 MBBS,MD(Microbiology)  
 (Consultant Microbiologist)

Page 1 of 2

(This is only professional opinion and not the diagnosis. Please correlate clinically)

Sector 37-D, BPTP, Dwarka Express Way, Gurugram, Hry.,

Ph.: 0124-6034444, 8526000000, E-mail : signaturehospital@gmail.com, Web.: www.thesignaturehealthcare.com

PARK GROUP OF HOSPITAL : ★ West Delhi ★ South Delhi ★ Gurugram ★ Faridabad ★ Panipat ★ Karnal

Patient Name : Mr. SATYAVAN	UHID : 15003
Age / Gender : 33 Years 9 Months 26Days / Male	IPNO :
Referred By : Dr. CMO	Registered : 28/09/2022/ 9.09 AM
Req.No : 22227782	Sample Collection Dt & Tm : 28/09/2022/ 10.46 AM
Sample ID : 2237322	Sample Receiving Dt & Tm : 28/09/2022/ 10:47 AM
Patient Type : OPD	Report Released on : 28/09/2022/ 12.22 PM
Bed No :	

**BIOCHEMISTRY**


**PROTEINS**


TOTAL PROTEIN (Biuret)	6.7	g/dl	6.0 - 8.3	SERUM
ALBUMIN (BCG- DYE)	4.5	g/dl	3.2 - 5.0	SERUM
GLOBULIN Calculated	2.2	gm/dl	1.5 - 3.6	
A/G RATIO Calculated	2.05		0.9 - 2.0	

-\*\*\*\* End of Report \*\*\*\*-

Lab Technician

Dr.NishaTiwari  
(MD.Microbiology)

  
 Dr. Neha Gupta  
 MBBS,MD(Pathology)  
 (Consultant Pathologist)

  
 Dr. Shreya Pradhan  
 MBBS,MD(Microbiology)  
 (Consultant Microbiologist)

Page 2 of 2

(This is only professional opinion and not the diagnosis. Please correlate clinically)

Sector 37-D, BPTP, Dwarka Express Way, Gurugram, Hry.,

Ph.: 0124-6034444, 8526000000, E-mail : signaturehospital@gmail.com, Web.: www.thesignaturehealthcare.com

**PARK GROUP OF HOSPITAL : ★ West Delhi ★ South Delhi ★ Gurugram ★ Faridabad ★ Panipat ★ Karnal**

  
**The Signature**  
ADVANCED SUPER SPECIALITY  
H O S P I T A L



Patient Name : Mr. SATYAVAN	UHID : 15003
Age / Gender : 33 Years 9 Months 26Days / Male	IPNO :
Referred By : Dr. CMO	Registered : 28/09/2022/ 9.09 AM
Req.No : 22227782	Sample Collection Dt & Tm : 28/09/2022/ 10.46 AM
Sample ID : 2237322	Sample Receiving Dt & Tm : 28/09/2022/ 10:47 AM
Patient Type : OPD	Report Released on : 28/09/2022 / 11.45 AM
Bed No :	

**HEMATOLOGY**

**Blood Group And Rh Factor**


TEST NAME	RESULT	UNITS	BIOLOGICAL
TEST METHOD			REFERENCE INTERVAL SPECIMEN TYPE
BLOOD GROUP(ABORh)	"B" POSITIVE		

-\*\*\*\* End of Report \*\*\*\*-

Lab Technician

Dr.NishaTiwari  
(MD.Microbiology)

  
Dr. Neha Gupta  
MBBS,MD(Pathology)  
(Consultant Pathologist)

  
Dr. Shreya Pradhan  
MBBS,MD(Microbiology)  
(Consultant Microbiologist)

(This is only professional opinion and not the diagnosis. Please correlate clinically)

Sector 37-D, BPTP, Dwarka Express Way, Gurugram, Hry.,

Ph.: 0124-6034444, 8526000000, E-mail : signaturehospital@gmail.com, Web.: www.thesignaturehealthcare.com  
PARK GROUP OF HOSPITAL : ★ West Delhi ★ South Delhi ★ Gurugram ★ Faridabad ★ Panipat ★ Karnal

  
**The Signature**  
ADVANCED SUPER SPECIALITY  
H O S P I T A L



Patient Name : Mr. SATYAVAN UHID : 15003  
Age / Gender : 33 Years 9 Months 26Days / Male IPNO :  
Referred By : Dr. CMO Registered : 28/09/2022/ 9.09 AM  
Req.No : 22227782 Sample Collection Dt & Tm : 28/09/2022/ 10.46 AM  
Sample ID : 2237322 Sample Receiving Dt & Tm : 28/09/2022/ 10:47 AM  
Patient Type : OPD Report Released on : 29/09/2022/ 3.40 PM  
Bed No :

**BIOCHEMISTRY**

**Glycosylated Haemoglobin**


TEST NAME	RESULT	UNITS	BIOLOGICAL
TEST METHOD			REFERENCE INTERVAL SPECIMEN TYPE
HbA1C (GLYCOSYLATED HEMOGLOBIN)	5.3	%	4.6 - 6.2

Metabolically Healthy Patients 4.5 6.0  
Good Control 6.1 6.5  
Fair Control 6.6 7.0  
Poor Control > 7.0

\*\*\*\* End of Report \*\*\*\*

Lab Technician Dr.NishaTiwari  
(MD.Microbiology)

  
Dr. Neha Gupta  
MBBS,MD(Pathology)  
(Consultant Pathologist)

  
Dr. Shreya Pradhan  
MBBS,MD(Microbiology)  
(Consultant Microbiologist)

Page 1 of 1

(This is only professional opinion and not the diagnosis. Please correlate clinically)

Sector 37-D, BPTP, Dwarka Express Way, Gurugram, Hry.,

Ph.: 0124-6034444, 8526000000, E-mail : signaturehospital@gmail.com, Web.: www.thesignaturehealthcare.com

PARK GROUP OF HOSPITAL . : ★ West Delhi ★ South Delhi ★ Gurugram ★ Faridabad ★ Panipat ★ Karnal

Patient Name : Mr. SATYAVAN	UHID : 15003
Age / Gender : 33 Years 9 Months 26Days / Male	IPNO :
Referred By : Dr. CMO	Registered : 28/09/2022/ 9.09 AM
Req.No : 22227782	Sample Collection Dt & Tm : 28/09/2022/ 10.46 AM
Sample ID : 2237322	Sample Receiving Dt & Tm : 28/09/2022/ 10:47 AM
Patient Type : OPD	Report Released on : 28/09/2022 / 12.24 PM
Bed No :	

**CLINICAL PATHOLOGY**

**Urine Routine And Microscopy.**


TEST NAME	RESULT	UNITS	BIOLOGICAL
TEST METHOD			REFERENCE INTERVAL    SPECIMEN TYPE
QUANTITY	40 ML		
COLOUR	PALE YELLOW		
TURBIDITY	CLEAR		
SPECIFIC GRAVITY (Bromthymol Blue)	1.030		1.003-1.030    Urine
PH (Chromatography)	9.0		4.7-7.0    Urine

-\*\*\*\* End of Report \*\*\*\*-

Lab Technician

Dr.NishaTiwari  
(MD.Microbiology)

  
 Dr. Neha Gupta  
 MBBS,MD(Pathology)  
 (Consultant Pathologist)

  
 Dr. Shreya Pradhan  
 MBBS,MD(Microbiology)  
 (Consultant Microbiologist)

Page 1 of 3

(This is only professional opinion and not the diagnosis. Please correlate clinically)

Sector 37-D, BPTP, Dwarka Express Way, Gurugram, Hry.,

Ph.: 0124-6034444, 8526000000, E-mail : signaturehospital@gmail.com, Web.: www.thesignaturehealthcare.com

**PARK GROUP OF HOSPITAL : ★ West Delhi ★ South Delhi ★ Gurugram ★ Faridabad ★ Panipat ★ Karnal**

Patient Name : Mr. SATYAVAN	UHID : 15003
Age / Gender : 33 Years 9 Months 26Days / Male	IPNO :
Referred By : Dr. CMO	Registered : 28/09/2022/ 9.09 AM
Req.No : 22227782	Sample Collection Dt & Tm : 28/09/2022/ 10.46 AM
Sample ID : 2237322	Sample Receiving Dt & Tm : 28/09/2022/ 10:47 AM
Patient Type : OPD	Report Released on : 28/09/2022 / 12.24 PM
Bed No :	

**CLINICAL PATHOLOGY**

**CHEMICAL EXAMINATION**


UROBILINOGEN (Ehrlichs Aldehyde Reaction)	NORMAL	NORMAL	Urine
PROTEIN	NIL	NIL	
BLOOD	NIL	NIL	
KETONE (Sodium Nitroprusside)	NIL	NIL	Urine
BILIRUBIN (Diazonium Salt)	NIL	NIL	SERUM
GLUCOSE (Benedicts Test)	NIL	NIL	Urine
NITRITE	NEGATIVE		

-\*\*\*\* End of Report \*\*\*\*-

Lab Technician

Dr.NishaTiwari  
(MD.Microbiology)

  
 Dr. Neha Gupta  
 MBBS,MD(Pathology)  
 (Consultant Pathologist)

  
 Dr. Shreya Pradhan  
 MBBS,MD(Microbiology)  
 (Consultant Microbiologist)

(This is only professional opinion and not the diagnosis. Please correlate clinically)

Sector 37-D, BPTP, Dwarka Express Way, Gurugram, Hry.,

Ph.: 0124-6034444, 8526000000, E-mail : signaturehospital@gmail.com, Web.: www.thesignaturehealthcare.com

**PARK GROUP OF HOSPITAL : ★ West Delhi ★ South Delhi ★ Gurugram ★ Faridabad ★ Panipat ★ Karnal**

Patient Name : Mr. SATYAVAN	UHID : 15003
Age / Gender : 33 Years 9 Months 26Days / Male	IPNO :
Referred By : Dr. CMO	Registered : 28/09/2022/ 9.09 AM
Req.No : 22227782	Sample Collection Dt & Tm : 28/09/2022/ 10.46 AM
Sample ID : 2237322	Sample Receiving Dt & Tm : 28/09/2022/ 10:47 AM
Patient Type : OPD	Report Released on : 28/09/2022/ 12.24 PM
Bed No :	

**CLINICAL PATHOLOGY**

**MICROSCOPIC EXAMINATION - URINE**


PUS CELLS (Microscopic)	1-2	/HPF	0 - 3	Urine
RBC- Urine (Per Oxidase Reaction)	NIL	/HPF	NIL	Urine
EPITHELIAL CELLS	0-2	/HPF	0 - 5	
CAST	NIL		NIL	
CRYSTALS	NIL		NIL	
BACTERIA	NIL			
OTHERS	NIL			


COMMENTS: Actual numerical values for WBCs, RBCs and Epithelial cells are not defined and must be correlated clinically.


Test Methods: Reagent strip analysis and urine sediment microscopy.  
 Reagent strip / chemical analysis are based on: pH-Double Indicator principle; Specific gravity Ion exchange method; Glucose Glucose oxidase-peroxidase/Benedicts; Protein Acid-base indicator/Sulfosalicylic acid; Urobilinogen Coupling reaction/Ehrlichsreaction, Bilirubin Coupling reaction, Ketones Nitroprusside method/Rotheras test.

-\*\*\*\* End of Report \*\*\*\*-

Lab Technician

  
 Dr.NishaTiwari  
 (MD.Microbiology)

  
 Dr. Neha Gupta  
 MBBS,MD(Pathology)  
 (Consultant Pathologist)

  
 Dr. Shreya Pradhan  
 MBBS,MD(Microbiology)  
 (Consultant Microbiologist)

(This is only professional opinion and not the diagnosis. Please correlate clinically)

Sector 37-D, BPTP, Dwarka Express Way, Gurugram, Hry.,

Ph.: 0124-6034444, 8526000000, E-mail : signaturehospital@gmail.com, Web.: www.thesignaturehealthcare.com

**PARK GROUP OF HOSPITAL : ★ West Delhi ★ South Delhi ★ Gurugram ★ Faridabad ★ Panipat ★ Karnal**

**TRANSTHORACIC ECHO- DOPPLER REPORT**

NAME - MR.SATYAVAN	AGE/SEX -33/M
MR. NO. - 15003	DATE - 28/9/2022

**M-MODE / 2-D DESCRIPTION**

- ❖ **Left Ventricle:** No regional wall motion abnormality. LVEF ~ 60 %.
- ❖ **Left Atrium:** Normal.
- ❖ **Right atrium:** It is Normal Sized.
- ❖ **Right ventricle:** It is Normal Sized. RV Systolic Function is Normal.
- ❖ **Aortic valve:** Aortic Cusps are Normal.
- ❖ **Mitral valve:** It Appears Normal.
- ❖ **Tricuspid valve:** It Appears Normal.
- ❖ **Pulmonic valve:** It Appears Normal.
- ❖ **Main pulmonary artery & its branches:** Appear Normal.
- ❖ **Pericardium:** No Pericardial Effusion Seen
- ❖ **Inter atrial septum:** It is Intact.
- ❖ **Inter ventricular septum:** It is Intact.
- ❖ **IVC:** It is Normal in Size, collapsing & Respiratory Variability.
- ❖ **Clot / Vegetation:** No Intracardiac Clot, Vegetation.

**Measurements (mm):**

LEFT HEART			RIGHT HEART		
	Observed values (mm)	Normal values		Observed values (mm)	Normal values
Aortic root	29	20-36	IVC size	-	17-21mm
Aortic valve opening		(22mm/M <sup>2</sup> ) 15-26 (mm/M <sup>2</sup> )	IVC respiratory variability		>50%
LA size	30	19-40 (mm/M <sup>2</sup> )	RA size	-	<18cm <sup>2</sup>
LA volume index (ml/M <sup>2</sup> )		<34 ml/M <sup>2</sup>	RV basal		24-42mm
LVID(D) ' "	52	(ED=37-56)	RV mid cavity	-	20-35mm
LVID(S)	42		RV longitudinal	-	56-86mm
IVS(D)	9	(ED=6-12)	RVOT proximal	-	18-33mm
PW(D)	11	(ED=5-10)	TAPSE	-	>15mm
			RV free wall thickness	-	<5mm
LVEF(%)	60%	55%-70%	RVEF		>44%

(This is only professional opinion and not the diagnosis. Please correlate clinically)

Sector 37-D, BPTP, Dwarka Express Way, Gurugram, Hry.,

Ph.: 0124-6034444, 8526000000, E-mail : signaturehospital@gmail.com, Web.: www.thesignaturehealthcare.com

**PARK GROUP OF HOSPITAL : ★ West Delhi ★ South Delhi ★ Gurugram ★ Faridabad ★ Panipat ★ Kamal**



Doppler velocities (cm/sec)

Aortic valve		Pulmonary valve	
Max/ Vel	115	Max velocity	106
Max/ PG		Max PG	
Mitral valve		Tricuspid valve	
E	62	Max Velocity	
A	63	PASP	-
DT	-	E/E' (>6)	-
E/A	-	S' Velocity (>10cm2/sec)	-

Regurgitation

MR		TR	
Severity	Nil	Severity	Nil
AR		PR	
Severity	Nil	Severity	Nil

Final Interpretation:

- No regional wall motion abnormality. LVEF ~ 60 %
- Normal Cardiac Chamber Dimension.
- No MR, No AR. No TR.
- Normal MIP.
- No Vegetation, Pericardial Effusion.



**Dr. AJAY DUA**  
 DNB (Medicine), DNB (Cardiology)  
 Sr. Consultant Interventional Cardiology

(This is only professional opinion and not the diagnosis. Please correlate clinically)

Sector 37-D, BPTP, Dwarka Express Way, Gurugram, Hry.,

Ph.: 0124-6034444, 8526000000, E-mail : signaturehospital@gmail.com, Web.: www.thesignaturehealthcare.com

**PARK GROUP OF HOSPITAL** : ★ West Delhi ★ South Delhi ★ Gurugram ★ Faridabad ★ Panipat ★ Karnal

**DEPARTMENT OF IMAGING & INTERVENTIONAL RADIOLOGY, THE SIGNATURE HOSPITAL**

<b>NAME: SATYAVAN</b>	<b>DATE: 28/09/2022</b>
<b>AGE: 33 Y/M</b>	<b>MR NO.: 15003</b>

**USG WHOLE ABDOMEN**

**LIVER:** is normal in size and echotexture. No evidence of any focal lesion or IHBR dilation is present. Portal vein and CBD are normal in caliber at porta.

**GALL BLADDER** is well distended and lumen is echofree. Wall thickness is normal. No pericholecystic fluid is seen.

**SPLEEN** is normal in size and echotexture. No focal lesion is seen.

**PANCREAS** is normal in size and echotexture. Peripancreatic fat planes are clear. MPD is not dilated.

**RIGHT KIDNEY:** is normal in size and position and outline. Corticomedullary differentiation is maintained. There is no evidence of any focal lesion / calculus / backpressure changes.

**LEFT KIDNEY:** is normal in size and position and outline. Corticomedullary differentiation is maintained. There is no evidence of any focal lesion / calculus / backpressure changes.

**URINARY BLADDER** is well distended and lumen is echofree. Wall thickness is normal. No evidence of any focal lesion.

**PROSTATE:** is normal in size.

No free fluid is noted.

**IMPRESSION:**

- **No significant abnormality.**

*Please correlate clinically*



**Dr. Guru**  
Senior Consultant  
Diagnostic & Interventional Radiology

(This is only professional opinion and not the diagnosis. Please correlate clinically)

Sector 37-D, BPTP, Dwarka Express Way, Gurugram, Hry.,

Ph.: 0124-6034444, 8526000000, E-mail : signaturehospital@gmail.com, Web.: www.thesignaturehealthcare.com

**PARK GROUP OF HOSPITAL** : ★ West Delhi ★ South Delhi ★ Gurugram ★ Faridabad ★ Panipat ★ Karnal

UID	15003	Date: 28 Sep 2022
Name/Age/Sex :	SATYAVAN 33Yr / Male	
Treating Dr. :		

**X - RAY CHEST PA VIEW**

**FINDINGS :**

**Mild Prominent bronchovascular markings noted at bilateral lung fields .**

Trachea is in midline.

Cardiac silhouette maintained.

Both CP angles are clear.

Rest of lung parenchyma are normal.

Bony cage and soft tissues are normal.

The domes of the diaphragms are normal in position, and show smooth outline.

**IMPRESSION:**

**Mild Prominent bronchovascular markings noted at bilateral lung fields.**

**For clinical correlation.**



Dr. Avinash Rathod (DMRD)  
Consultant Radiologist  
Reg. No. 2011/05/1616/1616

(This is only professional opinion and not the diagnosis. Please correlate clinically)

Sector 37-D, BPTP, Dwarka Express Way, Gurugram, Hry.,

Ph.: 0124-6034444, 8526000000, E-mail : signaturehospital@gmail.com, Web.: www.thesignaturehealthcare.com

**PARK GROUP OF HOSPITAL** : ★ West Delhi ★ South Delhi ★ Gurugram ★ Faridabad ★ Panipat ★ Karnal