



Info Department <info@aakashhospital.com>

Health Check up Booking Confirmed Request(bobS3124),Package Code- PKG10000249, Beneficiary Code-34082

Mediwheel <noreply@mediwheel.in>

Wed, Sep 8, 2021 at 11:31 AM

To: "info@aakashhospital.com" <info@aakashhospital.com>, Mediwheel Admin <santosh@policywheel.com>

Cc: Mediwheel CC <wellness1@mediwheel.in>, Mediwheel CC <customercare@mediwheel.in>



011-41195959

Email:wellness@mediwheel.in

Hi **Aakash Hospital,**

Diagnostic/Hospital Location :**90/43 Malviya Nagar New Delhi** City Delhi

We have received the confirmation for the following booking .

Beneficiary Name : PKG10000249

Beneficiary Name : sushmita gupta

Member Age : 25

Member Gender : Female

Member Relation : Spouse

Package Name : Mediwheel Metro BOB Full Body Health Checkup Female Below 40

Location : GULAB BAUG,Bihar-854326

Contact Details : 9728606010

Booking Date : 08-09-2021

Appointment Date : 10-09-2021

Instructions to undergo Health Check:

1. Please ensure you are on complete fasting for 10-To-12-Hours prior to check
2. During fasting time do not take any kind of medication, alcohol, cigarettes, tobacco or any other liquids (except Water) in the morning.
3. Bring urine sample in a container if possible (containers are available at the Health Check centre).
4. Please bring all your medical prescriptions and previous health medical records with you
5. Kindly inform the health check reception in case if you have a history of diabetes and cardiac problems.

For Women:

1. Pregnant Women or those suspecting are advised not to undergo any X-Ray test
2. It is advisable not to undergo any Health Check during menstrual cycle.

We request you to facilitate the employee on priority.



भारत सरकार
Unique Identification Authority of India

नामांकन क्रम / Enrollment No 20370837101420

सुशमिता गुप्ता
Sushmita Gupta
D/O Anil Kumar Gupta
10/10/1995
MIDHAT TANKA COLONY
MIDHAT NAGAR
Village of Madga Ambekar Nagar
Distt. Prayagraj - 221005
9415106121

Ref: 816+221 8807631+8008371



UID: 503890F09IN



आपका आधार क्रमांक / Your Aadhaar No.

8827 7159 4873

आधार - आम आदमी का अधिकार



भारत सरकार
GOVERNMENT OF INDIA

सुशमिता गुप्ता
Sushmita Gupta



जन्म वर्ष / Year of Birth: 1995
लिंग / Female



8827 7159 4873

आधार - आम आदमी का अधिकार

Sushmita Gupta

Amodita

DR. AMODITA AHUJA
MBBS, MS (Obs), DNB, FMAS
Consultant Gynaecologist
DMC No. - 86620



Aakash HospitalTM

Care with concern

(A unit of Dr. Gaba & Associates Medicare Pvt. Ltd.)



CIN No. U85110DL2004PTC125538

90/43, Malviya Nagar, New Delhi-110017
#+91-11-40501000 (100 Lines), 9871027922
info@aakashhospital.com, www.aakashhospital.com

NAME: SUSHMITA GUPTA

AGE: 25 YRS

SEX: FEMALE

REF. BY: MEDICAL

DATE: 09.09.21

ULTRASOUND WHOLE ABDOMEN

LIVER: - Normal sized, with homogenous echotexture. No focal lesion seen. Intra hepatic biliary system not dilated. Intra hepatic veins radicles are normal.

GALL BLADDER: - Normal distention. No mass lesion or calculus seen in the lumen. Extra hepatic biliary system is not dilated.

PANCREAS: - Normal size and echotexture. No focal lesion seen. Pancreatic duct not dilated.

SPLEEN: - Normal size and echotexture. No focal lesion seen. Spleno-portal axis is normal.

KIDNEYS: - Both kidneys normally identified in the respective renal fossae. They demonstrate normal size, contour and echo pattern with no evidence of hydronephrosis or calculus seen on either side.

Right kidney measures approx. 8.6 cm in the long axis.

Left kidney measures approx. 9.4 cm in the long axis.

URINARY BLADDER: - Moderately distended. No calculus or diverticulum's seen. Walls are normal. Both UV Junctions are normal.

UTERUS: - Normal sized (46 x 32 mm), demonstrating normal endometrial echo complex (4.5 mm) and even echo-textured myometrium.

OVARIES: - Normally visualized.

Retroperitoneum does not show any abnormally enlarged lymph nodes. No pleural effusion or ascites seen. Bowel loops are unremarkable. Both iliac fossae are normal.

IMPRESSION:- No significant abnormality detected.

Kindly correlate clinically.


DR. SALSABEEL.S
DMRD.DNB(RADIOLOGY)
DMC-35954

AREA OF EXPERTISE

• Interventions
(Vascular & Nonvascular)
• FNAC

• Biopsy
• Drainages
• Doppler Scans

• 3D & 4D Scans
• Varicose Vein
Laser Treatment





Aakash HospitalTM

Care with concern

(A unit of Dr. Gaba & Associates Medicare Pvt. Ltd.)



CIN No. U85110DL2004PTC125538

90/43, Malviya Nagar, New Delhi-110017
#+91-11-40501000 (100 Lines), 9871027922
info@aakashhospital.com, www.aakashhospital.com

NAME: SUSHMITA GUPTA AGE: 25 YRS SEX: FEMALE

REF.BY: MEDICAL DATE: 09.09.21

ULTRASOUND WHOLE ABDOMEN

LIVER:-Normal sized, with homogenous echotexture. No focal lesion seen. Intra hepatic biliary system not dilated. Intra hepatic veins radicles are normal.

GALL BLADDER: - Normal distention. No mass lesion or calculus seen in the lumen. Extra hepatic biliary system is not dilated.

PANCREAS: - Normal size and echotexture. No focal lesion seen. Pancreatic duct not dilated.

SPLEEN: - Normal size and echotexture. No focal lesion seen. Spleno-portal axis is normal.

KIDNEYS: - Both kidneys normally identified in the respective renal fossae. They demonstrate normal size, contour and echo pattern with no evidence of hydronephrosis or calculus seen on either side.

Right kidney measures approx. 8.6 cm in the long axis.

Left kidney measures approx. 9.4 cm in the long axis.

URINARY BLADDER: - Moderately distended. No calculus or diverticulum's seen. Walls are normal. Both UV Junctions are normal.


UTERUS: - Normal sized (46 x 32 mm), demonstrating normal endometrial echo complex (4.5 mm) and even echo-textured myometrium.

OVARIES: - Normally visualized.

Retroperitoneum does not show any abnormally enlarged lymph nodes. No pleural effusion or ascites seen. Bowel loops are unremarkable. Both iliac fossae are normal.

IMPRESSION:- No significant abnormality detected.

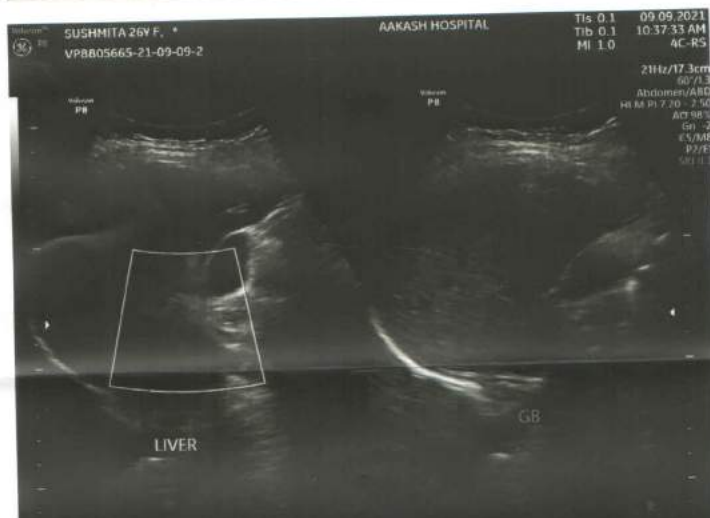
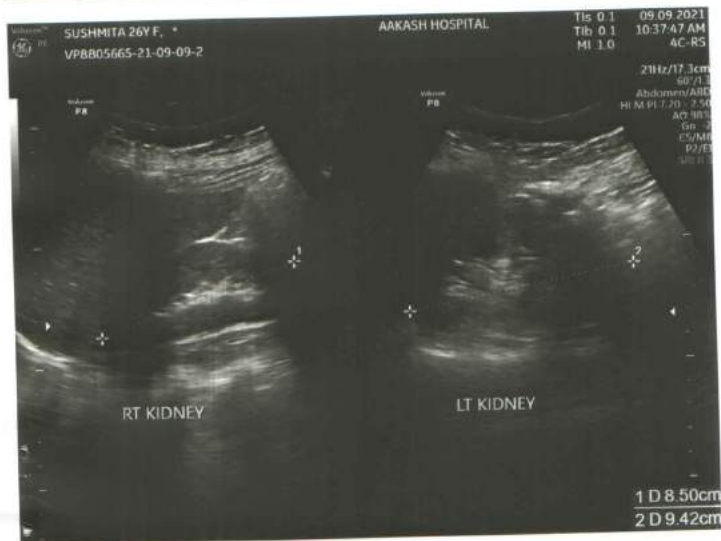
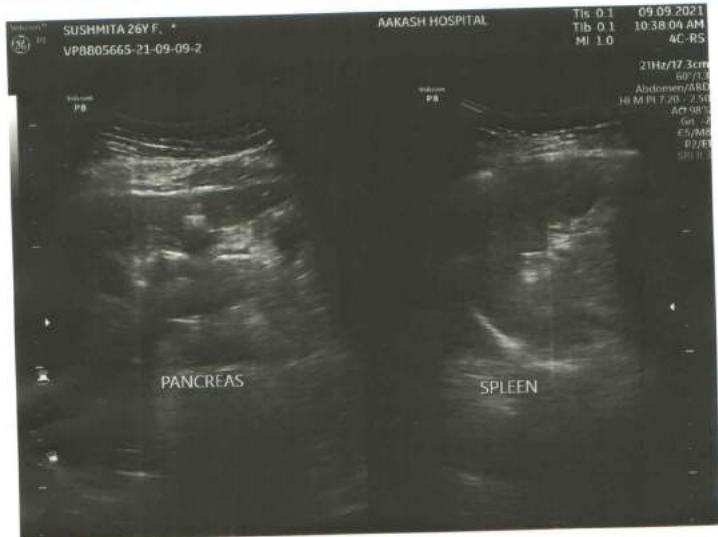
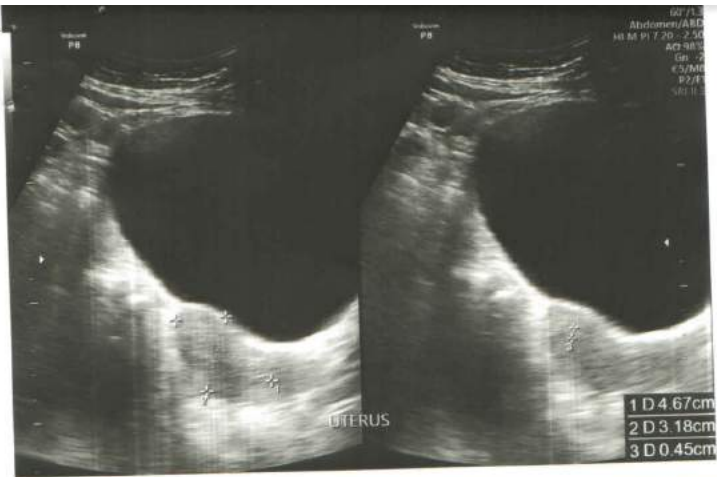
Kindly correlate clinically.


DR.SALSABEEL.S
DMRD.DNB(RADIOLOGY)
DMC-35954

AREA OF EXPERTISE

- Interventions (Vascular & Nonvascular)
- FNAC
- Biopsy
- Drainages
- Doppler Scans
- 3D & 4D Scans
- Varicose Vein Laser Treatment







ISO 9001:2008 CERTIFIED

Aakash HospitalTM

Care with concern

(A unit of Dr. Gaba & Associates Medicare Pvt. Ltd.)



CIN No. U85110DL2004PTC125538

90/43, Malviya Nagar, New Delhi-110017
#+91-11-40501000 (100 Lines), 9871027922
info@aakashhospital.com, www.aakashhospital.com

ECHOCARDIOGRAM REPORT

NAME : MS SUSHMITA
AGE/SEX : 25/F
DATE : 09.09.21

ECHOCARDIOGRAPHY & COLOR DOPPLER REPORT

MEASUREMENT	VALUE	NORMAL RANGE
AORTIC ROOT DIAMETER	26	20 – 37 mm
AORTIC VALVE OPENING	16	15 – 26 mm
LEFT ATRIAL DIMENSION	29	19 - 40 mm
RV DIMENSION	N	07 – 26 mm
RV THICKNESS	N	03 -09 mm
LV ED DIMENSION	48	37 – 56 mm
LV ES DIMENSION	33	22 - 40 mm
IVS THICKNESS	ED – 07 ES – 09	06 – 12 mm
LVPW THICKNESS	ED – 06 ES – 08	05 – 11 mm
IVS/LVPW RATION	N	
MITRAL VALVE	DE-N EF – N	
INDICES OF LV FUNCTION		
LVEF	60%	60 +/-5 %
FS	32%	24 -42 %

AREA OF EXPERTISE

- Interventions
(Vascular & Nonvascular)
- FNAC

- Biopsy
- Drainages
- Doppler Scans

- 3D & 4D Scans
- Varicose Vein
Laser Treatment





Aakash HospitalTM

Care with concern

(A unit of Dr. Gaba & Associates Medicare Pvt. Ltd.)



CIN No. U85110DL2004PTC125538

90/43, Malviya Nagar, New Delhi-110017
#+91-11-40501000 (100 Lines), 9871027922
info@aakashhospital.com, www.aakashhospital.com

IMAGING

- ❖ LV normal size. Good contractility. RWMA absent. No thrombus.
- ❖ LA normal in size. No clot.
- ❖ RV & RA normal size. RV contractility.
- ❖ Mitral valve leaflets normal. PML motion normal. No annular calcification present.
- ❖ Normal tricuspid & pulmonic valves.
- ❖ Aortic valve- tricuspid.
- ❖ Pericardium normal.

RWMA: ABSENT

DOPPLER:-

MV	E 1.08 m/sec	A 0.56 m/sec	MR	0/4
TV	0.40 m/sec		TR	0/4
AV	1.10 m/sec		AR	0/4
PV	0.85 m/sec		PR	0/4

COLOUR FLOW MAPPING: NORMAL.

FINAL IMPRESSION:-

- ❖ Normal LV wall motion and systolic function.
- ❖ Normal flow across valves.
- ❖ No LV clot, Vegetation, pericardial effusion.

DR. Rahul Trehan
MD, Medicine
Consultant Physician & Cardiologist

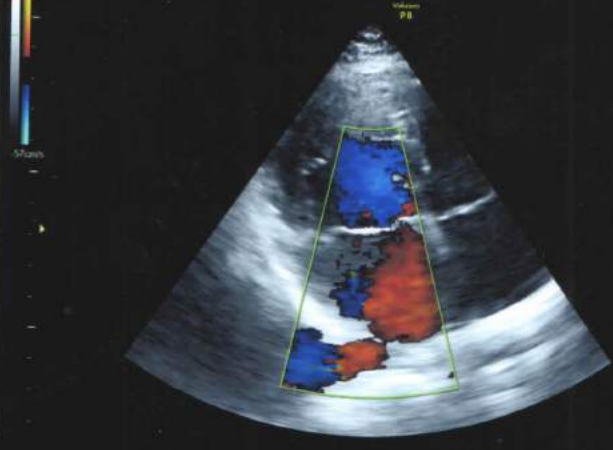
AREA OF EXPERTISE

- Interventions (Vascular & Nonvascular)
- FNAC
- Biopsy
- Drainages
- Doppler Scans
- 3D & 4D Scans
- Varicose Vein Laser Treatment

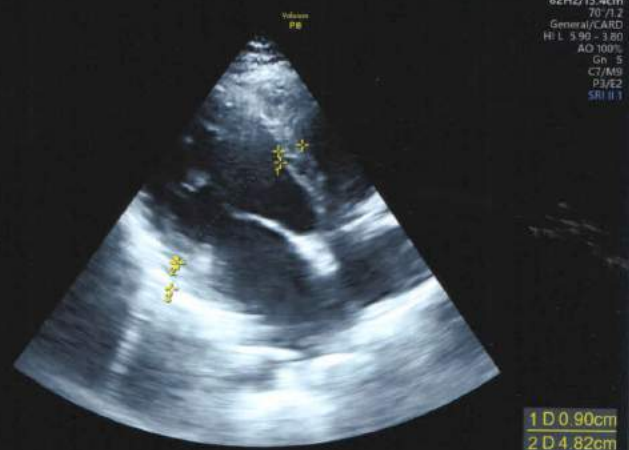

AAKASH HOSPITAL, MALVIYA NAGAR

SUSHMITA 26 F. * AAKASH HOSPITAL Tis 0.9 09.09.2021 SUSHMITA 26 F. * AAKASH HOSPITAL Tis 0.7 09.09.2021
 VP8805665-21-09-09-11 1:04:48 PM 35c-RS VP8805665-21-09-09-11 1:04:56 PM 35c-RS



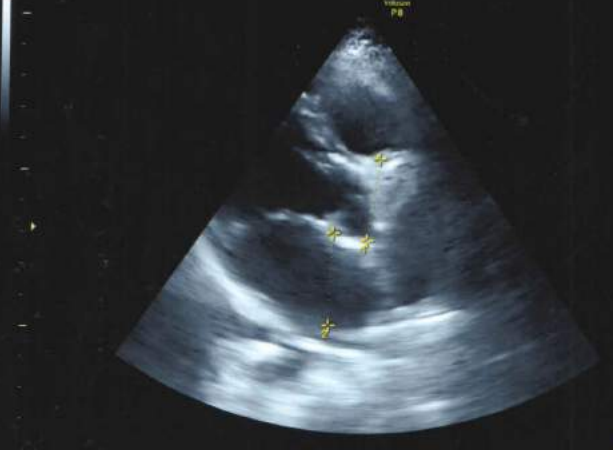
25Hz/13.4cm
 70°/1.2
 General/CARD
 HI L 5.90 - 3.80
 AO 100%
 Gn 5
 C7/M9
 P3/E2
 SRI II.1
 AO 100%
 Gn -2.4
 Freq mid
 Qual norm
 WMF mid2
 PRF 3.2kHz



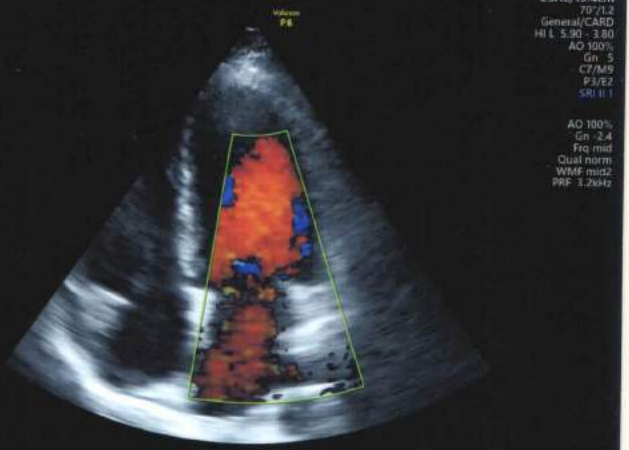
82Hz/13.4cm
 70°/1.2
 General/CARD
 HI L 5.90 - 3.80
 AO 100%
 Gn 5
 C7/M9
 P3/E2
 SRI II.1

1 D 0.90cm
 2 D 4.82cm
 3 D 0.86cm

SUSHMITA 26 F. * AAKASH HOSPITAL Tis 0.7 09.09.2021 SUSHMITA 26 F. * AAKASH HOSPITAL Tis 0.9 09.09.2021
 VP8805665-21-09-09-11 1:05:39 PM 35c-RS VP8805665-21-09-09-11 1:06:12 PM 35c-RS



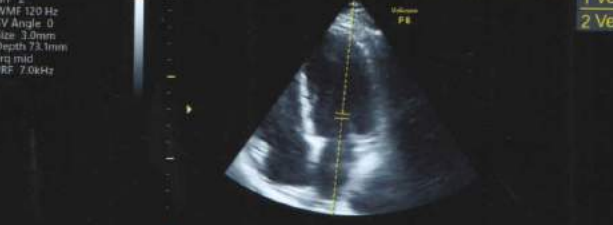
82Hz/13.4cm
 70°/1.2
 General/CARD
 HI L 5.90 - 3.80
 AO 100%
 Gn 5
 C7/M9
 P3/E2
 SRI II.1



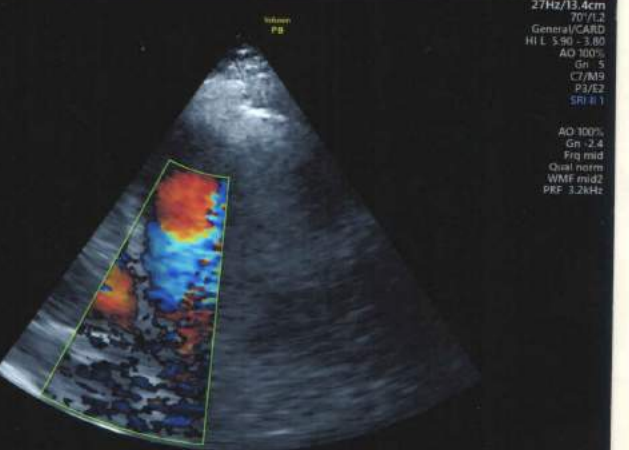
25Hz/13.4cm
 70°/1.2
 General/CARD
 HI L 5.90 - 3.80
 AO 100%
 Gn 5
 C7/M9
 P3/E2
 SRI II.1
 AO 100%
 Gn -2.4
 Freq mid
 Qual norm
 WMF mid2
 PRF 3.2kHz

1 D 2.63cm
 2 D 2.94cm

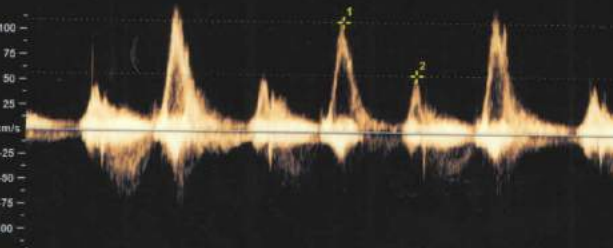
SUSHMITA 26 F. * AAKASH HOSPITAL Tis 1.1 09.09.2021 SUSHMITA 26 F. * AAKASH HOSPITAL Tis 0.9 09.09.2021
 VP8805665-21-09-09-11 1:07:18 PM 35c-RS VP8805665-21-09-09-11 1:07:36 PM 35c-RS



1 Vel 108.70cm/s
 2 Vel 56.20cm/s
 27Hz/13.4cm
 70°/1.2
 General/CARD
 HI L 5.90 - 3.80
 AO 100%
 Gn 5
 C7/M9
 P3/E2
 SRI II.1



27Hz/13.4cm
 70°/1.2
 General/CARD
 HI L 5.90 - 3.80
 AO 100%
 Gn 5
 C7/M9
 P3/E2
 SRI II.1
 AO 100%
 Gn -2.4
 Freq mid
 Qual norm
 WMF mid2
 PRF 3.2kHz





Aakash HospitalTM

Care with concern

(A unit of Dr. Gaba & Associates Medicare Pvt. Ltd.)



CIN No. U85110DL2004PTC125538

90/43, Malviya Nagar, New Delhi-110017
#+91-11-40501000 (100 Lines), 9871027922
info@aakashhospital.com, www.aakashhospital.com

NAME: SUSHMITA GUPTA

AGE: 25 Y

SEX: FEMALE

REF.BY: MEDICAL

DATE: 09.09.21

X RAY NO: 23433

CHEST (PA VIEW)

The diaphragmatic domes have smooth contours, a normal arched shape and occupy a normal position.

The costophrenic angles are clear.

Both lungs are normally aerated and are applied to the chest wall on all sides.

The mediastinum is centered and of normal width.

The cardiac and vascular shadows show a normal configuration.

The thoracic skeleton is symmetrically shaped and the spine is unremarkable.

The soft tissue envelope of chest shows no abnormalities.

IMP: NORMAL STUDY


DR.R.DUGGAL
MD(RADIOLOGY)
DMC-2595

AREA OF EXPERTISE

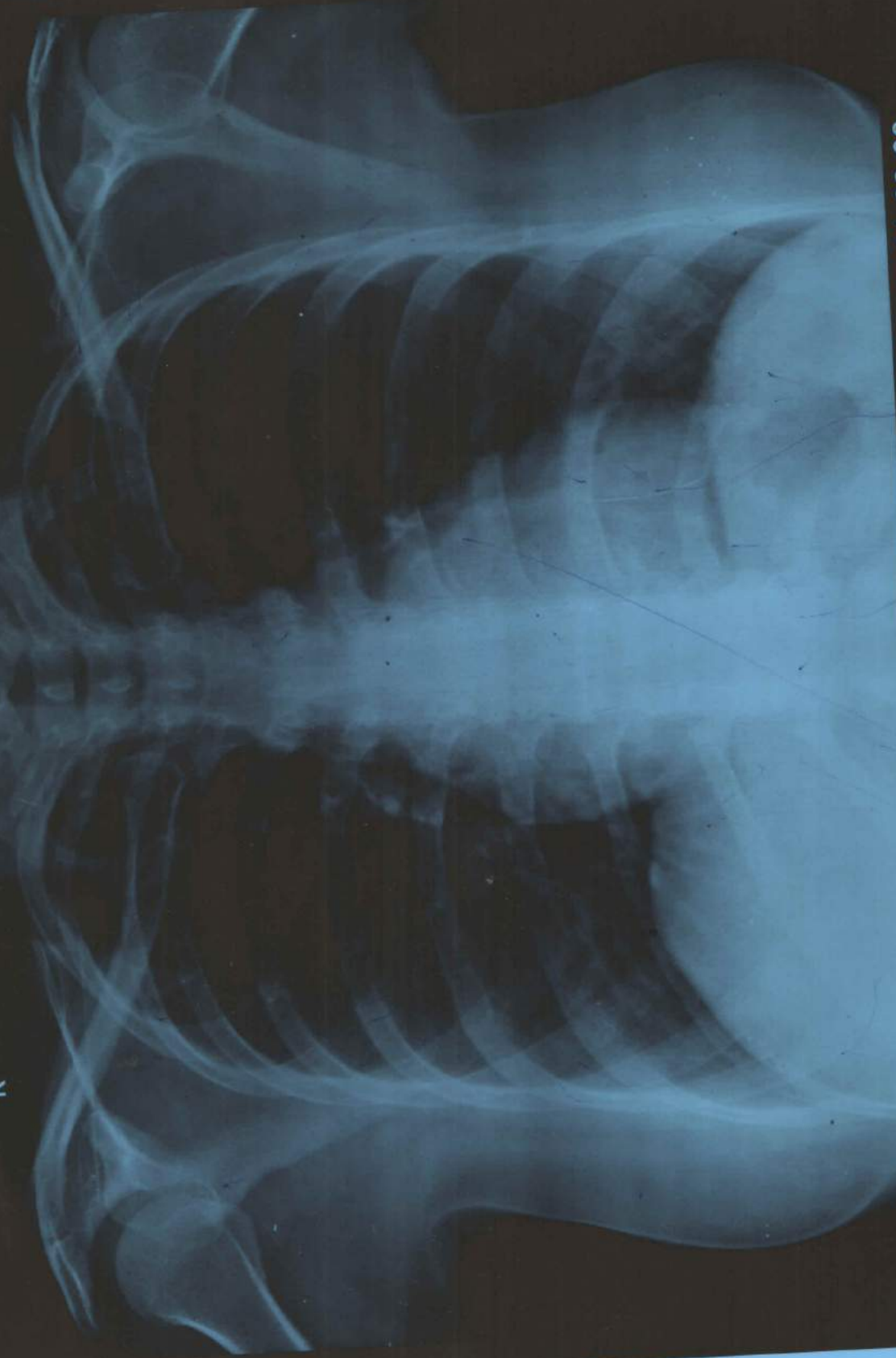
- Interventions (Vascular & Nonvascular)
- FNAC

- Biopsy
- Drainages
- Doppler Scans

- 3D & 4D Scans
- Varicose Vein Laser Treatment



R



SUSHMITA GUPTA 25YRS AKH 23433 F CHEST PA 2021-09-09
AAKASH HOSPITAL 90/43, MALVIYA NAGAR, PH-40501000



90/43, Malviya Nagar, New Delhi-110017
 #011 40501000 (100 Lines), 9871027922
 info@aakashhospital.com, www.aakashhospital.com

Name	Mrs. SUSHITA GUPTA	Srl No.	54	Sample Coll.	09/09/202123:33:34
Ref. By	SELF	Age	26 Yrs. Female	Report printing	12/09/202116:54:35
UHID	01	Dep.	OPD	Patient Id	2109090054

Test Name	Result	Unit	Normal Value
<u>COMPLETE HAEMOGRAM</u>			
HAEMOGLOBIN (Hb)	12.6	gm/dl	11.5 - 16.5
TOTAL LEUCOCYTE COUNT (TLC)	6,000	/cumm	4000 - 11000
DIFFERENTIAL LEUCOCYTE COUNT (DLC)			
NEUTROPHIL	50	%	40 - 75
LYMPHOCYTE	45	%	20 - 45
EOSINOPHIL	02	%	01 - 06
MONOCYTE	03	%	02 - 10
BASOPHIL	00	%	0.0 - 1.0
ESR (WESTEGREN's METHOD)	10	mm/1st hr.	0 - 20
R B C COUNT	4.11	Millions/cmm	3.8 - 4.8
P.C.V / HAEMATOCRIT	37.6	%	35 - 45
M C V	91.5	fl.	80 - 100
M C H	30.5	Picogram	27.0 - 31.0
M C H C	33.4	gm/dl	33 - 37
PLATELET COUNT	2.46	Lakh/cmm	1.50 - 4.00
RDW	12.3	FL	11.6 - 14.0

**** End Of Report ****

Page 1

Dr. MEENA METRE
 MBBS, MD
 CONSULTANT PATHOLOGIST



ISO 9001:2008 CERTIFIED



90/43, Malviya Nagar, New Delhi-110017
 #011 40501000 (100 Lines), 9871027922
 info@akashhospital.com, www.aakashhospital.com

Name	Mrs. SUSHITA GUPTA	Srl No.	54	Sample Coll.	09/09/202123:33:34
Ref. By	SELF	Age	26 Yrs. Female	Report printing	12/09/202116:54:38
UHID	01	Dep.	OPD	Patient Id	2109090054

Test Name	Result	Unit	Normal Value
-----------	--------	------	--------------

HAEMATOLOGY

BLOOD GROUP ABO	"B"		
RH TYPING	POSITIVE		
<u>LIVER FUNCTION TEST (LFT)</u>			
BILIRUBIN TOTAL Diazo Method	0.2	mg/dl	0 - 1.0
CONJUGATED (D. Bilirubin) Diazo Method	0.1	mg/dl	0.00 - 0.25
UNCONJUGATED (I.D. Bilirubin)	0.1	mg/dl	0.00 - 0.70
TOTAL PROTEIN Biuret Method	7.1	gm/dl	6.6 - 8.3
ALBUMIN BCG Method	4.1	gm/dl	3.4 - 4.8
GLOBULIN	3.0	gm/dl	2.3 - 3.5
A/G RATIO	1.3		
SGOT IFCC Method	18	IU/L	0 - 32
SGPT IFCC Method	18	IU/L	0.0 - 33.0
ALKALINE PHOSPHATASE IFCC Method	70	U/L	35.0 - 104.0
GAMMA GT Glupa C Method	19	IU/L	6.0 - 42.0
LFT INTERPRET			



90/43, Malviya Nagar, New Delhi-110017
 #011 40501000 (100 Lines), 9871027922
 info@aakashhospital.com, www.aakashhospital.com

Name	Mrs. SUSHITA GUPTA	Srl No. 54	Sample Coll. 09/09/202123:33:34
Ref. By	SELF	Age 26 Yrs. Female	Report printing 12/09/202116:54:40
UHID	01	Dep. OPD	Patient Id 2109090054

Test Name	Result	Unit	Normal Value
<u>KIDNEY FUNCTION TEST (RFT)</u>			
BLOOD UREA Urease GLDH Method	23.3	mg /dl	15.0 - 45.0
SERUM CREATININE ENZYMATIC Method	0.6	mg%	0.5 - 1.4
SERUM URIC ACID Uricase-POD Method	4.1	mg%	2.4 - 5.7
BLOOD UREA NITROGEN (BUN)	10.8	mg%	6.0 - 20.0
SODIUM	140	mmol/L	136.0 - 149.0
POTASSIUM	4.4	mmol/L	3.5 - 5.5
CHLORIDE	108	mmol/L	98.0 - 109.0
<u>LIPID PROFILE</u>			
TRIGLYCERIDES GPO-Method	52	mg/dL	40.0 - 165.0
TOTAL CHOLESTEROL	152	mg/dL	123.0 - 199.0
H D L CHOLESTEROL DIRECT	72.2	mg/dL	40.0 - 79.4
V L D L	10.4	mg/dL	4.7 - 22.1
L D L CHOLESTEROL CALCULATED	69.4	mg/dL	63.0 - 129.0
TOTAL CHOLESTEROL/HDL RATIO	2.10		0.0 - 4.97
LDL / HDL CHOLESTEROL RATIO	0.96		0.00 - 3.55

INTERPRETATION

TRIGLYCERIDE:- Level > 250mg/dL is associated with an approximately 2-fold greater risk of coronary vascular disease. Elevation of triglycerides can be seen with obesity, medication, fast less than 12 hrs., alcohol intake, diabetes melitus, and pancreatitis.



90/43, Malviya Nagar, New Delhi-110017
 #011 40501000 (100 Lines), 9871027922
 info@aakashhospital.com, www.aakashhospital.com

Name	Mrs. SUSHITA GUPTA	Srl No.	54	Sample Coll.	09/09/202123:33:34
Ref. By	SELF	Age	26 Yrs. Female	Report printing	12/09/202116:54:43
UHID	01	Dep.	OPD	Patient Id	2109090054

Test Name	Result	Unit	Normal Value
-----------	--------	------	--------------

CHOLESTEROL:- Its fractions and triglycerides are the important plasma lipids in defining cardiovascular risk factors and in the management of cardiovascular disease. Highest acceptable and optimum values of cholesterol values of cholesterol vary with age. Values above 220 mg/dl are associated with increased risk of CHD regardless of HDL & LDL values.

HDL-CHOLESTEROL:- Level <35 mg/dL is associated with an increased risk of coronary vascular disease even in the face of desirable levels of cholesterol and LDL - cholesterol.

LDL - CHOLESTEROL & TOTAL CHOLESTEROL:- Levels can be strikingly altered by thyroid, renal and liver disease as well as hereditary factors. Based on total cholesterol, LDL- cholesterol, and total cholesterol/HDL - cholesterol ratio, patients may be divided into the three risk categories :-

	<u>CHOLESTEROL</u>	<u>LDL-CHOLESTEROL</u>	<u>CHO/HDL RATIO</u>
Acceptable/Low Risk	: < 200 mg/dL	: <130 mg/dL	: < 4.5
Borderline High Risk	: 200-239 mg/dL	: 130-159 mg/dl	: 4.5 - 6.0
High Risk	: > 240 mg /dL	: > 160 mg/dL	: > 6.0

APO A1 & APO B:- Recent studies have shown that Apolipoproteins A1 & B might be the best indicators of Coronary Artery Disease risk in an individual. Patients who have normal lipid profile may have abnormal Apo A1 & Apo B values. Ratio of Apo B : Apo A1 is >1 in cases of increased CHD risk.

**** End Of Report ****

Page 4

Dr. MEENA METRE
 MBBS, MD
 CONSULTANT PATHOLOGIST



90/43, Malviya Nagar, New Delhi-110017
 #011 40501000 (100 Lines), 9871027922
 info@akashhospital.com, www.aakashhospital.com

Name	Mrs. SUSHITA GUPTA	Srl No.	54	Sample Coll.	09/09/202123:33:34
Ref. By	SELF	Age	26 Yrs. Female	Report printing	12/09/202116:54:43
UHID	01	Dep.	OPD	Patient Id	2109090054

Test Name	Result	Unit	Normal Value
-----------	--------	------	--------------

BIOCHEMISTRY

BLOOD SUGAR FASTING GOD-POD Method	93	mg/dl	70 - 110
BLOOD SUGAR PP GOD-POD Method	98	mg/dl	80 - 140
URINE SUGAR FASTING	NIL		NIL

STOOL EXAMINATION

STOOL ROUTINE & MICROSCOPY

PHYSICAL EXAMINATION

COLOUR/ APPEARANCE	BROWNISH
CONSISTENCY	SEMI-FORMED
PUS	NIL
MUCUS	NIL
BLOOD	NIL
CHEMICAL REACTION	
REACTION	6.0
MICROSCOPY EXAMINATION	
PUS CELLS	2-4/HPF
EPITHELIAL CELLS /HPF	1-2
RBC'S	NIL



90/43, Malviya Nagar, New Delhi-110017
 #011 40501000 (100 Lines), 9871027922
 info@akashhospital.com, www.aakashhospital.com

Name	Mrs. SUSHITA GUPTA	Srl No.	54	Sample Coll.	09/09/202123:33:34
Ref. By	SELF	Age	26 Yrs. Female	Report printing	12/09/202116:54:44
UHID	01	Dep.	OPD	Patient Id	2109090054

OVA NIL
 CYST NIL
 VEG. MATTER ABSENT
 BACTERIA NIL
 OTHERS NIL

URINE EXAMINATION TEST

PHYSICAL EXAMINATION

QUANTITY	30	ml.	
COLOUR	PALE YELLOW		Pale yellow
TRANSPARENCY	CLEAR		
SPECIFIC GRAVITY	1.025		1.005-1.030
PH	6.0		6.0-7.5

CHEMICAL EXAMINATION

ALBUMIN	NIL		Nil
REDUCING SUGAR	NIL		Nil
KETON	NIL		
LEUCOCYTE	NIL		
NITRITES	NEGATIVE		
BLOOD	NIL		

MICROSCOPIC EXAMINATION

PUS CELLS	1-2	/HPF	0-5
RBC'S	NIL	/HPF	0-2



Aakash Hospital™

Care with concern

(A unit of Dr. Gaba & Associates Medicare Pvt. Ltd.)



90/43, Malviya Nagar, New Delhi-110017
 #011 40501000 (100 Lines), 9871027922
 info@aakashhospital.com, www.aakashhospital.com

Name Mrs. SUSHITA GUPTA
 Ref. By SELF
 UHID 01

Srl No. 54
 Age 26 Yrs. Female
 Dep. OPD

Sample Coll. 09/09/202123:33:34
 Report printing 12/09/202116:54:46
 Patient Id 2109090054

Test Name	Result	Unit	Normal Value
CASTS	NIL		Occasional
CRYSTALS	NIL		
EPITHELIAL CELLS	OCCASIONAL /HPF		0-3
BACTERIA	NIL		Nil

**** End Of Report ****

Dr. MEENA METRE
 MBBS, MD
 CONSULTANT PATHOLOGIST



Aakash Hospital™

Care with concern

(A unit of Dr. Gaba & Associates Medicare Pvt. Ltd.)



90/43, Malviya Nagar, New Delhi-110017
#011 40501000 (100 Lines), 9871027922
info@aakashhospital.com, www.aakashhospital.com

PATIENT NAME : MRS. SUSHMITA

AGE / SEX : 28 Years / F

REG No : 3429

REG.DATE/TIME : 09/09/2021

UID No : 101446013

PRINT DATE : 12/09/2021

REF. BY Dr. : SELF

AREA : SAKET



HORMONE

<u>Investigation</u>	<u>Result</u>	<u>Unit</u>	<u>Biological Reference Interval</u>
T3 SERUM (CLIA)	2.21	nmol/L	0.92 - 2.79
T4 SERUM (CLIA)	114.00	nmol/L	58.1 - 140.6
TSH SERUM(CLIA)	2.59	uIU/ml	0.35 - 5.5

REFERANCE RANGE FOR Children

1-4 days : 1.00-39.00

5 days-5 months : 1.7 - 9.1

5 months - 20 years : 0.70 - 6.40

Remarks :

(1) 4.2 to 15 μ IU/mL - Correlate clinically as physiological and other factors may falsely elevate TSH level. (2) TSH Values may be transiently altered because of non thyroidal illness. (3) Some drugs may decrease TSH values, e.g., L-dopa, Glucocorticoids. (4) Some drugs may increase TSH values, e.g., Iodine, Lithium, Amiodarone. Abbreviations.

.....END OF REPORT.....



Dr.Sherry Khanna
DNB(Pathology)
Head-Lab



Aakash Hospital™

Care with concern

(A unit of Dr. Gaba & Associates Medicare Pvt. Ltd.)



90/43, Malviya Nagar, New Delhi-110017
#011 40501000 (100 Lines), 9871027922
info@aakashhospital.com, www.aakashhospital.com

PATIENT NAME : MRS. SUSHMITA
REG No : 3429
UID No : 101446013
REF. BY Dr. : SELF

AGE / SEX : 28 Years / F
REG.DATE/TIME : 09/09/2021
PRINT DATE : 12/09/2021
AREA : SAKET



BIOCHEMISTRY

<u>Investigation</u>	<u>Result</u>	<u>Unit</u>	<u>Biological Reference Interval</u>
HbA1c WHOLE BLOOD (HPLC)	4.90	%	4.8 - 5.9

CLINICAL EVALUATION:

RECOMMENDED DCCT NGSP GUIDELINES FOR HbA1C LEVELS :

Normal 4.8 % - 5.9%
Target for diabetics : < 7 %
Therapeutic action required > 8 %

.....END OF REPORT.....



Shrey Khanna



Aakash Hospital™

Care with Concern

(A unit of Dr. Gaba & Associates Medicare Pvt. Ltd.)



90/43, Malviya Nagar, New Delhi-110017 #011 40501000 (100 Lines), 9871027922
info@aakashhospital.com, www.aakashhospital.com

Name of patient : <i>Sushmeta Gupta</i>	Age : <i>25</i>	M/F : <i>F.</i>
Address :		
Consultant : <i>Dr. Seema Gupta</i>	Speciality : <i>Ophthalmal</i>	Date : <i>9/9/21.</i>

Investigations :	Presenting Complaints:	Provisional Diagnosis																					
<p>Systemic Examination :</p> <ul style="list-style-type: none"> • Followup/Next visit • Diet / Nutrition Explained • Preventive Steps Explained • Prognosis Explained 	<p>Present History :</p> <p>Past History :</p> <p>Family History :</p> <p>H/o any Allergy :</p> <p>Vitals :</p> <p>BP :</p> <p>Pulse :</p> <p>Temp :</p> <p>Pain Scale (0-10)</p> <p>Wt/Ht (if required)</p> <p>Immunization</p>	<p>Rx for medical examination</p> <table> <tr> <td></td> <td>RE</td> <td>LE</td> </tr> <tr> <td>vision</td> <td></td> <td>6/18.</td> </tr> <tr> <td>distance</td> <td>6/60</td> <td>6/6</td> </tr> <tr> <td>agl</td> <td>6/6</td> <td></td> </tr> <tr> <td>Ref</td> <td>-2.25 Dfm -0.5 Dyl x 180°</td> <td>-1.75 Dfm -0.5 Dyl x 180°</td> </tr> <tr> <td>Near</td> <td>NB</td> <td>NB.</td> </tr> <tr> <td>color vision</td> <td>WNL</td> <td>WNL.</td> </tr> </table> <p>Signature : <i>Dr. Seema Gupta</i> Dr. Seema Gupta MBBS, DOMS Sr. Consultant Eye Surgeon Reg. No. - 45002 986203877</p>		RE	LE	vision		6/18.	distance	6/60	6/6	agl	6/6		Ref	-2.25 Dfm -0.5 Dyl x 180°	-1.75 Dfm -0.5 Dyl x 180°	Near	NB	NB.	color vision	WNL	WNL.
	RE	LE																					
vision		6/18.																					
distance	6/60	6/6																					
agl	6/6																						
Ref	-2.25 Dfm -0.5 Dyl x 180°	-1.75 Dfm -0.5 Dyl x 180°																					
Near	NB	NB.																					
color vision	WNL	WNL.																					

In case of emergency contact Duty Doctor,
Aakash Hospital Ph. : 40501000, #9818166605

If you want HOME VISIT for Doctor/Nurse/Injection/Dressing/
Blood Sample Collection , Please call : 011 40501000, 9910086605



Aakash Hospital™

Care with Concern

(A unit of Dr. Gaba & Associates Medicare Pvt. Ltd.)



90/43, Malviya Nagar, New Delhi-110017 #011 40501000 (100 Lines), 9871027922
info@aakashhospital.com, www.aakashhospital.com

Name of patient: Mrs. Sushmita		Age: 26	M/F: F.
Address:			
Consultant: Dr. Tanvi	Speciality: OBGYN.	Date: 9/9/21.	

Investigations :	Presenting Complaints:	Provisional Diagnosis
Systemic Examination :	<p>1/0 Delayed menses : Rx many years.</p> <p>Present History :</p> <p>PMc = $\frac{4-5d}{40-45d}$ No WDPV No dysmenorrhea</p>	<p>USG Pelvis</p> <p>S. TSH = 0.6#</p> <p>K/c/o Hypothyroidism on 25ug OTD.</p> <p>Adv.</p> <p>Syp 1/2 time 2tp → 2tp x 3 months</p>
	<p>Past History :</p> <p>Family History :</p> <p>Wulligainda M/P = 7/9/21.</p> <p>H/o any Allergy :</p> <p>Vitals :</p> <p>BP :</p> <p>Pulse :</p> <p>Temp :</p> <p>Pain Scale (0-10)</p> <p>Wt/Ht (if required)</p> <p>Immunization</p>	
<ul style="list-style-type: none"> Followup/Next visit Diet / Nutrition Explained Preventive Steps Explained Prognosis Explained 	Signature :	Date/Time :

Nil gynaec
intervention

- 2. Ovalife - Plus. 1 tab
od
X 2 months.

Dr. JAYVIR BABA
MBBS, DGO (Obs)
Consultant Gynaecologist
DMC No. - 11451
Aakash Hospital, Malviya Nagar



TSH test 3 months

