


Address: D/O Satyendra Kumar, Gauri Punda, Patna, Bihar, 803201

UNIQUE IDENTIFICATION AUTHORITY OF INDIA



भारत सरकार
GOVERNMENT OF INDIA


नूपूर कुमारी
 Nupoor Kumari
 जन्म का साल / Year of Birth : 1993
 इसलतरी / Female

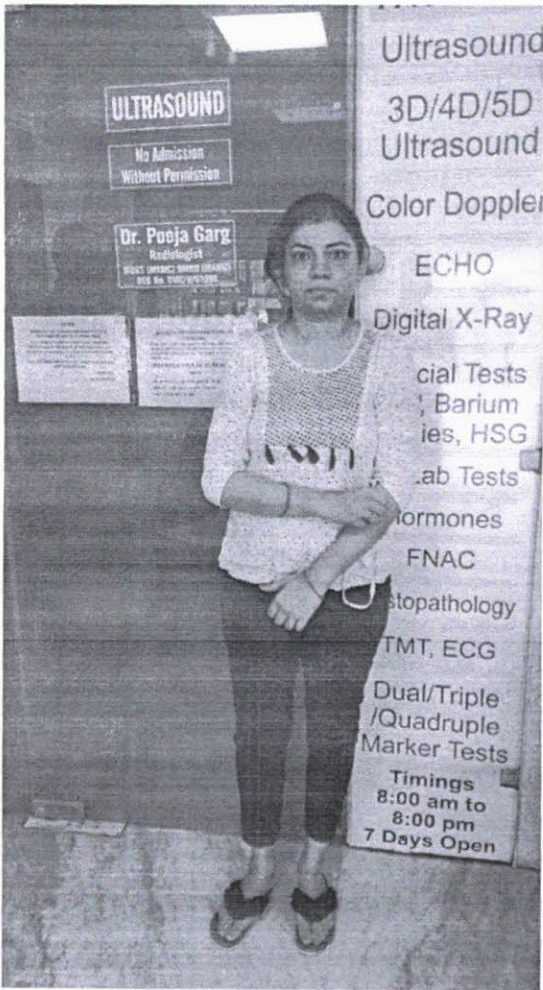
8538 3819 1354

आधार - आम आदमी का अधिकार

Nupoor Kumari

Dr. NITIN AGARWAL
 MBBS, MD
 Regn. No. DMC-R-1436
ONEPLUS ULTRASOUND LAB
 47, Harsh Vihar, Pitam Pura,
 Delhi-110034
 Ph. 011-42480101, 9599913051
 E-mail: oneplusul@gmail.com





[Handwritten signature]

Dr. NITIN AGARWAL
MBBS, MD
Regn. No. DMC-R-1436

Nayoor Keemari

ONEPLUS ULTRASOUND LAB
47, Harsh Vihar, Pitam Pura,
Delhi-110034
Ph. 011-42480101, 9599913051
E-mail: oneplusul@gmail.com

I, Nupoor Kumari, hereby declare that I do not want stool test for personal reason.

Nupoor Kumari



Dr. NITIN AGARWAL
MBBS, MD
Regn. No. DMC-R-1436

ONEPLUS ULTRASOUND LAB
47, Harsh Vihar, Pitam Pura,
Delhi-110034
Ph. 011-42480101, 9599913051
E-mail: oneplusul@gmail.com

ONEPLUS ULTRASOUND LAB

47, HARSH VIHAR, PITAMPURA, DELHI- 110034

Ms. NUPPOOR KUMARI
ID : 1887
Age : 28/F
Ref by : MEDIWHEEL
Indication 1 :
Indication 2 :
Indication 3 :
COMMENTS : Normal ECG.

ID : 1887
H/W : 159/65
Recorded : 26-2-2022 12:11
Medication 1 :
Medication 2 :
Medication 3 :

Nuppoor Kumari

BPM : 82
BP : 116/78
P Axis : 60 deg
QRS Axis : 43 deg
T Axis : 19 deg

P duration : 96 msec
PR duration : 160 msec
QRS duration : 100 msec
QT interval : 313 msec
QTc interval : 351 msec

Raw E.C.G.(Seq)

Unconfirmed Report Reviewed By:

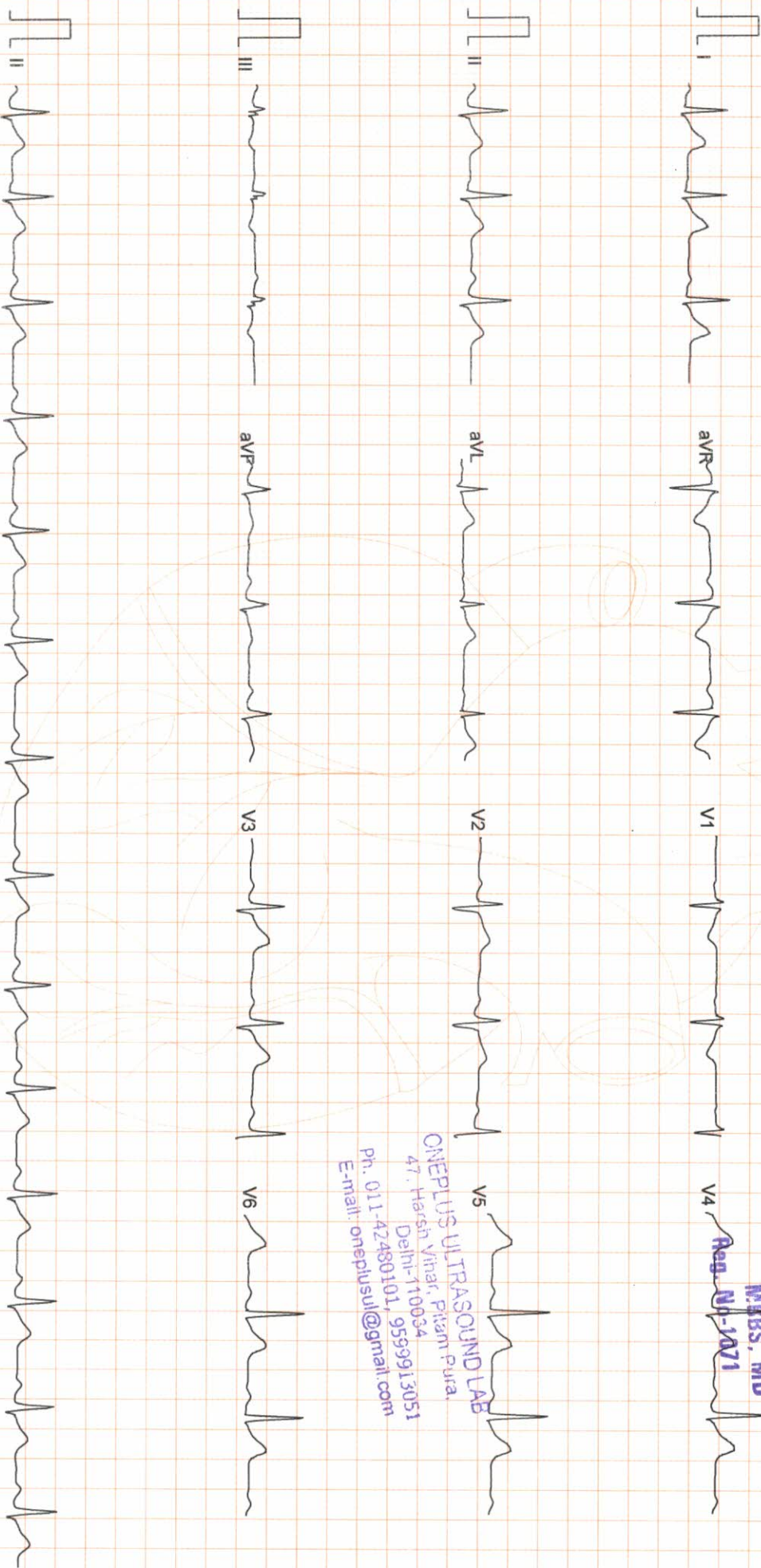
Cardiologist

Dr. P.K. GUPTA

M.B.S., MD

Reg. No-1071

ONEPLUS ULTRASOUND LAB
47, Harsh Vihar, Pitampura,
Delhi-110034
Ph. 011-42480101, 9599913051
E-mail: onepusul@gmail.com



Filtered

25mm/Sec 10mm/mV

CardiCom, INDIA

ONEPLUS ULTRASOUND LAB

47, HARSH VIHAR PITAMPURA DELHI 110034

Ms. NUPOOR KUMARI

ID : 989
 H/Wt : 159/65
 Recorded : 26-2-2022 12:13

TREADMILL TEST SUMMARY REPORT
 Protocol: BRUCE

Age : 28/F
 Ref. by : MEDIVHEEL
 Indication1 :
 Indication2 :
 Indication3 :

History:
 Medication1 :
 Medication2 :
 Medication3 :

PHASE	PHASE TIME	STAGE TIME	SPEED (Km./Hr.)	GRADE (%)	H.R. (BPM)	B.P. (mmHg)	RPP X100	II	ST LEVEL (mm) V2	V5	METS
SUPINE					85	116/78	98	1.0	0.8	1.4	
STANDING					86	116/78	99	1.0	0.8	1.4	
STAGE 1	2:59	2:59	2.70	10.00	119	126/80	149	0.9	0.5	1.7	4.80
STAGE 2	5:44	2:44	4.00	12.00	151	140/86	211	0.5	0.0	0.8	6.91
PEAK EXER	5:50	2:50			157	140/86	219	0.3	0.1	0.8	6.98
RECOVERY	2:59	2:59	0.00	0.00	92	120/78	110	0.4	0.0	0.5	

RESULTS

Exercise Duration : 5:50 Minutes
 Max Heart Rate : 157 bpm
 Max Blood Pressure : 140/86 mmHg
 Max Work Load : 6.98 METS
 Reason of Termination :

5:50 Minutes
 157 bpm 81 % of target heart rate 192 bpm
 140/86 mmHg
 6.98 METS

Handwritten: JMK not achieved, fatigue
 Negat for all other

QUEST US ULTRASOUND LAB
 47, Harsh Vihar, Pitampura,
 Delhi-110034
 Ph: 011-42480101, 9599913051
 Email: oneplusul@gmail.com

Handwritten: Nupoor Kumari

Cardiologist
Dr. P.K. GUPTA
 M.BBS, MD
 Reg. No-1071

ONEPLUS ULTRASOUND LAB

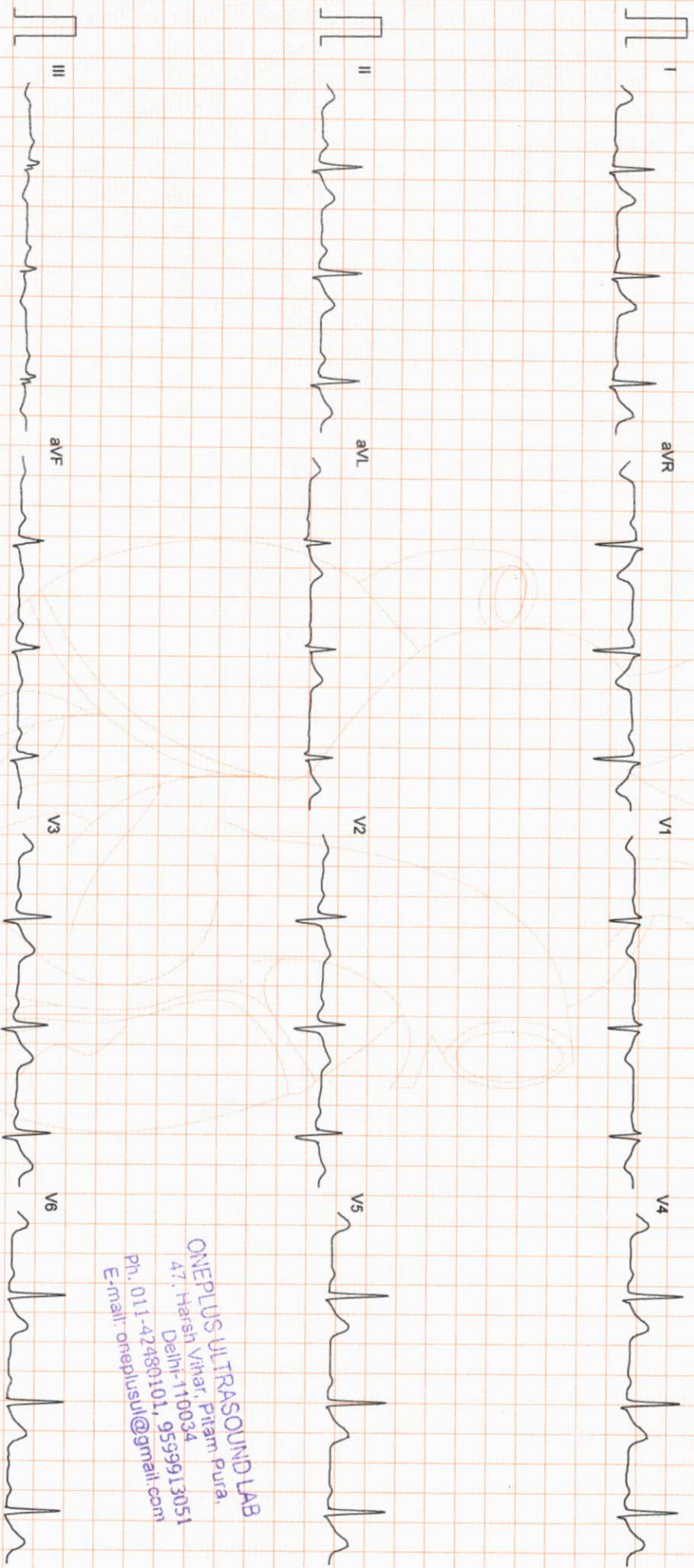
SUPINE
PRETEST

ST @ 10mm/mV
80ms PostJ

Ms. NUPPOOR KUMARI
I.D. : 989
AGE/SEX : 28/F

RATE : 85 BPM
B.P. : 116/78 mmHg

RAW E.C.G.



ONEPLUS ULTRASOUND LAB
47, Harsh Vihar, Pitam Pura,
Delhi-110034
Ph. 011-42489101, 9539913051
E-mail: oneplusul@gmail.com

Filtered

25mm/sec 10mm/mV

ART-10

CardiCom, INDIA Ph.:091-731-2620740, TeleFax:091-731-2431214

ONEPLUS ULTRASOUND LAB

STANDING
PRETEST

ST @ 10mm/mV
80ms PostU

Ms. NUPPOOR KUMARI

I.D. : 989

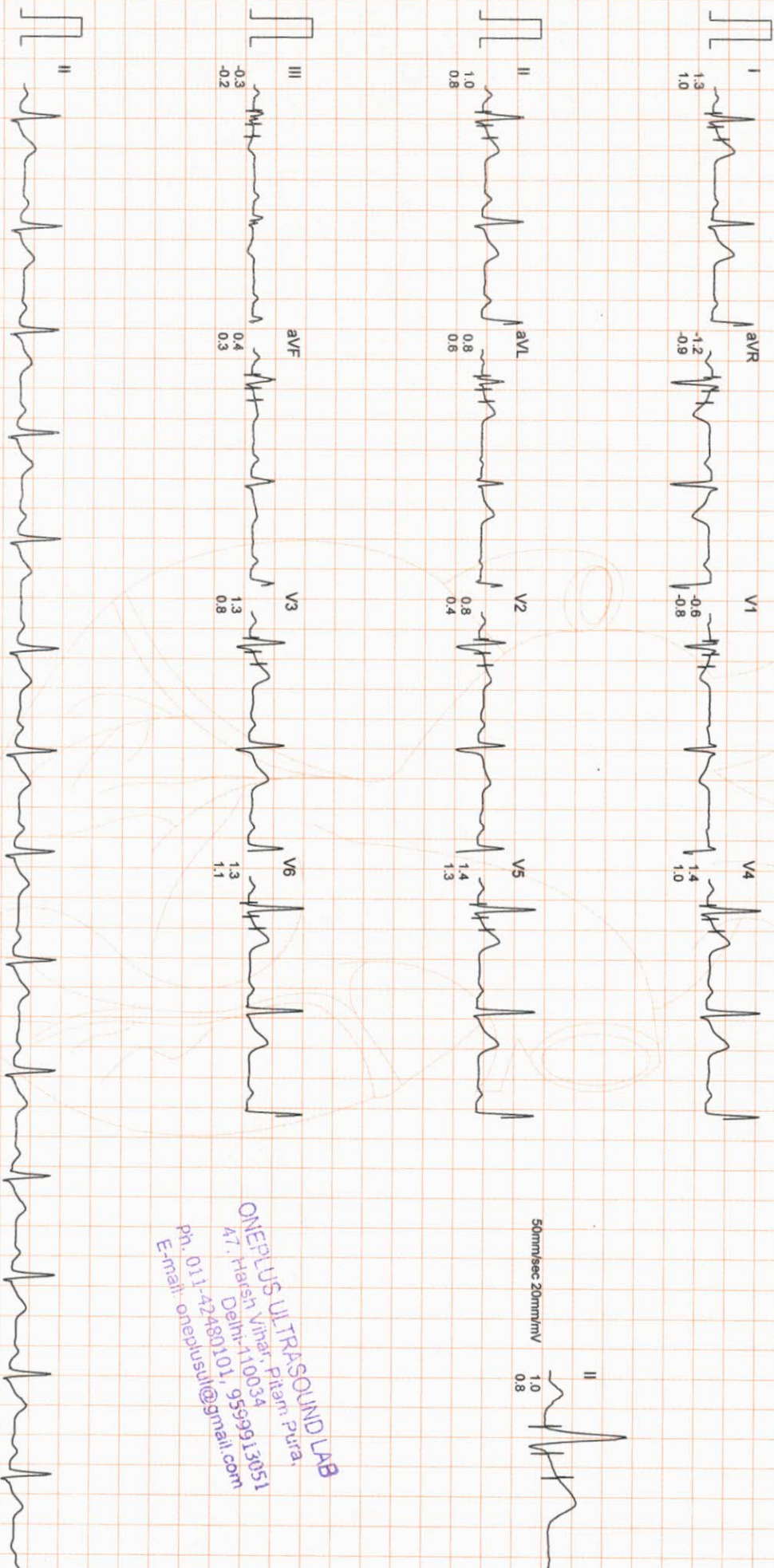
AGE/SEX : 28/F

RECORDED : 26-2-2022 12:13

RATE : 86 BPM

B.P. : 116/78 mmHg

LINKED MEDIAN



50mm/sec 20mm/mV



ONEPLUS ULTRASOUND LAB
A7, Harsh Vihar, Pitara, Pura,
Delhi-110034
9599913051
Ph. 011-42480101, 9599913051
Email: oneplusul@gmail.com

Filtered

Computer Corrected Baseline

25mm/sec 10mm/mV

ARRIVAL

CardiCom, INDIA Ph.:091-731-2620740, Telefax:091-731-2431214

ONEPLUS ULTRASOUND LAB

Ms. NUPPOOR KUMARI

I.D. : 989

AGE/SEX : 28/F

RECORDED : 26-2-2022 12:13

RATE : 119 BPM

B.P. : 126/80 mmHg

BRUCE

EXERCISE 1

PHASE TIME : 2:59

STAGE TIME : 2:59

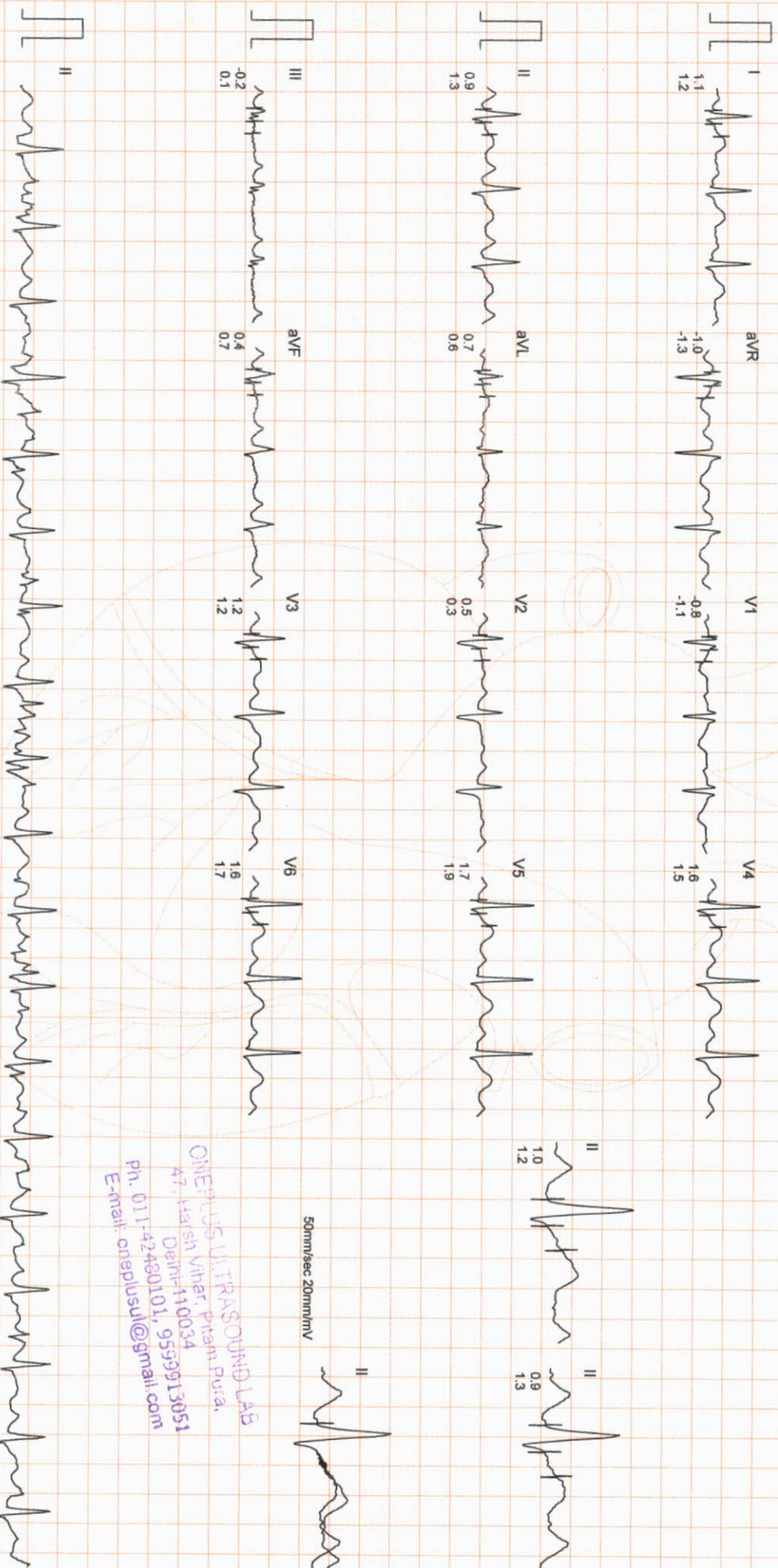
ST @ 10mm/mV

80ms PostI

SPEED : 2.7 Km./Hr.

GRADE : 10.0 %

LINKED MEDIAN



ONEPLUS ULTRASOUND LAB
47, Harsh Vihar, Preetm Pura,
Delhi-110034
Ph. 011-42480101, 9599913051
E-mail: oneplusul@gmail.com

50mm/sec 20mm/mV

Filtered

Computer Corrected Baseline

25mm/sec 10mm/mV

ASCIW

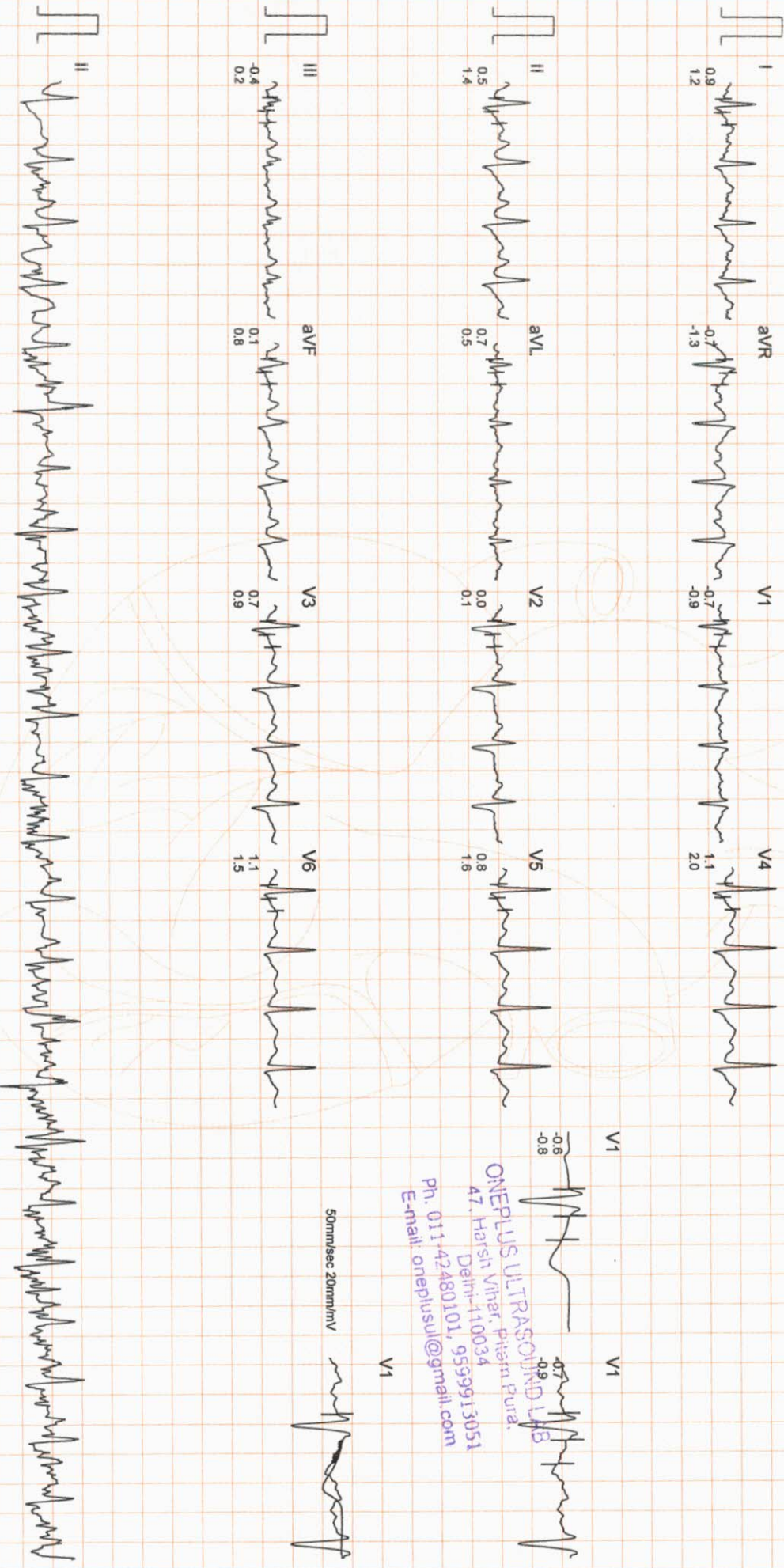
CardiCom, INDIA Ph.:091-731-2620740, TeleFax:091-731-2431214

ONEPLUS ULTRASOUND LAB

Ms. NUPPOOR KUMARI
I.D. : 989
AGE/SEX : 28/F
RECORDED : 26-2-2022 12:13

BRUCE
EXERCISE 2
PHASE TIME : 5:44
STAGE TIME : 2:44

ST @ 10mm/mV
80ms PostJ
SPEED : 4.0 Km./Hr.
GRADE : 12.0 %
LINKED MEDIAN



ONEPLUS ULTRASOUND LAB
47, Harsh Vilhar, Pitam Pura,
Delhi-110034
Ph. 011-42480101, 9599913051
E-mail: oneplusul@gmail.com

ONEPLUS ULTRASOUND LAB

Ms. NUPPOOR KUMARI

I.D. : 989

AGE/SEX : 28/F

RECORDED : 26-2-2022 12:13

RATE : 157 BPM

B.P. : 140/86 mmHg

BRUCE

PEAK EXER

PHASE TIME : 5:50

STAGE TIME : 2:50

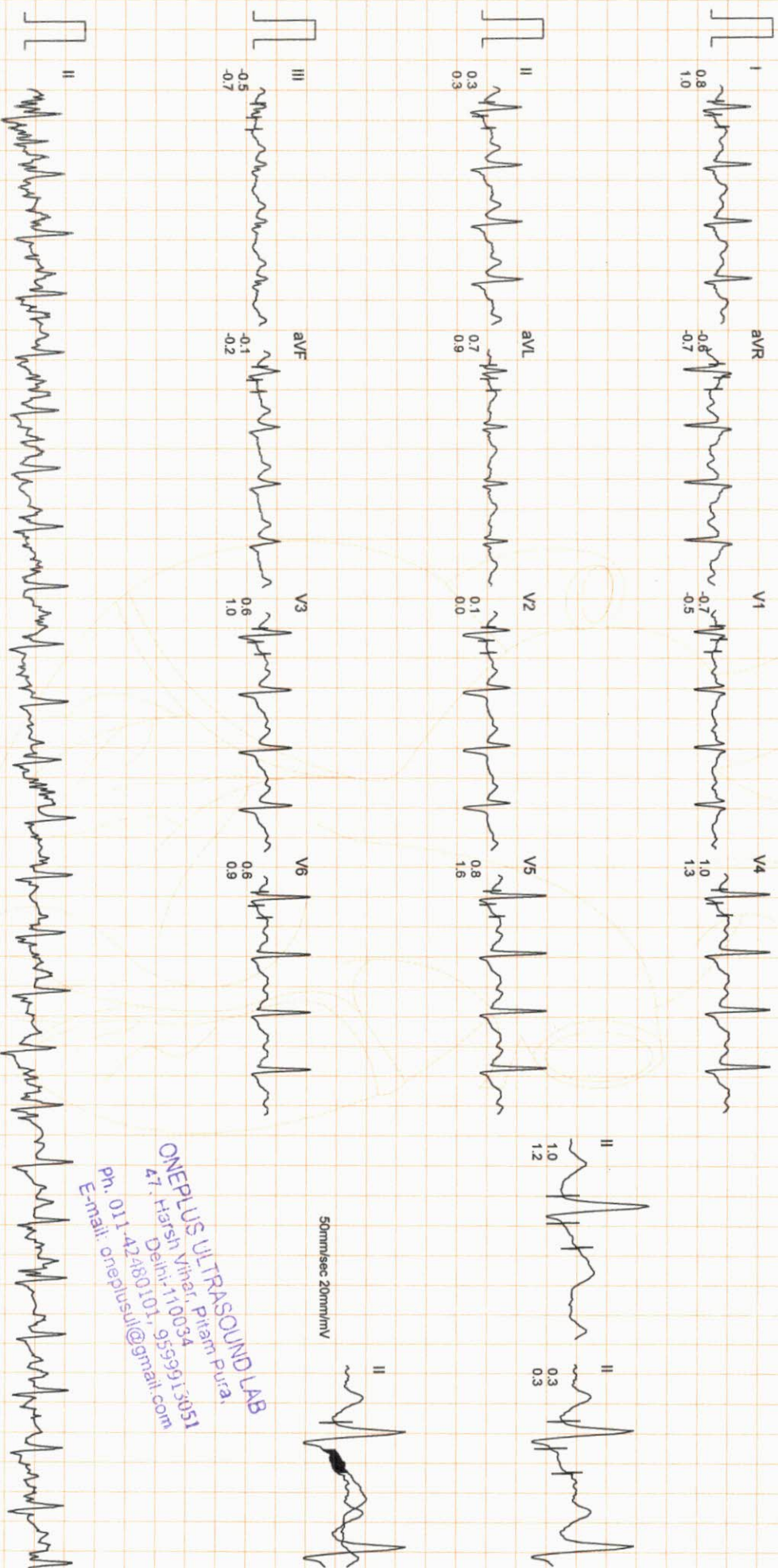
ST @ 10mm/mV

80ms PostJ

SPEED : 4.0 Km./Hr.

GRADE : 12.0 %

LINKED MEDIAN



ONEPLUS ULTRASOUND LAB
47, Harsih Nagar, Pitamber Park,
Deshprasti, 110034
955936113051
Ph. 011-47480110
E-mail: oneplusul@gnmt.com

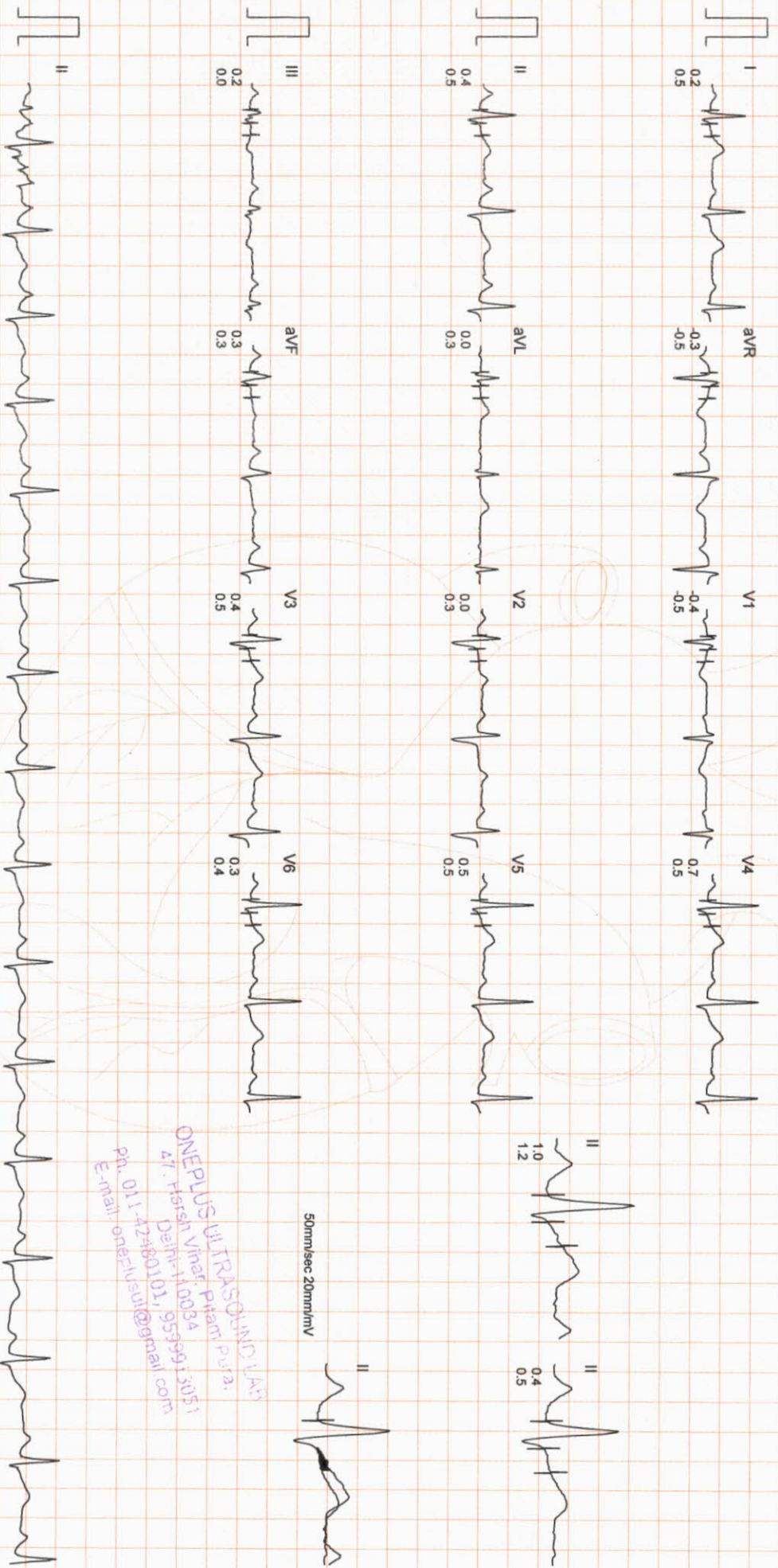
ONEPLUS ULTRASOUND LAB

Ms. NUPPOOR KUMARI
I.D. : 989
AGE/SEX : 28/F
RECORDED : 26-2-2022 12:13

RATE : 92 BPM
B.P. : 120/78 mmHg



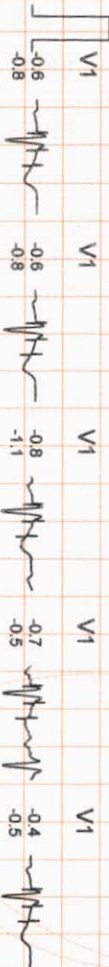



BRUCE
RECOVERY
PHASE TIME : 2:59

ST @ 10mm/mV
80ms PostJ
SPEED : 0.0 Km./Hr.
GRADE : 0.0 %
LINKED MEDIAN






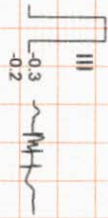
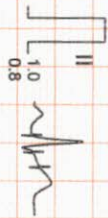

ONEPLUS ULTRASOUND LAB
47, Ferozsh Vihar, Pitam, Pura,
Delhi-110034
Ph. 011-42480101, 9539913051
E-mail: oneplusul@gmail.com

STAGE	SUPINE	STANDING	STAGE 1	PEAK EXERCISE	RECOVERY
Speed	0.0Kmph	0.0Kmph	2.59	5:50	2:59
%	0.0%	0.0%	2.7Kmph	4.0Kmph	0.0Kmph
HR	85 bpm	86 bpm	10.0%	12.0%	0.0%
B.P.	116/78	116/78	119 bpm	157 bpm	92 bpm
80ms PostJ	80ms PostJ	80ms PostJ	80ms PostJ	80ms PostJ	80ms PostJ

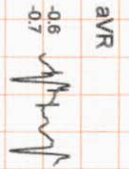






ONEPLUS ULTRASOUND LAB
 47, Harsh Vihar, Pitampura,
 Delhi-110034
 Phone: 011-42480101, 9539913051
 E-mail: onepusul@gmail.com







STANDING
0.0Kmph
0.0%
86 bpm
B.P. 118/78
80ms PostJ









PEAK EXERCISE
5:30
2:50
4.0Kmph
12.0%
157 bpm
B.P. 140/86
80ms PostJ



STANDING
0.0Kmph
0.0%
86 bpm
B.P. 118/78
80ms PostJ



PEAK EXERCISE
5:30
2:50
4.0Kmph
12.0%
157 bpm
B.P. 140/86
80ms PostJ



ONEPLUS ULTRASOUND LAB
A7: Hrish Vihar, Pitam, Pura,
Delhi-110034
Ph. 011-42480101, 9599918051
E-mail: oneplusul@gmail.com



OnePLUS
Ultrasound Lab
— QUALITY FIRST... ALWAYS! —

Dr. Nitin Agarwal
Pathologist & Director
Ex. Sr. Res. MAMC
& Lok Nayak Hospital
Ex. Chief of Lab Dr. Lal Path Labs.

Dr. Pooja (Garg) Agarwal
Radiologist & Director
MAMC & Lok Nayak Hospital

Name	: Mrs. NUPOOR KUMARI	Age/Sex	: 28 YRS/Female
Ref. By	: Dr. MEDIWHEEL	Lab No	: 012202260010
Date	: 26-Feb-2022	Patient ID	: LSHHI91728

ULTRASOUND EXAMINATION----WHOLE ABDOMEN

Liver is normal in size (15.0 cm) and outline with normal echopattern. No abscess or mass lesion seen. Hepatic veins, portal vein, IVC and aorta are normal. Intrahepatic biliary radicles are not dilated. CBD is normal in caliber.

Gall bladder is well distended with anechoic lumen. Wall thickness is normal.

Both kidneys are normal in size, shape, position, outline and echopattern.. Corticomedullary differentiation is maintained. No pelvicalyceal dilation or mass lesion is seen. **A concretion is seen at mid pole calyx of right kidney.**

Spleen is normal in size and echotexture. No mass lesion seen.

Pancreas is normal in size, outline and echotexture.


Urinary bladder is normal in shape and position. No evidence of intravesical stone or mass seen.

Uterus is normal in size (measures 7.3 x 3.6 cm), shape, **retroverted in position. Hence suboptimal transabdominal pelvic evaluation is possible. Hence TVS is advised.**

No adnexal mass lesion is seen.

No abnormal bowel wall thickening seen in right iliac fossa.
No mass or free fluid seen anywhere in abdomen.

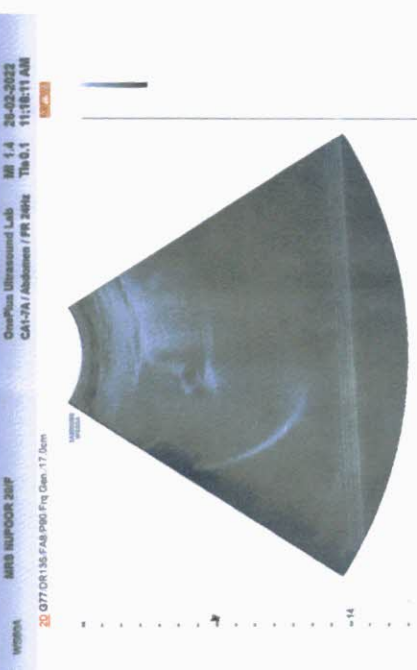
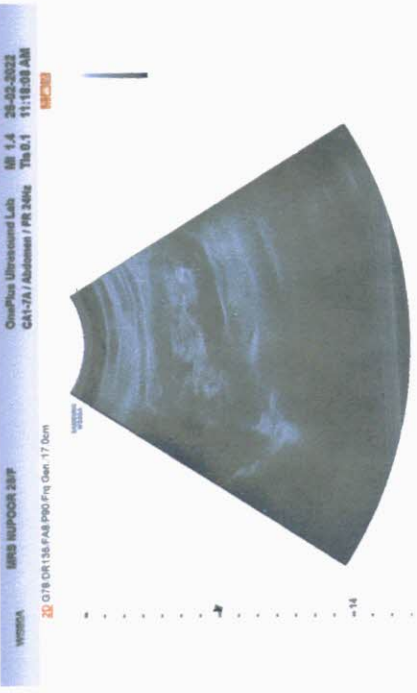
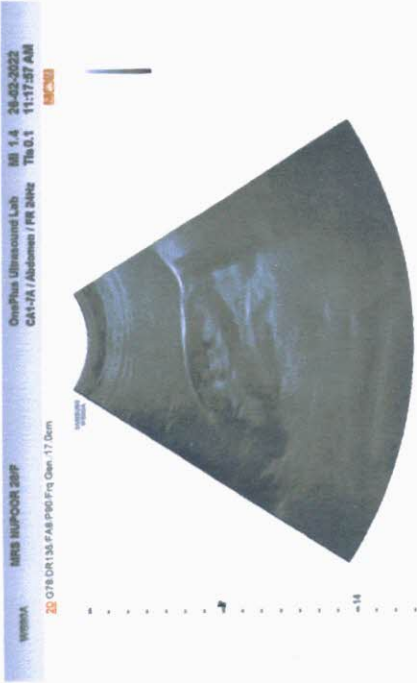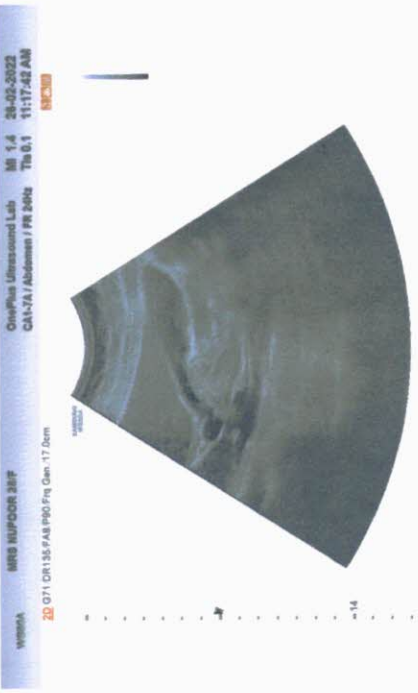
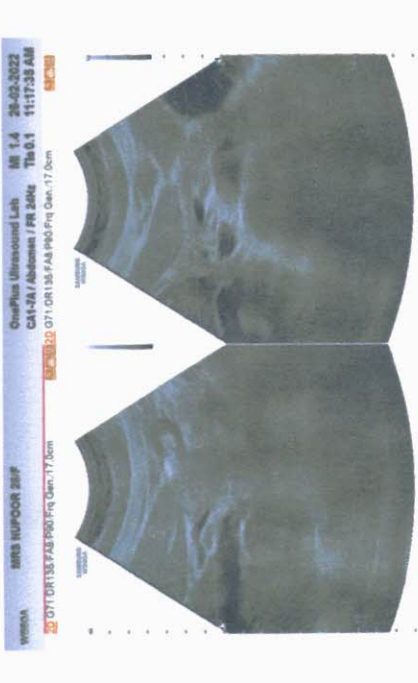
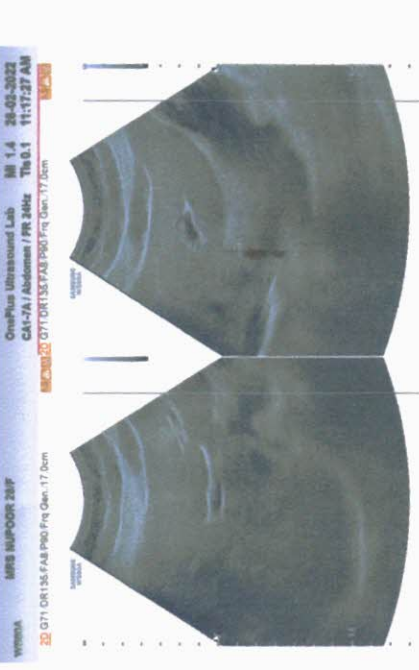

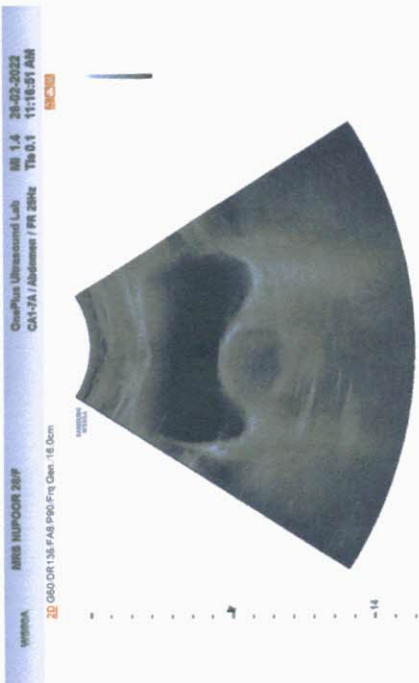
Please correlate clinically


DR. POOJA GARG
RADIOLOGIST
REG NO- DMC/R/03398

Dr. POOJA GARG
M.B.B.S., D.M.R.D
Reg No. DMC/R/03398
Radiologist

Type By : DARSHITA

47, Harsh Vihar, Pitampura, New Delhi-110034 | Ph.: 011-42480101, 9599913051
E-mail: oneplusul@gmail.com | Web.: www.oneplusul.in



D1 15.92 cm



OnePLUS
Ultrasound Lab

— QUALITY FIRST... ALWAYS! —

Dr. Nitin Agarwal

Pathologist & Director
Ex. Sr. Res. MAMC
& Lok Nayak Hospital
Ex. Chief of Lab Dr. Lal Path Labs.

Dr. Pooja (Garg) Agarwal


Radiologist & Director
MAMC & Lok Nayak Hospital

Name	: Mrs. NUPOOR KUMARI	Age/Sex	: 28 YRS/Female
Ref. By	: Dr. MEDIWHEEL	Lab No	: 012202260010
Date	: 26-Feb-2022	Patient ID	: LSHHI91728

X-ray-Chest PA view

Bony cage and soft tissues are normal.
Cardiothoracic ratio is normal.
Mediastinum is normal.
Both hila are normal.
Both costophrenic angles are clear.
Both domes of diaphragm are normal.
Lung fields are clear. No parenchymal lesion seen.

IMPRESSION: Normal Study.

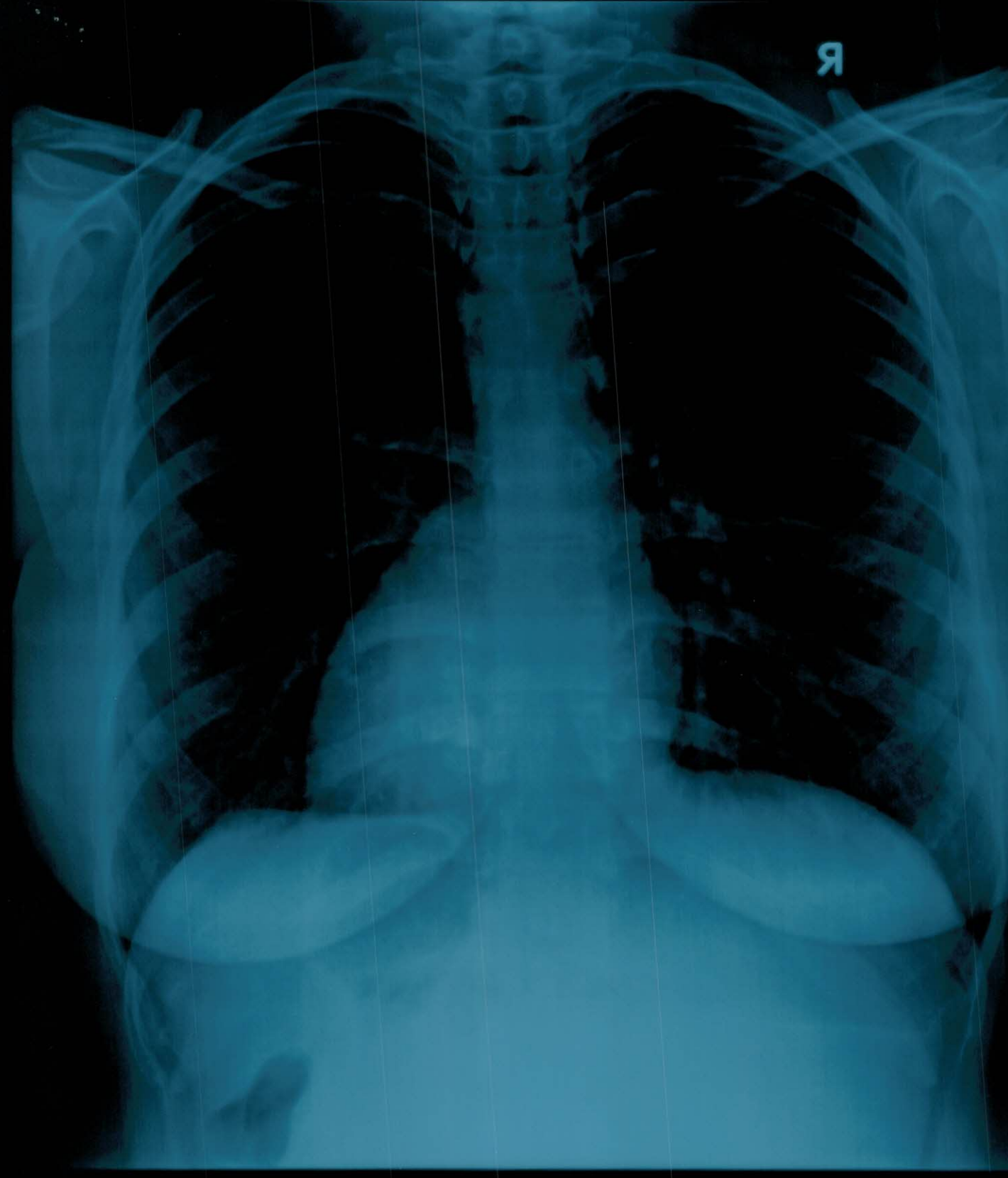

DR. POOJA GARG
RADIOLOGIST
REG NO- DMC/R/03398

Dr. POOJA GARG
M.B.B.S., D.M.R.D
Reg No. DMC/R/03398
Radiologist

Type By : pooja

47, Harsh Vihar, Pitampura, New Delhi-110034 | Ph.: 011-42480101, 9599913051
E-mail: onepusul@gmail.com | Web.: www.oneplusul.in

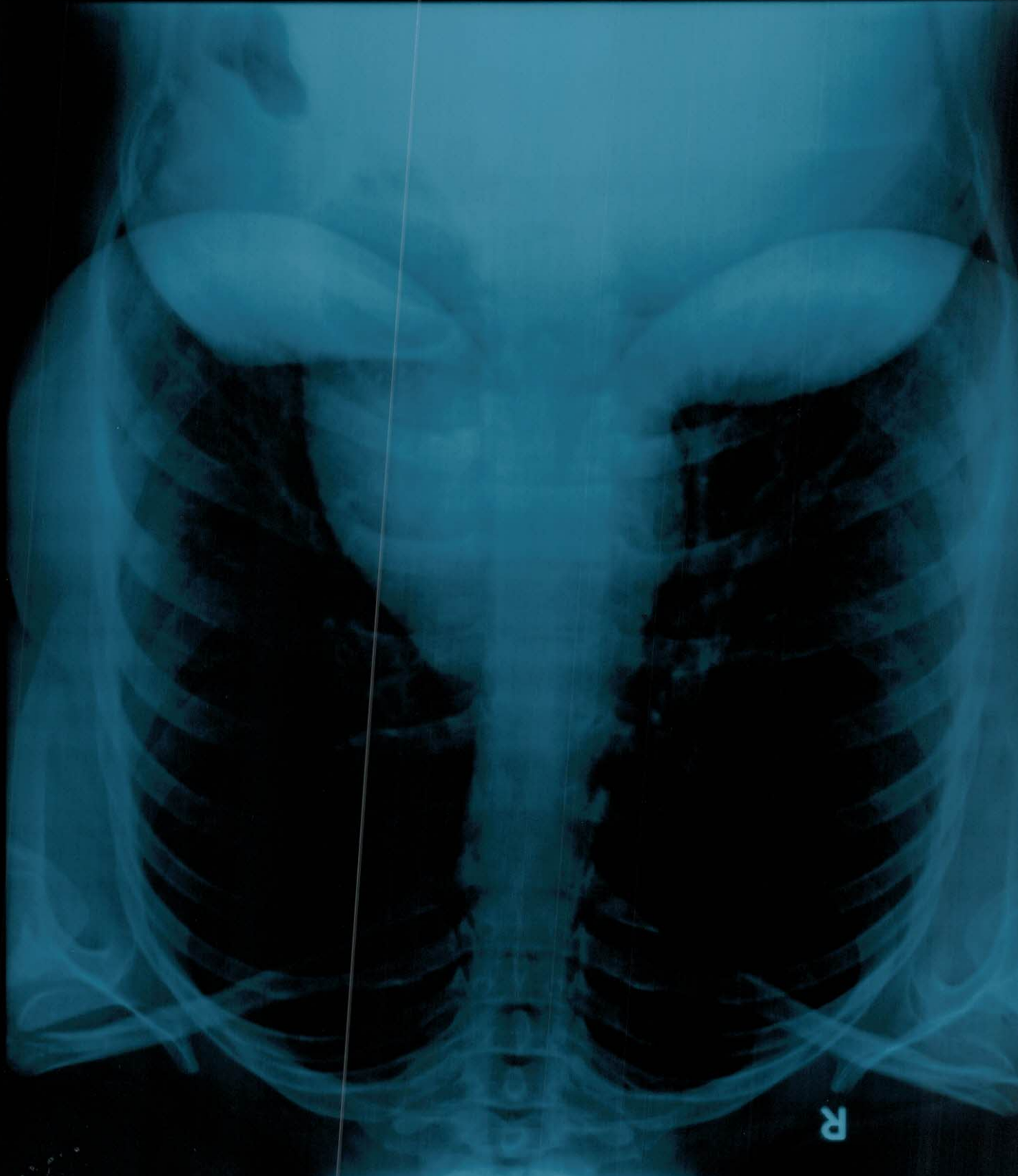
Clinical correlation is essential for final diagnosis. • If test results are unsatisfactory please contact personally or on phone. • This report is for perusal of doctors only.
• All disputes Subject to Delhi Jurisdiction only. • Not for medicolegal purposes. • All congenital anomalies in a foetus may not be diagnosed in routine obstetric ultrasound.



R

MRS NUPOR KUMARI AGE 28 YRS 26-2-2022 F CHEST PA
ONEPLUS ULTRASOUND LAB, 47-HARSH VIHAR, PITAMPURA

MRS NUPUR KUMARI AGE 28 YRS 26-2-2022 F CHEST PA
ONEPLUS ULTRASOUND LAB, 47-HARSH VIHAR, PITAMPURA



R