



# ANNUAL HEALTH CHECK UP

NAME: Shitka Moore

AGE: 35 SEX- MALE/ FEMALE

DATE: 26-12-22

UHID: \_\_\_\_\_

HEIGHT: 160 CM

BP: 120/80

WEIGHT: 58 Kg

SP O2:- 98%

CHIEF COMPLAINTS: NO

MEDICAL HISTORY: NO

SURGICAL HISTORY: NO

PERSONAL HISTORY:

MARITAL STATUS: Married/Unmarried

No of Children: 1

HABITS: SMOKING TOBACCO ALCOHOL PAAN SNUFF

DIET: VEG, NONVEG, MIXED

PHYSICAL ACTIVITY LEVEL: NO

FAMILY HISTORY: H/O HTN/ DM/CAD/ASTHMA/ CANCER/ANY OTHER



Name : Mrs. SHITAL MORE Age : 35Yr Gender : Female  
UHID : MHN1.0000131077 / NSKAH29256 W/BNo/RefNo : AHC  
Lab No : AHN1.C2200790 LRN : 688259  
Ref Doctor : SELF REFERRAL



Collected on : 26-DEC-2022 05:50:45 PM Received on : 26-DEC-2022 05:52:17 PM Reported on : 26-DEC-2022 06:11:09 PM

**MediWheel Full Body Health Checkup Female Below 40 Package**

**CERVICAL/VAGINAL SMEAR II SLIDE**

**Brief Clinical History:**

last menstrual period -17/12/2022

**SOURCE OF SPECIMEN :**

Cervical Smear-Conventional

**I. Specimen Adequacy**

Satisfactory for evaluation

**II. General Categorization :**

Negative for intraepithelial lesion or malignancy

**Other non neoplastic findings:**

Smears show intermediate squamous epithelial cells and parabasal cells. Occasional clusters of benign endocervical cells are seen. Moderate neutrophilic infiltrate is seen. There is no evidence of dysplasia or malignancy. There is no evidence of candida or trichomonas.

Negative for intraepithelial lesion or malignancy features suggest begin cellular changes of inflammation.

**Epithelial abnormalities:**

Absent

Swaminarayan Nagar, Off Mumbai-Agra Highway,  
Panchvati, Nashik - 422 003.

+91 - 253 - 2510250 / 350 / 450 / 550 / 750

apollonashik@apollohospitals.com

www.askapollo.com

**HISTOPATHOLOGY**

QFAHN/BILL/003/V1



Name : Mrs. SHITAL MORE

Age : 35Yr

Gender : Female

UHID : MHN1.0000131077 / NSKAH29256

W/BNo/RefNo : AHC

Lab No : AHN1.C2200790 LRN : 688259

Ref Doctor : SELF REFERRAL



Collected on : 26-DEC-2022 05:50:45 PM

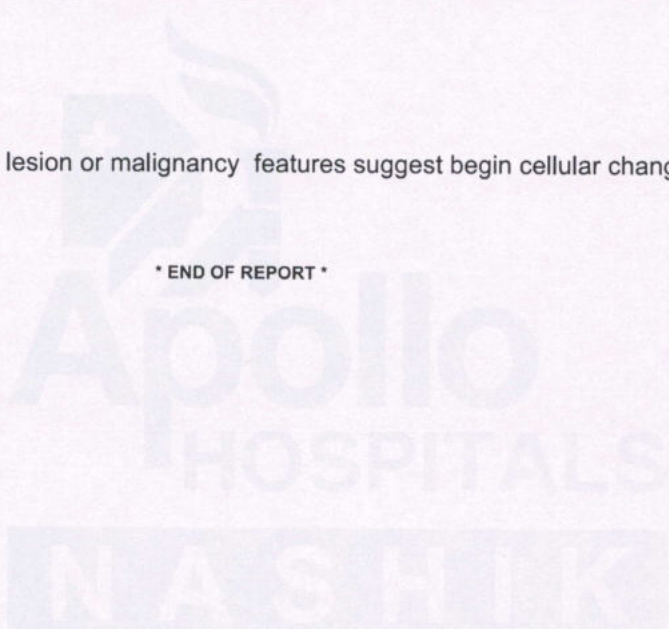
Received on : 26-DEC-2022 05:52:17 PM

Reported on : 26-DEC-2022 06:11:09 PM

**Comments :**

' Negative for intraepithelial lesion or malignancy features suggest begin cellular changes of inflammation.

\* END OF REPORT \*



Reported By:

Dr.KISHOR KHODKE

Typed By: 137375

Printed On : 11-JAN-2023 01:15:53 PM



H Swaminarayan Nagar, Off Mumbai-Agra Highway,  
Panchvati, Nashik - 422 003.

QFAHN/BILL/003/V1

+91- 253 - **BIOCHEMISTRY** / 550 / 750

apoltonashik@apoltohospitals.com

www.askapollo.com



Name : Mrs. SHITAL MORE Age : 35Yr 1Mth 5Days Gender : Female  
UHID : MHN1.0000131077 / NSKAH29256 W/BN/RefNo : AHC  
SIN \ LRN : 11565993 \ 11565999 \ 11566001 \ 688259  
Specimen : Serum  
Ref Doctor : SELF REFERRAL



lected on : 26-DEC-2022 11:32:34 AM Received on : 26-DEC-2022 11:32:46 AM Reported on : 26-DEC-2022 03:13:27 PM

**MediWheel Full Body Health Checkup Female Below 40 Package**

<u>TEST NAME</u>	<u>RESULT</u>	<u>BIOLOGICAL REFERENCE INTERVALS</u>	<u>UNITS</u>
GLUCOSE - SERUM / PLASMA (POST PRANDIAL) (GOD-PAP)	93	Normal: <140	mg/dL
GLUCOSE - SERUM / PLASMA (FASTING) (GOD-PAP)	75	Non-Diabetic: <=100 Impaired: upto125 Diabetic: >=126	mg/dL
ALT(SGPT) - SERUM / PLASMA (UV,Using Pyridoxal Phosphate:IFCC)	29 *	Healthy Adults:30 - 65	U/L
ALBUMIN - SERUM (BCG)	4.5	Healthy Adults:3.5-5.0	g/dL
GLOBULIN - SERUM:(Calculated)	3.5	Healthy Adults:1.8 - 3.6	g/dL
ALBUMIN:GLOBULIN - SERUM(RATIO) (Calculated)	1.3	Healthy Adults:1.1 - 1.8	
ALKALINE PHOSPHATASE - SERUM/PLASMA (Modified IFCC Method)	89	0 - 100	U/L
AST (SGOT) - SERUM (UV,Using Pyridoxal Phosphate:IFCC)	22	Healthy Adults:15 - 37	U/L
BILIRUBIN, TOTAL - SERUM (DCA with ATCS)	0.8	Healthy Adults:<=1.0	mg/dL
CHOLESTEROL - SERUM / PLASMA (CHOD-PAP with ATCS)	131	Desirable:<200 Borderline:200 - 240 High Risk:>=240	mg/dL
CREATININE - SERUM / PLASMA	0.7	Healthy Women: 0.6 - 1.0	mg/dL



Swaminarayan Nagar, Off Mumbai-Agra Highway,  
Panchvati, Nashik - 422 003.

QFAHN/BILL/003/V1

+91- 253 - **BIOCHEMISTRY** / 550 / 750

apoltonashik@apoltohhospitals.com

www.askapollo.com



Name : Mrs. SHITAL MORE Age : 35Yr 1Mth 5Days Gender : Female  
 UHID : MHN1.0000131077 / NSKAH29256 W/BN/RefNo : AHC  
 SIN \ LRN : 11565993 \ 11565999 \ 11566001 \ 688259  
 Specimen : Serum  
 Ref Doctor : SELF REFERRAL



Collected on : 26-DEC-2022 11:32:34 AM Received on : 26-DEC-2022 11:32:46 AM Reported on : 26-DEC-2022 03:13:27 PM

(Enzymatic Method)			
<b>GGTP: GAMMA GLUTAMYL TRANSPEPTIDASE - SERUM</b>	<b>12</b>	0 - 50	U/L
(L-gamma-glutamyl-3-carboxy-4-nitranilide)			
<b>HDL CHOLESTEROL - SERUM / PLASMA</b>	<b>56</b>	Low: <40	mg/dL
(Immuno-inhibition)		High: >=60	
<b>TOTAL CHOLESTEROL/HDL CHOLESTEROL RATIO(Calculated)</b>	<b>2.3</b>	Desirable :< 4.5	
<b>LDL CHOLESTEROL - SERUM / PLASMA (DIRECT LDL)</b>	<b>145</b>		mg/dL
(Enzymatic Method)			
<b>PROTEIN, TOTAL - SERUM / PLASMA</b>	<b>8.0</b>	Healthy Adults:6.4 - 8.2	g/dL
(Modified Biuret)			
<b>TOTAL T3: TRI IODOTHYRONINE - SERUM</b>	<b>154</b>	Healthy Adults: 69 - 215	ng/dL
(Chemiluminescence)		Pregnant Women: 1st Trimester:121-308 2nd & 3rd Trimesters:152-362	
<b>TOTAL T4: THYROXINE - SERUM</b>	<b>8.2</b>	Healthy Adults: 5.2 - 12.7	µg/dL
(Chemiluminescence)		Pregnancy:1stTrimester:7.8 - 16.2 2nd & 3rd Trimesters: 9.1 - 18.3	
<b>TRIGLYCERIDES - SERUM</b>	<b>70</b>	Normal: <150	mg/dL
(GPO-PAP with ATCS)		Borderline High:150-199 High: 200-499 Very High: >=500	
<b>TSH: THYROID STIMULATING HORMONE - SERUM</b>	<b>1.64</b>	Euthyroid: 0.3 - 4.5	uIU/mL
(Chemiluminescence)		Hypothyroid: 7.1 - >75.0 Pregnancy(All Trimesters):0.2-3.5	



Swaminarayan Nagar, Off Mumbai-Agra Highway,  
Panchvati, Nashik - 422 003.

QFAHN/BILL/003/V1

+91- 253 - **BIOCHEMISTRY** / 550 / 750

apoltonashik@apoltohospitals.com

www.askapollo.com



Name : Mrs. SHITAL MORE Age : 35Yr 1Mth 5Days Gender : Female  
 UHID : MHN1.0000131077 / NSKAH29256 W/BN/RefNo : AHC  
 SIN \ LRN : 11565993 \ 11565999 \ 11566001 \ 688259  
 Specimen : Serum  
 Ref Doctor : SELF REFERRAL



Collected on : 26-DEC-2022 11:32:34 AM Received on : 26-DEC-2022 11:32:46 AM Reported on : 26-DEC-2022 03:13:27 PM

UREA - SERUM / PLASMA (Enzymatic,Urease-GLDH)	15	Healthy Adults:15 - 38	mg/dL
UREA NITROGEN SERUM/PLASMA:(Calculated)	7	Healthy Adults:7 - 18	mg/dL
URIC ACID - SERUM (Enzymatic colorimetric)	4.9	Healthy Women:2.6 - 6.0	mg/dL
BILIRUBIN CONJUGATED (DIRECT) - SERUM (DCA with ATCS)	0.3	Healthy Adults:0.0-0.3	mg/dL
BILIRUBIN UNCONJUGATED - SERUM(Calculated)	0.5	Healthy Adults:0.0 - 0.7	mg/dL

Report Status:Final

KINDLY CORRELATE RESULTS WITH CLINICAL FINDINGS.

**Apollo**  
HOSPITALS  
\* END OF REPORT \*  
**NASHIK**

CHECKED BY 724600  
724600

*Jinal*

Printed On : 26-DEC-2022 05:40:56 PM

Dr.Minal Desale



H Swaminarayan Nagar, Off Mumbai-Agra Highway,  
Panchvati, Nashik - 422 003.

QFAHN/BILL/003/V1

+91- 253 - **BIOCHEMISTRY** 550 / 750

apollonashik@apollohospitals.com

www.askapollo.com



Name : Mrs. SHITAL MORE Age : 35Yr 1Mth 5Days Gender : Female  
 UHID : MHN1.0000131077 / NSKAH29256 W/BN/RefNo : AHC  
 SIN \ LRN : 11565994 \ 688259  
 Specimen : Whole blood  
 Ref Doctor : SELF REFERRAL



Collected on : 26-DEC-2022 11:32:34 AM Received on : 26-DEC-2022 11:32:46 AM Reported on : 26-DEC-2022 03:13:21 PM

MediWheel Full Body Health Checkup Female Below 40 Package

TEST NAME	RESULT	BIOLOGICAL REFERENCE INTERVALS	UNITS
GLYCOSYLATED HEMOGLOBIN (HbA1C) - WHOLE BLOOD (Immunoturbidimetric assay)	4.9	HbA1C Degree of Control <6.0 Non-diabetic level <7.0 Goal* >8.0 Action Suggested**	%
Mean Plasma Glucose (MPG) Estimate:	97.1400		mg/dL

\*Some danger of hypoglycemic reaction in Type I diabetics. Some glucose intolerant individuals and "sub-clinical" diabetics may show(elevated) HbA1c in this area.

\*\*High risk of developing long term complications. "ActionSuggested" depends on individual patient circumstances.

Report Status:Final

KINDLY CORRELATE RESULTS WITH CLINICAL FINDINGS.

\* END OF REPORT \*

CHECKED BY 724600  
724600

*Jinal*

Printed On : 26-DEC-2022 05:41:16 PM

Dr.Minal Desale



Swaminarayan Nagar, Off Mumbai-Agra Highway,  
Panchvati, Nashik - 422 003.

QFAHN/BILL/003/V1

+91-253-2510250/250/550/550/750

apollonashik@apollohospitals.com

www.askapollo.com



Name : Mrs. SHITAL MORE Age : 35Yr 1Mth 5Days Gender : Female  
 UHID : MHN1.0000131077 / NSKAH29256 W/BN0/RefNo : AHC  
 SIN \LRN : 11565998 \ 11566000 \ 688259  
 Specimen : Urine  
 Ref Doctor : SELF REFERRAL



Collected on : 26-DEC-2022 10:39:54 AM Received on : 26-DEC-2022 10:46:04 AM Reported on : 26-DEC-2022 12:08:22 PM

MediWheel Full Body Health Checkup Female Below 40 Package

**TEST NAME** **RESULT** **BIOLOGICAL REFERENCE INTERVALS** **UNITS**

URINE ROUTINE (CUE)

Specific Gravity	1.025	1.016 - 1.026	
Color,:	PALE YELLOW		
Transparency:	Clear		
Reaction:	Acidic		
Protein :	Negative		
Sugar:	Negative		
pH	5.0	4.6 - 8	
Blood:	Negative		
Ketone	Negative		
Bile Pigments:	Negative		
Bile Salts :	Negative		
Urobilinogen	Normal		
Nitrite	Negative		

DEPOSITS:

RBC	00	0 - 2	/hpf
WBC/Pus Cells	0-2		/hpf
/Sqc(Transitional/Squamous epithelial cells)	2-3		/hpf

C B C WITH ESR (AUTOMATION + STANDARD METHOD)

Hemoglobin	9.4 *	11.0 - 16.0	g/dl
Haematocrit	32.9 *	34.0 - 48.0	%
RBC COUNT	4.55	3.7 - 5.6	Million/ul
MCV	72.3 *	75.0 - 95.0	fl





H Swaminarayan Nagar, Off Mumbai-Agra Highway,  
Panchvati, Nashik - 422 003.

QFAHN/BILL/003/V1

+91- 253 - 2511011 / 2511050 / 2511051 / 2511052 / 750

apollonashik@apollohospitals.com

www.askapollo.com



**Apollo**  
HOSPITALS  
NASHIK

Name : **Mrs. SHITAL MORE** Age : **35Yr 1Mth 5Days** Gender : **Female**  
 UHID : **MHN1.0000131077 / NSKAH29256** W/BNo/RefNo : **AHC**  
 SIN \LRN : **11565998 \ 11566000 \ 688259**  
 Specimen : **Urine**  
 Ref Doctor : **SELF REFERRAL**



Collected on : 26-DEC-2022 10:39:54 AM Received on : 26-DEC-2022 10:46:04 AM Reported on : 26-DEC-2022 12:08:22 PM

MCH	20.6 *	26.0 - 32.0	pg
MCHC	28.5 *	31.0 - 36.0	g/dl
RDW	16.9 *	11 - 16	%
Platelet Count(Optical/Impedance)	291	140 - 440	10 <sup>3</sup> /mm <sup>3</sup>
WBC Count	6.37	4.0 - 11.0	10 <sup>9</sup> /mm <sup>3</sup>
<b>Differential Count</b>			
Neutrophils	60	40 - 75	%
Lymphocytes	30	20 - 45	%
Eosinophils	03	1 - 6	%
Monocytes	07	1 - 10	%
Basophils	00	0 - 1	%
ERYTHROCYTE SEDIMENTATION RATE (ESR)	06	0 - 20	mm/1st hr

Comments : casts:absent  
crystals:absent

Report Status:Final

KINDLY CORRELATE RESULTS WITH CLINICAL FINDINGS.

\* END OF REPORT \*

**Apollo**  
HOSPITALS  
**NASHIK**

CHECKED BY : 1168194  
724600

Dr.Minal Desale

Printed On : 26-DEC-2022 05:41:41 PM



Swaminarayan Nagar, Off Mumbai-Agra Highway,  
Panchvati, Nashik - 422 003.

QFAHN/BILL/003/V1

+91-253-2510573 / 550 / 550 / 750

apollonashik@apollohospitals.com

www.askapollo.com



**Apollo**  
HOSPITALS  
NASHIK

Name : Mrs. SHITAL MORE Age : 35Yr 1Mth 5Days Gender : Female  
UHID : MHN1.0000131077 / NSKAH29256 W/BNo/RefNo : AHC  
SIN \LRN : 11565996 \ 688259  
Specimen : Blood  
Ref Doctor : SELF REFERRAL



Collected on : 26-DEC-2022 11:32:34 AM Received on : 26-DEC-2022 11:33:17 AM Reported on : 26-DEC-2022 02:01:23 PM

**MediWheel Full Body Health Checkup Female Below 40 Package**

**TEST NAME RESULT**

**BLOOD GROUPING AND TYPING (ABO and Rh) : (Agglutination)**

Group: **A**  
Rh (D) Type: **POSITIVE**

Report Status:Final

KINDLY CORRELATE RESULTS WITH CLINICAL FINDINGS.

\* END OF REPORT \*

**Apollo**  
HOSPITALS  
NASHIK

CHECKED BY : 1161266  
724600

Dr.Minal Desale

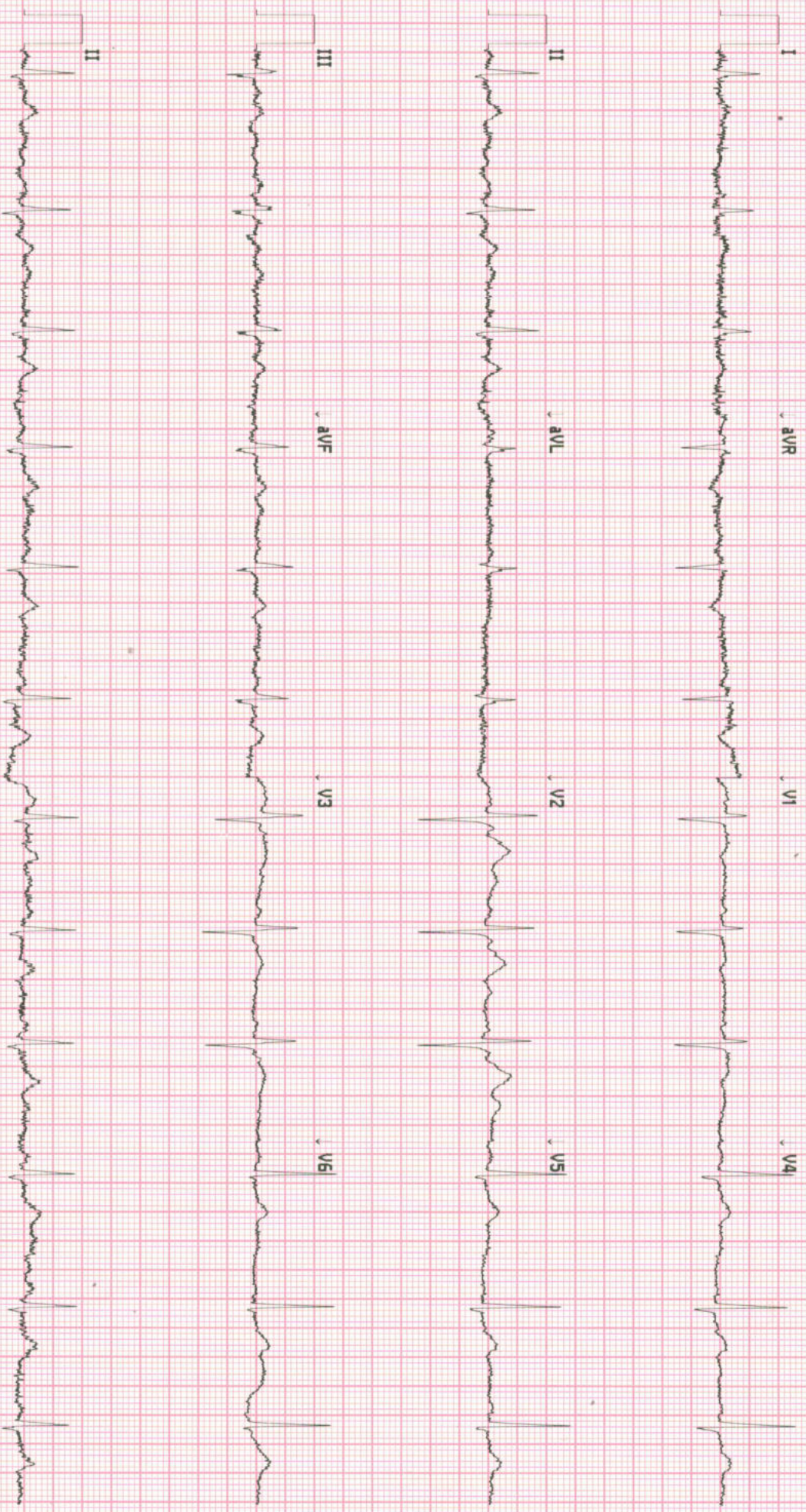
Printed On : 26-DEC-2022 05:41:58 PM

More, Shital  
ID:  
DOB:  
35yr, Female

26-Dec-2022 14:09:07

Vent rate: 71 BPM  
PR int: 129 ms  
QRS dur: 103 ms  
QT/QTc: 384/406 ms  
P-R-T axes: 43 27 60

SINUS RHYTHM  
NORMAL ECG  
UNCONFIRMED REPORT



113500188213

No Site Name

Site # 0 Cart # 2 Version 2.0.4.0 Sequence #21691 25mm/s 10mm/mV 0.05-150 Hz



Swaminarayan Nagar, Off Mumbai-Agra Highway,  
Panchvati, Nashik - 422 003.

+91- 253 - 2510250 / 350 / 450 / 550 / 750

apollonashik@apollohospitals.com

www.askapollo.com

QFAHN/BILL/003/V1



Apollo  
HOSPITALS  
NASHIK

- Mrs Prasad More.
- NO covid H/O by Pt
- Both vaccine taken by Pt.
- NO M/H History.

Date - 26/12/22

Age 35  
Male

- Calculus seen in lower anterior region.
- occlusal pit caries in 36 adn restoration.
- Mucopain gel for topical application 3-4 times  
a days

Dr. N. S.



H Swaminarayan Nagar, Off Mumbai-Agra Highway,  
Panchvati, Nashik - 422 003.

+91- 253 - 2510250 / 350 / 450 / 550 / 750

apollonashik@apollohospitals.com

www.askapollo.com

QFAHN/BILL/003/V1

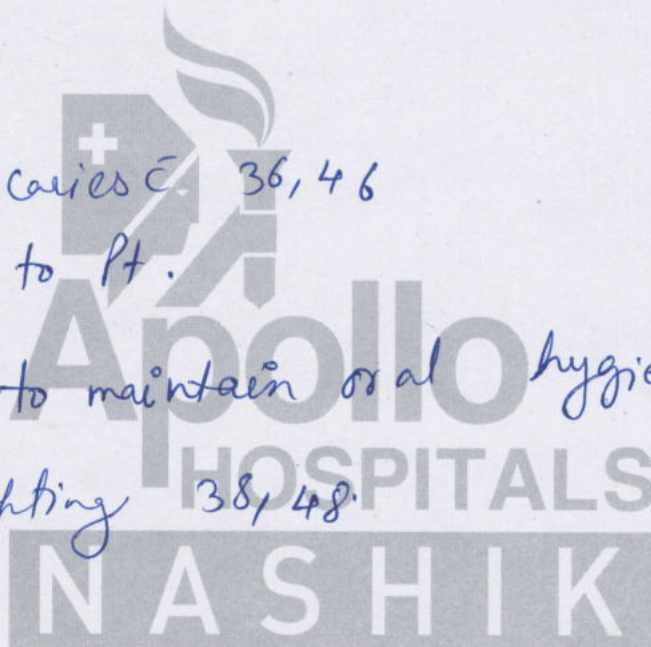


Apollo  
HOSPITALS  
NASHIK

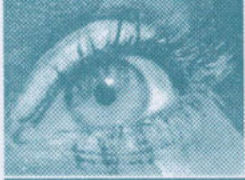- Shital More.
- NO covid H/o to Pt.
- B0th vaccine taken to Pt.
- NO Medical H/o by Pt

Date 26/12/22  
Age 35.  
female

- Buccal pit caries 36, 46
- Scaling adv to Pt.
- Pt is adv to maintain oral hygiene.
- Partial erupting 38, 48.



↓  
Priya



# OPHTHALMOLOGY



Name : Mrs. Shital More  
 Occupation : \_\_\_\_\_  
 Age : 35 Sex : Male  Female  S/M/W/D  
 Address : Nsc  
 Tel. No. \_\_\_\_\_

Date 26/11/20 UNIT \_\_\_\_\_  
 Room No. \_\_\_\_\_ Out Patient   
 Ref. Physician : \_\_\_\_\_  
 Copies to : \_\_\_\_\_

## REPORT ON OPHTHALMIC EXAMINATION

HISTORY : \_\_\_\_\_

PRESENT COMPLAINT : \_\_\_\_\_

PAST HISTORY : DM / HTN / ALLERGY

### ON EXAMINATION

RE 6/24 LE 6/24

VISION :

	RIGHT					LEFT				
	PGP	SPH	CYL	AXIS	VA	PGP	SPH	CYL	AXIS	VA
DIST		<u>1.5</u>	<u>0.75</u>	<u>30</u>			<u>2.0</u>	<u>0.5</u>	<u>140</u>	
NEAR	<u>—————</u>					<u>—————</u>				

### AR / Retinoscopy :

RIGHT			LEFT		
SPH	CYL	AXIS	SPH	CYL	AXIS
<u>1.5</u>	<u>1.0</u>	<u>33</u>	<u>2.5</u>	<u>1.5</u>	<u>130</u>

### Refraction or Acceptance :


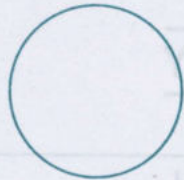
	RIGHT					LEFT				
	SPH	CYL	AXIS	VA	SPH	CYL	AXIS	VA		
DIST	<u>1.5</u>	<u>0.75</u>	<u>30</u>	<u>6/6</u>	<u>2.5</u>	<u>1.0</u>	<u>135</u>	<u>6/6</u>		
NEAR	<u>—————</u>					<u>—————</u>				

CV2

Anterior Segment :

RE

LE

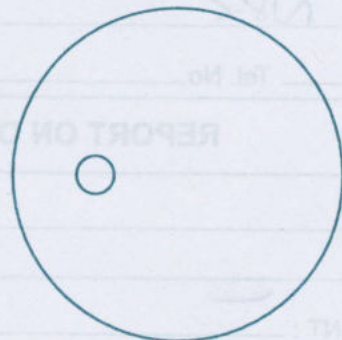
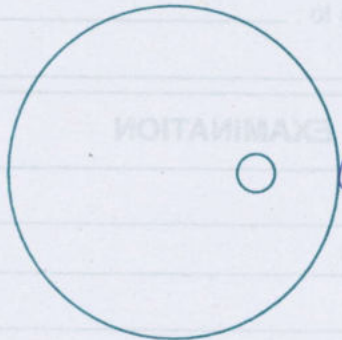


*R pupils very @  
white*

Fundus :

RE

LE



*good @*

Diagnosis :

*Myopic Atropia*

Advise / Rx:

*Tear drops*

LEFT				RIGHT			
VA	AXIS	CYL	SPH	VA	AXIS	CYL	SPH

CONSULTANT OPHTHALMOLOGIST



Swaminarayan Nagar, Off Mumbai-Agra Highway,  
Panchvati, Nashik - 422 003.

+91- 253 - 2510250 / 350 / 450 / 550 / 750

apollonashik@apollohospitals.com


www.askapollo.com

QFAHN/BILL/003/V1



**Apollo**  
HOSPITALS  
NASHIK

### MD (Radiology)

**Patient Details** : Mrs. SHITAL MORE | Female | 35Yr 1Mth 5Days  
**UHID** : MHN1.0000131077 **Patient Location:** AHC  
**Patient Identifier:** NSKAH29256   
**DRN** : 222031459 **Completed on :** 26-DEC-2022 13:03  
**Ref Doctor** : SELF REFERRAL

### ULTRASOUND - WHOLE ABDOMEN

**LIVER** : Normal in size. Echotexture is uniform and normal.  
No I.H.B.D./ focal lesions.

**PORTAL VEIN**: Normal in size.

**GALL BLADDER**: Well distended with normal walls and lumen.  
No calculi/pericholecystic fluid.

**COMMON BILE DUCT**: Normal in size.

**PANCREAS** : Visualized portion of head and body of pancreas appears normal in size and echotexture. Rest of the pancreas is obscured due to bowel gases.

**AORTA, IVC and para aortic areas** are normal.

**SPLEEN** : Normal in size and echotexture.

**KIDNEYS**: Both kidneys are normal in site, size and echotexture.

No evidence of calculi/ hydronephrosis.

Right kidney measures : 11.3 x 5.5 cm.

Left kidney measures : 11.6 x 5.4 cm.

**URINARY BLADDER**: Well distended with normal walls.

No evidence of calculi/ growth/ diverticula.

**UTERUS**: Anteverted. Normal in size and echotexture.

Uterus measures : 4.4 x 3.9 x 7.9 cm.

Combined endometrial thickness is normal and measures 7mm.





H Swaminarayan Nagar, Off Mumbai-Agra Highway,  
Panchvati, Nashik - 422 003.

+91- 253 - 2510250 / 350 / 450 / 550 / 750

apollonashik@apollohospitals.com

www.askapollo.com

QFAHN/BILL/003/V1



**Apollo**  
HOSPITALS  
NASHIK

Mrs. SHITAL MORE

MHN1.0000131077

NSKAH29256

**ULTRASOUND - WHOLE ABDOMEN**

**OVARIES:**

Right ovary measures : 2.9 x 2.4 cm.

Left ovary measures : 2.3 x 2.5 cm.

Normal in size and echotexture.

Visualized bowel loops appear grossly normal.

No evidence of any free fluid in the peritoneal cavity.

**Impression**

No significant abnormality is detected.

--- END OF THE REPORT ---

Kunal Kalyanrao Patil

Consultant - MD (Radiodiagnosis)

**Apollo**  
HOSPITALS  
NASHIK



Swaminarayan Nagar, Off Mumbai-Agra Highway,  
Panchvati, Nashik - 422 003.

+91- 253 - 2510250 / 350 / 450 / 550 / 750

apollonashik@apollohospitals.com

www.askapollo.com

QFAHN/BILL/003/V1



### MD (Radiology)

**Patient Details** : Mrs. SHITAL MORE | Female | 35Yr 1Mth 5Days

**UHID** : MHN1.0000131077

**Patient Location:** AHC

**Patient Identifier:** NSKAH29256



**DRN** : 122051329

**Completed on :** 26-DEC-2022 09:58

**Ref Doctor** : SELF REFERRAL

### X-RAY CHEST PA

Both lung fields are clear.

Both hila are normal in size and position.

Costophrenic and cardiophrenic angles are clear.

Cardiac size and contour are within normal limits.

Rib cage is normal.

Soft tissues are normal.

#### **Impression**

No significant abnormality is detected.

--- END OF THE REPORT ---

Kunal Kalyanrao Patil

Consultant - MD (Radiodiagnosis)



H Swaminarayan Nagar, Off Mumbai-Agra Highway,  
Panchvati, Nashik - 422 003.

+91- 253 - 2510250 / 350 / 450 / 550 / 750

apollonashik@apollohospitals.com

www.askapollo.com

QFAHN/BILL/003/V1



Apollo  
HOSPITALS  
NASHIK

Date- 26/12/22

Age 35

Male

- Mrs Prasad More.
- NO covid H/O by Pt
- Both vaccine taken by Pt.
- NO M/H History.

- Calculus seen in lower anterior region.
- occlusal pit carries 36 adw restoration.
- Mucobain gel for topical application 3-4 times  
a days

Dr. N. S. N. N.