

24/9/2022

clo. scanty. flow on & off one out
of 4 cycles
No other gyn complaint.

H/O hypothyroidism. — since pregnancy

OH - 1FTUSC - Twin - 4 1/2 yrs. $\left\{ \begin{array}{l} \text{♀} \\ \text{♀} \end{array} \right.$

Vitals :

Bp 100/60
wt 62 kg
HT 151.5 cm

Chief Complaints :

H/O Present Illness :

Past M/S/H - ~~none~~ Taking 75mg. Levothyroxine.
Family H/O - Mother - DM + hypothyroids.

Past History :

MH - 2-3 days. (N) to scanty flow.
25-28 days.

Investigation :

Drug Allergies : (if any)

Treatment: CMP - 8/9/2022.

GC - Fair, Afab
P I O C C

PS - slight milky white discharge
Pr - ut Av, (N) size

B/ Lp acc.

✓ pap smear





Dental

Routine dental checkup

Vitals :

Chief Complaints :

H/O Present Illness :

Past History :

Adv. Scaling & Polishing
Composite restoration $\frac{8}{8}$

Investigation :

Drug Allergies : (if any)

Treatment :

Rx

- Metroglol 0.9g/100ml gel
Apply 2-3 times a day.
Massage it for 2 mins & leave for 10 mins
- Warm Saline rinses
for 2-3 times a day



Gurgaon

Q Block South City 11, Sohna Road, Main Sector-47, Gurgaon, Haryana Ph.: 0124-49000000 Fax : 0124-2218733
E-mail : parkmedicenters@gmail.com

• West Delhi • South Delhi • Faridabad • Panipat • Karnal

the health care providers

the health care providers





DERMATOLOGY

24/9/22

Bermouat N

Vitals :

Chief Complaints :

? melasma.
+
? comedonal
acne.

Adv:--
=

H/O Present Illness :

- SUNCROSS SOFT
Sunscreen

8am - 12pm

Past History :

H/O thyroid
disorder

- BRISTAA INTENSE
CREAM

Investigation :

Drug Allergies : (if any)

N/K

(2/A) m _____ x 10 days

Treatment :

Chemical peel
+
comedone
extraction

→ DEMELAN CREAM

(2/A) o _____ N
x 10 days

→ Cap OXIDON PLUS

Once daily (10)

→ R/v after 10 days

Gurgaon

Q Block South City 11, Sohna Road, Main Sector-47, Gurgaon, Haryana Ph.: 0124-4900000 Fax : 8124-4900000
E-mail : parkmedicenters@gmail.com

● West Delhi ● South Delhi ● Faridabad ● Panipat ● Karnal



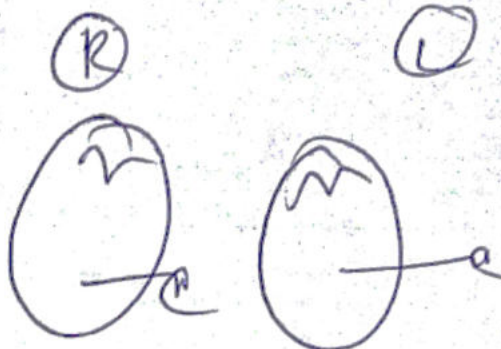


For medical exam

Vitals :

Chief Complaints :

Ran



H/O Present Illness :

Past History :

Oral - none

Investigation :

Drug Allergies : (if any)

Nose - septum middle
Bilateral nasal cavity - clear

Treatment :

~~As~~
Pure tone audiogram

24/9/22



Gurgaon

Q Block South City 11, Sohna Road, Main Sector-47, Gurgaon, Haryana Ph.: 0124-4900000 Fax : 0124-2218733
E-mail : parkmedcenters@gmail.com

● West Delhi ● South Delhi ● Faridabad ● Panipat ● Karnal

DEPARTMENT OF PATHOLOGY

Patient Name : Mrs. KUMARI NIVA
MR No : 662279
Age/Sex : 32 Years 9 Months 31 Days / Female
Type : OPD
TPA/Corporate : MEDIWHEEL PVT LTD

Bill Date : 24/09/2022 / 10.12 AM
Reporting Date : 24/09/2022
Sample ID : 45400
Bill/Req. No. : 22965450
Ref Doctor : Dr.RMO

Test	Result	Blo. Ref. Interval	Units	Method
BLOOD SUGAR FASTING				
PLASMA GLUCOSE FASTING	71	60 - 100	mg/dl	GOD TRINDERS

***** END OF THE REPORT *****

Dr.NALANDA BUKTARE
MD (Pathology)

Dr.PRADIP KUMAR
Consultant (Microbiology)

Dr.NISHA TIWARI
MBBS, MD (Microbiology)
USER NM AMIT



(This is only professional opinion and not the diagnosis, Please correlate clinically)

Q Block South City 11, Sohna Road, Main Sector-47, Gurgaon, Haryana
Ph.: 0124-4900000 (100 Lines) Fax : 0124-2218733 E-mail : parkmedcenters@gmail.com

PARK GROUP OF HOSPITALS : West Delhi • South Delhi • Gurgaon • Karnal • Panipat • Hodal • Ambala • Behror

the **health** care providers

the **health** care providers



Cert. No. MC - 4830



Cert. No. H-2016-0369

DEPARTMENT OF PATHOLOGY

Patient Name : Mrs. KUMARI NIVA

MR No : 662279

Age/Sex : 32 Years 9 Months 31 Days / Female

Type : OPD

TPA/Corporate : MEDIWHEEL PVT LTD

Bill Date : 24/09/2022 / 10.12 AM

Reporting Date : 24/09/2022

Sample ID : 45400

Bill/Req. No. : 22965450

Ref Doctor : Dr.RMO

Test	Result	Bio. Ref. Interval	Units	Method
BLOOD SUGAR 2 HR. PP				
BLOOD SUGAR P.P.	87	80 - 150	mg/dl	

***** END OF THE REPORT *****

Dr.NALANDA BUKTARE
MD (Pathology)

Dr.PRADIP KUMAR
Consultant (Microbiology)

Dr.NISHA TIWARI
MBBS, MD (Microbiology)
USER NM AMIT



(This is only professional opinion and not the diagnosis, Please correlate clinically)

Q Block South City 11, Sohna Road, Main Sector-47, Gurgaon, Haryana
Ph.: 0124-4900000 (100 Lines) Fax : 0124-2218733 E-mail : parkmedicenters@gmail.com

PARK GROUP OF HOSPITALS : West Delhi • South Delhi • Gurgaon • Karnal • Panipat • Hodal • Ambala • Behror

the **health** care providers

the **health** care providers



DEPARTMENT OF PATHOLOGY

Patient Name : Mrs. KUMARI NIVA
 MR No : 662279
 Age/Sex : 32 Years 9 Months 31 Days / Female
 Type : OPD
 TPA/Corporate : MEDIWHEEL PVT LTD

Bill Date : 24/09/2022
 Reporting Date : 25/09/2022
 Sample ID : 45400
 Bill/Req. No. : 22965450
 Ref Doctor : Dr.RMO

Test	Result	Bio. Ref. Interval	Units
URINE ROUTINE AND MICROSCOPY			
PHYSICAL CHARACTERSTICS			
QUANTITY	40ml	5 - 100	
COLOUR	Pale Yellow	Pale Yellow	
TURBIDITY	Slightly Turbid		
SPECIFIC GRAVITY	1.015		
PH	6.0		
CHEMICAL EXAMINATION-1			
UROBILINOGEN	NIL	NIL	mg/dl
URINE PROTEIN	NIL		
BLOOD	NIL		
TOTAL BILIRUBIN	NIL	0.1 - 1.2	mg/dL
GLUCOSE	NIL		mg/dL
URINE KETONE	Negative	Negative	
MICRO.EXAMINATION			
PUS CELL	1-2/hpf	<1	
RED BLOOD CELLS	NIL	NIL	
EPITHELIAL CELLS	1-2/hpf	4--5/HPF	
CASTS	NIL	NIL	
CRYSTALS	NIL	NIL	

***** END OF THE REPORT *****



Dr.NALANDA BUKTARE
MD (Pathology)

Dr.PRADIP KUMAR
Consultant (Microbiology)

Dr.NISHA TIWARI
MBBS, MD (Microbiology)

USER NM AMIT

(This is only professional opinion and not the diagnosis, Please correlate clinically)

Q Block South City 11, Sohna Road, Main Sector-47, Gurgaon, Haryana
 Ph.: 0124-4900000 (100 Lines) Fax : 0124-2218733 E-mail : parkmedicenters@gmail.com

PARK GROUP OF HOSPITALS : West Delhi • South Delhi • Gurgaon • Karnal • Panipat • Hodal • Ambala • Behror

the health care providers

the health care providers



DEPARTMENT OF PATHOLOGY

Patient Name : Mrs. KUMARI NIVA

MR No : 662279

Age/Sex : 32 Years 9 Months 31 Days / Female

Type : OPD

TPA/Corporate : MEDIWHEEL PVT LTD

Bill Date : 24/09/2022

Reporting Date : 24/09/2022

Sample ID : 45400

Bill/Req. No. : 22965450

Ref Doctor : Dr.RMO

Test	Result	Bio. Ref. Interval	Units
BLOOD GROUPING AND RH FACTOR			
BLOOD GROUP	* B * RH POSITIVE		

***** END OF THE REPORT *****



Sample no.



Dr.NALANDA BUKTARE
MD (Pathology)

Dr.PRADIP KUMAR
Consultant (Microbiology)

Dr.NISHA TIWARI
MBBS, MD (Microbiology)

USER NM AMIT

(This is only professional opinion and not the diagnosis, Please correlate clinically)

Q Block South City 11, Sohna Road, Main Sector-47, Gurgaon, Haryana
Ph.: 0124-4900000 (100 Lines) Fax : 0124-2218733 E-mail : parkmedicenters@gmail.com

PARK GROUP OF HOSPITALS : West Delhi • South Delhi • Gurgaon • Karnal • Panipat • Hodal • Ambala • Behror





DEPARTMENT OF PATHOLOGY

Patient Name : Mrs. KUMARI NIVA

MR No : 662279

Age/Sex : 32 Years 9 Months 31 Days / Female

Type : OPD

TPA/Corporate : MEDIWHEEL PVT LTD

Bill Date : 24/09/2022 / 10.12 AM

Reporting Date : 24/09/2022

Sample ID : 45400

Bill/Req. No. : 22965450

Ref Doctor : Dr.RMO

Test	Result	Bio. Ref. Interval	Units	Method
CBC				
HAEMOGLOBIN	13.7	12 - 15	gm/dL	COLORIMETRY
TOTAL LEUCOCYTE COUNT	8300	4000 - 10000	/ μ L	ELECTRICAL IMPEDANCE
DIFFERENTIAL COUNT				
NEUTROPHILS	65	40.0 - 80.0	%	FLOW CYTOMETRY
LYMPHOCYTES	25	20.0 - 40.0	%	FLOW CYTOMETRY
MONOCYTES	08	2.0 - 10.0	%	FLOW CYTOMETRY
EOSINOPHILS	02	0.0 - 5.0	%	FLOW CYTOMETRY
BASOPHILS	00	0.0 - 2.0	%	FLOW CYTOMETRY
RED BLOOD CELL COUNT	3.9	3.5 - 5.5	millions/ μ L	ELECTRICAL IMPEDANCE
PACKED CELL VOLUME	36.0	35.0 - 50.0	%	ELECTRICAL IMPEDANCE
MEAN CORPUSCULAR VOLUME	90.6	83 - 101	fL	ELECTRICAL IMPEDANCE
MEAN CORPUSCULAR HAEMOGLOBIN	34.5	27 - 31	Picogrammes	CALCULATED
MEAN CORPUSCULAR HB CONC	38.1	33 - 37	g/dl	CALCULATED
PLATELET COUNT	138	150 - 450	thou/ μ L	ELECTRICAL IMPEDANCE
RDW	13.1	11.6 - 14.5	%	CALCULATED

***** END OF THE REPORT *****

Dr.NALANDA BUKTARE
MD (Pathology)

Dr.PRADIP KUMAR
Consultant (Microbiology)

Dr.NISHA TIWARI
MBBS, MD (Microbiology)
USER NM AMIT



(This is only professional opinion and not the diagnosis, Please correlate clinically)

Q Block South City 11, Sohna Road, Main Sector-47, Gurgaon, Haryana
Ph.: 0124-4900000 (100 Lines) Fax : 0124-2218733 E-mail : parkmedicenters@gmail.com

PARK GROUP OF HOSPITALS : West Delhi • South Delhi • Gurgaon • Karnal • Panipat • Hodal • Ambala • Behror

the **health** care providers

the **health** care providers



DEPARTMENT OF PATHOLOGY

Patient Name : Mrs. KUMARI NIVA
 MR No : 662279
 Age/Sex : 32 Years 9 Months 31 Days / Female
 Type : OPD
 TPA/Corporate : MEDIWHEEL PVT LTD

Bill Date : 24/09/2022
 Reporting Date : 24/09/2022
 Sample ID : 45400
 Bill/Req. No. : 22965450
 Ref Doctor : Dr.RMO

Test	Result	Bio. Ref. Interval	Units
ESR (WESTERGREN)			
E.S.R.	30 H	0 - 15	mm at the end of 1st hr

***** END OF THE REPORT *****



Dr.NALANDA BUKTARE
MD (Pathology)

Dr.PRADIP KUMAR
Consultant (Microbiology)

Dr.NISHA TIWARI
MBBS, MD (Microbiology)
USER NM AMIT



(This is only professional opinion and not the diagnosis, Please correlate clinically)

Q Block South City 11, Sohna Road, Main Sector-47, Gurgaon, Haryana
Ph.: 0124-4900000 (100 Lines) Fax : 0124-2218733 E-mail : parkmedicenters@gmail.com

PARK GROUP OF HOSPITALS : West Delhi • South Delhi • Gurgaon • Karnal • Panipat • Hodal • Ambala • Behror

the **health** care providers the **health** care providers

DEPARTMENT OF PATHOLOGY

Patient Name : Mrs. KUMARI NIVA

MR No : 662279

Age/Sex : 32 Years 9 Months 31 Days / Female

Type : OPD

TPA/Corporate : MEDIWHEEL PVT LTD

Bill Date : 24/09/2022 / 10.12 AM

Reporting Date : 25/09/2022

Sample ID : 45400

Bill/Req. No. : 22965450

Ref Doctor : Dr.RMO

Test	Result	Bio. Ref. Interval	Units	Method
THYROID PROFILIE				
TRI-iodothyronine (T3)	0.84	0.60 - 1.81	ng/ml	Chemiluminescence
THYROXINE (T4)	8.2	5.01 - 12.45	µg/dL	Chemiluminescence
THYROID STIMULATING HORMONE (TSH)	4.82	0.5-5.50 ,	µIU/ml	
SPECIMEN TYPE	SERUM			

Method : chemiluminescent immunoassay

Note : Clinical Significance:

Thyroid function tests (TFTs) is a collective term for blood tests used to check the function of the thyroid. TFTs may be requested if a patient is thought to suffer from hyperthyroidism (overactive thyroid) or hypothyroidism (underactive thyroid), or to monitor the effectiveness of either thyroid-suppression or hormone replacement therapy. It is also requested routinely in conditions linked to thyroid disease, such as atrial fibrillation and anxiety disorder. A TFT panel typically includes thyroid hormones such as thyroid-stimulating hormone (TSH, thyrotropin) and thyroxine (T4), and triiodothyronine (T3) depending on local laboratory policy.

Note: Please correlate with clinical condition

***** END OF THE REPORT *****



Dr. NALANDA BUKTARE
MD (Pathology)

Dr. PRADIP KUMAR
Consultant (Microbiology)

Dr. NISHA TIWARI
MBBS, MD (Microbiology)
USER NM DINESH

(This is only professional opinion and not the diagnosis, Please correlate clinically)

Q Block South City 11, Sohna Road, Main Sector-47, Gurgaon, Haryana - 122001

Ph.: 0124-4900000 (100 Lines) Fax : 0124-2218733 E-mail : parkmedicenters@gmail.com

PARK GROUP OF HOSPITALS : West Delhi • South Delhi • Gurgaon • Karnal • Panipat • Hodal • Ambala • Behror

the **health** care providers

the **health** care providers



NABL
Cert. No. MC - 4830



NABH
Cert. No. H-2018-0369

DEPARTMENT OF PATHOLOGY

Patient Name : Mrs. KUMARI NIVA

MR No : 662279

Age/Sex : 32 Years 9 Months 31 Days / Female

Type : OPD

TPA/Corporate : MEDIWHEEL PVT LTD

Bill Date : 24/09/2022 / 10.12 AM

Reporting Date : 24/09/2022

Sample ID : 45400

Bill/Req. No. : 22965450

Ref Doctor : Dr.RMO

Test	Result	Bio. Ref. Interval	Units	Method
LFT (LIVER FUNCTION TEST)				
LFT				
TOTAL BILIRUBIN	0.9	0.1 - 1.2	mg/dL	DIAZO
DIRECT BILIRUBIN	0.4	0 - 0.4	mg/dL	DIAZO
INDIRECT BILIRUBIN	0.5	0.10 - 0.6	mg/dL	CALCULATED
SGOT (AST)	24	0 - 45	U/L	IFCC WITHOUT PYRIDOXAL PHOSPHATE
SGPT (ALT)	18	0 - 45	U/L	IFCC WITHOUT PYRIDOXAL PHOSPHATE
ALKALINE PHOSPHATASE	87	30 - 170	IU/L	MODIFIED IFCC
TOTAL PROTEINS	7.1	6.4 - 8.0	g/dL	BIURET
ALBUMIN	4.3	3.3 - 5.5	g/dL	BCG DYE
GLOBULIN	2.8	2.3 - 4.5	g/dL	CALCULATED
A/G RATIO	1.54	1.1 - 2.2		CALCULATED

***** END OF THE REPORT *****



Dr.NALANDA BUKTARE
MD (Pathology)

Dr.PRADIP KUMAR
Consultant (Microbiology)

Dr.NISHA TIWARI
MBBS, MD (Microbiology)
USER NM AMIT

(This is only professional opinion and not the diagnosis, Please correlate clinically)

Q Block South City 11, Sohna Road, Main Sector-47, Gurgaon, Haryana 122001
Ph.: 0124-4900000 (100 Lines) Fax : 0124-2218733 E-mail : parkmedcenters@gmail.com

PARK GROUP OF HOSPITALS : West Delhi • South Delhi • Gurgaon • Karnal • Panipat • Hodal • Ambala • Behror

the **health** care providers

the **health** care providers



DEPARTMENT OF PATHOLOGY

Patient Name : Mrs. KUMARI NIVA
MR No : 662279
Age/Sex : 32 Years 9 Months 31 Days / Female
Type : OPD
TPA/Corporate : MEDIWHEEL PVT LTD

Bill Date : 24/09/2022 / 10.12 AM
Reporting Date : 24/09/2022
Sample ID : 45400
Bill/Req. No. : 22965450
Ref Doctor : Dr.RMO


Test	Result	Bio. Ref. Interval	Units	Method
KFT (RENAL PROFILE)				
KFT				
SERUM UREA	17	10 - 45	mg/dL	UREASE-GLDH
SERUM CREATININE	0.9	0.4 - 1.4	mg/dL	MODIFIED JAFFES
SERUM URIC ACID	4.4	2.5 - 7.0	mg/dL	URICASE
SERUM SODIUM	144	136 - 145	meq/l	ISE
SERUM POTASSIUM	4.0	3.5 - 5.5	meq/l	ISE
SERUM CALCIUM	8.6	8.5 - 10.5	mg/dL	ARSENAZO III
SERUM PHOSPHORUS	2.8	2.5 - 4.5	mg/dL	AMMONIUM MOLYBDATE

***** END OF THE REPORT *****

Dr.NALANDA BUKTARE
MD (Pathology)

Dr.PRADIP KUMAR
Consultant (Microbiology)

Dr.NISHA TIWARI
MBBS, MD (Microbiology)
USER NM AMP



(This is only professional opinion and not the diagnosis, Please correlate clinically)

Q Block South City 11, Sohna Road, Main Sector-47, Gurgaon, Haryana
Ph.: 0124-4900000 (100 Lines) Fax : 0124-2218733 E-mail : parkmedicenters@gmail.com

PARK GROUP OF HOSPITALS : West Delhi • South Delhi • Gurgaon • Karnal • Panipat • Hodal • Ambala • Behror

the **health** care providers

the **health** care providers



DEPARTMENT OF PATHOLOGY

Patient Name : Mrs. KUMARI NIVA
 MR No : 662279
 Age/Sex : 32 Years 9 Months 31 Days / Female
 Type : OPD
 TPA/Corporate : MEDIWHEEL PVT LTD

Bill Date : 24/09/2022 / 10.12 AM
 Reporting Date : 24/09/2022
 Sample ID : 45400
 Bill/Req. No. : 22965450
 Ref Doctor : Dr.RMO

Test	Result	Bio. Ref. Interval	Units	Method
LIPID PROFILE				
TOTAL CHOLESTEROL	172	0 - 250	mg/dL	CHOD -Trinder
SERUM TRIGLYCERIDES	102	60 - 165	mg/dl	GPO-TRINDER
HDL-CHOLESTEROL	46	30 - 70	mg/dl	DIRECT
VLDL CHOLESTEROL	20	6 - 32	mg/dL	calculated
LDL	106	50 - 135	mg/dl	calculated
LDL CHOLESTEROL/HDL RATIO	2.3	1.0 - 3.0	mg/dL	calculated
TOTAL CHOLESTEROL/HDL RATIO	3.7	2.0 - 5.0	mg/dl	calculated


***** END OF THE REPORT *****

Dr.NALANDA BUKTARE
 MD (Pathology)

Dr.PRADIP KUMAR
 Consultant (Microbiology)

Dr.NISHA TIWARI
 MBBS, MD (Microbiology)

USER NM AMIT



(This is only professional opinion and not the diagnosis, Please correlate clinically)

Q Block South City 11, Sohna Road, Main Sector-47, Gurgaon, Haryana 1
 Ph.: 0124-4900000 (100 Lines) Fax : 0124-2218733 E-mail : parkmedicenters@gmail.com

PARK GROUP OF HOSPITALS : West Delhi • South Delhi • Gurgaon • Karnal • Panipat • Hodal • Ambala • Behror

the **health** care providers

the **health** care providers





DEPARTMENT OF RADIOLOGY

Cert. No. MC - 4830 Cert. No. H-2018-0366

Patient Name	Mrs. KUMARI NIVA	Billed Date	: 24/09/2022	10.12 AM
Reg No	662279	Reported Date	: 24/09/2022	
Age/Sex	32 Years 9 Months 31Days / Female	Req. No.	: 22965450	
Type	OPD	Consultant Doctor	: Dr. RMO	

USG WHOLE ABDOMEN

The real time, B mode, gray scale sonography of the abdominal organs was performed.

LIVER : The liver is normal in size 14.4cm shape and echotexture. No evidence of any focal lesion. IHBR is not dilated.

GALL BLADDER : The gall bladder is well distended . No evidence any calculus or mass seen.

GB wall thickness with in normal limits.No evidence of pericholecystic fluid is seen.

BILE DUCT :The common bile duct is normal in caliber. No evidence of calculus is noted in common bile duct.

SPLEEN :The spleen is normal in size 9.7cm and shape.Its echotexture is homogeneous.No evidence of focal lesion is noted.

PANCREAS :The pancreas is normal in size, shape, contours and echotexture.No evidence of solid or cystic mass lesion is noted.MPD is not dilated. No evidence of peripancreatic collection.

KIDNEYS : The bilateral kidneys are normal in size and echotexture. Cortico-medullary differentiation is maintained.There is no evidence of obvious calculus or hydronephrosis.

URINARY BLADDER :The urinary bladder is partially distended.It shows uniformly thin walls and sharp mucosa.No evidence of calculus is seen. No evidence of mass or diverticulum is noted.

UTERUS: The uterus is anteverted. It measures 6.0x4x4.1 cms. in the longitudinal, anteroposterior and transverse dimensions respectivelyThe uterine margins is smooth and does not reveal any contour abnormalities.

The uterine myometrium shows homogeneous echotexture.

No evidence of leiomyoma is noted. No solid or cystic mass lesion is noted.

The endometrial echo is in the midline and measures 7.4mm.

The ovaries on the either side show normal echotexture.

No adnexal mass is seen.No cyst is seen in ovaries.

No evidence of ascites or interbowel free fluid is seen.

No evidence of obvious retroperitoneal or mesentric lymphadenopathy is seen.

IMPRESSION- NORMAL STUDY

To be correlated clinically.

Dr. ANSHU K. SHARMA
MBBS, MD
CONSULTANT RADIOLOGIST

Dr. MANJEET SEHRAWAT
MBBS, MD, PDCC
CONSULTANT RADIOLOGIST



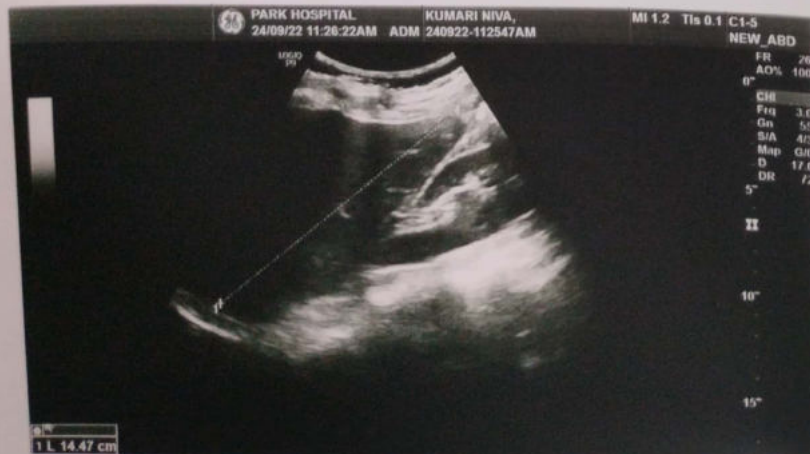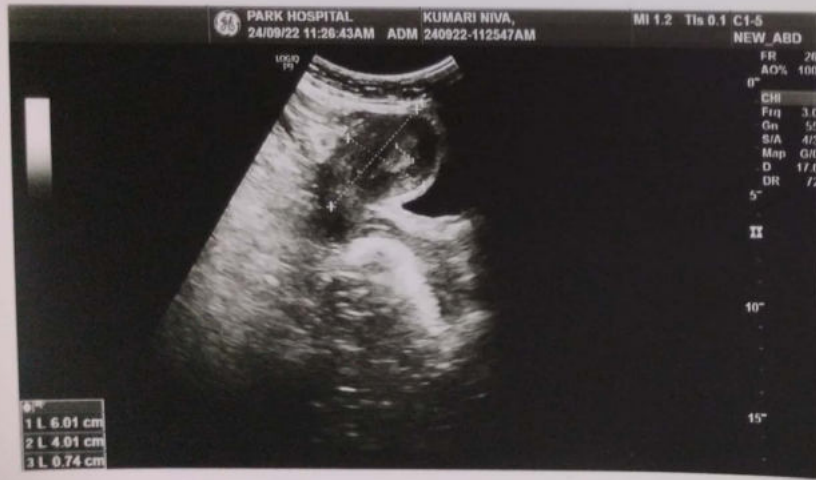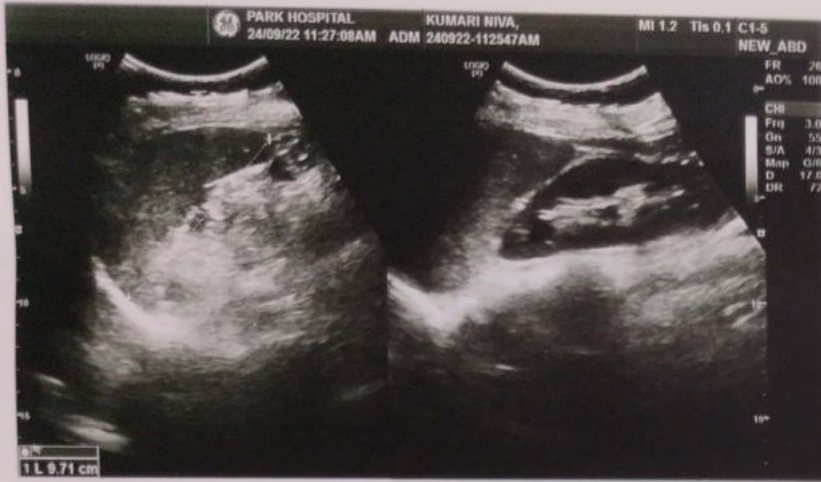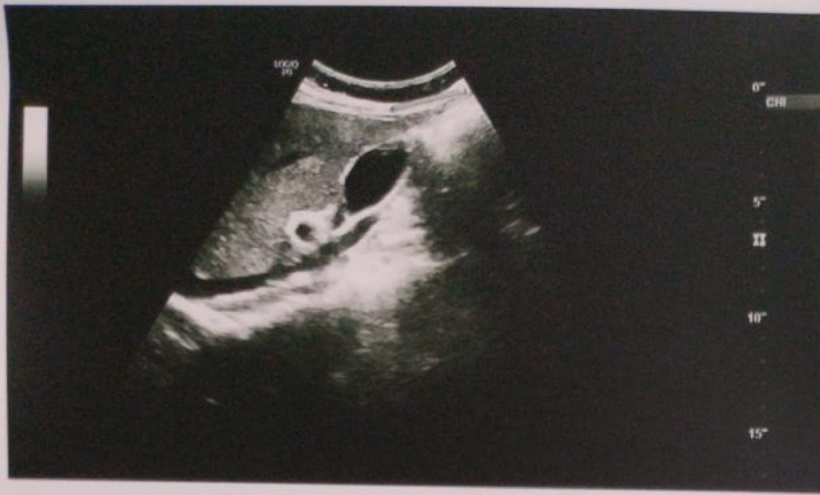(This is only professional opinion and not the diagnosis, Please correlate clinically)

Q Block South City 11, Sohna Road, Main Sector-47, Gurgaon, Haryana
Ph.: 0124-4900000 (100 Lines) Fax : 0124-2218733 E-mail : parkmedicenters@gmail.com

PARK GROUP OF HOSPITALS : West Delhi • South Delhi • Gurgaon • Karnal • Panipat • Hodal • Ambala • Behror

the **health** care providers

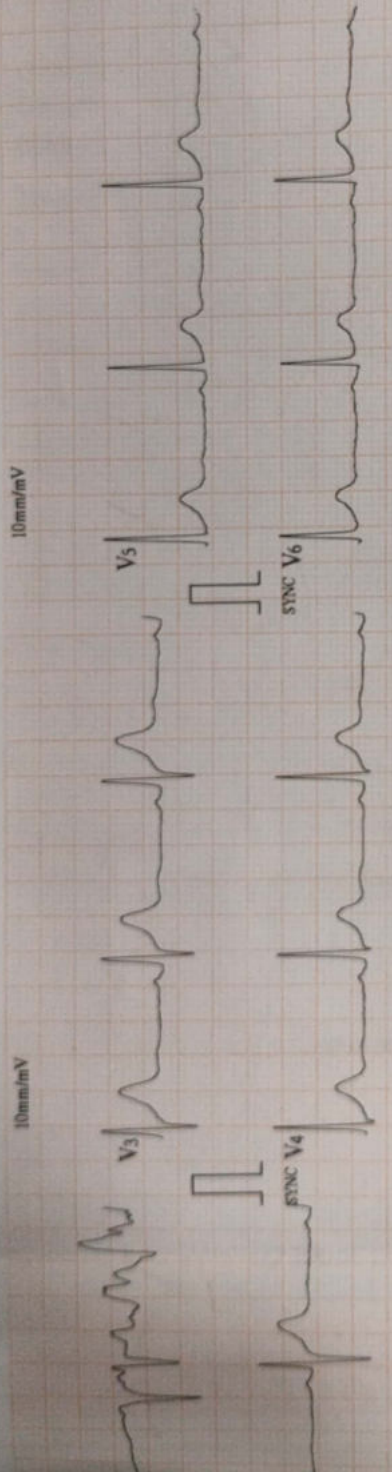
the **health** care providers

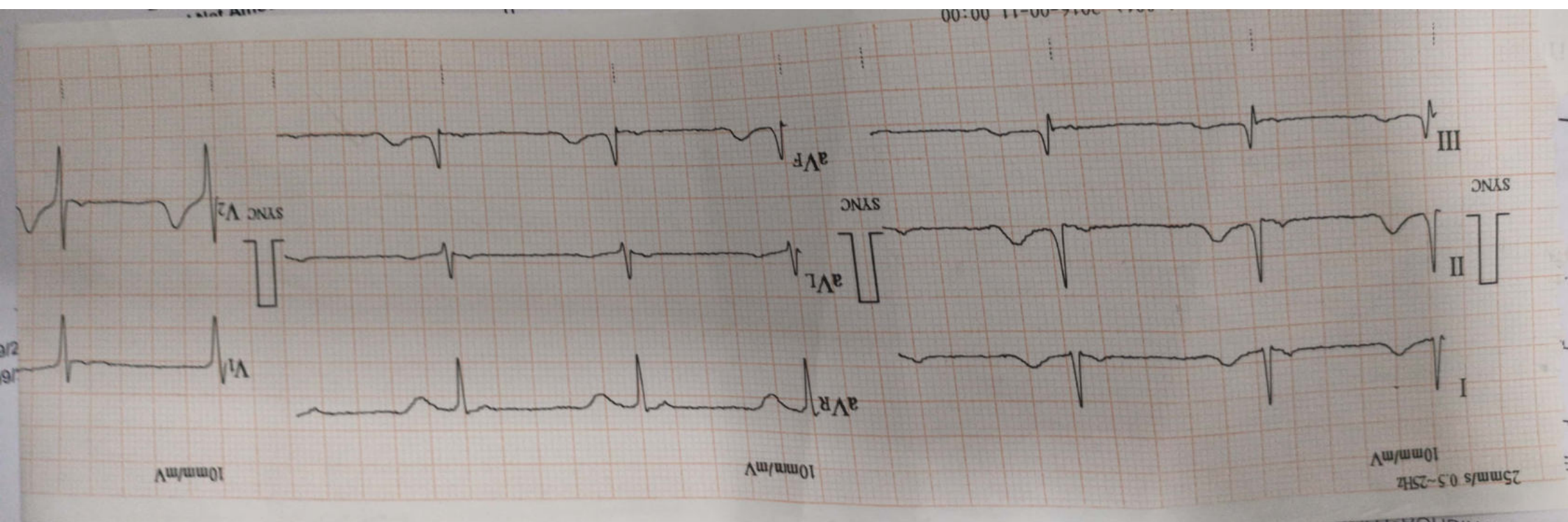


ID : 0001 HR : 62 bpm
 R-R : 953 ms
 P-R : 190 ms
 QRS : 100 ms
 QT/QTc : 364/372 ms
 P/QRS/T : 25/50/44 ms
 RV5/SV1 : 1.490/0.650 mV
 RV5-SV1 : 2.140 mV
 Name: Chandan K S N
 Sex : male
 Age : 32 yr
 24/9/20

Sinus Rhythm
 Left Atrial Enlargement
 Long P-R Interval

Unconfirmed report Verified by: _____







DEPARTMENT OF RADIOLOGY

Cert. No. MC - 4830

Cert. No. H-2016-0369

Patient Name	Mrs. KUMARI NIVA	Billed Date	24/09/2022	10.12 AM
Reg No	662279	Reported Date	24/09/2022	
Age/Sex	32 Years 9 Months 31Days / Female	Req. No.	22965450	
Type	OPD	Consultant Doctor	Dr. RMO	

X-RAY CHEST AP/PA

X-RAY CHEST P.A. VIEW

Bilateral lungs appears normal.

No focal lung lesion seen.

No evidence of free fluid is seen.

Both hila are normal in size, have equal density and bear normal relationship.

The heart and trachea are central in position and no mediastinal abnormality is visible.

The cardiac size is normal for patient age and view.

The domes of the diaphragms are normal in position, and show smooth outline.

To be correlated clinically



Dr. ANSHU K. SHARMA
MBBS, MD
CONSULTANT RADIOLOGIST

Dr. MANJEET SEHRAWAT
MBBS, MD, PDCC
CONSULTANT RADIOLOGIST

Dr. NEENA SIKKA
MBBS, DNB
CONSULTANT RADIOLOGIST

(This is only professional opinion and not the diagnosis, Please correlate clinically)

Q Block South City 11, Sohna Road, Main Sector-47, Gurgaon, Haryana
Ph.: 0124-4900000 (100 Lines) Fax : 0124-2218733 E-mail : parkmedicenters@gmail.com

PARK GROUP OF HOSPITALS : West Delhi • South Delhi • Gurgaon • Karnal • Panipat • Hodal • Ambala • Behror

the **health** care providers

the **health** care providers



R

