

Facilities:

All clinical Biomedical & Hematology Investigations including Bone Marrow Examination
VPT, Podiascan & Complete Foot Care (First Time in Purvanchal)
All Hormonal Investigation by Chemiluminescent Method
Visceral Fat by (AB-140) Ambulatory BP Monitoring
CGMS & Insulin Pump Available
PFT, 2D-ECHO (Color Doppler), Holter, TMT, Cardiac-3 available
VIA, VILI, Colposcopy available
Special Endocrinological Investigation Protocols.

ISO 9001:2008 Certified
Mobile: 9389994334, 9554572190, 9453837595



Panacea Pathology

Clinical Reference Lab

Persistence, Preparedness and Precision
EQAS (CMC Vellore Attached) & IQAS System
पूर्वाचल की सर्वोत्तम गुणवत्ता वाली पैथोलॉजी

PATIENT NAME : MONIKA CHAUHAN

AGE/GENDER : 29YRS/FEMALE

REFD BY DR. : ARCO FEMI HEALTHCARE LTD.

RECEIVED DATE : 11-02-2023(09:30AM)

SAMPLE : BLOOD & URINE

REPORT DATE : 13-02-2023(02:00PM)

PATHOLOGY REPORT

COMPLETE BLOOD COUNT (CBC)

TEST	LAB TEST VALUES	NORMAL RANGE
HEMOGRAM		
HEMOGLOBIN (FLOW CYTOMETRY)	12.0	13 – 16 gm/dl
TOTAL LEUCOCYTE COUNT (TLC)	6,300	4000 – 11000
RBC COUNT	3.75	3.5 – 5.5
PCV (HCT)	37.2	37 – 47
MCV	99.2	80 – 95
MCH	32.0	28 – 34
MCHC	32.3	30 – 36
PLATELET COUNT	3,48,000	1,50,000 – 4,00,000
E.S.R. (WINTROBE FIRST HOURS)	12.0	20 mm/1 st hr
DIFFERENTIAL LEUCOCYTE		
NEUTROPHILS	66	40 – 75%
LYMPHOCYTES	26	20 – 45%
EOSINOPHILS	04	1 – 6%
MONOCYTES	04	2 – 8%
BASOPHILS	00	< 2 %

RENAL & KIDNEY PROFILE, SERUM

TEST	LAB TEST VALUES	NORMAL RANGE
RENAL FUNCTION TESTS		
BLOOD UREA NITROGEN (BUN)	10.0	10 – 50 mg/dl
SERUM CREATININE	0.75	0.60 – 1.60 mg/dl
URIC ACID	3.98	3.60 – 7.70 mg/dl
ALKALINE PHOSPHATASE (ALP)	88.0	142 – 353 mg/dl
TOTAL PROTIENS	7.50	0 – 39 mg/dl
ALBUMIN	4.15	3.8 – 5.4 mg/dl
SERUM GLOBULIN	3.35	2.1 – 3.5 mg/dl
CALCIUM	9.0	8.80 – 10.20
PHOSPHORUS	3.04	2.50 – 5.00
SERUM SODIUM NA+	1.005	135.00 – 155.00 mEq/Ltr
SERUM POTASIUUM K+	4.12	3.60 – 5.50 mEq/Ltr
ICALCIUM	1.22	1.10 – 1.35 mmol/L
SERUM CHLORIDE CL+	101.3	98.00 – 110.00 mEq/Ltr

PAGE 1

Lab Technician

PANACEA HOSPITAL
(A UNIT OF AAROH HEALTHCARE PVT. LTD.)
REG. NO. 1000
B.36/47, B-36, KABIR NAGAR
DURGAM, Pathology

Timing : 8.00 a.m. to 9.00 p.m. (Sunday 8.00 a.m. to 3.00 p.m.)

This Report is not valid for medico legal purpose

Note: These tests have technical limitations. Clinico-pathological interpretation is necessary. In case of any disparity test may be repeated immediately.

Address : 36/44 FK Kabir Nagar, Durgakund, Varanasi – 221005

Email: dramishra@gmail.com, drpallaviojha@gmail.com Website: panaceahospital.org

Facilities:
 All clinical Biomedical & Hematology Investigations
 including Bone Marrow Examination
 VPT, Podiascan & Complete Foot Care (First Time in Purvanchal)
 All Hormonal Investigation by Chemiluminescent Method
 Visceral Fat by (AB-140) Ambulatory BP Monitoring
 CGMS & Insulin Pump Available
 PFT, 2D-ECHO (Color Doppler), Holter, TMT, Cardiac-3 available
 VIA, VILI, Colposcopy available
 Special Endocrinological Investigation Protocols.

ISO 9001:2008 Certified
 Mobile: 9389994334, 9554572190, 9453837595



Panacea Pathology Clinical Reference Lab

Persistence, Preparedness and Precision
 EQAS (CMC Vellore Attached) & IQAS System
 पूर्वीचल की सर्वोत्तम गुणवत्ता वाली पैथोलॉजी

PATIENT NAME : MONIKA CHAUHAN	AGE/GENDER : 29YRS/FEMALE
REFD BY DR. : ARCO FEMI HEALTHCARE LTD.	RECEIVED DATE : 11-02-2023(09:30AM)
SAMPLE : BLOOD & URINE	REPORT DATE : 13-02-2023(02:00PM))

PATHOLOGY REPORT

LIPID PROFILE, SERUM

TEST	LAB TEST VALUES	NORMAL RANGE
BLOOD CHEMISTRY		
TOTAL CHOLESTEROL (SERUM)	145.0	Desirable:- < 200 mg/dl Borderline:- 200 – 239 mg/dl High:- > 240 mg/dl
TRIGLYCERIDES (SERUM)	132.0	35 – 170 mg/dl
HDL CHOLESTEROL (SERUM)	38.0	35.30 – 79.50 mg/dl
LDL CHOLESTEROL (SERUM)	80.6	< 130 mg/dl
VLDL	26.8	< 40 mg/dl
CHOLESTROL/HDL RATIO	3.81	< 3.0 Low Risk Ratio 3.0 – 5.0 Avg Risk > 5.0 High Risk
LDL/HDL RATIO	2.10	< 3 Ratio

BLOOD GROUP

TEST	LAB TEST VALUES
BLOOD GROUP ABO & RH FACTOR	
BLOOD GROUP	"A"
RH FACTOR	POSITIVE

GLYCOSYLATED HEMOGLOBIN (HBA1C)

TEST	LAB TEST VALUES	NORMAL RANGE
HBA1C	5.7	Normal : <5.97 % Good Control : 5.97 – 6.81% Fair Control : 6.81 – 7.65% Poor Control : >7.65%

THYROID PROFILE (T3, T4, TSH)

TEST	LAB TEST VALUES	NORMAL RANGE
THYROID FUNCTION TEST		
T3	0.92	0.60 – 1.81 ng/ml
T4	7.56	4.50 – 10.90 ug/dl
TSH	1.13	0.39 – 6.10 uIU/mL

PAGE 2

Lab Technician

PANACEA HOSPITAL
 (A UNIT OF AAROH HEALTHCARE PVT. LTD.)
 REG. NO. 1000
 B.36/44 B KABIR NAGAR
 DURGAKUND, VARANASI
 M.D., Pathology

Timing : 8.00 a.m. to 9.00 p.m. (Sunday 8.00 a.m. to 3.00 p.m.)

This Report is not valid for medico legal purpose

Note: These tests have technical limitations. Clinico-pathological interpretation is necessary. In case of any disparity test may be repeated immediately.

Address : 36/44 FK Kabir Nagar, Durgakund, Varanasi – 221005

Email: dramishra@gmail.com, drpallaviojha@gmail.com Website: panaceahospital.org

activities:

All clinical Biomedical & Hematology Investigations including Bone Marrow Examination VPT, Podiascan & Complete Foot Care (First Time in Puryanchal) All Hormonal Investigation by Chemiluminescent Method Visceral Fat by (AB-140) Ambulatory BP Monitoring CGMS & Insulin Pump Available PFT, 2D-ECHO (Color Doppler), Holter, TMT, Cardiac-3 available VIA, VILI, Colposcopy available Special Endocrinological Investigation Protocols.

ISO 9001:2008 Certified
Mobile: 9389994334, 9554572190, 9453837595



Panacea Pathology

Clinical Reference Lab

Persistence, Preparedness and Precision
EQAS (CMC Vellore Attached) & IQAS System
पूर्वाचल की सर्वोत्तम गुणवत्ता वाली पैथोलॉजी

PATIENT NAME : MONIKA CHAUHAN	AGE/GENDER : 29YRS/FEMALE
REFD BY DR. : ARCO FEMI HEALTHCARE LTD.	RECEIVED DATE : 11-02-2023(09:30AM)
SAMPLE : BLOOD & URINE	REPORT DATE : 13-02-2023(02:00PM)

PATHOLOGY REPORT

LIVER PROFILE TEST, SERUM

TEST	LAB TEST VALUES	NORMAL RANGE
BIO CHEMISTRY		
TOTAL BILIRUBIN	0.76	0.0 – 1.1 mg/dl
DIRECT BILIRUBIN	0.22	0.0 – 0.2 mg/dl
INDIRECT BILIRUBIN	0.54	< 0.90 mg/dl
SGOT (AST)	22.6	0 – 52 mg/dl
SGPT (ALT)	25.6	0 – 39 mg/dl
GGT (GYT)	15.0	< 55 U/L

URINE ROUTINE EXAMINATION

TEST	LAB TEST VALUES	NORMAL RANGE
PHYSICAL EXAMINATION		
QUANTITY	29	ML
COLOUR	STRAW	PALE YELLOW
APPEARANCE	CLEAR	CLEAR
SPECIFIC GRAVITY	1.005	1.01 – 1.03
PH	5.5	4.7 – 7.5
CHEMICAL EXAMINATION		
GLUCOSE	Not Detected	Not Detected
PROTEIN	NIL	Not Detected
MICROSCOPIC EXAMINATION		
PUS CELLS	1-2	0-5
RBC	Not Detected	Not Detected
EPITHELIAL CELLS	2-3	0-5
CASTS	Not Detected	Not Detected
CRYSTALS	Not Detected	Not Detected
BACTERIA	Not Detected	Not Detected

RANDOM/FASTING BLOOD SUGAR

TEST	LAB TEST VALUES	NORMAL RANGE
RBS/FBS		
RANDOM BLOOD SUGAR	117.0	125-140 mg/dl
FASTING BLOOD SUGAR	99.0	70-125 mg/dl

----- End of Report -----

Lab Technician

PANACEA HOSPITAL
(A UNIT OF AAROH HEALTHCARE PVT. LTD.)
REG. NO. 11500
B.36/44, KABIR NAGAR
DURGAKUND, VARANASI
M.D. Pathology

Timing : 8.00 a.m. to 9.00 p.m. (Sunday 8.00 a.m. to 3.00 p.m.)

This Report is not valid for medico legal purpose

Note: These tests have technical limitations. Clinico-pathological interpretation is necessary. In case of any disparity test may be repeated immediately.

Address : 36/44 FK Kabir Nagar, Durgakund, Varanasi – 221005

Email: dramishra@gmail.com, drpallaviojha@gmail.com Website: panaceahospital.org



PANACEA HOSPITAL

B 36/44 F.K KABIR NAGAR, DURGAKUND
TOLLFREE NO-18001233070.
Whatsapp No - 8795832852
www.piire.org



OP Slip

Print Date : 11-Feb-2023 12:03PM



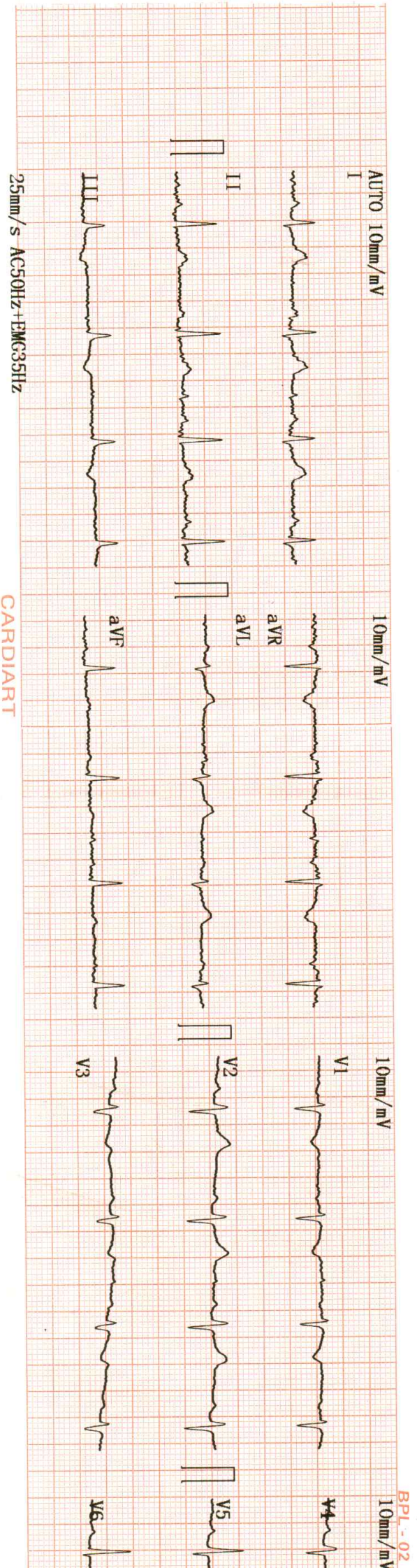
UHID No :- UD-22230003589 **OP No** :- OP-22230013331 **OP Date** :- 11 Feb 2023 12:02PM
Patient Name :- Mrs MONIKA CHAUHAN BOB **Age/Sex** :- 30 Y/Female **Mobile No** :- 8840189830
Husband :- VIKASH KUMAR SINGH **Department** :- DIABETES, ENDOCRINOLOGY & METABOLIC PHYSICIAN
Pay Type :- Cash **Consultant** :- Dr ASHUTOSH MISHRA (MD(MEDICINE), IMS, BHU)
Token No :- NOR. - 11 **Paid/Bal** :- 0.00 /500.00
Patient Type :- Normal
Address :- N 16/12-S, KOLHUA VINAYAK, varanasi

BP :- 120/70
 height :- 150
 Weight (kg) :- 65.6
 BMI :- 29.2

Rx
 HbA1c = 5.7%
 OGD
 PCOD
 R.
 Anel's Exum 60mg
 Tab. Diabems (10) ON
 Tab. Rybuls (3mg) SUNITAN,
 Tab. Obetur (12.5) 1/2
 R/A 2 months

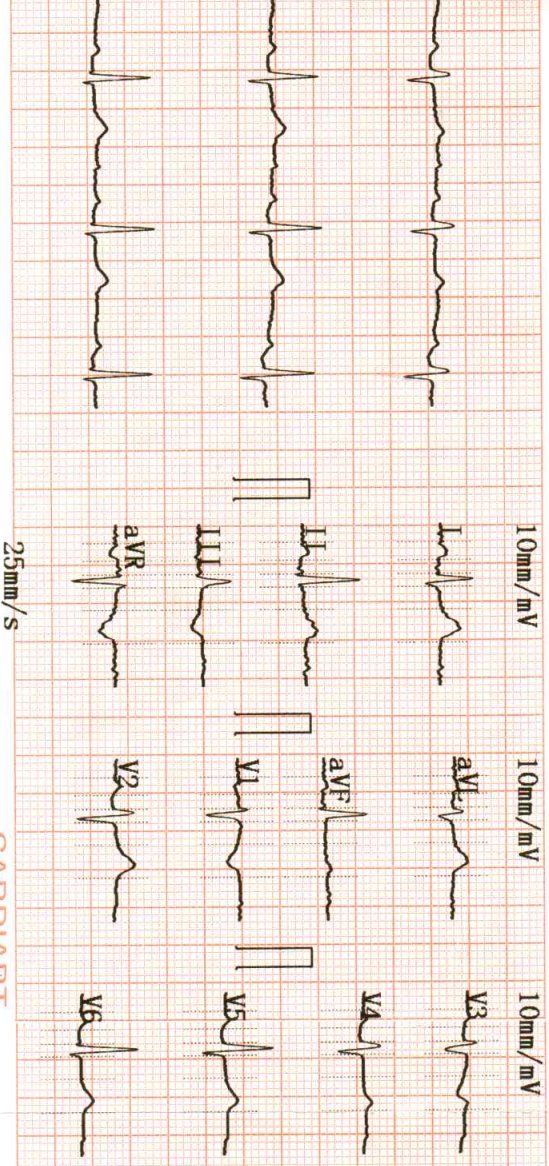
(X) ob/gy.

Printed By : Mr NITIN YADAV
 Created By : Mr NITIN YADAV



BPL - 02

10mm/mV



CARDIART

2023-02-11 14:13

ID : _____
 Name : Mohika Chauhan
 Sex : F
 Height : _____
 SYS : _____
 DIA : _____

HR : 74 bpm
 PR Interval : 172 ms
 P Duration : 97 ms
 QRS Duration : 70 ms
 T Duration : 179 ms
 QT/QTc : 369/410 ms
 P/QRS/T Axis : 5.5/68.1/14.3 deg
 R (V5) / S (V1) : 0.66/0.42 mV
 R (V5) + S (V1) : 1.08 mV

<< Conclusions >>

Normal Sinus Rhythm;
 Cardiac electric axis normal;
 Report need physician confirm

Physician _____

Pallavi Mishra
DR. PALLAVI MISHRA
 MBBS, MD (GENERAL MEDICINE)
 MCI Reg. No. 52033



PANACEA HOSPITAL

A shelter for many hearts A Home for many lives

(An ISO 9001:2008 Certified Organisation)

Lab Attached with CMC Vellore Under EQAS Scheme

Name	MRS.MONIKA CHAUHAN	Sex /Age	30/F	Date	11/02/2023
Ref. by	Dr.Pallavi Mishra(MD)	BSA - m ²		Echo window	fair

Echo - Cardiography

MITRAL VALVE Doppler	AML - normal morphology MV Flow - E - 0.8 A-0.4 E/A=1.74	PML - normal morphology MVA - 3.0 cm ² Mitral Regurgitation - No
TRICUSPID VALVE Doppler	Normal TV Flow -No	Tricuspid Regurgitation - No
PULMONARY VALVE Doppler	Normal PV Flow -No	Pulmonary Regurgitation - No
AORTIC VALVE Doppler	Trileaflet-No AV Flow - no	Aortic Regurgitation - no
MEASUREMENT	Aorta - 17.7 (20-38) mm IVS ed - 8.0 (6 -12) mm LVID ed - 39.4 (35 - 55) mm LVPW ed - 8.0 (6 -12) mm OA - 7 (> 5) mm	LA - 28.6 (24-32) mm IVS es -9.7 (6 - 12) mm LVID es - 18.3 (24 - 40) mm LVPW es - 8.6 (6 -12) mm EPSS - 6 (< 9) mm

CONCLUSION

All cardiac chamber dimensions are WNL
 No valvular abnormalities
 Good LV systolic function present Modified Simpson's method (4C, 2C) (LVEF-85%)
 No diastolic dysfunction present (E/A = 1.74) by tissue Doppler (E/e'=6.2)
 No RWMA
 No pericardial effusion
 Intact IAS / IV
 No PAH
 No intra cardiac mass /thrombus /vegetation

IMPRESSION

Normal Echocardiogram

Niraj Mishra
 Niraj Mishra
 Physician Assistant
 (PHIRE)

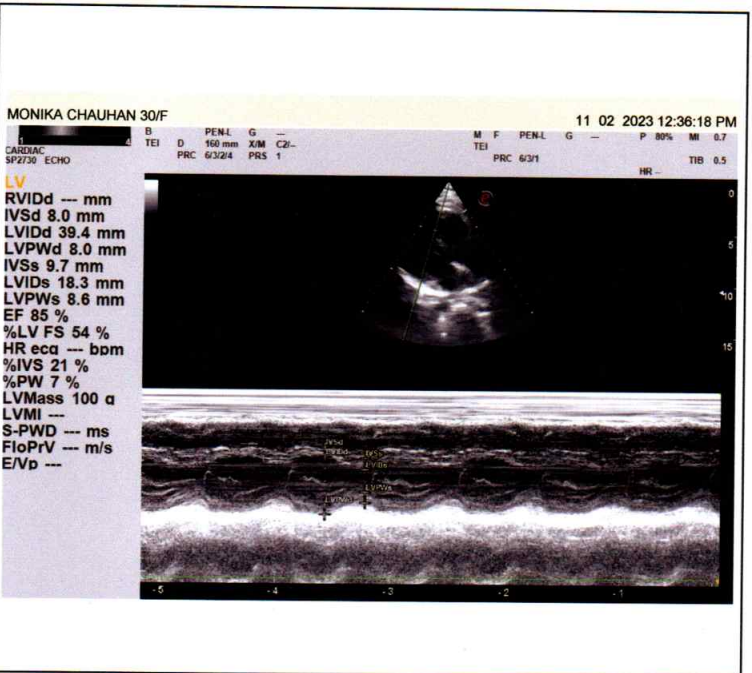
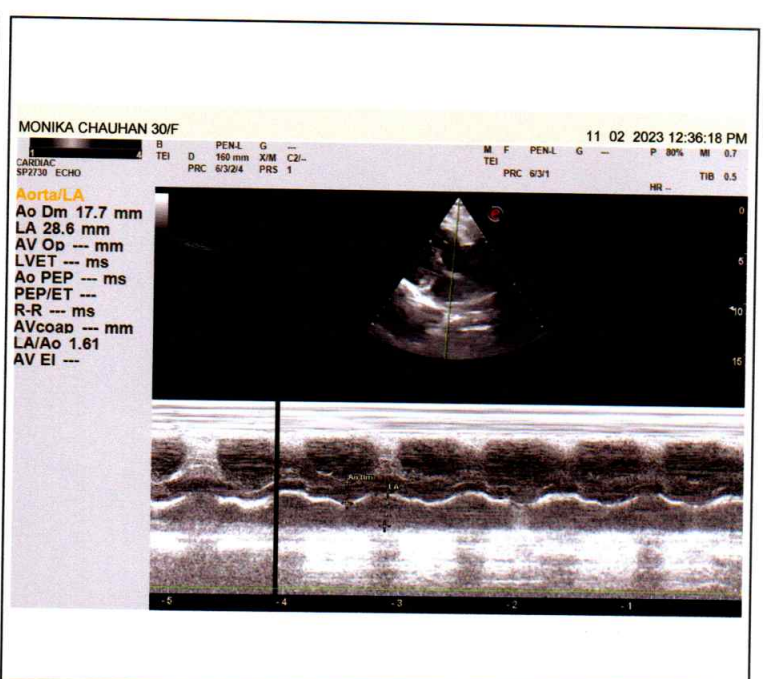
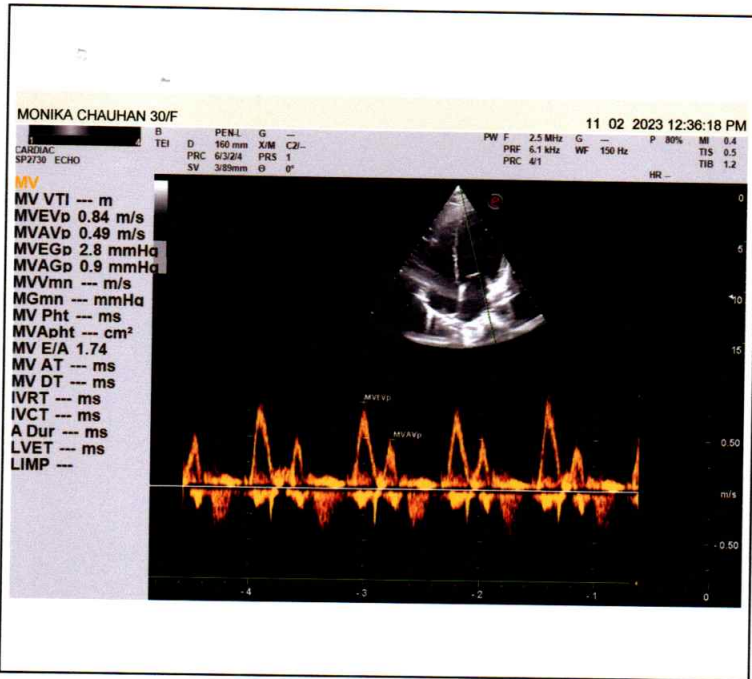
Pallavi Mishra
 Dr. Pallavi Mishra
 MBBS, MD (MED) Lucknow
 Echocardiography Specialist, MIAE
 Non-invasive cardiologist
 Women Cardiologist
 Diabetocardiologist

DR. PALLAVI MISHRA
 MBBS, MD (GENERAL MEDICINE)
 MCI Reg.No. 52033

Address : Kabir Nagar (Near Sanjay Shiksha Niketan), Durgakund, Varanasi

Mobile : 9554572190 / 9453837595 / Recpn. 9389994334

E-mail : dramishra@gmail.com, drpallaviojha@gmail.com, Website: www.piire.org





PANACEA HOSPITAL

A shelter for many hearts A Home for many lives

(An ISO 9001:2008 Certified Organisation)

Lab Attached with CMC Vellore Under EQAS Scheme

NAME: MRS. MONIKA CHAUHAN

AGE/SEX: 30 YRS / FEMALE

REF BY: DR. ASHUTOSH MISHRA (MD)

DATE: 11/02/2023

ULTRA SOUND FOR ABDOMAN REPORT

- Liver:** Normal in shape and size and shows smooth and regular margin.
No diffuse/focal lesion seen.
- Gall bladder** Partially distended with normal wall thickness and echo-free lumen.
- CBD** Visualized part normal in course & caliber.
- Pancreas:** Normal in size, shape & echogenicity.
Margins are smooth & regular.
No diffuse/ focal lesion seen. Pancreatic tail obscured.
- Spleen:** Normal in size(9.8 cm) shape & echogenicity.
Margins are smooth & regular. No diffuse / focal lesion seen.
Splenic vessels at hilum is normal.
- Kidney:** Right kidney: 9.0 X 4.8cm
Left kidney: 9.9 X 4.7 cm
Normal cortical echogenicity with well maintained Cortical-medullary differentiation.
Pelvicalyceal system normal.
No calculus/mass lesion seen.
No hydronephrosis/ hydroureter seen.

Address : Kabir Nagar (Near Sanjay Shiksha Niketan), Durgakund, Varanasi

Mobile : 9554572190 / 9453837595 / Recpn. 9389994334

E-mail : dramishra@gmail.com, drpallaviojha@gmail.com, **Website:** www.piire.org



Call Now - 1800-123-3070

PANACEA HOSPITAL

A shelter for many hearts A Home for many lives

(An ISO 9001:2008 Certified Organisation)

Lab Attached with CMC Vellore Under EQAS Scheme

Urinary bladder: Normally distended, wall thickness is normal.

No echogenic foci lumen or diverticula seen.

Both VUJ appears normal.

No E.R. calculus / mass lesion seen.

Uterus: Uterus normal in size shape, & echogenicity.

Margins are smooth & regular.

Endometrial thickness within normal limits .

Ovary: *Left ovary normal in size and shows normal morphology.*

Right ovary shows a well defined anechoic cystic

lesion measuring 2.6 X 2.3 cm without evidence of internal septation , calcification or solid component S/O simple cyst.

Others: No free fluid in peritoneal cavity.

No free fluid in bilateral pleural cavity.

IMPRESSION:

- *Right ovarian simple cyst. ✓*

Please correlate clinically and further investigations.

Pallavi
DR. PALLAVI MISHRA

MBBS MD(MED) Lucknow

Echocardiography specialist, MIAE

Non invasive cardiologist

Women cardiologist

Tusharika Rai
Radiologist

Dr.Tusharika Rai

MBBS MS

Note: (1) This report is not valid for medico-legal purposes.

(2) In case of any discrepancy due typing error, please get it Rectified immediately.

Address : Kabir Nagar (Near Sanjay Shiksha Niketan), Durgakund, Varanasi

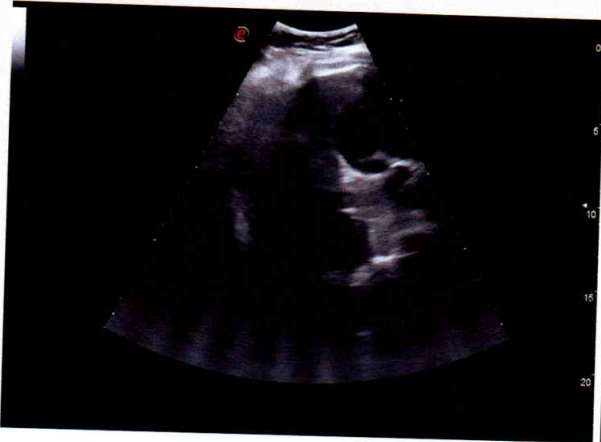Mobile : 9554572190 / 9453837595 / Recpn. 9389994334

E-mail : dramishra@gmail.com, drpallaviojha@gmail.com, Website: www.piire.org

MONIKA CHAUHAN 30/F

11 02 2023 12:45:58 PM

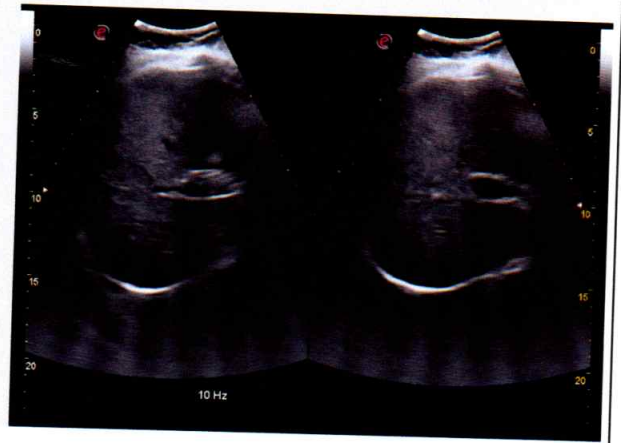ABDOMINAL AC2541 ABD
B TEI D GEN-M G
211 mm X/M C2/-
PRC 19/2/3/5 PRS 4 P 60% MI 0.8



MONIKA CHAUHAN 30/F

11 02 2023 12:45:58 PM

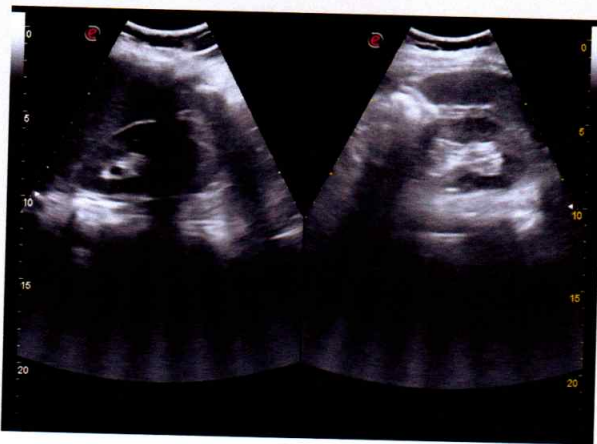ABDOMINAL AC2541 ABD
B TEI D GEN-M G
211 mm X/M C2/-
PRC 19/2/3/5 PRS 4 P 60% MI 0.8



MONIKA CHAUHAN 30/F

11 02 2023 12:45:58 PM

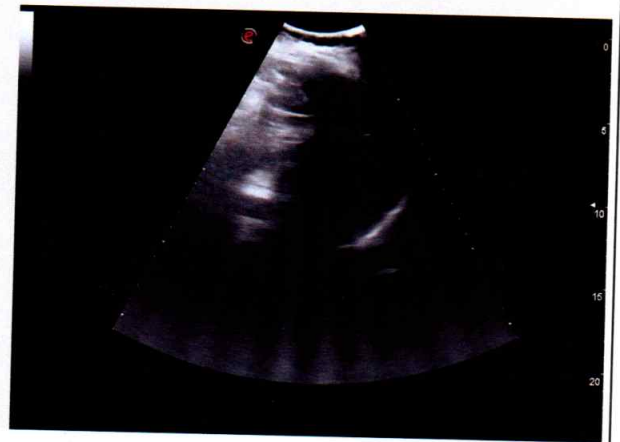ABDOMINAL AC2541 ABD
B TEI D GEN-M G
211 mm X/M C2/-
PRC 19/2/3/5 PRS 4 P 60% MI 0.8



MONIKA CHAUHAN 30/F

11 02 2023 12:45:58 PM

ABDOMINAL AC2541 ABD
B TEI D GEN-M G
211 mm X/M C2/-
PRC 19/2/3/5 PRS 4 P 60% MI 0.8

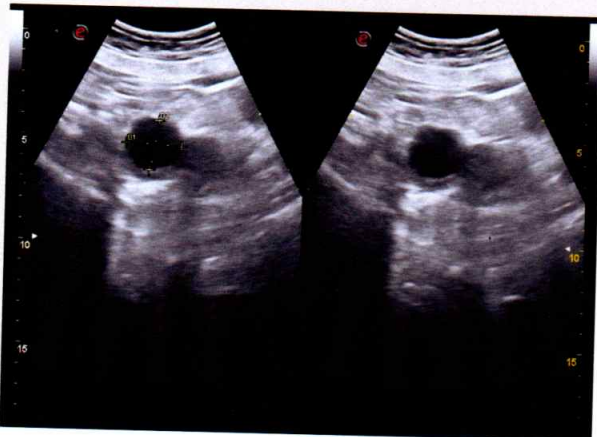


MONIKA CHAUHAN 30/F

11 02 2023 12:45:58 PM

ABDOMINAL AC2541 ABD
B TEI D GEN-M G
169 mm X/M C2/-
PRC 19/2/3/5 PRS 4 P 60% MI 0.8

D-Ratio
D1
26.5 mm
D2
23.8 mm
D/D
111 %





Call Now - 1800-123-3070

PANACEA HOSPITAL

A shelter for many hearts A Home for many lives

(An ISO 9001:2008 Certified Organisation)

Lab Attached with CMC Vellore Under EQAS Scheme

NAME: MRS. MONIKA CHAUHAN

AGE/SEX: 30 YRS / FEMALE

REF BY: DR. ASHUTOSH MISHRA (MD)

DATE: 11/02/2023

X-RAY CHEST PA

BOTH LUNG FIELDS AND PLEURAE:

Both lungs show normal bronchovascular pattern.

Right & left hila are normal

No focal mass or calcification is seen

There is no evidence of any fluid in the both the pleural cavities.

Both domes of diaphragms are normal in position.

MEDIASTINUM:

Trachea is central in position.

Cardiac silhouette is of normal size and configuration.

No evidence of pericardial effusion.

No significant lymphadenopathy is seen.

Visualized skeleton is normal.

NO SIGNIFICANT RADIOGRAPHIC ABNORMALITY.

REPORTED BY

DR. Rahul Kumar Tiwari

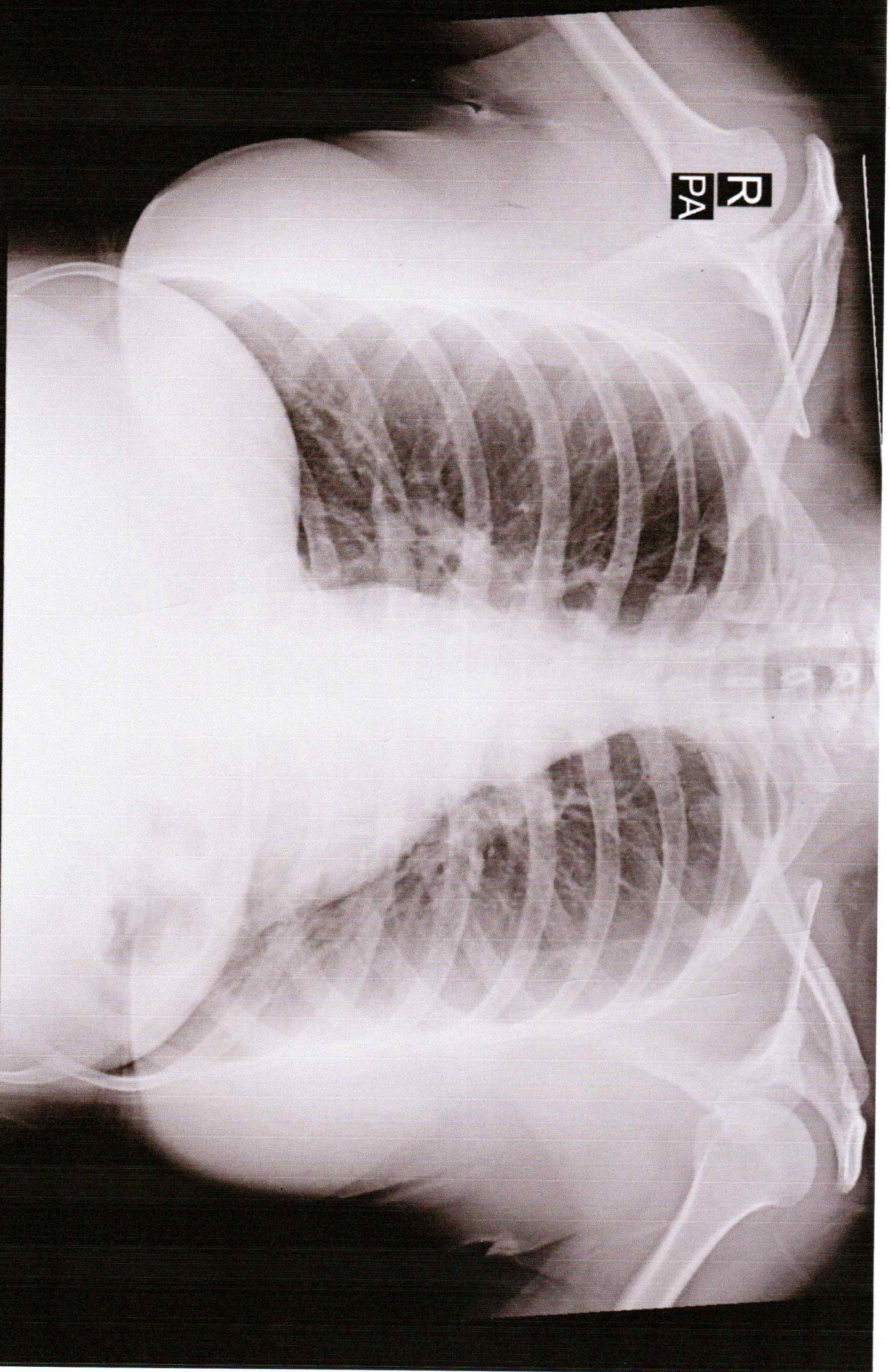
MBBS, MD (Radio Diagnosis)

Reg.No. 57557

Address : Kabir Nagar (Near Sanjay Shiksha Niketan), Durgakund, Varanasi

Mobile : 9554572190 / 9453837595 / Recpn. 9389994334

E-mail : dramishra@gmail.com, drpallaviojha@gmail.com, Website: www.piire.org



MONIKA CHAUHAN BOB 30YF 3589 O CHEST P.A. 11-Feb-23 01:02 PM

PANACEA HOSPITAL, KABIR NAGAR, DURGAKUND, VARANASI