

Aadhaar will be helpful in availing Government and Non-Government services in future .




ભારતીય વિશિષ્ટ ઓળખાણ પ્રાધિકરણ

Unique Identification Authority of India

સરનામું: પતિનું નામ: મયંકકુમાર
વનમાલિદાસ શ્રીરક. 5/બી. કૃષ્ણાનગર
સોસાયટી-1, ચોકશિવાડીની સામે, અડાજણ
રાહેર રોડ, સુરત, અડાજણ ક્ર. ગુજરાત,
395009

Address: W/O: Mayankkumar Vanmalidas
Kotak, 5/B, Krishnanagar Society-1, Opp
chokshiwadi, Adajan rander road, Surat,
Adajan Dn, Gujarat, 395009

6343 8203 8935



1947

help @ uidai.gov.in



www.uidai.gov.in

www

Retinal Screening

Check Up

Requested

Done

Requested

Done

Check Up

umber :

nt Medical &

Post-Prandial

CEM



HEALTH CHECK-UP SUMMARY

Name: Binita Kotale

Date: 27/08/2022

Email ID:

Sex: Female Age: 52 Years Contact No: 91277 579359 Remarks:

Under-weight

Normal

Over-weight

i> BMI

Height (in Cm): 154 Weight (in Kg): 64 BMI: 27 kg/m²

ii> Blood Pressure & Pulse

110/70 mmHg
72/min.

If high or low, whether the person is on medication: YES / NO

iii> Blood Tests & Lung Function Remarks

RS }
CVS }
CNS }

If abnormal, whether the person is on medication: YES / NO

iv> Eye Test Remarks

Eye test R/I 6/6 L/I 6/6

Color Vision: A

v> Heart Disease

Whether any specific heart ailment detected (ECG findings):

normal

vi> Any other problems needing attention / Overall Assessment :

HTN - 6 years.

Revival Diagnostic

401, Aqua Corridor,
B/s. Star Bazar, Surat-395009
Mo. 91062-28601

Chirag Patel
Signature of the Doctor

Dr. Chirag Patel
M.B.B.S. G-49432

Laboratory Test Result are Subject to technical limitation and should be clinically correlate for final diagnosis

4th Floor, Aqua Corridor, Hazira Road, Adajan Paal, Surat-395009.

☎ 0261 2747788

✉ revivaldiagnostics.surat@gmail.com

🌐 www.revivaldiagnostics.com

This medical report is not intended for medico-legal purposes.





NAME: Binita Kotak SEX: F
BIRTHDATE: 30/06/1970 AGE: 52

DEPARTMENT OF OPHTHALMOLOGY

EYE TEST:

1. VISION:

RIGHT EYE - 6/6

LEFT EYE - 6/6

2. COLOR VISION:

RIGHT EYE - (2)

LEFT EYE - (2)

3. FUNDUS:

RIGHT EYE - (2)

LEFT EYE - (2)

REMARKS:

(Signature)

Revival Diagnostic
401, Aqua Corridor,
B/s. Star Bazar, Surat-395009
Mo. 91062-28601

(Signature)
Ophthalmologist/Optometrist

Laboratory Test Result are Subject to technical limitation and should be clinically correlate for final diagnosis

REVIVAL DIAGNOSTICS



Dental Assessment Form

NAME Binita Kotak
AGE 30/06/1970

DATE 27-08-2022
SEX SZ

* CHIEF COMPLAINT

- A CLINICAL FEATURES :- missing tooth -
- 1 CAVIES :- NO
2 MISSING TOOTH :- lower - bilateral 2nd molar
3 MALOCCLUSION :- NO
4 FILLING :- NO
- B DIAGNOSIS :- normal
- C PERSONAL HISTORY :- (A)
- D PROVISIONAL D/G :- (A)
- E MEDICAL HISTORY :- tooth extraction,
- F FINAL D/G :- (A)
- G TREATMENT PLAN :- Filling

CLINT SIGN

DOCTOR SIGN

Binita Kotak

Revival Diagnostic
401, Aqua Corridor,
B/s. Star Bazar, Surat-395009
Mo. 91062-28601

Laboratory Test Result are Subject to technical limitation and should be clinically correlate for final diagnosis



Name : BINITA M KOTAK
Age/Sex : 52 Yrs. Female
UHID : 21317
Ref. By Dr. : MEDI WHEEL
Catagory : CTR

Date : 27-Aug-2022 8:44 am
Receipt No : 5285
Lab ID : 16997


Collection Date & Time : 27-Aug-2022 8:44 am

CBC HAEMOGRAM


PARAMETER	RESULT	UNITS	Biological Reference Range
Hemoglobin	: 11.7	gm/dL	11.5-16.4
RBC Count	: 4.99	m/c.mm.	3.9-5.6
WBC Count	: 8200	c. mm.	4,000 - 10,000
Platelet Count	: 2.69	c. mm.	1.5 Lac - 5.0 Lac
Blood Indices			
Hematocrit (PCV)	: 38.4	%	36-47 %
MCV	: 77.0	fl	75-96
MCH	: 23.4	pg	27-32
MCHC	: 30.5	g/dL	30-36
RDW	: 13.2	%	11- 16
ESR (WINTORBE)	: 08	mm./hr.	0-30 below the age of 50 yrs.
DIFF WBC Count			
Neutrophils	: 50	%	40-75
Lymphocytes	: 45	%	20-50
Eosinophils	: 03	%	1-6
Monocytes	: 02	%	2-10
Basophils	: 00	%	0-5
Band Form	: 00	%	0-5
Smear Study			
Platelets in Smear	: Adequate		
Malarial Parasites	: Malarial Parasites Not Detected		
Blood Group	: "O"		
RH Factor	: Positive		

Lab Technician/Technologist

Revival Diagnostic
401, Aqua Corridor,
B/s. Star Bazar, Surat-395009
Mo. 91062-28601


Dr. Mihir Icecreamwala
M.B.B.S.,M.D. Pathologist

Operator Name: Namrata Patel Reporting Print Date & Time: 27-Aug-2022
Lab Report Results are subject to technical limitation and should be clinically correlate for final diagnosis



REVIVAL DIAGNOSTICS



Name : BINITA M KOTAK
Age/Sex : 52 Yrs./Female
UHID : 21317
Ref. By Dr. : MEDI WHEEL

Date : 27-Aug-2022 8:44 am
Rec. No : 5285
Lab ID : 16997
Category : CTR


Collection Date & Time : 27-Aug-2022 8:44 am

BIOCHEMISTRY

TEST	RESULTS	Unit	BIOLOGICAL REFERENCE RANGE
GGT <i>IFCC, Without Pyridoxal Phosphate</i>	: 25	U/L	5 - 50 U/L
SGOT <i>IFCC, Without Pyridoxal Phosphate</i>	: 20	U/L	0 - 50 U/L
SGPT <i>IFCC, Without Pyridoxal Phosphate</i>	: 20	U/L	0 - 50 U/L
Alkaline Phosphatase <i>ALP-AMP</i>	: 111	IU/l	38 - 126 IU/l
Total Bilirubin <i>DIAZO METHOD</i>	: 0.3	mg/dl	0.2 - 1.2 mg/dl
Direct Bilirubin <i>DIAZO METHOD</i>	: 0.1	mg/dl	0.1 - 0.4 mg/dl
Indirect Bilirubin <i>CALCULATED</i>	: 0.2	mg/dl	0.1 - 0.8 mg/dl
Blood Urea Nitrogen (BUN) <i>GLDH-UREASE METHOD</i>	: 11	mg/dl	9 - 20 mg/dl
Creatinine <i>(METHOD : ENZYMATIC)</i>	: 0.5	mg/dl	0.5 - 1.5 mg/dl
Uric Acid <i>URICASE-POD</i>	: 7.3	mg/dl	2.7 - 7.3 mg/dl
Blood Sugar - F	: 128	mg/dL	70 - 110 mg/dL
Urine Sugar - F	: Absent		
Urine Ketone - F	: Absent		
Blood Sugar- PP	: 139	mg/dL	80 - 140 mg/dL
Urine Sugar - PP	: Absent		
Urine Ketone - PP	: Absent		
Total Protein <i>Biuret</i>	: 6.8	gm/dl	6.3 - 8.2 gm/dl
S.Albumin	: 3.9	gm/dl	3.7 - 5.3 gm/dl

Revival Diagnostic

401, Aqua Corridor,
B/s. Star Bazar, Surat-395009
Mo. 91062-28601


Dr. Mihir Icecreamwala
M.B.B.S., M.D. Pathologist

Reporting Date & Time : 27-Aug-2022 04:24:00PM

Test Performed On Fully Automated Clinical Chemistry Analyser EM-200

Laboratory Test Result are Subject to technical limitation and should be clinically correlate for final diagnosis

📍 4th Floor, Aqua Corridor, Hazira Road, Adajan Paal, Surat-395009.
☎ 0261 2747788 ✉ revivaldiagnostics.surat@gmail.com 🌐 www.revivaldiagnostics.com

This medical report is not intended for medico-legal purposes.

REVIVAL DIAGNOSTICS



BCG(Bromo Cresol Green)

Globulin CALCULATED	: 2.9	gm/dl	2.4 - 3.2 gm/dl
A/G Ratio CALCULATED	: 1.34	gm/dl	1 - 2.3 gm/dl



Revival Diagnostic

401, Aqua Corridor,
B/s. Star Bazar, Surat-395009
Mo. 91062-28601

Dr. Mihir Icecreamwala
M.B.B.S.,M.D. Pathologist

Reporting Date & Time : 27-Aug-2022 04:24:00PM

Test Performed On Fully Authomated Clinical Chemistry Analyser EM-200

Laboratory Test Result are Subject to technical limitation and should be clinically correlate for final diagnosis

📍 4th Floor, Aqua Corridor, Hazira Road, Adajan Paal, Surat-395009.
☎ 0261 2747788 ✉ revivaldiagnostics.surat@gmail.com 🌐 www.revivaldiagnostics.com

This medical report is not intended for medico-legal purposes.



Name : BINITA M KOTAK
Age/Sex : 52 Yrs. Female
UHID : 21317
Ref. By Dr. : MEDI WHEEL
Catagory : CTR

Date : 27-Aug-2022
Receipt No : 5285
Lab ID : 16997


Collection Date & Time : 27-Aug-2022 8:44 am

REPORT OF SERUM LIPID PROFILE

Test	Result	Biological Reference Range	
Serum Cholesterol (Mehod : CHOD-POD)	231	Normal	: Less than 200 mg / dl
		Borderline	: 200 to 239 mg / dl
		Undesirable	: More than 240 mg / dl
Serum Triglyceride (Mehod : GPO-POD)	289	Normal	: Less than 150 mg / dl
		Borderline High	: 150 to 199 mg / dl
		High	: 200 - 499 mg / dl
		Very High	: More than 500 mg / dl
Serum HDL - Cholesterol (Mehod : PVS-PEGME Precipitation with CHOD-POD)	47	Desirable	: More than 65 mg / dl
		Borderline	: 45 to 65 mg / dl
		Undesirable	: Less than 45 mg / dl
Serum LDL - Cholesterol (Mehod : Calculated)	126.2	Optimal	: Less than 100 mg / dl
		Above Optimal	: 100 - 129 mg / dl
		Borderline High	: 130 to 159 mg / dl
		High	: 160 to 189 mg / dl
		Very High	: More than 190 mg / dl
VLDL (Mehod : Calculated)	57.8	Normal	: 5 to 30 mg / dl
Chol. / HDL - Chol. Ratio	4.9	Low Risk	: Less than 3.1
		Vedium Risk	: 3.1 to 5.9
		High Risk	: More than 6
LDL / HDL - Chol. Ratio	2.69	Low Risk	: Less than 3.55
		Medium Risk	: 3.55 - 4
		High Risk	: More than 6

Lab Technician/Technologist

Revival Diagnostic
 401, Aqua Corridor,
 B/s. Star Bazar, Surat-395009
 Mo. 91062-28601


 Dr. Mihir Icecreamwala
 M.B.B.S..M.D. Pathologist

Operator Name: Zarna Gandhi

Reporting PrintDate & Time: 27-Aug-2022

Laboratory Test Result are Subject to technical limitation and should be clinically correlate for final diagnosis

1999

1998

1997

1996

1995

1994

1993

1992

1991

1990

1989



Name : BINITA M KOTAK
Age/Sex : 52 Yrs. / Female
UHID : 21317
Category : CTR
Ref. By Dr. : MEDI WHEEL

Date : 27-Aug-2022 8:44 am
Receipt No : 5285
Lab ID : 16997
Collection Date & Time : 27-Aug-2022 8:44 am

ROUTINE URINE EXAMINATION REPORT

PHYSICAL EXAMINATION :

Quantity : 30 ml
Colour : Pale Yellow
Appearance : Clear
Reaction : Acidic
Specific Gravity : 1.020

CHEMICAL EXAMINATION :


Proteins : Absent
Sugar : Absent
Acetone : Absent
Bile Salts : Absent
Bile Pigments : Absent
Urobilinogen : Normal
O.B.T. : Negative

MICROSCOPIC EXAMINATION :

Pus Cells : 2-3/hpf.
R. B. C. : Absent
Epithelial Cells : 1-2/hpf.
Bacteria : Absent
Casts : Absent
Crystals : Absent
Yeast cell : Absent
Mucus : Absent
Other Findings : NIL

Lab Technician/Technologist

Revival Diagnostic
401, Aqua Corridor,
B/s. Star Bazar, Surat-395009
Mo. 91002-28601


Dr. Mihir Icecreamwala
M.B.B.S.,M.D. Pathologist

Laboratory Test Result are Subject to technical limitation and should be clinically correlate for final diagnosis

Operator Name: Zafar Khan, Aqua Corridor, Hazira Road, Surat-395009, Reporting Print Date & Time: 27-Aug-2022 01:39:00PM
☎ 0261 2747788 ✉ revivaldiagnostics.surat@gmail.com 🌐 www.revivaldiagnostics.com

This medical report is not intended for medico-legal purposes.



Name : BINITA M KOTAK

Date : 27-Aug-2022

Age/Se : 52 Yrs. Female

12:00:00AM

UHID : 21317

Receipt No: 5285

Ref. By : MEDI WHEEL

Lab ID : 16997

Category : CTR

Collection Date & Time : 27-Aug-2022 8:44 am

STOOL EXAMINATION

GENERAL EXAMINATION

Consistency : Semi Solid
Color : Brown
Mucus : Absent
Pus : Absent
Blood : Absent

CHEMICAL EXAMINATION

Reaction : Acidic
Occult Blood : Absent

MICROSCOPIC EXAMINATION

Ova : Absent
Cysts : Absent
Pus Cells : Absent / Hpf.
Red Blood Cells : Absent / Hpf.
Macrophage Cells : Absent
Epithelial Cells : Absent / Hpf.
Starch : Absent
Vegetable cells : Absent
Crystals : Absent

Revival Diagnostic

401, Aqua Corridor,
B/s. Star Bazar, Surat-395009
Mo. 91062-28601

Lab Technician/Technologist
Zarna K Gandhi (Msc. Biotech)

Pathologist/ Pathologist
Dr. Mihir icecearmwala /Dr. Sodavadiya Kirankumar

Operator Name : Zarna Gandhi

Reporting Print Date & Time : 27-Aug-2022

Laboratory Test Result are Subject to technical limitation and should be clinically correlate for final diagnosis

4th Floor, Aqua Corridor, Hazira Road, Adajan Paal, Surat-395009.

0261 2747788

revivaldiagnostics.surat@gmail.com

www.revivaldiagnostics.com

This medical report is not intended for medico-legal purposes.



Name : BINITA M KOTAK
Age/Sex : 52 Yrs. Female
UHID : 21317
Ref. By Dr. : MEDI WHEEL
Category : CTR

Date : 27-Aug-2022 8:44 am
Receipt No : 5285

Lab ID : 16997
Collection Date & Time : 27-Aug-2022 8:44 am


THYROID TEST

TEST	RESULT	Biological Reference Range
T3	0.95	0.87 - 1.78 ng/ml
T4	9.14	4.60 - 13.5 ug/dl
TSH	2.61	0.50 - 5.50 uIU/ml 5.5 to 15 uIU/ml - Suggested Clinical co-relation Or Repeat test with new sample as physiological factors can give falsely high TSH Above 15uIU/ml Hypothyroid

PREGNANT WOMEN normal ranges for TSH:
1st Trimester :0.0878 - 2.8293 uIU/ml
2nd Trimester :0.1998 - 2.7915 uIU/ml
3rd Trimester :0.307 - 2.9028 uIU/ml
Ref:Tietz Fundamentals of Clinical Chemistry.

Lab Technician/Technologist

Revival Diagnostic
401, Aqua Corridor,
B/s. Star Bazar, Surat-395009
Mo. 91062-28601


Dr. Mihir Icecreamwala
M.B.B.S.,M.D. Pathologist

Operator Name : Zarna Gandhi

Reporting Print Date & Time : 27-Aug-2022

Laboratory Test Result are Subject to technical limitation and should be clinically correlate for final diagnosis

REVIVAL DIAGNOSTICS



Name : BINITA M KOTAK

Date : 27-Aug-2022

Age/Sex : 52 Yrs. Female

Receipt No : 5285

UHID : 21317

Ref. By Dr. : MEDI WHEEL

Lab ID : 16997

Report By Dr. : Dr.

Catagory : CTR

Collection Date & Time : 27-Aug-2022 8:44 am

REPORT OF GLYCOSYLATED HEMOGLOBIN [HbA1C]

Parameter	Result	Unit	Biological Reference Interval
Hemoglobin A1C(HbA1C)	8.2	%	HbA1C Degree of Glucose Control

< 5.6 % Non Diabetics
5.7 - 6.4 % Prediabetics
> = 6.5 % Diabetics

(REF : Wallace, 11th Edition)

REMARKS:

6 - 7 % Excellent Control
7 - 8 % Good Control
8 -10 % Unsatisfactory Control
> 10 % Poor Control

Method : High performance liquid chromatography (HPLC)


MEAN BLOOD GLUCOSE OVER THE PAST 60 DAYS FROM THE HbA1C RESULT : 000 mg/dl

Remarks : GHb test is useful for the long term control and monitoring of diabetes mellitus since it reflects the integration of blood glucose levels during past 4-8 weeks.

Revival Diagnostic

401, Aqua Corridor,
B/s. Star Bazar, Surat-395009
Mo. 91062-28601

Lab Technician/Technologist


Dr. Mihir Icecreamwala
M.B.B.S..M.D. Pathologist

Operator Name :Zarna Gandhi

Reporting Print Date & Time :27-Aug-2022

Laboratory Test Result are Subject to technical limitation and should be clinically correlate for final diagnosis

☎ 0261 2747788

✉ revivaldiagnostics.surat@gmail.com

🌐 www.revivaldiagnostics.com

This medical report is not intended for medico-legal purposes.

📍 4th Floor, Aqua Corridor, Hazira Road, Adajan Paal, Surat-395009.



NAME	BINITA KOTAK	DATE	27-Aug-22
REFERRED BY	MEDI WHEEL	AGE / SEX	52 YRS / F

Thanks for the reference

USG ABDOMEN AND PELVIS

LIVER: is normal in size and shows increased echotexture.

No evidence of intrahepatic biliary radicles dilatation / focal space occupying lesion.

The portal vein and common bile duct shows normal caliber.

GALL BLADDER: is distended and shows smooth walls. Wall thickness is normal.

No evidence of sludge / calculus. No evidence of pericholecystic collection.

SPLEEN: Is normal in size and shows normal echo pattern.

PANCREAS: shows normal echo anatomy and its relationship with splenic vein is normal.

KIDNEYS: Both the kidneys are normal in size, shape and location and show normal cortico-medullary differentiation.

Right kidney measures- 9.5 x 4.0 cms.

Left kidney measures- 9.7 x 4.2 cms.

No evidence of hydronephrosis or calculus.

URINARY BLADDER: is distended with smooth walls.

No evidence of diverticulum or calculus.

UTERUS: is anteverted and shows normal endometrial echo reflectivity.

OVARY: Both ovaries are normal in size and appear normal.

No evidence of ascites or pleural effusion.

Fluid and gas filled bowel loops with normal wall thickness and peristalsis noted.

IMPRESSION:

- Fatty Liver - Grade I

Dr. Chirag K. Patel
M.B.B.S-D.M.P.D.
REG. NO. G-23509
Revival Diagnostics
DR. CHIRAG K. PATEL
RADIOLOGIST
4th Floor, Aqua Corridor,
Nr. Star Bazar, Hazira Main Road,
Adajan, Surat-395009.
Mo. 97266 726683

Laboratory Test Result are Subject to technical limitation and should be clinically correlate for final diagnosis

4th Floor, Aqua Corridor, Hazira Road, Adajan Paal, Surat-395009.

0261 2747788

revivaldiagnostics.surat@gmail.com

www.revivaldiagnostics.com

This medical report is not intended for medico-legal purposes.



NAME	BINITA KOTAK	DATE	27-Aug-22
REFERRED BY	MEDI WHEEL	AGE / SEX	52 YRS / F

Thanks for the reference

SONOMAMMOGRAPHY OF BOTH BREAST - SCREENING

There is no evidence of obvious mass lesion in both the breasts.

The glandular and fatty tissue shows normal appearance.

There is no evidence of skin thickening noted.

There is no evidence of enlargement of axillary lymph node on both sides.

IMPRESSION :

- normal study

Dr. Chirag K. Patel

MRBS-DMPD

Reg. No. G-23509

RDR CHIRAG K. PATEL

RADIOLOGIST

4th Floor, Aqua Corridor,
Nr. Star Bazar, Hazira Main Road,

Adajan, Surat-395009.

Mo. 97266 726683

Laboratory Test Result are Subject to technical limitation and should be clinically correlate for final diagnosis

4th Floor, Aqua Corridor, Hazira Road, Adajan Paal, Surat-395009.

0261 2747788

revivaldiagnostics.surat@gmail.com

www.revivaldiagnostics.com

This medical report is not intended for medico-legal purposes.

R

NAME: BINITA M KOTAK
AGE: 52 YRS / FEMALE
REF BY: MEDI WHEEL





Name : BINITA M KOTAK
Age/Sex : 52 Yrs. Female
UHID : 21317
Ref. By Dr : MEDI WHEEL
Category : CTR

Date : 27-Aug-2022
Rec No : 5285

Lab ID : 16997

Collection Date & Time : 27-Aug-2022 8:44 am

CHEST RADIOGRAPH-PA VIEW

Hilar shadows are within normal limits.

Pulmonary vasculature appears normal.

Cardiac appears normal in size.

Both domeh of the diaphragm are smooth.

Both costophrenic recesses are clear.

Both lung fields appear normal.

Visualized bones and soft tissue shadows appear normal.

IMPRESSION:

NORMAL STUDY.

Dr. Chirag K. Patel

MBBS-DMPD

Reg. No. G-23509

Revival Diagnostic

DR. CHIRAG K. PATEL

Nr. Star Bazar, Hazira Road, Adajan, Surat-395009.

RADIOLOGIST

Mo. 97266 726683

Laboratory Test Result are Subject to technical limitation and should be clinically correlate for final diagnosis

📍 4th Floor, Aqua Corridor, Hazira Road, Adajan Paal, Surat-395009.

☎ 0261 2747788

✉ revivaldiagnostics.surat@gmail.com

🌐 www.revivaldiagnostics.com

This medical report is not intended for medico-legal purposes.



Name : BINITA M KOTAK
Age/Sex : 52 Yrs. Female
UHID : 21317
Ref. By Dr : MEDI WHEEL
Category : CTR

Date : 27-Aug-2022
Rec No : 5285

Lab ID : 16997

Collection Date & Time : 27-Aug-2022 8:44 am

CHEST RADIOGRAPH-PA VIEW

Hilar shadows are within normal limits.

Pulmonary vasculature appears normal.

Cardiac appears normal in size.

Both domeh of the diaphragm are smooth.

Both costophrenic recesses are clear.

Both lung fields appear normal.

Visualized bones and soft tissue shadows appear normal.

IMPRESSION:

NORMAL STUDY.

Dr. Chirag K. Patel

MBBS-DMPD

Reg. No. G-23509

Revival Diagnostic

DR. CHIRAG K. PATEL

Nr. Star Bazar, Hazira Road, Adajan, Surat-395009.

RADIOLOGIST

Mo. 97266 726683

Laboratory Test Result are Subject to technical limitation and should be clinically correlate for final diagnosis

4th Floor, Aqua Corridor, Hazira Road, Adajan Paal, Surat-395009.

0261 2747788

revivaldiagnostics.surat@gmail.com

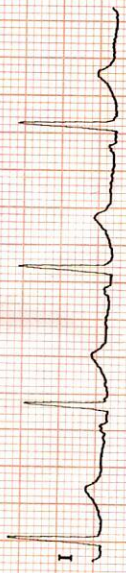
www.revivaldiagnostics.com

This medical report is not intended for medico-legal purposes.

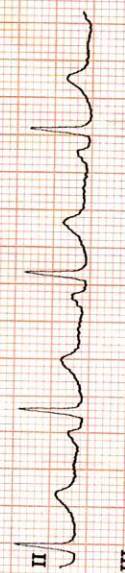
10mm/mV

AUTO

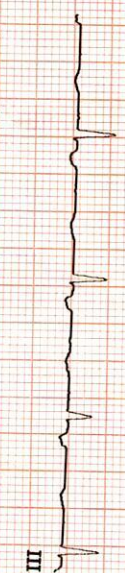
I



II



III



25mm/s

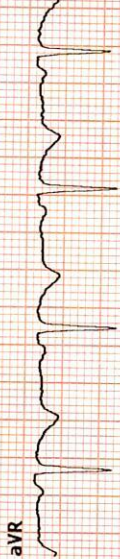AC-ON 0.05-35Hz

ARROW CE

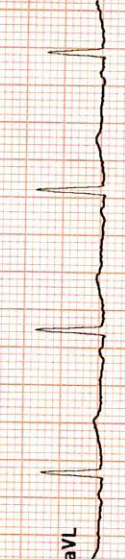
REDIUS8 CARDIAC

10mm/mV

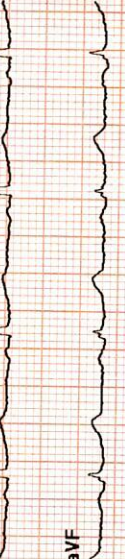
aVR



aVL

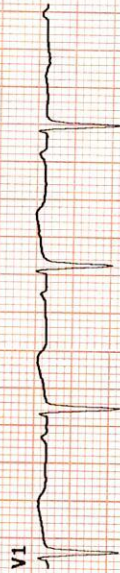

aVF

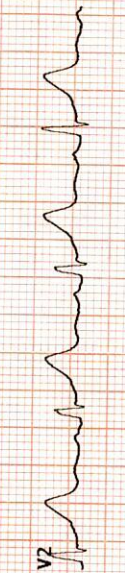


10mm/mV

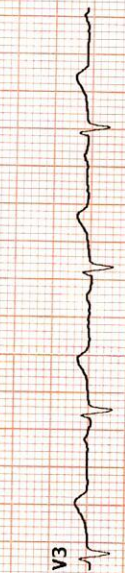V1



V2

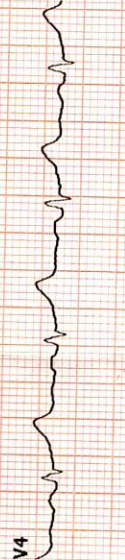

V3

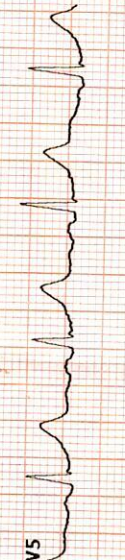

10mm/mV

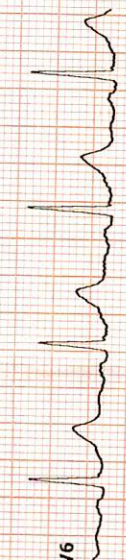V4



V5



V6



25mm/s

ARROW CE

2022-8-27 9:02:59

ID Card:

ID: 00002744

Name: BINITA M KOTAK

Gender: Female

Age: 52

Height(cm): 154

Weight(Kg): 64

BP(mmHg): /

HR.....bpm 80

P-R.....ms 116

Q-R-S.....ms 76

QT/QTc.....ms 410/473

P/QRS/T AXES.....deg 54/13/54

RV5/SV1.....mV 0.62/0.88

RV5+SV1.....mV 1.50

*The result must be confirmed by doctor!

Report Confirmed by: DR ADITI PATEL

Aditi Patel

Revival Diagnostic

401, Aqua Corridor,

B/s. Star Bazar, Surat-395009

Mo. 91062-28601

DR. ADITI PATEL
M.B.B.S., D. CARD (MUM)
CLINICAL CARDIOLOGIST
REG. NO. G-42901.

WILSON
WILSON
WILSON

WILSON
WILSON
WILSON

REVIVAL DIAGNOSTICS



Name : BINITA M KOTAK
Age/Sex : 52 Yrs. Female
UHID : 21317
Ref. By Dr : MEDI WHEEL
Category : CTR

Date : 27-Aug-2022
Rec No : 5285

Lab ID : 16997

Collection Date & Time : 27-Aug-2022 8:44 am

Test	Observed Value	Biological Reference Interval
ECG		

1. The rhythm is sinus.
2. Heart rate is 80 beats per minute.
3. Normal P,QRS,T wave axis.
4. Normal PR,QRS,Q.T. Duration.
5. No pathological q wave or ST-T changes seen.
6. No evidence of chamber hypertrophy or enlargement seen.

IMPRESSION : ECG WITHIN NORMAL LIMITS.

DR. ADITI PATEL
M.B.B.S., D. CARD (MUM)
CLINICAL CARDIOLOGIST
REG.NO.G-42901

Revival Diagnostic
401, Aqua Corridor,
B/s. Star Bazar, Surat-395009
Mo. 91062-28601

Laboratory Test Result are Subject to technical limitation and should be clinically correlate for final diagnosis

📍 4th Floor, Aqua Corridor, Hazira Road, Adajan Pal, Surat-395009.
☎ 0261 2747788, 9825947712 ✉ revivaldiagnostics.surat@gmail.com 🌐 www.revivaldiagnostics.com
This medical report is not intended for medico-legal purposes.

Faint, illegible text or markings in the lower-left quadrant.

Faint, illegible text or markings in the center-right area.



binita kotak
27.08.2022 08:43:18

805	21-Aug-22
806	21-Aug-22

તમારો આધાર નંબર / Your Aadhaar No. :

6343 8203 8935

મારો આધાર, મારી ચોળખ



15009



ભારત સરકાર

Government of India

બિનીતા મયાંકકુમાર કોટક

Binita Mayankkumar Kotak

જન્મ તારીખ / DOB : 30/06/1970

સ્ત્રી / Female



6343 8203 8935

મારો આધાર, મારી ચોળખ

Patient Name
Age / Sex
Height :
Address
Name of D
Location /
Insurance

Date & Time of Sample Collection :
Blood / Serum / Plasma / Urine /

21-10-2022 Time of Sample
Stool / Sputum

3010613970

action : _____



2D-ECHOCARDIOGRAPHY & COLOR DOPPLER REPORT

Name:	BINITA KOTAK	Age/Gender	52Yrs /Female
Referred by.	MEDI WHEEL	Date	27/08/2022

VITALS: BP = 110/70mmHg, PULSE =72 bpm, SPO2 =98%

INDICATION: Preventive Health check up

- **CARDIAC CHAMBERS:** Left Ventricle: Normal size, Left Atrium: Normal size.
- No e/o thrombus in LA/LV.
- **Right Atrium:** Normal size. **Right Ventricle:** Normal size,
- **Normal Right Ventricular function.** (TAPSE=20mm)
- **Normal Left Ventricular systolic function. LVEF = 60% ,**
No regional wall abnormality. No thinning / scarring / dyskinesia of LV wall.
- **No Concentric Left Ventricular Hypertrophy.** (IVSd= 11 mm),
- **Grade I / IV Left Ventricular Diastolic Dysfunction [LVDD].**
- No Doppler evidence of raised LVEDP (E/E'= 7)
- **LV Compliance :**
No Left Ventricular Diastolic Dysfunction [LVDD]. No Doppler e/o raised LVEDP.
- **VALVES:**
- Structurally Normal Mitral valve/ Aortic valve/Tricuspid valve/ Pulmonary valve .
No significant Valvular Stenosis.
- **Doppler findings:** AV max = 1.22 m/s, PV max = 0.91 m/s.
Trivial Pulmonary Regurgitation, Trivial Tricuspid regurgitation.
- **No Pulmonary Arterial Hypertension. PASP** by TRjet vel.method = 23 mmHg.
- **SEPTAE:** IAS / IVS Appear Intact.
- **IVC :** Normal in dimension and shows good inspiratory 15mm collapse.
- **OTHERS:** No e/o Pericardial effusion / vegetation.

IMPRESSION:

**NORMAL LV SYSTOLIC FUNCTION, LVEF= 60 %, NO RWMA,
NO LVH , GRADE I LVDD ,TRIVIAL PR/TR, NO PAH.**

Revival Diagnostic
401, Aqua Corridor,
B/s. Star Bazar, Surat-395009
Mo. 91062-28601

DR SUSHIL YADAV
CONSULTING & CLINICAL
CARDIOLOGIST

Laboratory Test Result are Subject to technical limitation and should be clinically correlate for final diagnosis

📍 4th Floor, Aqua Corridor, Hazira Road, Adajan Pal, Surat-395009.

☎ 0261 2747788, 9825947712 ✉ revivaldiagnostics.surat@gmail.com 🌐 www.revivaldiagnostics.com

This medical report is not intended for medico-legal purposes.

