

Mediwheel



भारत सरकार
Unique Identification Authority of India
Government of India

नोंदणी क्रमांक:/ Enrolment No.: 2722/40027/00758


Download Date: 10/09/2019

To
प्रीती कुमारी
Preeti Kumari
D/O: Ramjitt Prasad
85/1,deen dayal nagar
senior MIG 23,HOUSING BOARD COLONY
Itarsi
Itarsi
Hoshangabad Madhya Pradesh - 461111
9820992892

Generation Date: 17/01/2013

Signature valid

Digitally signed by
UNIQUE IDENTIFICATION
AUTHORITY OF INDIA 04
Date: 2019.09.10 20:02:47
IST



QR Code with Photograph

a/f

Prasad

आपला आधार क्रमांक / Your Aadhaar No. :

2919 7664 4426

VID : 9150 9222 3981 9909

माझे आधार, माझी ओळख



भारत सरकार
Government of India




प्रीती कुमारी
Preeti Kumari
जन्म तारीख/DOB: 21/05/1992
महिला/ FEMALE

2919 7664 4426

VID : 9150 9222 3981 9909

माझे आधार, माझी ओळख



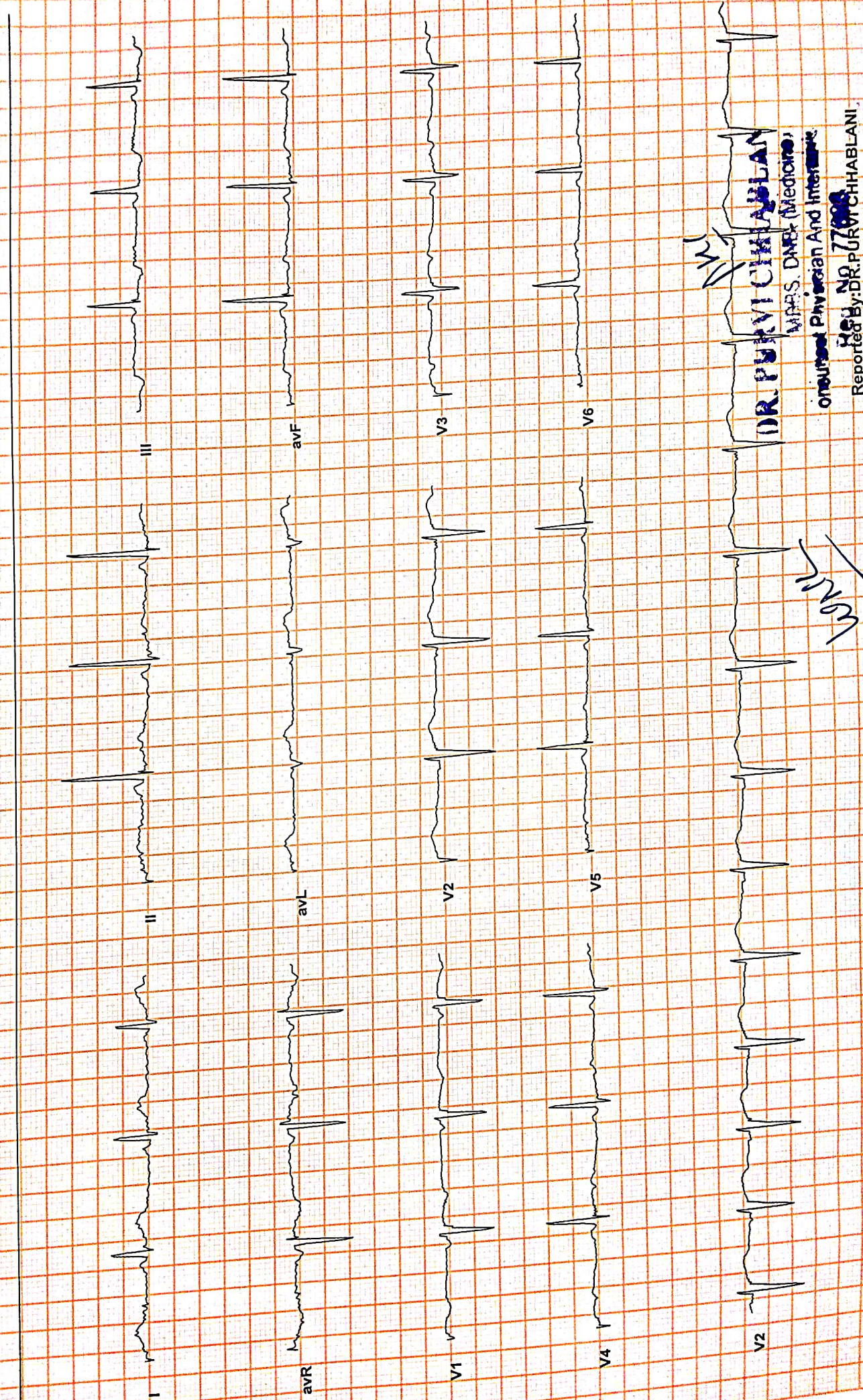
DR. PLUS HEALTHCARE CENTRE
NATTANI HEIGHTS, 3-WING,
MUMBAI CENTRAL (EAST)

DR. HARI CHHABLANI
M.B.B.S.F.C.C.P.(RESP.MEDICINE) PGDHHM, PGDMLS
RESPIRATORY & ALLERGIC CARE

PLUS HEALTHCARE CENTRE - MUMBAI CENTRAL

ECG

12-Mar-22 12:06:30 / HF 0.05 Hz - LF 100 Hz / Notch 50 Hz / Sn 1.00 Cm/mV / Sw 25 mm/s



12/3/22

DR. PURVI CHHABLANI

M.D. (Medicine)

General Physician And Internist

Reported By: DR. PURVI CHHABLANI



Dr-Plus Healthcare Centre

NATHANI HEIGHTS, B-Wing, Shop No. 42, Ground Floor, Opp. Mumbai Central Station (East), Mumbai - 400 008.

NAME : PREETI KUMARI

29/F

DATE:12/03/2022

REF BY : DR. HARI CHHABLANI

2D-ECHO. AND COLOR DOPPLER REPORT

- NORMAL CARDIAC VALVES WITH TRIVIAL TR.
- NORMAL CARDIAC CHAMBERS
- NO E/O REGIONAL WALL MOTION ABNORMALITY. WITH NORMAL LVEF OF 62 %.
- NO E/O PULMONARY HYPERTENSION .PASP 33 mmHg by TR jet.
- NO E/O LEFT VENTRICULAR HYPERTROPHY.
- NO E/O DIASTOLIC DYSFUNCTION.
- NO E/O PERICARDIAL EFFUSION.
- NO E/O INTRACARDIAC CLOT OR VEGETATION
- INTACT IAS / IVS

- CONVENTIONL DOPPLER :

E TO A RATIO IS MORE THAN ONE IN LV INFLOW.

THERE IS NO GRADIENT ACROSS AV,LVOT OR RVOT

PASP FROM TR JET IS 33 mm OF Hg.

- COLOUR DOPPLER:

TRIVIAL TR

EF Slope	108	mm/sec		
Opening Amplitude	23			
Posterior leaflet				
E.P.S.S	02	mm		
Mitral valve prolapse				
Vegetations				
TRICUSPID VALVE	OBSERVED	NORMAL VALUES		
PULMONARY VALVE	OBSERVED	NORMAL VALUES		
EF Slope				
'A' Wave				
Midsystolic notch				
Flutter				
Other Findings				
AORTIC VALVE	OBSERVED	NORMAL VALUES		
Cuspal opening	18	mm		
Closure line	Central			
Eccentricity index	1			
Other Findings				
DIMENSIONS	OBSERVED	NORMAL VALUES		
1. Lvd (Diastolic)	40	26-52		
2. Lvd (Systolic)	28	24-42mm		
3. RVD (Diastolic)	16	7-23mm		
4. IVST (Diastolic)	09	6-11mm		
5. IVST (Systolic)	15			
6. LVPWT (Diastolic)	09	6-11mm		
7. LVPWT (Systolic)	15			
8. Aortic root	27	22-37mm		
9. left Atrium	33	19-40mm		
	STRUCTURE	REGURG GRADING	VELOCITY m/sec	STENOSIS GRADIENT mm/Hg
			Max mean	Peak mean
MITRAL VALVE	NORMAL	0/3	/	/
TRICUSPID VELVE	NORMAL	TRIVIAL	/	/
PULMONARY VELVE	NORMAL	0/4	/	/
AORTIV VALVE	NORMAL	0/4	/	/

"DR. PLUS HEALTHCARE CENTRE"
NATHANI HEIGHTS', B-WING,
42, MUMBAI CENTRAL (EAST)

DR. P.H. CHHABLANI
M.B.B.S, DNB.(MEDICINE)
CONSULTANT PHYSICIAN AND CARDIOLOGIST.

DR. PURVI CHHABLANI

MDBS, DNB- (Medicine)
Consultant Physician And Intensive

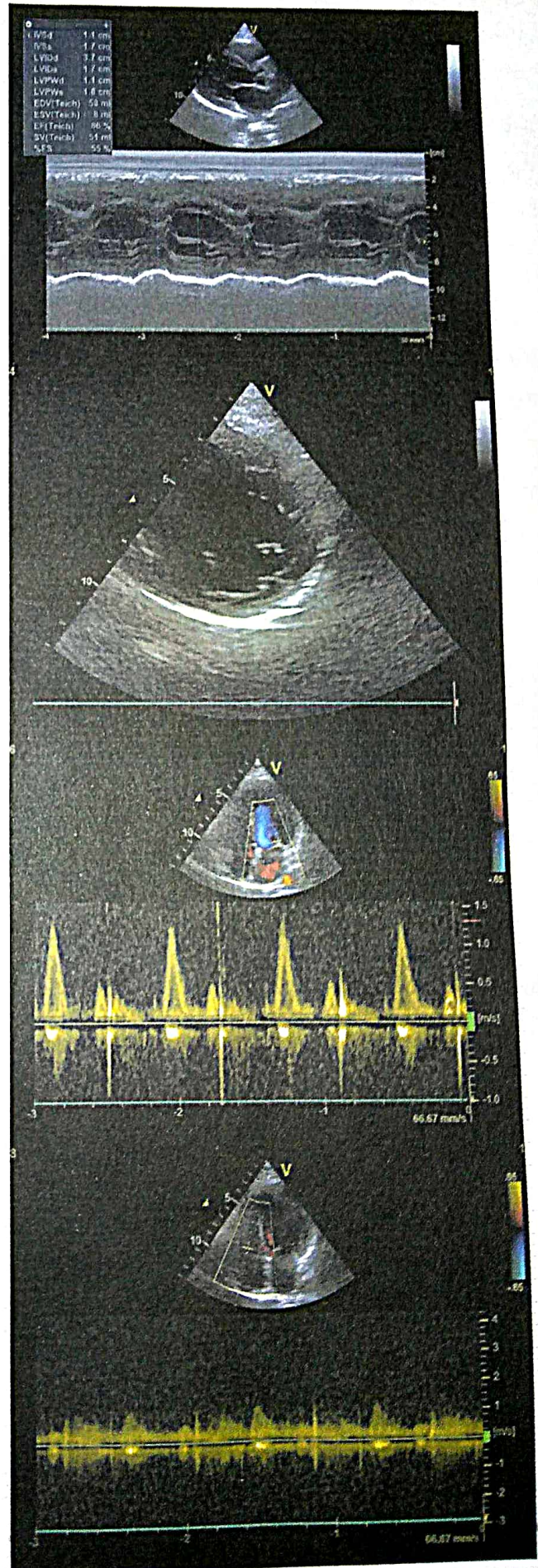
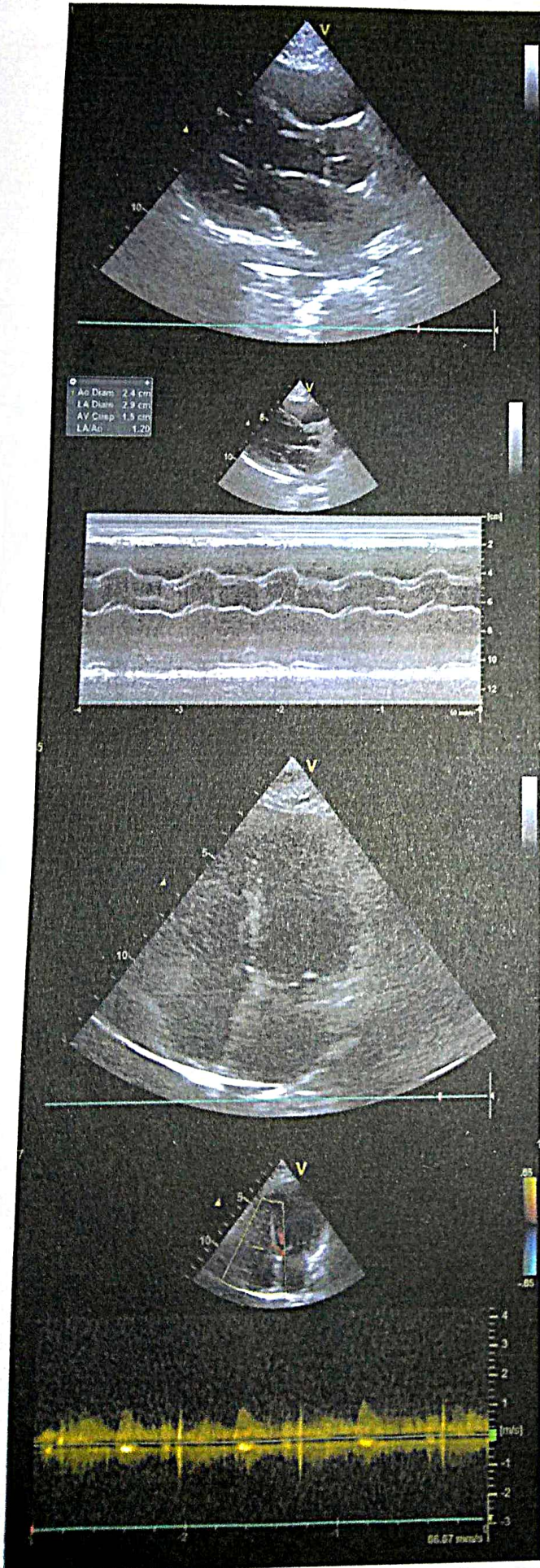
Reg No 77696

Name PREETI KUMARI

Sex Female

Age 29

Date 12/03/2022





Dr-Plus Healthcare Centre

NATHANI HEIGHTS, B-Wing, Shop No. 42, Ground Floor, Opp. Mumbai Central Station (East), Mumbai - 400 008.

Patient Name	:	PREETI KUMARI	Sex:	FEMALE
Doctor's Name	:	DR. HARI CHHABLANI	Age:	29
Date	:	12/03/2022		

ULTRASONOGRAPHY OF THE ABDOMEN AND THE PELVIS:

The relevant sonographic findings include the following:

HEPATOBIILIARY APPARATUS

The liver is normal in size and echogenicity. No obvious focal parenchymal lesion is seen. Intrahepatic biliary radicals are not dilated. The portal vein and the common bile duct are normal.

GALL BLADDER

The gall bladder is adequately distended. The wall thickness is normal. No echogenic contents are noted in its lumen. There is no pericholecystic collection noted.

PANCREAS

The pancreas shows normal echogenicity and size. No focal or diffuse lesions are noted. No evidence of calcification is noted.

SPLEEN

The spleen appears normal in size and echogenicity. No focal or diffuse lesions are noted. No evidence of calcification is noted.

KIDNEYS

Right kidney measures : 9.76 x 3.3 cm , Left kidney measures : 10.2 x 3.6 cm.

Both the kidneys appear normal in size, shape and echogenicity. Both the pelvicalyceal system is normal and both corticomedullary differentiations are well maintained. There is no obvious focal or diffuse lesion noted.

No evidence of any calculus seen in either kidney.

URINARY BLADDER

The urinary bladder shows anechoic contents. Its wall thickness appears normal.

UTERUS

Uterus measures = 5.13 x 2.6 x 3.4 cms.

The uterus is anteverted and normal in size. There are no focal or diffuse lesions noted.

The endometrium appears normal (6.6 mm).

OVARIES


Both the ovaries appear normal in size.

Right ovary measures :3.3 x 3.6 Cm , Left ovary measures :3.4 x 4.0 cm

There is no obvious evidence of abdominal or pelvic lymphadenopathy or ascites .

No other obvious pelvic mass is seen. No probe-tenderness is noted.

IMPRESSION: No significant abnormality is detected.


DR. VICTOR X. COUTINNO
(MBBS, DMRE)

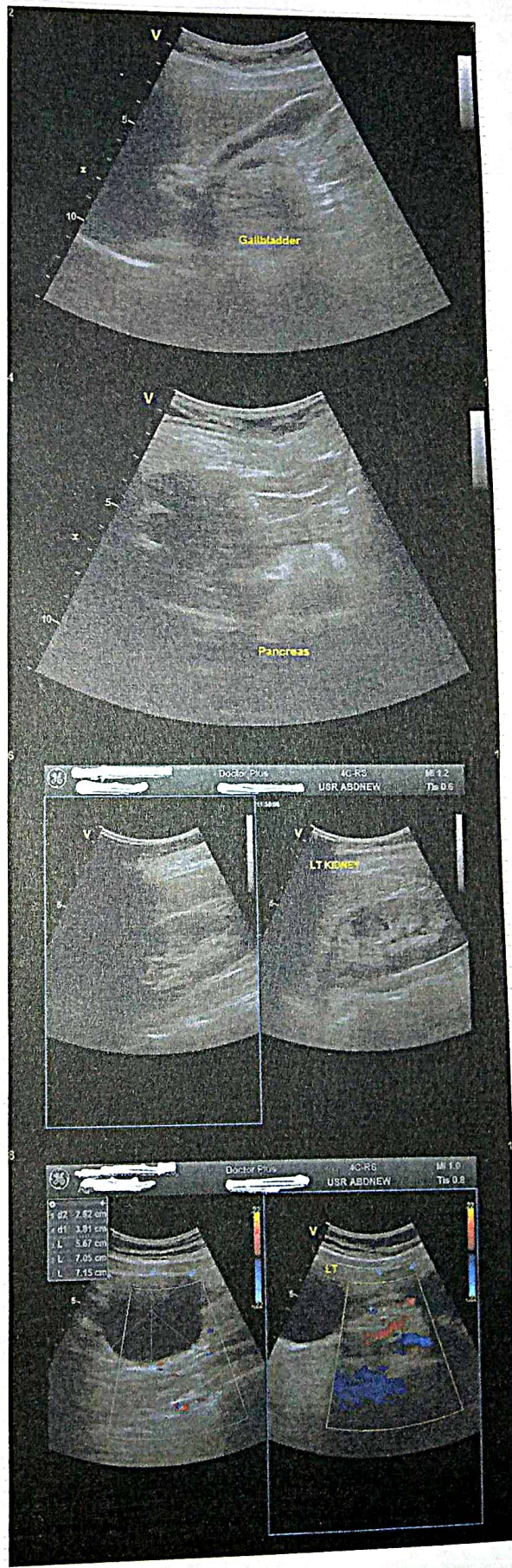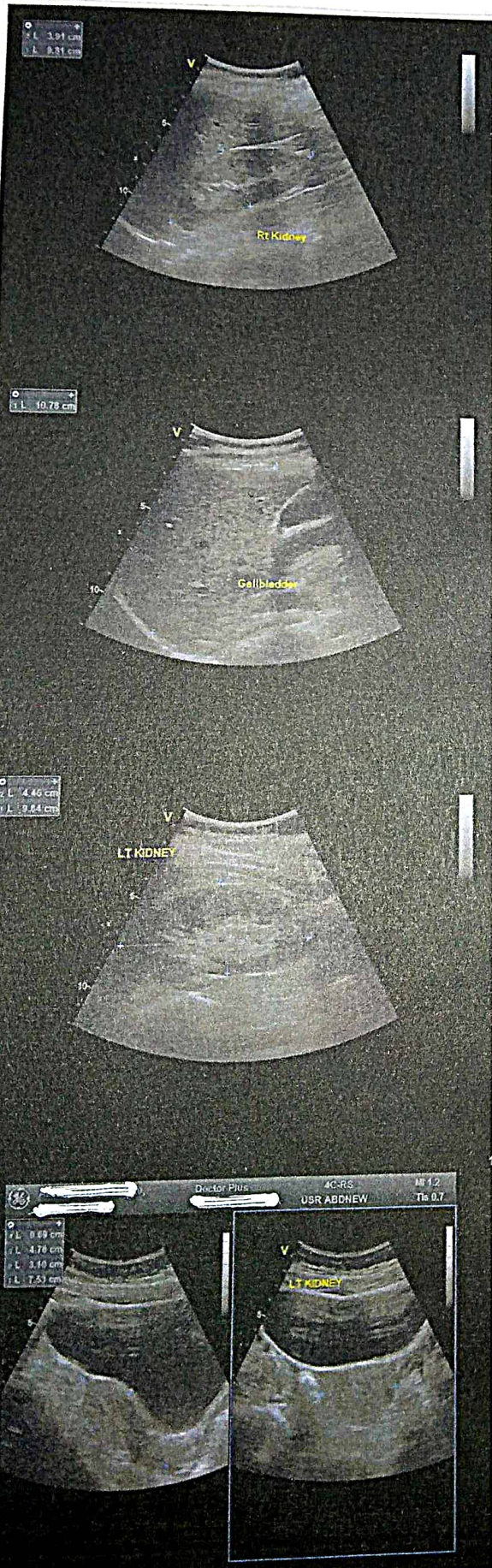
MMC REGD NO 847325

DR. PLUS HEALTHCARE CENTRE
NATHANI HEIGHTS', B-WING
42, MUMBAI CENTRAL (EAST)

Name **PREETI KUMARI**

Sex **Female**

Age **29**





Dr-Plus Healthcare Centre

NATHANI HEIGHTS, B-Wing, Shop No. 42, Ground Floor, Opp. Mumbai Central Station (East), Mumbai - 400 008.

Patient's Name : PREETI KIMARI

Report Date : 12/03/2022


Referred By : SELF

Age : 29 Years

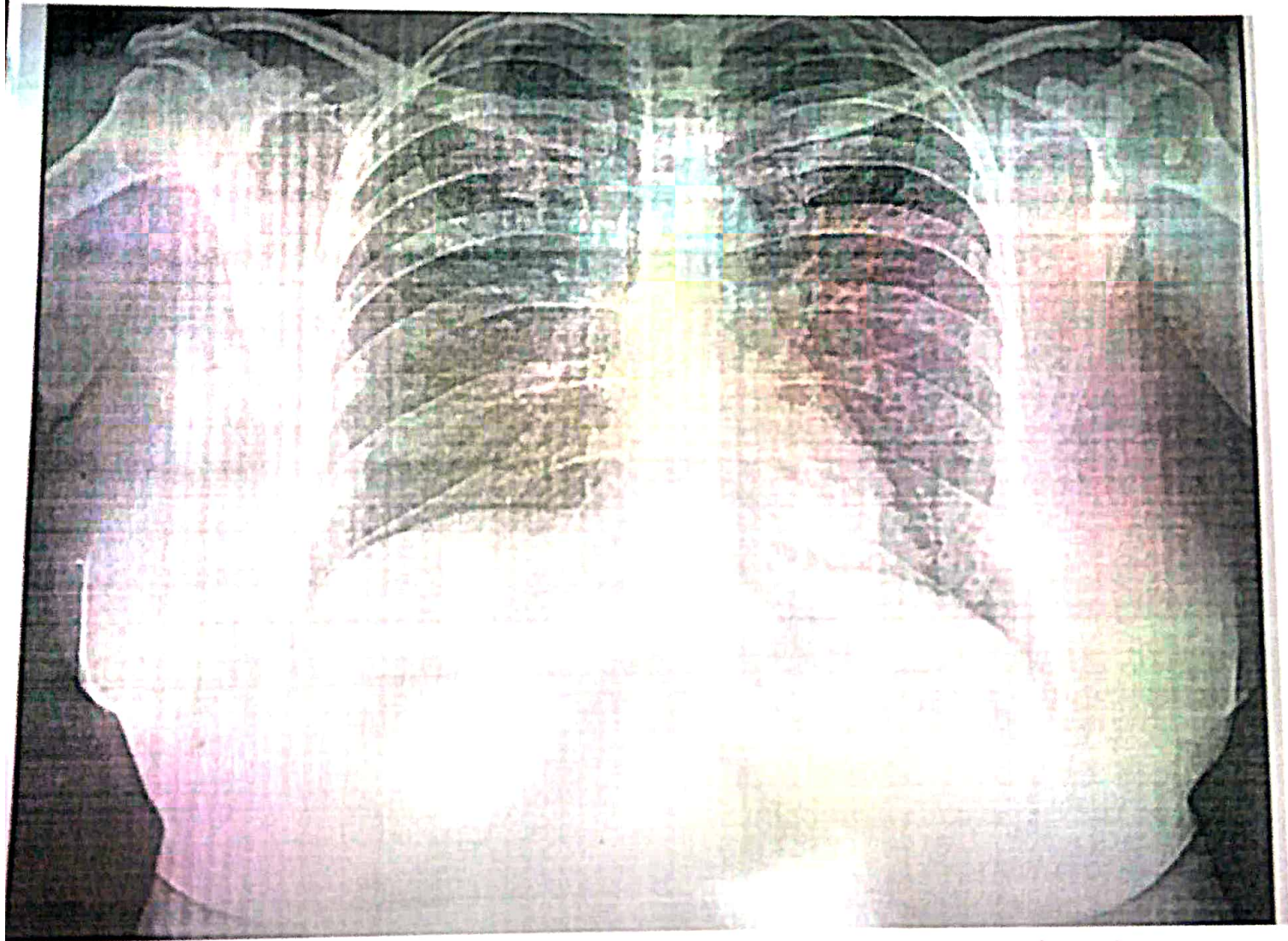
Sex : FEMALE

X- RAY CHEST

BOTH THE LUNG FIELED ARE CLEAR.
THE HILAR SHADOWS APPEAR NORMAL.
THE COSTO-PHRENIC ANGELS ARE CLEAR.
THE CARDIAC SHADOWS APPEAR NORMAL.
THE TRACHEAL IS CENTRAL IN POSITION.
THE BONY CAGE APPEARS NORMAL.


DR. A. J. MAZUMDAR
MD. DMRE, MDRD

DR. PLUS HEALTHCARE CENTRE
NATHANI HEIGHTS B-WING,
42, MUMBAI CENTRAL (EAST)



PREETI KUMARI

29/F

12/03/2022



Dr-Plus Healthcare Centre

NATHANI HEIGHTS, B-Wing, Shop No. 42, Ground Floor, Opp. Mumbai Central Station (East), Mumbai - 400 008.

Full Name

PREETI KUMARI

29/F

12/03/2022

Life to be assured:

	Type of Test	Actual Reading	Normal Range
1	Fasting Blood Sugar	79.6	70-100 mg%
2	PPBS	118	110 TO 140 mg%
3	Total Cholesterol	162.5	120-200 mg%
4	VERY LOW DENSITY LEVEL(VLDL)	14.5	10-30 mg/dl
5	High Density Lipid (HDL)	49.0	40-60 mg%
6	Low Density Lipid (LDL)	99	Upto 150
7	S. Triglycerides	114.5	50-150 mg%
8	CHOL/HDL	3.31	Upto 5
9	HDL/LDL	0.4	
10	S. Creatinine	0.9	0.5-1.2 mg%
11	Blood Urea Nitrogen (BUN)	16.6	7-21 mg%
12	BUN/CREAT RATIO	18.4	
13	S. Proteins	6.6	6.0-7.9 mg%
14	(a) Albumin	3.6	3.5-5.5 mg%
15	(b) Globulin	3.0	2.0-3.5 mg%
16	A/G RATIO	1.2	
17	S. Bilirubin	0.8	0.3-1.3mg%
18	(a) Direct	0.4	0.0-0.8 mg%
19	(b) Indirect	0.3	0.0-0.5 mg%
20	SGOT (AST)	25.6	05-34 IU
21	SGPT (ALT)	30.1	05-40 IU
22	GGTP (GGT)	38.5	05-50 IU
23	SGOT/SGPT	0.8	
24	HBA1C	5.3	UPTO 6.5
25	S. Alkaline Phosphatase	94.6	30-115 IU
26	T3	147.8	80-180ng/dl
27	T4	5.5	4.6-12 ug/dl
28	TSH	3.5	0.4-4.0 mIU/L
29	SERUM URIC ACID	5.6	2.5-7.2mg/dl
30	URINE SUGAR PP	ABSENT	
31	URINE SUGAR FASTING	ABSENT	
32	BLOOD GROUP	"O POSITIVE "	

DR. RAKESH PATKAR
M.D., P.N.B. (Pathology)
Reg. No. 2013/05/1660



Dr-Plus Healthcare Centre

NATHANI HEIGHTS, B-Wing, Shop No. 42, Ground Floor, Opp. Mumbai Central Station (East), Mumbai - 400 008.

Full Name
Life to be assured:

PREETI KUMARI

29/F

12/03/2022

HAEMOGRAM

Normal Range

1.	Red Blood Cell Count	3.7	[M : 4.5 - 5.6 / F : 3.5 - 5.5/cu.mm]
2.	Hb%	11.1	[M: 14-18 / F : 11-16%]
3.	Hematocrit	37.8	[M : 40-53 / F : 30-47 %]
4.	Indices:		
(a)	MCV(Mean Corpuscular Volume)	85.6	[79-101 cu.mi.]
(b)	MCH(Mean Corpuscular Hb)	29.8	[27-32 pg]
(c)	MCHC(Mean Corpuscular Hb Concentration)	32.5	[32-38%]
5.	Morphology		
	Macrocytes :	--	Microcytes: -- Hypochromia: --
	Poikilocytosis:	--	Anisocytosis: --
6.	Target cells:	--	
	Spherocytes:	--	Elliptocytes: --
7.	TOTALW.B.C.Count	5,800	{4000-11000/cu.mm}
Differential Count			
a)	Neutrophils :	60	[45 -70%] c) Eosinophils: 04 [01 - 06%]
b)	Lymphocytes :	31	[20 - 45%] d) Monocytes: 05 [00 - 08%]
e)	Basophils :	00	[00 - 01%]
8.	Platelets :3.12	1.5-4.5 Lacks/cu.mm	
9.	Erythrocyte Sedimentation Rate:15	20 mm at end of 1 hour	Method : Westergrens

ROUTINE URINE EXAMINATION (RUA)

1. Physical Examination:

(i)	Colour:	PALE YELLOW	(ii)	Sediment:	CLEAR
(iii)	Transparency:	CLEAR	(iv)	Reaction:	ACIDIC
(v)	Specific gravity	1.020			

2. Chemical Examination:

(i)	Protein :	NIL	(ii)	Sugar:	NIL
(iii)	Bile salt:	NIL	(iv)	Bile pigment:	NIL

3. Microscopic Examination:

(i)	Red Blood Cells:	ABSENT	(ii)	Epithelial Cells:	1 TO 2/ HPF
(iii)	Crystals:	ABSENT	(iv)	Pus Cells:	2 TO 3/HPF
(v)	Casts:	ABSENT	(vi)	Deposits:	ABSENT
(vii)	Bacteria's :	ABSENT			

DR. RAJESH PATKAR
M.D., D.N.B. (Pathology)
Reg. No. 2013/05/1660



Dr. Hari Chhablani

Cardiometabolic Physician & Intensivist
M.B.B.S., F.C.C.P. (RESP. MED.), PGDHHM,
PGDMLS, FELLOW INTENSIVE CARE MED.

ATTACHED TO: Wockhardt Hospital • Saifee Hospital • Apollo Spectra Hospital

NATHANI HEIGHTS, B-Wing, Shop No. 42, Ground Floor, Opp. Mumbai Central Station (East),
Mumbai - 400 008. • Cell : 98206 46163 • E : drharichhablani@gmail.com

PHYSICIAN REPORT

NAME : PREETI KUMARI 29/F

DATE : 12/03/2022

PRESENTING COMPLAINS: NIL.

TREATMENT : NIL.

PAST HISTORY: H/O B/L BREAST LUMP OPERATED - DETAILS NOT AVAILABLE.

FAMILY HISTORY: NOT SIGNIFICANT

HABITS: NIL.

HT.- 157 CM. WT.- 70 Kg. BMI.-28

P: 92/MIN., REGULAR BP: 110/70

EYE EXAMINATION : NEAR VISION B/E -N12 , DISTANT VISION - RT. EYE -2.5 , LT. EYE -2.5

COLOR VISION : NORMAL

RS: CLEAR

CVS: S1,S2 REGULAR

PA: SOFT

CNS: CLINICALLY NAD

LABS: ATTACHED

USG - WNL

2D-ACHO : WNL

ECG: WNL

X-RAY - WNL

ADVICE : MAMMOGRAM .

DR. HARI CHHABLANI

DR. HARI CHHABLANI
M.B.B.S., F.C.C.P. (RESP. MEDICINE), PGDHHM, PGDMLS
FELLOW INTENSIVE CARE
MMC REG. NO. - 91702