

Patient Name	: Mrs.M N CHANDRAKALA	Collected	: 09/Nov/2024 08:09AM
Age/Gender	: 52 Y 0 M 19 D/F	Received	: 09/Nov/2024 10:10AM
UHID/MR No	: CMYS.0000062540	Reported	: 09/Nov/2024 11:52AM
Visit ID	: CMYSOPV131284	Status	: Final Report
Ref Doctor	: Self	Sponsor Name	: ARCOFEMI HEALTHCARE LIMITED
Emp/Auth/TPA ID	: 22S38058		

DEPARTMENT OF HAEMATOLOGY

ARCOFEMI - MEDIWHEEL - FULL BODY ANNUAL PLUS CHECK ADVANCED - FEMALE - 2D ECHO - PAN INDIA - FY232

PERIPHERAL SMEAR , WHOLE BLOOD EDTA



Dr. PAVAN KUMAR M
M.B.B.S,M.D(Pathology)
Consultant Pathologist

SIN No:MYS241100323



Patient Name : Mrs.M N CHANDRAKALA	Collected : 09/Nov/2024 08:09AM
Age/Gender : 52 Y 0 M 19 D/F	Received : 09/Nov/2024 10:10AM
UHID/MR No : CMYS.0000062540	Reported : 09/Nov/2024 01:12PM
Visit ID : CMYSOPV131284	Status : Final Report
Ref Doctor : Self	Sponsor Name : ARCOFEMI HEALTHCARE LIMITED
Emp/Auth/TPA ID : 22S38058	

DEPARTMENT OF HAEMATOLOGY

ARCOFEMI - MEDIWHEEL - FULL BODY ANNUAL PLUS CHECK ADVANCED - FEMALE - 2D ECHO - PAN INDIA - FY232


Test Name	Result	Unit	Bio. Ref. Interval	Method
HEMOGRAM , WHOLE BLOOD EDTA				
HAEMOGLOBIN	12.2	g/dL	12.5-15	Spectrophotometer
PCV	37.30	%	36-46	Electronic pulse & Calculation
RBC COUNT	4.66	Million/cu.mm	3.8-4.8	Electrical Impedance
MCV	80	fL	83-101	Calculated
MCH	26.2	pg	27-32	Calculated
MCHC	32.7	g/dL	31.5-34.5	Calculated
R.D.W	13.6	%	11.6-14	Calculated
TOTAL LEUCOCYTE COUNT (TLC)	5,820	cells/cu.mm	4000-10000	Electrical Impedance
DIFFERENTIAL LEUCOCYTIC COUNT (DLC)				
NEUTROPHILS	62	%	40-80	Electrical Impedance
LYMPHOCYTES	31	%	20-40	Electrical Impedance
EOSINOPHILS	2	%	1-6	Electrical Impedance
MONOCYTES	4	%	2-10	Electrical Impedance
BASOPHILS	1	%	0-2	Electrical Impedance
ABSOLUTE LEUCOCYTE COUNT				
NEUTROPHILS	3608.4	Cells/cu.mm	2000-7000	Calculated
LYMPHOCYTES	1804.2	Cells/cu.mm	1000-3000	Calculated
EOSINOPHILS	116.4	Cells/cu.mm	20-500	Calculated
MONOCYTES	232.8	Cells/cu.mm	200-1000	Calculated
BASOPHILS	58.2	Cells/cu.mm	0-100	Calculated
Neutrophil lymphocyte ratio (NLR)	2		0.78- 3.53	Calculated
PLATELET COUNT	268000	cells/cu.mm	150000-410000	Electrical impedance
ERYTHROCYTE SEDIMENTATION RATE (ESR)	110	mm at the end of 1 hour	0-20	Modified Westergren
PERIPHERAL SMEAR				

R.B.C: Majority are normocytic normochromic. Also seen are few microcytes.

W.B.C: Are normal in number,morphology and distribution.

Platelets: Adequate and are seen in singles and clumps.

Hemoparasites: Not seen.



Dr. PAVAN KUMAR M
M.B.B.S,M.D(Pathology)
Consultant Pathologist

SIN No:MYS241100323




Patient Name : Mrs.M N CHANDRAKALA	Collected : 09/Nov/2024 08:09AM
Age/Gender : 52 Y 0 M 19 D/F	Received : 09/Nov/2024 10:10AM
UHID/MR No : CMYS.0000062540	Reported : 09/Nov/2024 01:12PM
Visit ID : CMYSOPV131284	Status : Final Report
Ref Doctor : Self	Sponsor Name : ARCOFEMI HEALTHCARE LIMITED
Emp/Auth/TPA ID : 22S38058	

DEPARTMENT OF HAEMATOLOGY

ARCOFEMI - MEDIWHEEL - FULL BODY ANNUAL PLUS CHECK ADVANCED - FEMALE - 2D ECHO - PAN INDIA - FY232

Test Name	Result	Unit	Bio. Ref. Interval	Method
BLOOD GROUP ABO AND RH FACTOR , WHOLE BLOOD EDTA				
BLOOD GROUP TYPE	O			Forward & Reverse Grouping with Slide/Tube Aggluti
Rh TYPE	POSITIVE			Forward & Reverse Grouping with Slide/Tube Agglutination



Dr. PAVAN KUMAR M
M.B.B.S,M.D(Pathology)
Consultant Pathologist

SIN No:MYS241100323



Patient Name : Mrs.M N CHANDRAKALA	Collected : 09/Nov/2024 08:09AM
Age/Gender : 52 Y 0 M 19 D/F	Received : 09/Nov/2024 12:41PM
UHID/MR No : CMYS.0000062540	Reported : 09/Nov/2024 12:43PM
Visit ID : CMYSOPV131284	Status : Final Report
Ref Doctor : Self	Sponsor Name : ARCOFEMI HEALTHCARE LIMITED
Emp/Auth/TPA ID : 22S38058	

DEPARTMENT OF BIOCHEMISTRY

ARCOFEMI - MEDIWHEEL - FULL BODY ANNUAL PLUS CHECK ADVANCED - FEMALE - 2D ECHO - PAN INDIA - FY232

Test Name	Result	Unit	Bio. Ref. Interval	Method
HBA1C (GLYCATED HEMOGLOBIN) , WHOLE BLOOD EDTA				
HBA1C, GLYCATED HEMOGLOBIN	4.2	%		HPLC
ESTIMATED AVERAGE GLUCOSE (eAG)	74	mg/dL		Calculated

Comment:

Reference Range as per American Diabetes Association (ADA) 2023 Guidelines:

REFERENCE GROUP	HBA1C %
NON DIABETIC	<5.7
PREDIABETES	5.7 – 6.4
DIABETES	≥ 6.5
DIABETICS	
EXCELLENT CONTROL	6 – 7
FAIR TO GOOD CONTROL	7 – 8
UNSATISFACTORY CONTROL	8 – 10
POOR CONTROL	>10

Note: Dietary preparation or fasting is not required.

- HbA1c is recommended by American Diabetes Association for Diagnosing Diabetes and monitoring Glycemic Control by American Diabetes Association guidelines 2023.
- Trends in HbA1c values is a better indicator of Glycemic control than a single test.
- Low HbA1c in Non-Diabetic patients are associated with Anemia (Iron Deficiency/Hemolytic), Liver Disorders, Chronic Kidney Disease. Clinical Correlation is advised in interpretation of low Values.
- Falsely low HbA1c (below 4%) may be observed in patients with clinical conditions that shorten erythrocyte life span or decrease mean erythrocyte age. HbA1c may not accurately reflect glycemic control when clinical conditions that affect erythrocyte survival are present.
- In cases of Interference of Hemoglobin variants in HbA1C, alternative methods (Fructosamine) estimation is recommended for Glycemic Control
 - A: HbF >25%
 - B: Homozygous Hemoglobinopathy.
 - (Hb Electrophoresis is recommended method for detection of Hemoglobinopathy)

Dr. PAVAN KUMAR M
M.B.B.S,M.D(Pathology)
Consultant Pathologist

SIN No:MYS241100326



Patient Name : Mrs.M N CHANDRAKALA	Collected : 09/Nov/2024 08:09AM
Age/Gender : 52 Y 0 M 19 D/F	Received : 09/Nov/2024 10:10AM
UHID/MR No : CMYS.0000062540	Reported : 09/Nov/2024 11:11AM
Visit ID : CMYSOPV131284	Status : Final Report
Ref Doctor : Self	Sponsor Name : ARCOFEMI HEALTHCARE LIMITED
Emp/Auth/TPA ID : 22S38058	

DEPARTMENT OF BIOCHEMISTRY

ARCOFEMI - MEDIWHEEL - FULL BODY ANNUAL PLUS CHECK ADVANCED - FEMALE - 2D ECHO - PAN INDIA - FY232

Test Name	Result	Unit	Bio. Ref. Interval	Method
LIPID PROFILE , SERUM				
TOTAL CHOLESTEROL	194	mg/dl	0-200	CHOD
TRIGLYCERIDES	59	mg/dl	0-150	GPO, Trinder
HDL CHOLESTEROL	72	mg/dL	40-60	CHOD
NON-HDL CHOLESTEROL	122	mg/dL	<130	Calculated
LDL CHOLESTEROL	109.9	mg/dL	<100	Calculated
VLDL CHOLESTEROL	11.86	mg/dL	<30	Calculated
CHOL / HDL RATIO	2.69		0-4.97	Calculated
ATHEROGENIC INDEX (AIP)	0.10		<0.11	Calculated

Comment:

Reference Interval as per National Cholesterol Education Program (NCEP) Adult Treatment Panel III Report.

	Desirable	Borderline High	High	Very High
TOTAL CHOLESTEROL	< 200	200 - 239	≥ 240	
TRIGLYCERIDES	<150	150 - 199	200 - 499	≥ 500
LDL	Optimal < 100 Near Optimal 100-129	130 - 159	160 - 189	≥ 190
HDL	≥ 60			
NON-HDL CHOLESTEROL	Optimal <130; Above Optimal 130-159	160-189	190-219	>220



Dr. PAVAN KUMAR M
M.B.B.S,M.D(Pathology)
Consultant Pathologist

SIN No:MYS241100321



Patient Name : Mrs.M N CHANDRAKALA	Collected : 09/Nov/2024 08:09AM
Age/Gender : 52 Y 0 M 19 D/F	Received : 09/Nov/2024 10:10AM
UHID/MR No : CMYS.0000062540	Reported : 09/Nov/2024 11:11AM
Visit ID : CMYSOPV131284	Status : Final Report
Ref Doctor : Self	Sponsor Name : ARCOFEMI HEALTHCARE LIMITED
Emp/Auth/TPA ID : 22S38058	

DEPARTMENT OF BIOCHEMISTRY

ARCOFEMI - MEDIWHEEL - FULL BODY ANNUAL PLUS CHECK ADVANCED - FEMALE - 2D ECHO - PAN INDIA - FY232

Test Name	Result	Unit	Bio. Ref. Interval	Method
LIVER FUNCTION TEST (LFT) , SERUM				
BILIRUBIN, TOTAL	0.57	mg/dl	0-1.2	NBD
BILIRUBIN CONJUGATED (DIRECT)	0.17	mg/dl	0-0.2	Diazotized sulfanilic acid
BILIRUBIN (INDIRECT)	0.40	mg/dL	0.0-1.1	Dual Wavelength
ALANINE AMINOTRANSFERASE (ALT/SGPT)	18	U/l	0-45	IFCC
ASPARTATE AMINOTRANSFERASE (AST/SGOT)	22.0	U/l	0-31	IFCC
AST (SGOT) / ALT (SGPT) RATIO (DE RITIS)	1.2		<1.15	Calculated
ALKALINE PHOSPHATASE	66.00	U/l	42-98	IFCC (AMP buffer)
PROTEIN, TOTAL	7.50	g/dl	6.4-8.3	Biuret
ALBUMIN	4.00	g/dl	3.5-5.2	Bromcresol Green
GLOBULIN	3.50	g/dL	2.0-3.5	Calculated
A/G RATIO	1.14		0.9-2.0	Calculated

Comment:

LFT results reflect different aspects of the health of the liver, i.e., hepatocyte integrity (AST & ALT), synthesis and secretion of bile (Bilirubin, ALP), cholestasis (ALP, GGT), protein synthesis (Albumin) Common patterns seen:

1. Hepatocellular Injury:

*AST – Elevated levels can be seen. However, it is not specific to liver and can be raised in cardiac and skeletal injuries.*ALT – Elevated levels indicate hepatocellular damage. It is considered to be most specific lab test for hepatocellular injury. Values also correlate well with increasing BMI. Disproportionate increase in AST, ALT compared with ALP. AST: ALT (ratio) – In case of hepatocellular injury AST: ALT > 1In Alcoholic Liver Disease AST: ALT usually >2. This ratio is also seen to be increased in NAFLD, Wilsons’s diseases, Cirrhosis, but the increase is usually not >2.

2. Cholestatic Patten:*ALP – Disproportionate increase in ALP compared with AST, ALT. ALP elevation also seen in pregnancy, impacted by age and sex.*Bilirubin elevated- predominantly direct , To establish the hepatic origin correlation with elevated GGT helps.

3. Synthetic function impairment:*Albumin- Liver disease reduces albumin levels, Correlation with PT (Prothrombin Time) helps.

4. Associated tests for assessment of liver fibrosis - Fibrosis-4 and APRI Index.



Dr. PAVAN KUMAR M
M.B.B.S,M.D(Pathology)
Consultant Pathologist

SIN No:MYS241100321



Patient Name : Mrs.M N CHANDRAKALA	Collected : 09/Nov/2024 08:09AM
Age/Gender : 52 Y 0 M 19 D/F	Received : 09/Nov/2024 10:10AM
UHID/MR No : CMYS.0000062540	Reported : 09/Nov/2024 11:38AM
Visit ID : CMYSOPV131284	Status : Final Report
Ref Doctor : Self	Sponsor Name : ARCOFEMI HEALTHCARE LIMITED
Emp/Auth/TPA ID : 22S38058	

DEPARTMENT OF BIOCHEMISTRY

ARCOFEMI - MEDIWHEEL - FULL BODY ANNUAL PLUS CHECK ADVANCED - FEMALE - 2D ECHO - PAN INDIA - FY232

Test Name	Result	Unit	Bio. Ref. Interval	Method
RENAL PROFILE/KIDNEY FUNCTION TEST (RFT/KFT) , SERUM				
CREATININE	0.57	mg/dL	0.51-1.04	Enzymatic colorimetric
UREA	19.72	mg/dl	13-43	Urease, UV
BLOOD UREA NITROGEN	9.2	mg/dL	8.0 - 23.0	Calculated
URIC ACID	4.40	mg/dL	2.6-6	Uricase
CALCIUM	9.10	mg/dl	8.6-10.3	Arsenazo III
PHOSPHORUS, INORGANIC	3.91	mg/dl	2.7-4.5	Molybdate
SODIUM	140	mmol/L	135-145	Direct ISE
POTASSIUM	4.0	mmol/L	3.5-5.1	Direct ISE
CHLORIDE	104	mmol/L	98 - 107	Direct ISE
PROTEIN, TOTAL	7.50	g/dl	6.4-8.3	Biuret
ALBUMIN	4.00	g/dl	3.5-5.2	Bromcresol Green
GLOBULIN	3.50	g/dL	2.0-3.5	Calculated
A/G RATIO	1.14		0.9-2.0	Calculated



Dr. PAVAN KUMAR M
M.B.B.S,M.D(Pathology)
Consultant Pathologist

SIN No:MYS241100321



Patient Name : Mrs.M N CHANDRAKALA	Collected : 09/Nov/2024 08:09AM
Age/Gender : 52 Y 0 M 19 D/F	Received : 09/Nov/2024 10:10AM
UHID/MR No : CMYS.0000062540	Reported : 09/Nov/2024 11:11AM
Visit ID : CMYSOPV131284	Status : Final Report
Ref Doctor : Self	Sponsor Name : ARCOFEMI HEALTHCARE LIMITED
Emp/Auth/TPA ID : 22S38058	

DEPARTMENT OF BIOCHEMISTRY

ARCOFEMI - MEDIWHEEL - FULL BODY ANNUAL PLUS CHECK ADVANCED - FEMALE - 2D ECHO - PAN INDIA - FY232

Test Name	Result	Unit	Bio. Ref. Interval	Method
GAMMA GLUTAMYL TRANSPEPTIDASE (GGT) , SERUM	14.00	U/l	0-38	IFCC



Dr. PAVAN KUMAR M
M.B.B.S,M.D(Pathology)
Consultant Pathologist

SIN No:MYS241100321



Patient Name : Mrs.M N CHANDRAKALA	Collected : 09/Nov/2024 08:09AM
Age/Gender : 52 Y 0 M 19 D/F	Received : 09/Nov/2024 10:10AM
UHID/MR No : CMYS.0000062540	Reported : 09/Nov/2024 12:53PM
Visit ID : CMYSOPV131284	Status : Final Report
Ref Doctor : Self	Sponsor Name : ARCOFEMI HEALTHCARE LIMITED
Emp/Auth/TPA ID : 22S38058	

DEPARTMENT OF IMMUNOLOGY

ARCOFEMI - MEDIWHEEL - FULL BODY ANNUAL PLUS CHECK ADVANCED - FEMALE - 2D ECHO - PAN INDIA - FY232

Test Name	Result	Unit	Bio. Ref. Interval	Method
THYROID PROFILE TOTAL (T3, T4, TSH) , SERUM				
TRI-iodothyronine (T3, TOTAL)	1.13	ng/mL	0.87-1.78	CLIA
THYROXINE (T4, TOTAL)	11.59	µg/dL	6.09-12.23	CLIA
THYROID STIMULATING HORMONE (TSH)	2.900	µIU/mL	0.38-5.33	CLIA

Comment:

For pregnant females	Bio Ref Range for TSH in uIU/ml (As per American Thyroid Association)
First trimester	0.1 - 2.5
Second trimester	0.2 – 3.0
Third trimester	0.3 – 3.0

- TSH is a glycoprotein hormone secreted by the anterior pituitary. TSH activates production of T3 (Triiodothyronine) and its prohormone T4 (Thyroxine). Increased blood level of T3 and T4 inhibit production of TSH.
- TSH is elevated in primary hypothyroidism and will be low in primary hyperthyroidism. Elevated or low TSH in the context of normal free thyroxine is often referred to as sub-clinical hypo- or hyperthyroidism respectively.
- Both T4 & T3 provides limited clinical information as both are highly bound to proteins in circulation and reflects mostly inactive hormone. Only a very small fraction of circulating hormone is free and biologically active.
- Significant variations in TSH can occur with circadian rhythm, hormonal status, stress, sleep deprivation, medication & circulating antibodies.

TSH	T3	T4	FT4	Conditions
High	Low	Low	Low	Primary Hypothyroidism, Post Thyroidectomy, Chronic Autoimmune Thyroiditis
High	N	N	N	Subclinical Hypothyroidism, Autoimmune Thyroiditis, Insufficient Hormone Replacement Therapy.
N/Low	Low	Low	Low	Secondary and Tertiary Hypothyroidism
Low	High	High	High	Primary Hyperthyroidism, Goitre, Thyroiditis, Drug effects, Early Pregnancy
Low	N	N	N	Subclinical Hyperthyroidism
Low	Low	Low	Low	Central Hypothyroidism, Treatment with Hyperthyroidism
Low	N	High	High	Thyroiditis, Interfering Antibodies
N/Low	High	N	N	T3 Thyrotoxicosis, Non thyroidal causes

Dr. PAVAN KUMAR M
 M.B.B.S, M.D(Pathology)
 Consultant Pathologist

SIN No: MYS241100327



Patient Name	: Mrs.M N CHANDRAKALA	Collected	: 09/Nov/2024 08:09AM
Age/Gender	: 52 Y 0 M 19 D/F	Received	: 09/Nov/2024 10:10AM
UHID/MR No	: CMYS.0000062540	Reported	: 09/Nov/2024 12:53PM
Visit ID	: CMYSOPV131284	Status	: Final Report
Ref Doctor	: Self	Sponsor Name	: ARCOFEMI HEALTHCARE LIMITED
Emp/Auth/TPA ID	: 22S38058		

DEPARTMENT OF IMMUNOLOGY

ARCOFEMI - MEDIWHEEL - FULL BODY ANNUAL PLUS CHECK ADVANCED - FEMALE - 2D ECHO - PAN INDIA - FY232

High	High	High	High	Pituitary Adenoma; TSHoma/Thyrotropinoma
------	------	------	------	--



Dr. PAVAN KUMAR M
M.B.B.S,M.D(Pathology)
Consultant Pathologist

SIN No:MYS241100327



Patient Name : Mrs.M N CHANDRAKALA	Collected : 09/Nov/2024 08:09AM
Age/Gender : 52 Y 0 M 19 D/F	Received : 09/Nov/2024 11:12AM
UHID/MR No : CMYS.0000062540	Reported : 09/Nov/2024 12:29PM
Visit ID : CMYSOPV131284	Status : Final Report
Ref Doctor : Self	Sponsor Name : ARCOFEMI HEALTHCARE LIMITED
Emp/Auth/TPA ID : 22S38058	

DEPARTMENT OF CLINICAL PATHOLOGY

ARCOFEMI - MEDIWHEEL - FULL BODY ANNUAL PLUS CHECK ADVANCED - FEMALE - 2D ECHO - PAN INDIA - FY232

Test Name	Result	Unit	Bio. Ref. Interval	Method
COMPLETE URINE EXAMINATION (CUE) , URINE				
PHYSICAL EXAMINATION				
COLOUR	PALE YELLOW		PALE YELLOW	Visual
TRANSPARENCY	CLEAR		CLEAR	Physical Measurement
pH	5.5		5-7.5	Double Indicator
SP. GRAVITY	1.020		1.002-1.030	Bromothymol Blue
BIOCHEMICAL EXAMINATION				
URINE PROTEIN	NEGATIVE		NEGATIVE	Protein Error Of Indicator
GLUCOSE	NEGATIVE		NEGATIVE	Glucose Oxidase
URINE BILIRUBIN	NEGATIVE		NEGATIVE	Azo Coupling Reaction
URINE KETONES (RANDOM)	NEGATIVE		NEGATIVE	Sodium Nitro Prusside
UROBILINOGEN	NORMAL		NORMAL	Modified Ehrlich Reaction
NITRITE	NEGATIVE		NEGATIVE	Diazotization
LEUCOCYTE ESTERASE	NEGATIVE		NEGATIVE	Leucocyte Esterase
CENTRIFUGED SEDIMENT WET MOUNT AND MICROSCOPY				
PUS CELLS	2 - 3	/hpf	0-5	Microscopy
EPITHELIAL CELLS	4 - 6	/hpf	<10	Microscopy
RBC	NIL	/hpf	0-2	Microscopy
CASTS	NIL		0-2 Hyaline Cast	Microscopy
CRYSTALS	ABSENT		ABSENT	Microscopy

Comment:

All urine samples are checked for adequacy and suitability before examination. All abnormal chemical examination are rechecked and verified by manual methods. Microscopy findings are reported as an average of 10 high power fields.



Dr. PAVAN KUMAR M
M.B.B.S,M.D(Pathology)
Consultant Pathologist

SIN No: MYS241100325



Patient Name	: Mrs.M N CHANDRAKALA	Collected	: 09/Nov/2024 08:09AM
Age/Gender	: 52 Y 0 M 19 D/F	Received	: 09/Nov/2024 11:12AM
UHID/MR No	: CMYS.0000062540	Reported	: 09/Nov/2024 11:53AM
Visit ID	: CMYSOPV131284	Status	: Final Report
Ref Doctor	: Self	Sponsor Name	: ARCOFEMI HEALTHCARE LIMITED
Emp/Auth/TPA ID	: 22S38058		

TERMS AND CONDITIONS GOVERNING THIS REPORT

1. Reported results are for information and interpretation of the referring doctor or such other medical professionals, who understand reporting units, reference ranges and limitation of technologies. Laboratories not be responsible for any interpretation whatsoever.
2. It is presumed that the tests performed are, on the specimen / sample being to the patient named or identified and the verifications of particulars have been confirmed by the patient or his / her representative at the point of generation of said specimen.
3. The reported results are restricted to the given specimen only. Results may vary from lab to lab and from time to time for the same parameter for the same patient (within subject biological variation).
4. The patient details along with their results in certain cases like notifiable diseases and as per local regulatory requirements will be communicated to the assigned regulatory bodies.
5. The patient samples can be used as part of internal quality control, test verification, data analysis purposes within the testing scope of the laboratory.
6. This report is not valid for medico legal purposes. It is performed to facilitate medical diagnosis only.



Dr. PAVAN KUMAR M
M.B.B.S, M.D(Pathology)
Consultant Pathologist



SIN No: MYS241100322

Patient Name	: Mrs. M N CHANDRAKALA	Age	: 52Yrs 0Mths 21Days
UHID	: CMYS.0000062540	OP Visit No.	: CMYSOPV131284
Printed On	: 10-11-2024 04:45 AM	Advised/Pres Doctor	: --
Department	: Radiology	Qualification	: --
Referred By	: Self	Registration No.	: --
Employeer Id	: 22S38058		

DEPARTMENT OF RADIOLOGY

LIVER: It is normal in size and is increased in echotexture. No focal lesions seen. IHBR are not dilated. CBD and Portal vein are normal.

GALL BLADDER: It is distended with evidence of a echogenic calculus measuring ~16.5mm noted within the lumen

SPLEEN: It is normal in size, outline and echopattern. No e/o focal lesions.

PANCREAS: It is normal.

RIGHT KIDNEY: It measures 9.8cm with parenchymal thickness of 1.2cm. It is normal in size, outline and echotexture. No e/o calculus or hydronephrosis seen.

LEFT KIDNEY: It measures 10.5cm with parenchymal thickness of 1.1 cm. It is normal in size, outline and echotexture. No e/o calculus or hydronephrosis seen.

URINARY BLADDER: It is well distended. The UB wall is normal. No calculi seen.

UTERUS AND OVARIES : Post menopausal status .

OTHERS: No e/o free fluid in the abdomen. No e/o lymphadenopathy. No e/o gut wall thickening. No mass lesion seen in the abdomen.

IMPRESSION:

- Grade I fatty liver
- Cholelithiasis .No features of cholecystitis

---End Of The Report---



Dr.CHETAN HOLEPPAGOL
MBBS, DNB(RADIO DIAGNOSIS)
90037
Radiology

Patient Name	: Mrs. M N CHANDRAKALA	Age	: 52Yrs 0Mths 23Days
UHID	: CMYS.0000062540	OP Visit No.	: CMYSOPV131284
Printed On	: 12-11-2024 07:56 AM	Advised/Pres Doctor	: --
Department	: Radiology	Qualification	: --
Referred By	: Self	Registration No.	: --
Employer Id	: 22S38058		

DEPARTMENT OF RADIOLOGY

RIGHT BREAST: It is normal in echopattern. No e/o focal nodular or mass lesions seen. No e/o calcifications. The skin over the breast is normal. Nipple and areola are normal. The subcutaneous, mammary and retro mammary zones are normal.

LEFT BREAST: It is normal in echopattern. No e/o focal nodular or mass lesions seen. No e/o calcifications. The skin over the breast is normal. Nipple and areola are normal. The subcutaneous, mammary and retro mammary zones are normal.

No e/o axillary lymphadenopathy.

IMPRESSION: NORMAL STUDY.

---End Of The Report---



Dr.CHETAN HOLEPPAGOL
MBBS, DNB(RADIO DIAGNOSIS)
90037
Radiology



Patient	Mrs. M N CHANDRAKALA	Doctor	SUJATHA T R	Appt ID	CMYSAPT1387
Age/Gender	52Y Female	Qualification	MBBS, PGDMCH	Consult Date	10 Nov 2024
UHID	CMYS.0000062540	Reg. No.	69649	Order Bill ID	CMYS-OCR-24647
				Visit Display ID	CMYSOPV131284

VITALS

Weight : 77.9Kgs	Height : 157Cms
Pulse : 70 BPM	Spo2 : 98%
BP : 135 / 80 MmHg	Respiratory Rate : 20 BPM
Temperature : 98 °F	

SUJATHA T R
Doctor's Signature

Apollo Health and Lifestyle Limited

(CIN-U85110TG2000PLC115819)

Corporate Office: 7-1-617/A, 7* Floor, Imperial Towers, Ameerpet, Hyderabad-500016, Telangana

Ph No: 040-4904 7777 | www.apollohl.com | Email ID:enquiry@apollohl.com

Patient Name	: Mrs. M N CHANDRAKALA	Age	: 52Yrs 0Mths 25Days
UHID	: CMYS.0000062540	OP Visit No.	: CMYSOPV131284
Printed On	: 14-11-2024 07:38 AM	Advised/Pres Doctor	: --
Department	: Cardiology	Qualification	: --
Referred By	: Self	Registration No.	: --
Employer Id	: 22S38058		

DEPARTMENT OF CARDIOLOGY

2D ECHOCARDIOGRAPHY STUDY

Impression:

Normal chambers and valves
No regional wall motion abnormality
Normal left ventricular systolic function. EF 62 %
No clots. No pericardial effusion

??????

Findings

Left Ventricle: No RWMA
Right Ventricle Normal
Left Atrium Normal
Right Atrium Normal
Aorta Normal
Pulmonary Artery Normal
IAS Intact
IVS Intact
Valves Normal
Pericardium Normal
Doppler Normal

Patient's Name : Mrs. Chandrakala Age & Sex; 52Yrs /Female

Date : 09.11.2024

UHID No:

Measurements

AO:2.5 cm

LA :2.8 cm

RV :2.7 cm

LVIDd 4.98 cm

LVIDs :3.08 cm

IVSd :0.86 cm

IVSs :1.27 cm

PWd :1.17 cm

PWs :1.14 cm

EF : 68.0 %

FS : 38.0 %

Doppler

MV TV AV PV


E : 0.79 m/s E --- m/s V max 1.46 m/s V max 1.07 m/s

A : 0.63 m/s A --- m/s

---End Of The Report---



Dr. GURU PRASAD B V
MBBS, PGDCC
69949
Cardiology



Patient Name	: Mrs. M N CHANDRAKALA	Age	: 52Yrs 0Mths 21Days
UHID	: CMYS.0000062540	OP Visit No.	: CMYSOPV131284
Printed On	: 10-11-2024 03:57 AM	Advised/Pres Doctor	: --
Department	: Cardiology	Qualification	: --
Referred By	: Self	Registration No.	: --
Employer Id	: 22S38058		

DEPARTMENT OF CARDIOLOGY

Observation :-

1. Sinus Rhythm.
2. Heart rate is 78 beats per minutes.

Impression:

NORMAL RESTING ECG.

---End Of The Report---



Dr. GURU PRASAD B V
MBBS, PGDCC
69949
Cardiology

8, 9, 12 ophthalm

Name : Mrs. MN CHANDRAKALA
Address : Mysore Mysore Karnataka INDIA 570001
Plan : ARCOFEMI MEDIWHEEL FEMALE AHC
CREDIT PAN INDIA OP AGREEMENT

Age : 52Y 0M 19D
sex : Female

UHID : CMYS.0000062540



CMYS.0000062540

OP No: CMYSOPV131284
Bill No: CMYS-OCR-24647
Date: Nov 9th, 2024, 8:08 AM

77.9
157
135/80

Sno.	Service Type/Service Name	Department	
1	ARCOFEMI - MEDIWHEEL - FULL BODY ANNUAL PLUS CHECK ADVANCED - FEMALE - 2D ECHO - PAN INDIA - FY2324		
1	ULTRASOUND - WHOLE ABDOMEN	Ultrasound Radiology	<input type="checkbox"/>
2	FITNESS BY GENERAL PHYSICIAN → P	Consultation	<input type="checkbox"/>
3	HbA1c, GLYCATED HEMOGLOBIN	Biochemistry	<input type="checkbox"/>
4	LBC PAP TEST- PAPSURE	Histopathology	<input type="checkbox"/>
5	COMPLETE URINE EXAMINATION	Clinical Pathology	<input type="checkbox"/>
6	SONO MAMMOGRAPHY - SCREENING	Mammography	<input type="checkbox"/>
7	BLOOD GROUP ABO AND RH FACTOR	Blood Bank	<input type="checkbox"/>
8	LIVER FUNCTION TEST (LFT)	Biochemistry	<input type="checkbox"/>
9	GLUCOSE, POST PRANDIAL (PP), 2 HOURS (POST MEAL)	Biochemistry	<input type="checkbox"/>
10	GLUCOSE, FASTING	Biochemistry	<input type="checkbox"/>
11	OPHTHAL BY GENERAL PHYSICIAN	Consultation	<input type="checkbox"/>
12	DIET CONSULTATION → P	General	<input type="checkbox"/>
13	DENTAL CONSULTATION	Consultation	<input type="checkbox"/>
14	BODY MASS INDEX (BMI)	General	<input type="checkbox"/>
15	X-RAY CHEST PA	X Ray Radiology	<input type="checkbox"/>
16	HEMOGRAM + PERIPHERAL SMEAR	Haematology	<input type="checkbox"/>
17	PERIPHERAL SMEAR	Haematology	<input type="checkbox"/>
18	LIPID PROFILE	Biochemistry	<input type="checkbox"/>
19	2 D ECHO → P	Cardiology	<input type="checkbox"/>
20	Gynaecology Consultation → P	Consultation	<input type="checkbox"/>
21	EKG	Cardiology	<input type="checkbox"/>
22	THYROID PROFILE (TOTAL T3, TOTAL T4, TSH)	Biochemistry	<input type="checkbox"/>
23	ENT CONSULTATION → P	Consultation	<input type="checkbox"/>
24	URINE GLUCOSE(POST PRANDIAL)	Clinical Pathology	<input type="checkbox"/>
25	URINE GLUCOSE(FASTING)	Clinical Pathology	<input type="checkbox"/>
26	GAMMA GLUTAMYL TRANSFERASE (GGT)	Biochemistry	<input type="checkbox"/>
27	RENAL PROFILE/RENAL FUNCTION TEST (RFT/KFT)	Biochemistry	<input type="checkbox"/>

CERTIFICATE OF MEDICAL FITNESS

This is to certify that I have conducted the clinical examination

of M.N. Chandrahala on 09/11/24

After reviewing the medical history and on clinical examination it has been found that he/she is

	Tick
<ul style="list-style-type: none"> • Medically Fit 	<input checked="" type="checkbox"/>
<ul style="list-style-type: none"> • Fit with restrictions/recommendations <p>Though following restrictions have been revealed, in my opinion, these are not impediments to the job.</p> <p>1.....</p> <p>2.....</p> <p>3.....</p> <p>However the employee should follow the advice/medication that has been communicated to him/her.</p> <p>Review after _____</p>	
<ul style="list-style-type: none"> • Currently Unfit. Review after _____ recommended 	
<ul style="list-style-type: none"> • Unfit 	

Dr. 
Medical Officer

This certificate is not meant for medico-legal purposes

Apollo Clinic
23, 1st Floor,
Kalidasa Road, Mysore - 02
Ph : 0821-4006040/41

Apollo Health and Lifestyle Limited

(CIN - U85110TG2000PLC115819)

Regd. Office: 1-10-60/62, Ashoka Raghupathi Chambers, 5th Floor, Begumpet, Hyderabad, Telangana - 500 016,

Ph No: 040-4904 7777, Fax No: 4904 7744 | Email ID: enquiry@apollohl.com | www.apollohl.com

APOLLO CLINICS NETWORK KARNATAKA

Bangalore (Basavanagudi) | Bellandur | Electronic City | Fraser Town | HSR Layout | Indira Nagar | JP Nagar | Kundalahalli | Koramangala | Sarjapur Road) **Mysore** (VV Mohalla)

Online appointments: www.apolloclinic.com

TO BOOK AN APPOINTMENT

 **1860 500 7788**

[Phy]

Mrs. M N Chandrakala
52yrs / Female

Height: 157cm	Weight: 77.9 kg	BMI:	Waist Circum:
Temp:	Pulse: 74	Resp: 18/min	B.P: 135/80

General Examination /
Allergies History

CS
RS
P/R / N/A

Clinical Diagnosis & Management Plan

GO Bell's palsy on R
Ho Hoarseness

Adv
T. Bantanna plus (20)
810

Dentist opm

ESR -> 110

Follow up date :


Doctor Signature

Apollo Clinic
23, 1st Floor,
Kalidasa Road, Mysore - 02
Ph : 0821-407-140/41

[ENT]

Date : 11/9/2024 Department : ENT
 Patient Name : Mrs. M N CHANDRAKALA Doctor : Dr. PRAVEEN KUMAR R
 UHID : CMYS.0000062540 Registration No. : 66012
 Age / Gender : 52Yrs 0Mths 19Days/ Female Qualification : MBBS, MS (ENT)
 Consultation Timing : 1:50 PM

Height :	Weight :	BMI :	Waist Circum :
Temp :	Pulse :	Resp :	B.P :

General Examination / Allergies History

Clinical Diagnosis & Management Plan

Cause for regular health check

Bilateral Ear wax

Audience for @ ? 5ppv

O/E Ear Bilateral Ear wax @

No Spontaneous / gave misty view
positional test - no misty view

Nose 1mm @

As - wax dissolved

Follow up date :

Doctor Signature
Apollo Clinic
 # 23, 1st Floor,
 Kalidasa Road, Mysore - 02
 Ph : 0821-4006040/41

Date : 11/9/2024 Department : Nutrition & Dietetics
 Patient Name : Mrs. M N CHANDRAKALA Doctor : Miss.MADHURA B P
 UHID : CMYS.0000062540 Registration No. : A104102
 Age / Gender : 52Yrs 0Mths 19Days/ Female Qualification : M.Sc. Nutrition and Dietetics
 Consultation Timing : 1:50 PM PhD*

IBW - 50kg

Height : 151 cms	Weight : 77.9 kg	BMI : 34 kg/m ²	Waist Circum :
Temp :	Pulse :	Resp :	B.P :

General Examination / Allergies History

Hb - 12.2
 ESR - 110
 LDL - 109.9

Clinical Diagnosis & Management Plan

Δ^{ctc} - Grade I Fatty liver, cholelithiasis.
 → Advised low fat, low calorie diet with fiber rich foods.
 → Include seeds like flaxseeds, pumpkin seeds, sunflower seeds, watermelon seeds & sesame seeds - 1 teaspoon each, dry roasted.
 → Cooking oil - 1/2 liter (per month). Use the combination of oils like Rice bran oil, Groundnut oil, coconut oil, mustard oil, Gingeli oil & Olive but do not mix all the oils & boil it together.
 → Avoid alcohol, sugar, too much of salt, baking soda & creams.
 → Avoid bakery products, chips, junk foods, deep fried foods, packed & processed foods.

Follow up date :

Doctor Signature 
Apollo Clinic
 # 23, 1st Floor,
 Kalidasa Road, Mysore - 02
 Ph : 0821-4006040/41
 9/11/2024

Date : 11/9/2024 Department : Obstetrics & Gynaecology
 Patient Name : Mrs. M N CHANDRAKALA Doctor : Dr.RASHMI B N
 UHID : CMYS.0000062540 Registration No. : 33393
 Age / Gender : 52Yrs 0Mths 19Days/ Female Qualification : MBBS, DGO, DNB (GYNAECOLOGY)
 Consultation Timing : 1:51 PM

Height :	Weight :	BMI :	Waist Circum :
Temp :	Pulse :	Resp :	B.P :

General Examination /

Allergies History

PH → AS
 AH → SHD, hypertension
 diam-cholelithiasis

↓

surgery of uterus.

~~mammogram~~

Clinical Diagnosis & Management Plan

past →

MH → regular cycle.
 menopause 1yr.

normal study.

ml → 200gms.

Pa. Both US
 GUT & Colon

adv: regular walk 1yasa.

GAB. SKELETAL XT (30)

0-0-1.

ortho of uterus → for knee pain.

Follow up date :

Rashmi

Doctor Signature

Apollo Clinic
 # 23, 1st Floor,
 Kalidasa Road, Mysore - 02
 Ph : 0821-4006040/41

[Ophthalm]

Date : 11/9/2024 Department : General Practice
 Patient Name : Mrs. MN CHANDRAKALA Doctor : Dr. SUJATHA T R
 UHID : CMYS.0000062540 Registration No. : 69649
 Age / Gender : 52 Yrs 0 Mths 19 Days / Female Qualification : MBBS, PGDMCH
 Consultation Timing : 1:50 PM

Height :	Weight :	BMI :	Waist Circum :
Temp :	Pulse :	Resp :	B.P :

General Examination / Allergies History

Clinical Diagnosis & Management Plan

Distance vision

Un $\left\{ \begin{array}{l} 6/6 \\ 6/6 \end{array} \right.$

Colour vision

(CO) = normal

Near vision

N6

Sub
Add

+ 2.75 Sp (BE)

Follow up date : 09/10/24


Doctor Signature

Apollo Clinic
23, 1st Floor,
Kalidasa Road, Mysore - 02
Ph : 0821-4006040/41

(Dental)

Date : 11/9/2024 Department : Dental
 Patient Name : Mrs. M N CHANDRAKALA Doctor : Dr. JYOTHISHREE P V
 UHID : CMYS.0000062540 Registration No. : 33268A
 Age / Gender : 52Yrs 0Mths 19Days/ Female Qualification : B.D.S[Bachelor of Dental Surgery]
 Consultation Timing : 1:50 PM

Height :	Weight :	BMI :	Waist Circum :
Temp :	Pulse :	Resp :	B.P :

General Examination / Allergies History

Clinical Diagnosis & Management Plan

O/E

$\frac{67}{67}$ Ongoing Implant treatment

$\frac{76541}{76541}$ Implant
 Bridge present
 $\frac{2112}{221123}$ Teeth present

Dr. Jyothishree P V

Follow up date :

Doctor Signature

Apollo Clinic
 # 23, 1st Floor,
 Kalidasa Road, Mysore - 02
 Ph : 0821-4006040/41

Patient Name	: Mrs. M N CHANDRAKALA	Age	: 52Yrs 0Mths 19Days
UHID	: CMYS.0000062540	OP Visit No.	: CMYSOPV131284
Printed On	: 09-11-2024 12:45 PM	Advised/Pres Doctor	: --
Department	: Radiology	Qualification	: --
Referred By	: Self	Registration No.	: --
Employer Id	: 22S38C5B		

DEPARTMENT OF RADIOLOGY

Lung fields are clear.

Cardio thoracic ratio is normal.

Apices, costo and cardio phrenic angles are free.


Cardio vascular shadow and hila show no abnormal feature.

Bony thorax shows no significant abnormality.

Domes of diaphragm are well delineated.

IMPRESSION: NORMAL STUDY.

---End Of The Report---



Dr. CHETAN HOLEPPAGOL
MBBS, DNB (RADIO DIAGNOSIS)
90037
Radiology

Patient Name: Mrs. M N CHANDRAKALA	Date : 09.11 .2024	Referring Doctor: Dr. Self
Age / Sex: 52Yrs/Female	UHID No : 62540	Location : OP
ULTRASONOGRAPHY- ABDOMEN & PELVIS		

LIVER: It is normal in size and is increased in echotexture. No focal lesions seen. IHBR are not dilated. CBD and Portal vein are normal.

GALL BLADDER: It is distended with evidence of a echogenic calculus measuring ~16.5mm noted within the lumen

SPLEEN: It is normal in size, outline and echopattern. No e/o focal lesions.

PANCREAS: It is normal.

RIGHT KIDNEY: It measures 9.8cm with parenchymal thickness of 1.2cm. It is normal in size, outline and echotexture. No e/o calculus or hydronephrosis seen.

LEFT KIDNEY: It measures 10.5cm with parenchymal thickness of 1.1 cm. It is normal in size, outline and echotexture. No e/o calculus or hydronephrosis seen.

URINARY BLADDER: It is well distended. The UB wall is normal. No calculi seen.

UTERUS AND OVARIES : Post menopausal status .

OTHERS: No e/o free fluid in the abdomen. No e/o lymphadenopathy. No e/o gut wall thickening. No mass lesion seen in the abdomen.

IMPRESSION:

- Grade I fatty liver
- Cholelithiasis .No features of cholecystitis

Dr. Karthik H V MDRD , DNB
Consultant Radiologist.

Apollo Health and Lifestyle Limited

CIN: U85110TG2000PLC115819

Regd Office: 1/10-60-62, Ashoka Raghupathi Chambers, 5th Floor, Begumpet, Hyderabad, Telangana - 500 016

Ph. No: (04) 4904 7777 Fax No: 4904 7744 | Email ID: enquiry@apollohi.com | www.apollohi.com

APOLLO CLINICS NETWORK KARNATAKA

Bangalore | Saravanejudi | Bellandur | Electronic City | Fraser Town | HSR Layout | Indira Nagar | JP Nagar | Kundalahalli |
Koramangala | Sarjapur Road | Mysore (VV Mohalla)

Online appointments: www.apolloclinic.com

TO BOOK AN APPOINTMENT

1860 500 7788


Patient Name: Mrs.Chandrakala	Date :09.11.2024	Referring Doctor: Dr .Self
Age / Sex: 52Yrs/Female	UHID No:	Location : OP
ULTRASONOGRAPHY- BREAST		

RIGHT BREAST: It is normal in echopattern. No e/o focal nodular or mass lesions seen. No e/o calcifications. The skin over the breast is normal. Nipple and areola are normal. The subcutaneous, mammary and retro mammary zones are normal.

LEFT BREAST: It is normal in echopattern. No e/o focal nodular or mass lesions seen. No e/o calcifications. The skin over the breast is normal. Nipple and areola are normal. The subcutaneous, mammary and retro mammary zones are normal.

No e/o axillary lymphadenopathy.

IMPRESSION: NORMAL STUDY.


Dr. Karthik H V MDRD , DNB
Consultant Radiologist.

Apollo Health and Lifestyle Limited

ICIN: URS11DTG2000PLC1158181

Regd Office: 1-10-60-62, Ashoka Raghupathi Chambers, 5th Floor, Begumpet, Hyderabad, Telangana - 500 016

Ph. No: 040 4908 7777 Fax No: 4908 7744 | Email ID: enquiry@apollohi.com | www.apollohi.com

APOLLO CLINICS NETWORK KARNATAKA

Bangalore / Basavanagudi | Bellandur | Electronic City | Fraser Town | HSR Layout | Indira Nagar | JP Nagar | Kundalahalli |
Koramangala | Sarjapur Road | Mysore (VV Mohalla)

Online appointments: www.apolloclinic.com

TO BOOK AN APPOINTMENT

 **1860 500 7788**

Patient's Name : Mrs. Chandrakala	Age & Sex; 52Yrs /Female
Date : 09.11.2024	UHID No:

2D ECHOCARDIOGRAPHY STUDY

Impression:

- Normal chambers and valves
- No regional wall motion abnormality
- Normal left ventricular systolic function. EF 68%
- No clots. No pericardial effusion

Findings

Left Ventricle:	No RWMA
Right Ventricle	Normal
Left Atrium	Normal
Right Atrium	Normal
Aorta	Normal
Pulmonary Artery	Normal
IAS	Intact
IVS	Intact
Valves	Normal
Pericardium	Normal
Doppler	Normal

Apollo Health and Lifestyle Limited

ICN: U85110TG2000PLC1158191

Regd. Office: 1, 10-60-62, Ashoka Raghupathi Chambers, 5th Floor, Begumpet, Hyderabad, Telangana - 500 016

Ph No: (040) 4104 7777 Fax No: 4904 7744 | Email ID: enquiry@apolloh.com | www.apolloh.com

APOLLO CLINICS NETWORK KARNATAKA

Bangalore (Basavanaguda) | Brindavan | Electronic City | Fraser Town | HSR Layout | Indra Nagar | JP Nagar | Kundalahalli | Koramangala | Sarjapur Road | Mysore (VV Mohalla)

Online appointments: www.apolloclinic.com

TO BOOK AN APPOINTMENT

 **1860 500 7788**

Patient's Name : Mrs. Chandrakala	Age & Sex; 52Yrs /Female
Date : 09.11.2024	UHID No:

Measurements

AO : 2.5 cm
 LA : 2.8 cm

 RV : 2.7 cm
 LVIDd 4.98 cm
 LVIDs : 3.08 cm
 IVSd : 0.86 cm
 IVSs : 1.27 cm
 PWd : 1.17 cm
 PWs : 1.14 cm
 EF : 68.0 %
 FS : 38.0 %

Doppler
 MV TV AV PV
 E 0.79 m/s E --- m/s V max 1.46 m/s V max 1.07 m/s
 :
 A: 0.63 m/s A --- m/s

Dr. GURU PRASAD. B. V, MBBS, PGDCC
 CONSULTANT – NON-INVASIVE CARDIOLOGY

Apollo Health and Lifestyle Limited

CIN: UWS110G2000PLC1158191
 Regd. Office: 1-10-60-62, Ashoka Raghupathi Chambers, 5th Floor, Begumpet, Hyderabad, Telangana - 500 016
 Ph: No: 040 4904 7777 Fax No: 4904 7744 | Email ID: enquiry@apollohl.com | www.apollohl.com

APOLLO CLINICS NETWORK KARNATAKA

Bangalore: Besivanahalli | Bellandur | Electronic City | Fraser Town | HSR Layout | Indira Nagar | JP Nagar | Kundalahalli |
 Koramangala | Sarjapur Road | Mysore (VV Mohalla)

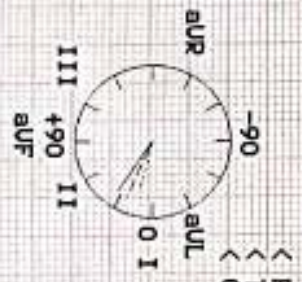
Online appointments: www.apolloclinic.com

TO BOOK AN APPOINTMENT

1860 500 7788

NO:

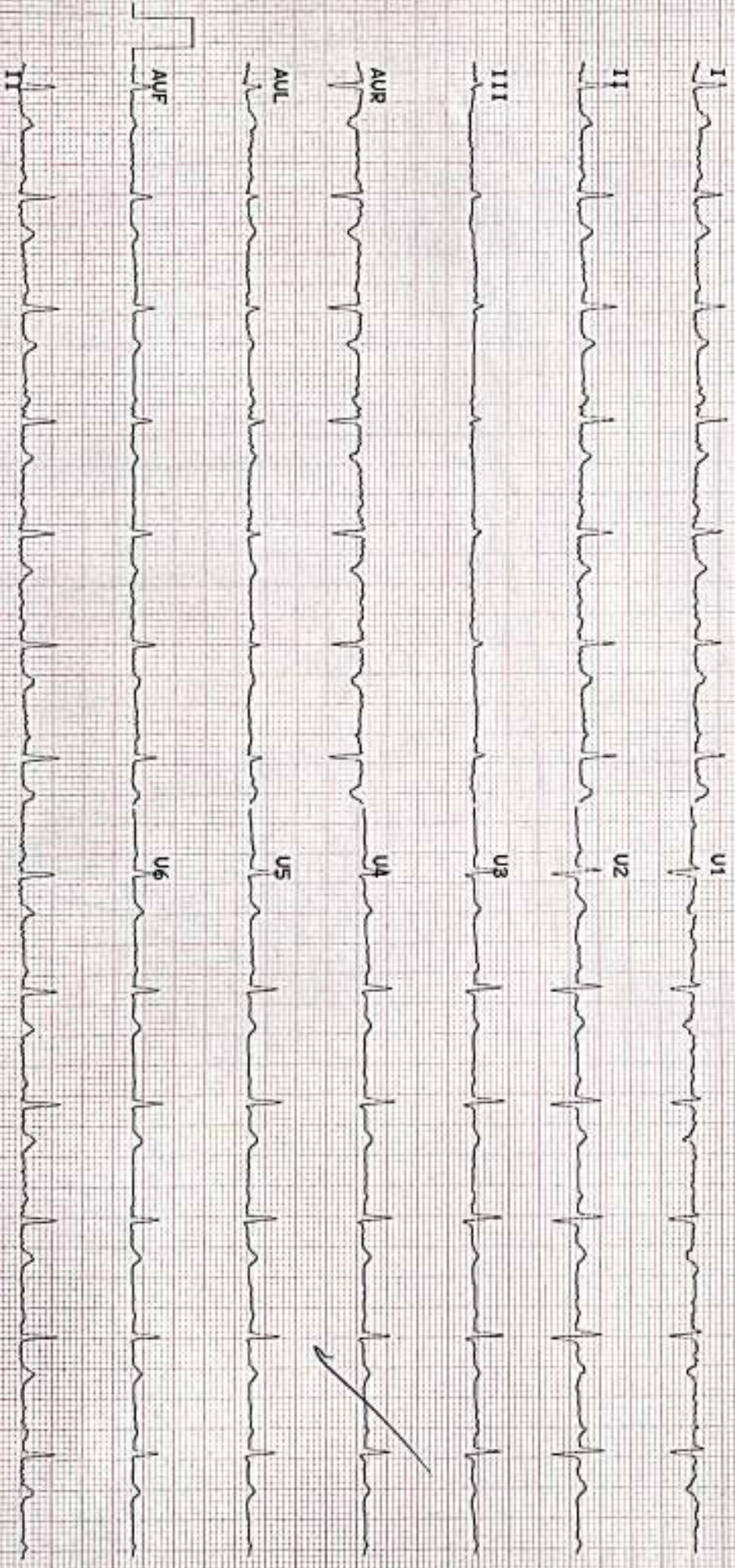
AGE: 52
 Measurement Results:
 QRS : 88 ms
 QT/QTcB : 362 / 415 ms
 PR : 146 ms
 P : 104 ms
 RR/PP : 762 / 760 ms
 P/QRS/T : 15 / 35 / 25 degrees
 QTd/QTcBd : 14 / 16 ms
 Sokolow : 0.8 mV
 NK : 10



Interpretation:

Unconfirmed report.

Apollo Clinic
 # 23, 1st Floor,
 Kaldasa Road, Mysore - 02
 Ph: 0821-4006040/41



Issue Date: 27/03/2013



भारत सरकार

Government of India

ಚಂದ್ರಕಲಾ ಎಮ್ ಎನ್

Chandrakala M N

పుట్టిన తేదీ / DOB: 21/10/1972

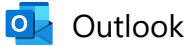
స్త్రీ / FEMALE

8737 8215 5787

शेरा आखार, शेरी पहचान



8737 8215 5787



Your appointment is confirmed

From noreply@apolloclinics.info <noreply@apolloclinics.info>

Date Fri 08-11-2024 13:33

To m.nagaraju@bankofbaroda.com <m.nagaraju@bankofbaroda.com>

Cc Mysore Apolloclinic <mysore@apolloclinic.com>; Yogeesh KV <mkt.mysore@apolloclinic.com>; Syamsunder M <syamsunder.m@apollohl.com>



Dear M N CHANDRAKALA,

Greetings from Apollo Clinics,

Your corporate health check appointment is confirmed at **KALIDASA RAOD clinic** on **2024-11-09** at **08:15-08:30**.

Payment Mode	
Corporate Name	ARCOFEMI HEALTHCARE LIMITED
Agreement Name	[ARCOFEMI MEDIWHEEL FEMALE AHC CREDIT PAN INDIA OP AGREEMENT]
Package Name	[ARCOFEMI - MEDIWHEEL - FULL BODY ANNUAL PLUS CHECK ADVANCED - FEMALE - 2D ECHO - PAN INDIA - FY2324]

"Kindly carry with you relevant documents such as HR issued authorization letter and or appointment confirmation mail and or valid government ID proof and or company ID card and or voucher as per our agreement with your company or sponsor."

Note: Video recording or taking photos inside the clinic premises or during camps is not allowed and would attract legal consequences.

Note: Also once appointment is booked, based on availability of doctors at clinics tests will happen, any pending test will happen based on doctor availability and clinics will be updating the same to customers.

Instructions to be followed for a health check:

1. Please ensure you are on complete fasting for 10-To-12-Hours prior to check.
2. During fasting time do not take any kind of alcohol, cigarettes, tobacco or any other liquids (except Water) in the morning. If any medications taken, pls inform our staff before health check.

3. Please bring all your medical prescriptions and previous health medical records with you.
4. Kindly inform our staff, if you have a history of diabetes and cardiac problems.

For Women:

1. Pregnant women or those suspecting are advised not to undergo any X-Ray test.
2. It is advisable not to undergo any health check during menstrual cycle.

For further assistance, please call us on our Help Line #: 1860 500 7788.

Clinic Address: 23, KALIDASA ROAD, VV MOHLLA, MYSORE.

Contact No: (0821) 400 6040 - 41.

P.S: Health Check-Up may take 4 - 5hrs for completion on week days & 5 - 6hrs on Saturdays, kindly plan accordingly, Doctor Consultation will be completed after all the Reports are ready.

Warm Regards,
Apollo Clinic