



## ECHOCARDIOGRAPHY REPORT

Name : Pruthvi .H.Parekh  
Regn.No. : CH-2024-0054215  
Age/Sex : 36 Years/Female

Date: 08/03/2024

### Study :

Structure	Patient Value	Normal Value
Aortic Valve annulus	26mm	<40 mm
Aortic valve Cusp separation	15mm	<18 mm
Left atrium	28mm	<40 mm
EPSS	04mm	<6 mm
Inter Ventricular Septum (diastole)	09mm	09 mm - 12 mm
Posterior Wall (diastole)	11mm	10 mm - 12 mm
LVID (diastole)	44mm	35 mm - 50 mm
LVID (systole)	28mm	24 mm - 35 mm
Ejection Fraction	60%	55 - 60 %

### Doppler Study :

Structure	Patient Value	Structure	Patient value
Mitral Valve E Wave	0.3m/s	Aortic Valve Velocity	0.64m/s
A Wave	0.7m/s	Peak aortic valve Grad	
Peak/Mean MVG		Pulmonary valve velocity	0.9m/s
MVA		Tricuspid Valve Gradient	


### Impression:

Normal Left Ventricle  
Normal LV systolic function, LVEF ~ 60 % (no RWMA at rest)  
Trivial MR  
Normal Diastolic function  
No evidence of visual Clot or vegetation  
Normal Pericardium



# CHARUSAT HOSPITAL



Patient Name : PRUTHVI HIMANSHU PAREKH	Sample No. : SAMPLE-0107730 
Patient ID : CH-2024-0054215	Visit No. : OPD/2024/03/0000415
Age/Sex : 36y/Female	Call Date : 08-Mar-2024 10:59
Referred By : KRUNAL VYAS	S. Coll. Date : 08-Mar-2024 15:07
Ward :	Report Date : 08-Mar-2024 15:09

## PP2B5

Investigation	Result	Normal Value
Post Prandial Blood Sugar (2Hrs)	109.3 mg/dl [NORMAL]	100 - 140


  
DR. NAIK BHATIA  
CONSULTANT PATHOLOGIST  
(M.B.B.S.D.C.P)

DR. KETAN KAPADIA  
CONSULTANT PATHOLOGIST  
(M.B.B.S.M.D)



# CHARUSAT HOSPITAL



Patient Name :	PRUTHVI HIMANSHU PAREKH	Sample No. :	SAMPLE-0107722 
Patient ID :	CH-2024-0054215	Visit No. :	OPD/2024/03/0000415
Age/Sex :	36y/Female	Call. Date :	08-Mar-2024 10:59
Referred By :	KRUNAL VYAS	S. Coll. Date :	08-Mar-2024 11:29
Ward :	-	Report Date :	08-Mar-2024 13:45

## Hemoglobin (HB)

Investigation	Result	Normal Value
Hemoglobin	12.0 gm/dl [NORMAL]	[M : 14-18, F : 12-16 ]

## WBC

Investigation	Result	Normal Value
R.B.C Count :	4.00 mill/c.mm [NORMAL]	[M : 4.5 - 5.5 , F : 3.8 - 5.2]
WBC :	7780 /c.mm [NORMAL]	4000 - 10000

## Platelet count

Investigation	Result	Normal Value
Platelets	3.04 Lakh/cmm [NORMAL]	1.5 - 4.5

## WBC count - Differential

Investigation	Result	Normal Value
Polymorphs	70 % [NORMAL]	40 - 70
Lymphocytes	24 % [NORMAL]	20 - 40
Eosinophils	02 % [NORMAL]	1 - 6
Monocytes	04 % [NORMAL]	2 - 10
Basophils	00 % [NORMAL]	0 - 1

## BLOOD UREA


Investigation	Result	Normal Value
Blood Urea	16.6 mg/dl [NORMAL]	15 - 40

## S.Creatinine



# CHARUSAT HOSPITAL



Patient Name : PRUTHVI HIMANSHU PAREKH	Sample No. : SAMPLE-0107722 
Patient ID : CH-2024-0054215	Visit No. : OPD/2024/03/0000415
Age/Sex : 36y/Female	Call. Date : 08-Mar-2024 10:59
Referred By : KRUNAL VYAS	S. Coll. Date : 08-Mar-2024 11:29
Ward : -	Report Date : 08-Mar-2024 13:45

### Investigation

Serum Creatinine

### Result

0.57 mg/dl [LOW]

### Normal Value

Male : 0.9 to 1.5 mg/dl  
Female : 0.8 to 1.2 mg/dl

### BUN

#### Investigation

BUN :

#### Result

8 [NORMAL]

#### Normal Value

8.0 to 23.0 (mg/dl)

### URIC ACID

#### Investigation

Serum Uric Acid

#### Result

4.10 mg/dl [NORMAL]

#### Normal Value

Male : 2.5 to 7.0  
Female : 1.5 to 6.0

### ESR

#### Investigation

ESR - After One Hour

#### Result

12 mm [HIGH]

#### Normal Value

[M : 3 - 5, F : 4 - 7]

### Blood Group

#### Investigation

ABO

#### Result

O

#### Normal Value

Rh :

Positive

### FASTING BLOOD GLUCOSE

#### Investigation

Fasting Blood Sugar :

#### Result

103.9 mg/dl [NORMAL]

#### Normal Value

70 - 110

### HBA1C

#### Investigation

Mean Blood Glucose

#### Result

131.2 mg/dl

#### Normal Value



Patient Name	PRUTHVI HIMANSHU PAREKH	Sample No. :	SAMPLE 0101122
Patient ID	CH-2024-0004215		
Age-Sex	30y/Female	Visit No. :	OPD/2024/03/000415
Referred By	KRUNAL VYAS	Coll. Date :	08-Mar-2024 10:59
Ward		B. Coll. Date :	08-Mar-2024 11:29
		Report Date :	08-Mar-2024 13:45

Hb A1c

6.2 %

- > 8 Action Suggested
- 7-8 Good Control
- < 7 Goal
- 6-7 Near Normal Glycemia
- < 6 Non-diabetic Level

### Comments

Hb A1c also known as Glycosylated Haemoglobin is the most important test for the assessment of longterm Blood glucose control (also called glycaemic control)

Hb A1c reflects mean glucose concentration over past 8-9 week and provides a much better indication of longterm glycaemic control than blood glucose determination

This Reaction is irreversible & therefore remains unaffected glucose & Haemoglobin. Long term complications of diabetes such as Retinopathy (Eye-complications)

nephropathy(Kidney-complications) & neuropathy(nerve complications) are potentially serious and can lead to blindness, kidney failure etc. Glycaemic control as monitored by Hb A1c measurement is considered most important

### TSH

Investigation	Result	Normal Value
TSH :	1.59 uIU/ml [NORMAL]	0.34 to 4.5 (uIU/ml)

### T3

Investigation	Result	Normal Value
T3-Triiodothyronine :	1.63 ng/ml [NORMAL]	0.69 to 2.15 (ng/ml)

### T4

Investigation	Result	Normal Value
T4-thyroxine :	88.4 ng/ml [NORMAL]	52.0 to 127.0 (ng/mL)


### LIPID PROFILE

Investigation	Result	Normal Value
---------------	--------	--------------



# CHARUSAT HOSPITAL



Patient Name : PRUTHVI HIMANSHU PAREKH	Sample No. : SAMPLE-0107722 
Patient ID : CH-2024-0054215	Visit No. : OPD/2024/03/0000415
Age/Sex : 36y/Female	Call. Date : 08-Mar-2024 10:59
Referred By : KRUNAL VYAS	S. Coll. Date : 08-Mar-2024 11:29
Ward : -	Report Date : 08-Mar-2024 13:45

Serum Cholesterol (Chol) :	228.6 mg/dl	<200 mg/dl Desirable 200-239 mg/dl Boderline High > 240 mg/dl High
Serum Trnglyceride :	161.4 mg/dl	<150 mg/dl Normal 150-199 mg/dl Boderline High 200-499 mg/dl High
S HDL Cholesterol	38.0 mg/dl	Men : >55, Wo : >65 Standread Risk Level Men : 35-55, Wo : 46-65 Risk Men : <35, Wo : <45
LDLC :	144.88 mg/dl	
VLDL :	45.72 mg/dl [HIGH]	10.0 to 30.0 (mg/dl)
LDL/HDL Ratio :	3.81 - [HIGH]	< 3.5
TC / HDL Ratio :	6.02 - [HIGH]	4.0 to 6.0
LDL (DIRECT) :	183.2 mg/dl [High]	< 100.0 (Optimal), 100.0 to 120.0 (Near Optimal), 130.0 to 159.0 (Border line high), 160.0 to 189.0 (High), > 190.0 (Very high)


## LIVER FUNCTION TEST

Investigation	Result	Normal Value
Total Bilirubin :	0.48 mg/dl [NORMAL]	0.0 to 1.2
Direct Bilirubin (DBIL) :	0.13 mg/dl [NORMAL]	0.0 to 0.30
ALT (SGPT) :	12.1 IU/L [NORMAL]	[0.0 - 40]
AST (SGOT) :	13.4 IU/L [NORMAL]	<= 45.0
Alkaline Phosphatase (ALP) :	107.2 IU/L [NORMAL]	15 - 80 - : 37.0 to 147.0



# CHARUSAT HOSPITAL



Patient Name : PRUTHVI HIMANSHU PAREKH	Sample No. : SAMPLE-0107722 
Patient ID : CH-2024-0054215	Visit No. : OPD/2024/03/0000415
Age/Sex : 36y/Female	Call. Date : 08-Mar-2024 10:59
Referred By : KRUNAL VYAS	S. Coll. Date : 08-Mar-2024 11:29
Ward : -	Report Date : 08-Mar-2024 13:45

Total Protein (TP) :	7.6 gm/dl [NORMAL]	[Adult 6.0 to 7.8]
Albumin (ALB) :	4.4 gm/dl [NORMAL]	3.5 to 5.0 (gm/dl)
Indirect Bilirubin (IBIL) :	0.35 [NORMAL]	0.0 to 0.75 (mg/dl)
Globulins :	3.2 gm/dl [NORMAL]	2.4 to 3.5 (gm/dl)
A/G Ratio :	1.3	


## URINE R & M

Investigation	Result	Normal Value
<b>Physical Examination :</b>		
Quantity :	10 ml	
Colour :	Pale Yellow -	
Appearance :	Clear -	
Odour :	URINIOD -	
Reaction :	Acidic -	
Specific Gravity :	1.020 -	
<b>Chemical Examination :</b>		
Albumin :	Absent -	
Sugar :	Absent -	
Bile Salts :	Absent -	
Bile Pigments :	Absent -	
Acetone :	Absent -	
Urobilinogen :	Absent -	
<b>Microscopic Examination :</b>		
Pus Cells :	1-2 -	
RBCs :	Absent -	
Epithelial cells :	3-4 -	



# CHARUSAT HOSPITAL



Patient Name :	PRUTHVI HIMANSHU PAREKH	Sample No. :	SAMPLE 0107722 
Patient ID :	CH-2024-0054215	Visit No. :	OPD/2024/03/0000415
Age/Sex :	36y/Female	Call. Date :	08-Mar-2024 10:59
Referred By :	KRUNAL VYAS	S. Coll. Date :	08-Mar-2024 11:29
Ward :	-	Report Date :	08-Mar-2024 13:45

Casts Absent -

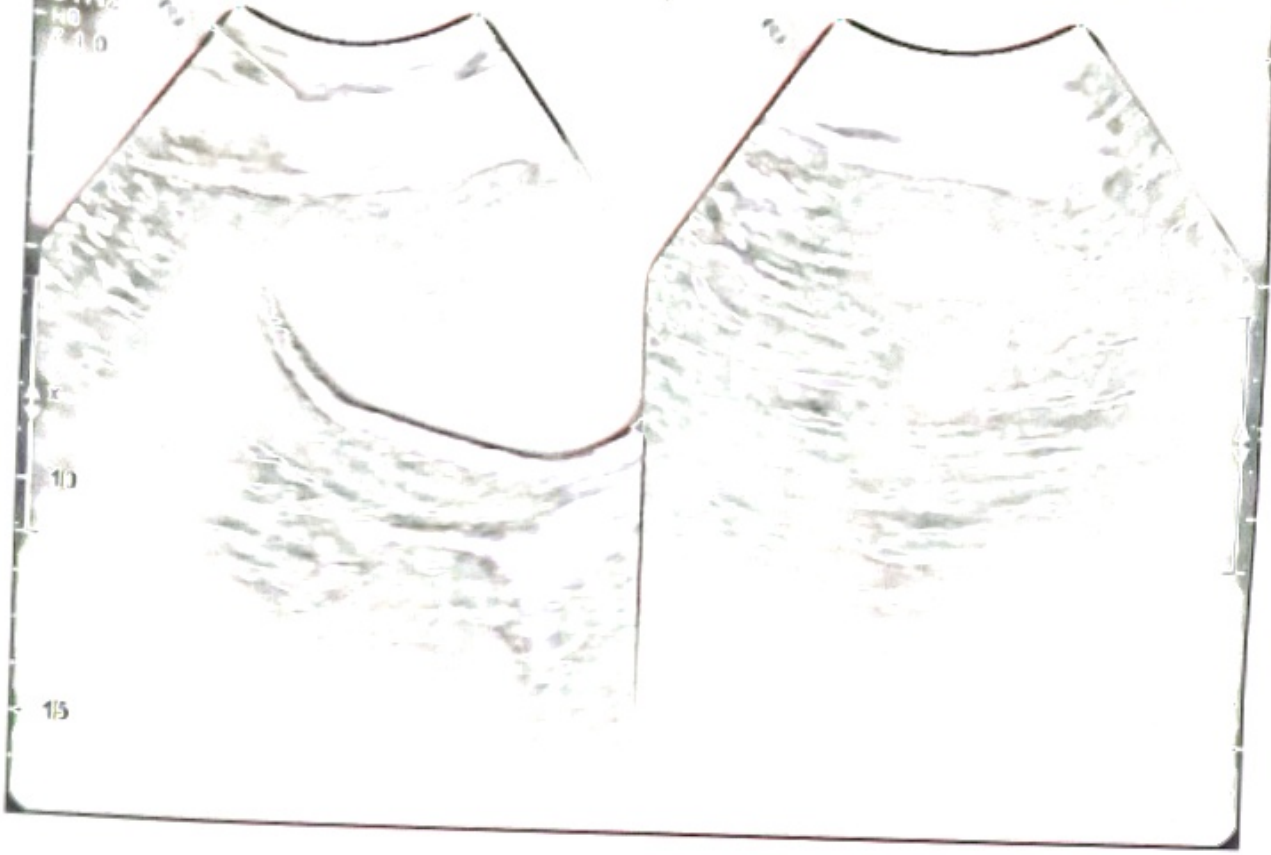Crystals Absent -

DR. NAITIK BHATIA  
CONSULTANT PATHOLOGIST  
(M.B.B.S.D.C.P)

  
DR. KETAN KAPADIA  
CONSULTANT PATHOLOGIST  
(M.B.B.S.M.D)



ABD NEW  
CS 0  
31Hz  
NO  
2.10



11.4x4.10 10.6x4.92



DATE	PATIENT NAME	AGE IN YEARS	SEX	REFERRED BY DR.	INVESTIGATION
28-03-2024	PRUTHVI H PAREKH	36	F	BODY PROFILE	UP TOTAL ABDOMEN USG

## MSG OF THE ABDOMEN/ PELVIS WAS PERFORMED

The liver is normal in size and echotexture. No focal solid or cystic lesions are seen. The intra hepatic biliary radicles are normal. The portal vein and CBD are normal. The gall bladder is well distended with no calculi or polyp. The wall is not thickened.

The pancreas reveals a normal echopattern, with no focal calcification or a neoplasm. The spleen reveals a normal sonographic features.

Both kidneys are normal in size and echotexture. Evidence of good cortico medullary differentiation is noted. No evidence of any calculi or hydronephrosis.

No free fluid or lymphadenopathy is seen.  
The urinary bladder is well distended with no calculi or polyps.

The uterus is anteverted, normal size.  
The endometrium is in the midline. No focal myoma is seen.  
Both the ovaries are normal in size and shape. No focal solid or cystic lesion is seen.

No adnexal abnormality is seen.  
No free fluid is seen in the pouch of douglas.

Size in CM.

Right	Left
Kidney	Kidney
11.23x4.18	10.63x4.92

## IMPRESSION :

**NO ABNORMALITY DETECTED.**

  
Dr. Pratik H. Parekh  
MBBS, DNB  
MEDICINE



DATE	PATIENT NAME	SEX	REFERRED BY DR	INVESTIGATION
08-03-2024	PRUTHVI H PAREKH	F	BODY PROFILE	X-RAY

### X-ray CHEST PA view.

No evidence of consolidation or infiltration seen involving both lungs.

Costophrenic sinuses are clear.

Vascular shadows are normal on both sides.

Hilar shadows show evidence of normal size, position & opacity.

Heart & aortic shadows show evidence of normal position & size.

Position of domes of diaphragm is normal. Bony cage show no abnormality.

### COMMENTS:

NO EVIDENCE OF ABNORMALITY DETECTED.

Thanks for reference  
DR KIRTI C THAKKAR  
M.B.B.S, D.M.R.D

ID: 0054215  
Name: Parakh, Pruthvi.H  
Age: 36 Years  
Gender: Male

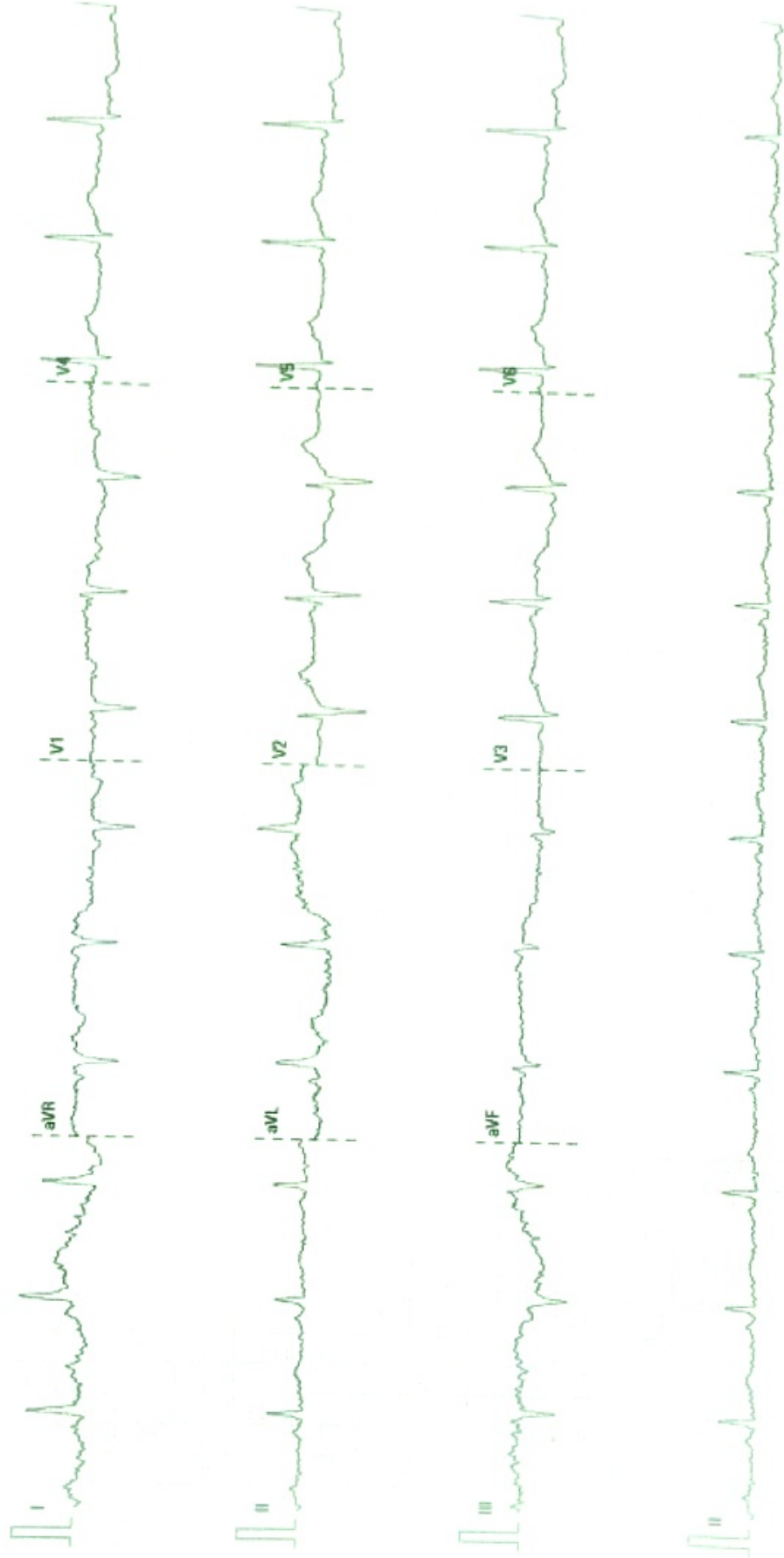
08-03-2024 11:31:29 AM

Vent. Rate  
PR Interval  
QRS Duration  
QT/QTc Interval  
P/QRS/T Axes  
QTc Hodges

77 bpm  
112 ms  
110 ms  
394/424 ms  
42/8/15 deg

Sinus rhythm

Unconfirmed Diagnosis



02.03.00.V2B 4.1 SN FN 52001667

CHARUSAT HOSPITAL

BGR 20 Hz

50 Hz

10 mm/mV

25 mm/s



**LALITABEN P. D. PATEL OPD SERVICES  
REGISTRATION FORM (OPD)**



M.O.  
Dr. Parvat Sir

Date & Time : 08-03-24

Registration No. : CH-2024-0054215

Name : Pruthvi M. Parakh Contact No. : (M) \_\_\_\_\_

Age : 36 Sex : F (O) \_\_\_\_\_

Address : \_\_\_\_\_

B.P. : 130/80 Pulse : 72 SpO<sub>2</sub> : 98

BMI : \_\_\_\_\_ Height : \_\_\_\_\_ Weight : \_\_\_\_\_

**OPD-INITIAL ASSESSMENT FORM**

Chief Complaints : Headache day up  
no any complaints

**CASE ANALYSIS**

Past History : \_\_\_\_\_  
\_\_\_\_\_  
\_\_\_\_\_

Present History : \_\_\_\_\_  
\_\_\_\_\_  
\_\_\_\_\_

G/E Vitals : \_\_\_\_\_

Systemic Examination : \_\_\_\_\_  
\_\_\_\_\_

**FAMILY HISTORY :**

- Diabetes
- IHD
- Hypertension
- Others (Specify) : \_\_\_\_\_

**PATIENT'S MEDICAL/OTHER HISTORY :**

- Hypertension
- Epilepsy
- Food Allergy
- Drug Allergy
- IHD
- Asthma
- AIDS/HIV
- Pregnancy
- T.B.
- Hepatitis B
- Bleeding Disorder
- Jaundice
- Hepatitis C

**HABBITTS :**

- Smoking
- Alcohol
- Tobacco
- Others (Specify) : \_\_\_\_\_

CHIEF/OPD/5083

Investigation/s Advised \_\_\_\_\_

Provisional Diagnosis \_\_\_\_\_

Allergy \_\_\_\_\_

Nutritional Advice \_\_\_\_\_

**TREATMENT ADVISED**

DATE	DOCTOR'S NOTE	REMARK
	<p><u>C. trachomatis</u></p> <p>NO complaint</p> <p>USG ⊕</p> <p>P<sub>3</sub>L<sub>2</sub> - P<sub>2</sub>C<sub>2</sub> Ferrelle (P<sub>2</sub>C<sub>2</sub> Act)</p> <p>1 Hysteroscopy.</p>	<p><u>Act</u></p> <p>T<sub>2</sub> 0+0-<del>1</del> 100</p> <p>As above</p>

Signature with Stamp



# DENTAL REGISTRATION FORM



Date & Time: 08/03/24

Registration No.: CH-2024-0054215

Name: Pruthvi H. Purohit

Contact No.: \_\_\_\_\_

Age: 36

Emergency Contact No.: \_\_\_\_\_

Sex: F

Address: \_\_\_\_\_

## OPD-INITIAL ASSESSMENT FORM

Chief Complain: Routine checkup.

### Family History :

- Diabetes
- Hypertension
- IHD
- Others (Specify) :

Habits :  Tobacco

- Hypertension
- Diabetes
- Epilepsy
- Bleeding Disorder
- Smoking

### Medical/Other History :

- IHD
- Asthma
- AIDS/HIV
- Pregnancy
- Other (Specify) :
- T.B.
- Hepatitis B
- Food Allergy
- Others (Specify) :
- Jaundice
- Hepatitis C
- Drug Allergy

### સંમતિ પત્રક

હું \_\_\_\_\_ ડાહરને મારી સારવાર કરવાની મંજૂરી આપું છું. આ સારવારની પૂરેપૂરી ખર્ચ, ડાહરા-ગેરડાહરા, દવાની કે ઇન્જેકશનની કાસ કાસર અને સારવારની સફળતા, નિષફળતા વિશે મને તમારા મારા સંબંધીઓને સમજૂતી આપેલ છે. મેં ડાહરને મારી વાર્ષિક સ્થિતિ તથા તેને લગતી દવા વિશે સંપૂર્ણ માહિતી આપેલ છે. જો કોઈપણ સંજોગોમાં સારવાર આપતી ડોક્ટર કે અભિવ્યક્તિ રહીશ તો તેની નિષફળતા માટે ડાહર કે આરુપેટ હોસ્પિટલ જવાબદાર નથી. તમારા સારવારની ડિપોઝીટ પેટે આપેલ રકમ મેળવવા માટે હકકાર રહીશ બહી. આ સંમતિ હું સ્વેચ્છાએ કોઈપણ દવાલ ઘાસર આપું છું.

ડાહરનું \_\_\_\_\_

જાણકું : \_\_\_\_\_

\_\_\_\_\_

દર્દી / સગાની સહી

### CONSENT

I \_\_\_\_\_ hereby request and authorize Doctor \_\_\_\_\_ to perform the required dental treatment. Doctor has informed me and my relatives about the treatment plan in details with success and failure of the treatment with all expenditure, possible complications from medicines or local anesthesia. I have informed the Doctor about my medical history and drug history in details. If in any circumstances, I am irregular or leave the treatment in between, the doctor and CHARUSAT Hospital will not be responsible for the same and treatment charges will not be returned back.

I give my consent to proceed with my dental treatment.

Date : \_\_\_\_\_

Time : \_\_\_\_\_

Patient's / Relative's Sign.

Investigation Advised : \_\_\_\_\_

Final Diagnosis : Missing 6/6, 6/7

Treatment Plan : \_\_\_\_\_

Date : 8/3/24

Name of Doctor Dr. Manishwani

Time : \_\_\_\_\_

Signature : \_\_\_\_\_

## DENTAL DEPARTMENT

Follow up

DATE	DOCTOR'S NAME	ESTIMATE	AMOUNT PAID	AMOUNT DUE
	<p style="text-align: center;">Dr. Surgery</p> <p>(10) on 21 9 for pain  <u>Adh</u>                      - Contrast bath                      - Plantar fascia stretching cream                      - hot post-ureum                      Hwy</p>			

Dr. Surgery





# OPHTHALMIC REGISTRATION FORM



Reg No : CH-2024-0054215

Date : 08-03-24

Patient's Name : Pruthvi N. Parekh Age : 36/F

Address : \_\_\_\_\_

Telephone No. : \_\_\_\_\_ Mobile No. : \_\_\_\_\_

Referred by / Care of : Routine Eye check up

Profession : \_\_\_\_\_

Type or work in daily routine : Driving / Watching TV / Computer / Reading / \_\_\_\_\_

History / Complain of : Diminution of Vision / Pain / Watering / Redness / Eyeache / Headache / Itching / Stickiness / Swelling / Irritation / Burning / F. B. Sensation / Photophobia / Diplopia / Squinting / Blackout / Floaters / Flashes / Injury /

Eye Involve : RE / LE / BE Duration : \_\_\_\_\_

Ophthalmic History : Surgery / Laser / FFA / Oct / Glaucoma / RP / Corneal Opacity / Injury / Amblyopia / Treatment

Any Surgery : Cataract / Glaucoma / Nil / RE / LE / BE

Family History : Glaucoma / RP / DM / Nil

SYSTEMIC : DM / HT / IHD / COPD / PROSTATE / WROID / ALLERGY / SMOKING / ALCOHOL Nil  
h/o glasses @ yrs. glasses @ yr old.

**EYE DETAILS :**

	<b>RE</b>	<b>LE</b>
V/A with <del>PH</del> <u>glasses</u>	<u>6/9</u>	<u>6/9</u>
IOP	<u>16 mm Hg</u>	<u>18 mm Hg</u>
OWN GLASS :	<u>-5.00 / -0.25 X 180</u>	<u>-5.75 / -0.25 X 153</u>
AR :	<u>-6.50 / -0.25 X 60</u>	<u>-5.50 / -0.25 X 80</u>

## GLASS PRESCRIPTION

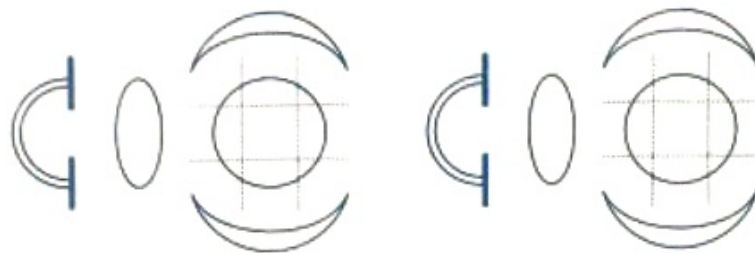
	R. E. V/A			L. E. V/A		
	SPH.	CYL.	AXIS	SPH.	CYL.	AXIS
Dis	-6.00	-0.25 X 180	6/9	-5.75	-0.25 X 150	6/9
Nr.						
Comp						

Bifocal / Distant / Near only / Constant / Progressive / Photocromatic

Remark : \_\_\_\_\_  
Signature : \_\_\_\_\_

CHH/OPH/5089

- |               |  |  |
|---------------|--|--|
| Lid           | <input checked="" type="checkbox"/> Swelling / Style / Chalazion / Entropion / Ectropion<br>Blepharitis / Meibominitis                                     | <input checked="" type="checkbox"/> Swelling / Style / Chalazion / Entropion / Ectropion<br>Blepharitis / Meibominitis                                     |
| Lacrimal :    | <input checked="" type="checkbox"/> Swelling / Patent / Partially Patent / Block<br>Punctual Stenosis  | <input checked="" type="checkbox"/> Swelling / Patent / Partially Patent / Block<br>Punctual Stenosis  |
| Conjunctiva : | Chemosis / Congestion / Pterygium / Pingecula  | Chemosis / Congestion / Pterygium / Pingecula  |
| Cornea :      | <input checked="" type="checkbox"/> Clear / Vasculi / Arcus Opacity / Adh Leucoma<br>Epi Defect / Ulcer / Keratitis / Spk                                  | <input checked="" type="checkbox"/> Clear / Vasculi / Arcus Opacity / Adh Leucoma<br>Epi Defect / Ulcer / Keratitis / Spk                                  |
| A/C :         | <input checked="" type="checkbox"/> Shallow / Deep / Hypopyon / Hypheama   | <input checked="" type="checkbox"/> Shallow / Deep / Hypopyon / Hypheama   |
| Pupil :       | <input checked="" type="checkbox"/> Non / Semi Full / Dilated / Synechia / Exfo<br>Pbi / Bi / Irregular / Synechia / Atrophy / Membrane                    | <input checked="" type="checkbox"/> Non / Semi Full / Dilated / Synechia / Exfo<br>Pbi / Bi / Irregular / Synechia / Atrophy / Membrane                    |
| Cataract :    | <input checked="" type="checkbox"/> Cortical / Post Polar / Post subcapsular<br>Nuclear : Grey / Yellow / Brown / Black / Mature<br>Pseudophakia / Aphakia | <input checked="" type="checkbox"/> Cortical / Post Polar / Post subcapsular<br>Nuclear : Grey / Yellow / Brown / Black / Mature<br>Pseudophakia / Aphakia |
| Ant Vit :     | <input checked="" type="checkbox"/> Cells Tobacco Dusting /  | <input checked="" type="checkbox"/> Cells Tobacco Dusting /  |
| Glow :        | <input checked="" type="checkbox"/> Normal / White / Yellow /  | <input checked="" type="checkbox"/> Normal / White / Yellow /  |

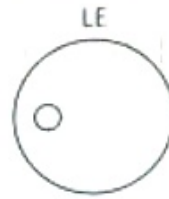
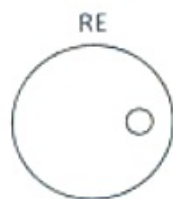


**SPECIAL NOTE**

**FUNDS**

- OD**
- Media : Clear / VH / Vitritis / Asteroid / Synchronis
- Disc :  Wnl / Pallor / Edema / Cupping \_\_\_\_\_ / NVD
- B/V :  NAD / BRVO / BRAO / CRVO / CRAG  
 Hemi CRVO / CSCR / ERM / CME / CSME
- Macula : FR N / DULL / CSCR / ERM / CME / CSME  
 MH / LMH / CNVM / DRUSEN / GA / HMD  
HGE / ATROPHY / PIGMENT / IJT / ESUDATES
- Cataract : N / MYOPIA / TEES / PIGMENT / HGE / CWS /  
 EXUDATES / HGE / VH / SUBHYALOID / TERA / RD /  
CD / COLOBOMA / BUCKLE / LASER / CRYO / MARKS

- OS**
- Media : Clear / VH / Vitritis / Asteroid / Synchronis
- Disc :  Wnl / Pallor / Edema / Cupping \_\_\_\_\_ / NVD
- B/V :  NAD / BRVO / BRAO / CRVO / CRAG  
 Hemi CRVO / CSCR / ERM / CME / CSME
- Macula : FR N / DULL / CSCR / ERM / CME / CSME  
 MH / LMH / CNVM / DRUSEN / GA / HMD  
HGE / ATROPHY / PIGMENT / IJT / ESUDATES
- Cataract : N / MYOPIA / TEES / PIGMENT / HGE / CWS /  
 EXUDATES / HGE / VH / SUBHYALOID / TERA / RD /  
CD / COLOBOMA / BUCKLE / LASER / CRYO / MARKS



REMARK / INVESTIGATION : (BE) Refractive Error.

GONIO / OM

**X**

**X**

COLOR VISION

FIELD OF VISION


FFA / OCT

BSCAN / ASCAN

K READING K1 45.75 @ 146  
K2 45.50 @ 146

K1 44.75 @ 49  
K2 45.50 @ 49

IOL POWER



DR. H. P. PAREKH 38Y/M  
CH-9120-9954310

CHEST PA

SHARUSAT HOSPITAL, CHANGA

CHANGA, DIST. SURAT