

भारत सरकार
Government of India
Unique Identification Authority of India

Address: W/O Raj Ranjan, Flat No 31 2nd Floor Vivekanand Appt. Madhuban Chowk, Rohini, Sector 8, Rohini Sector 8, North West Delhi, Delhi - 110085

पता: राज रंजन, फ्लैट नं 31 दूसरा फ्लोर विवेकानंद अपार्ट, मधुबन चौक, रोहिणी, विभाग 8, रोहिणी सेक्टर 8, उत्तर पश्चिमी, दिल्ली - 110085

2580 8803 0993

www.uidai.gov.in

Khushboo Kumari

Dr. POOJA SARG
M.B.B.S., D.M.R.D
Reg No. DMCTR/03398
Radiologist

भारत सरकार
Government of India

खुशबू कुमारी
Khushboo Kumari
जन्म तिथि/DOB: 05/01/1987
भारत/ FEMALE

2580 8803 0993

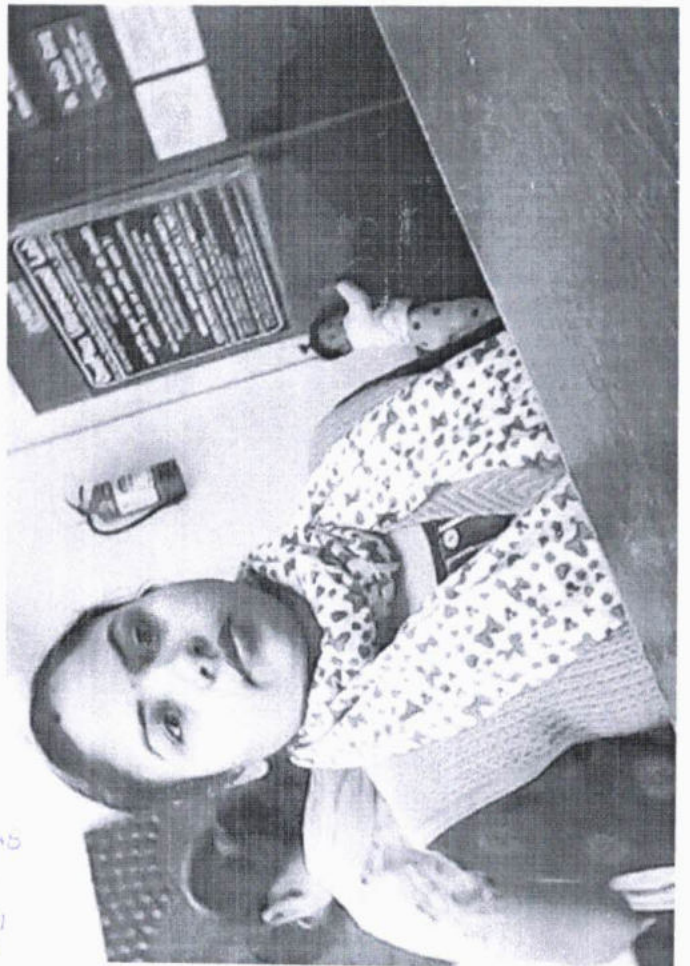मेरा आधार, मेरी पहचान

ONEPLUS ULTRASOUND LAB
47, Harsh Vihar, Pitam Pura,
Delhi-110034
Ph. 011-42480101, 9599913051
E-mail: oneplusul@gmail.com

Khushboo Karmari


Dr. POOJA GARG
M.B.B.S., D.M.R.D
Reg No. DMC/R/03398
Radiologist

ONEPLUS ULTRASOUND LAB
47, Harsh Vihar, Pitam Pura,
Delhi-110034
Ph. 011-42480101, 9599913051
E-mail: oneplusul@gmail.com



ONEPLUS ULTRASOUND LAB

47, HARSH VIHAR, PITAMPURA, DELHI- 110034

Ms. KHUSHBOO KUMARI

Age : 36/F
 Ref. by : MEDIWHEEL
 Indication1 :
 Indication2 :
 Indication3 :
 COMMENTS : Normal ECG.

ID : 2120
 H/W : 147/57
 Recorded : 25-2-2023 11:09
 Medication1 :
 Medication2 :
 Medication3 :

BPM : 93
 BP : 120/84
 P Axis : 69 deg
 QRS Axis : 55 deg
 T Axis : 41 deg

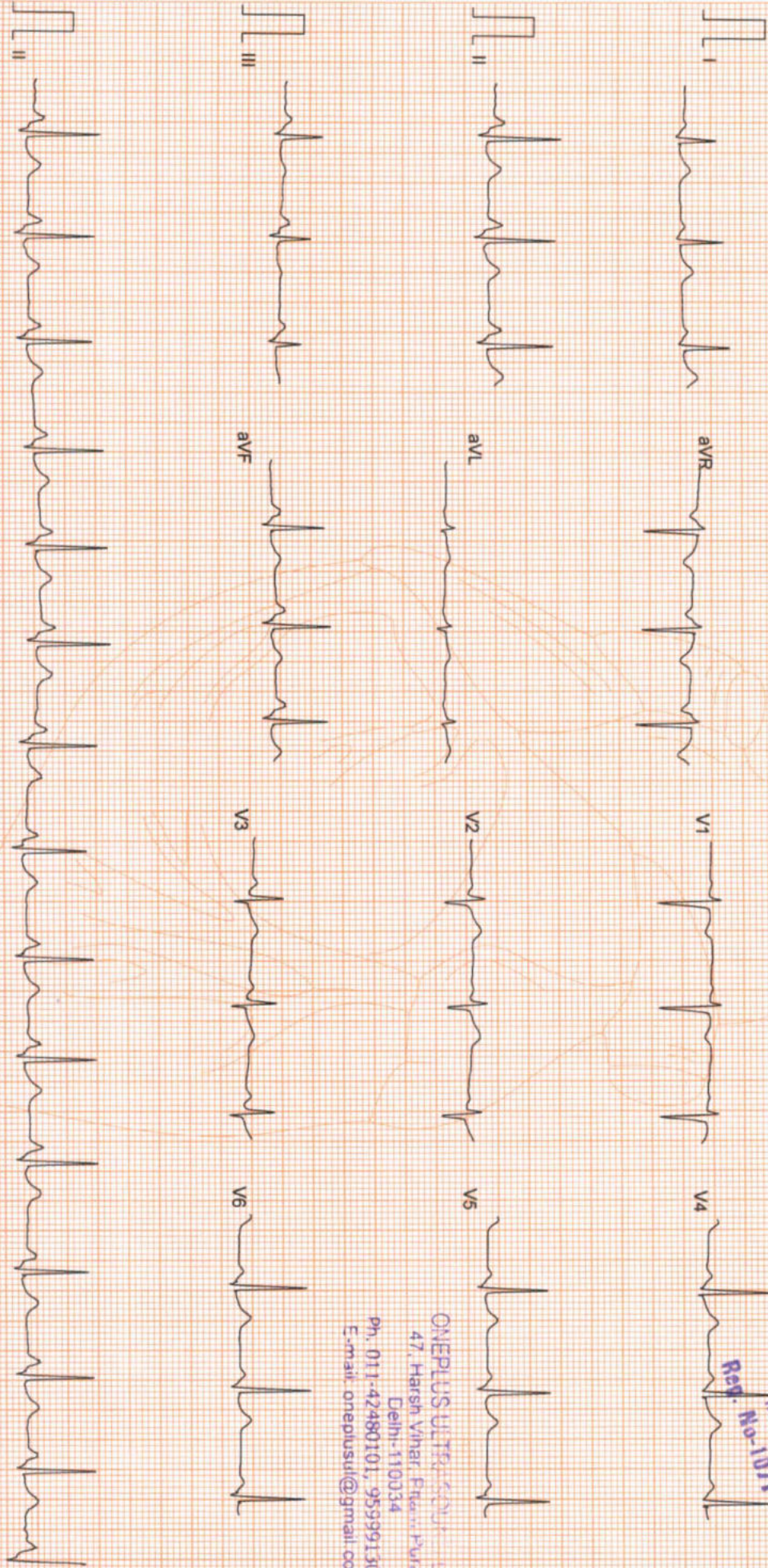
P duration : 83 msec
 PR duration : 116 msec
 QRS duration : 103 msec
 QT Interval : 290 msec
 QTc Interval : 347 msec

Raw E.C.G.(Seq)

Khushboo Kumari
 Cardiologist

Unconfirmed Report Reviewed By:

Dr. Anshu Gupta
 MBBS, MD
 Reg. No-10711



ONEPLUS ULTRASOUND LAB
 47, Harsh Vihar, Pitampura,
 Delhi-110034
 Ph. 011-42480101, 9599915051
 E-mail: oneplusul@gmail.com

Filtered

25mm/sec 10mm/mV

CardiCom, INDIA

ONEPLUS ULTRASOUND LAB

47, HARSH VIHAR PITAMPURA DELHI 110034

Ms. KHUSHBOO KUMARI

ID : 993

HMWT : 147/57
Recorded : 25-2-2023 11:11

Age : 36/F
Ref. by : MEDIMWHEEL
Indication 1 :
Indication 2 :
Indication 3 :

TREADMILL TEST SUMMARY REPORT
Protocol : BRUCE
History :
Medication 1 :
Medication 2 :
Medication 3 :

PHASE	PHASE TIME	STAGE TIME	SPEED (Km./Hr.)	GRADE (%)	H.R (BPM)	B.P (mmHg)	RPP X:100	II	ST LEVEL (mm) V2	V5	METS
SUPINE STANDING					92 89	120/84 120/84	110 106	0.6 0.7	0.9 0.9	0.4 0.4	
STAGE 1	2:59	2:59	2.70	10.00	135	120/84	162	0.9	0.8	0.9	4.80
STAGE 2	5:59	2:59	4.00	12.00	151	130/88	196	1.1	1.8	0.9	7.10
STAGE 3	7:29	1:29	5.40	14.00	167	150/90	250	1.3	1.8	1.2	8.54
PEAK EXER	7:30	1:30			165	150/90	247	1.3	1.7	1.2	8.56
RECOVERY	2:59	2:59	0.00	0.00	101	122/84	123	0.1	1.1	0.6	

RESULTS

Exercise Duration : 7:30 Minutes
Max Heart Rate : 167 bpm 90 % of target heart rate 184 bpm
Max Blood Pressure : 150/90 mmHg
Max Work Load : 8.56 METS
Reason of Termination :

Negative for inducible ischemia

Dr. Vishal
Cardiologist
01-11-1983, MD
Reg. No-1071

Khushboo Kumari

ONEPLUS ULTRASOUND LAB

47, Harsh Vihar, Pitam Pura,
Delhi-110034
Ph. 011-42480101, 9553913051
Email: oneplusul@gmail.com

Ms. KHUSHBOO KUMARI

I.D. : 993

AGE/SEX : 36/F

RECORDED : 25-2-2023 11:11

RATE : 92 BPM

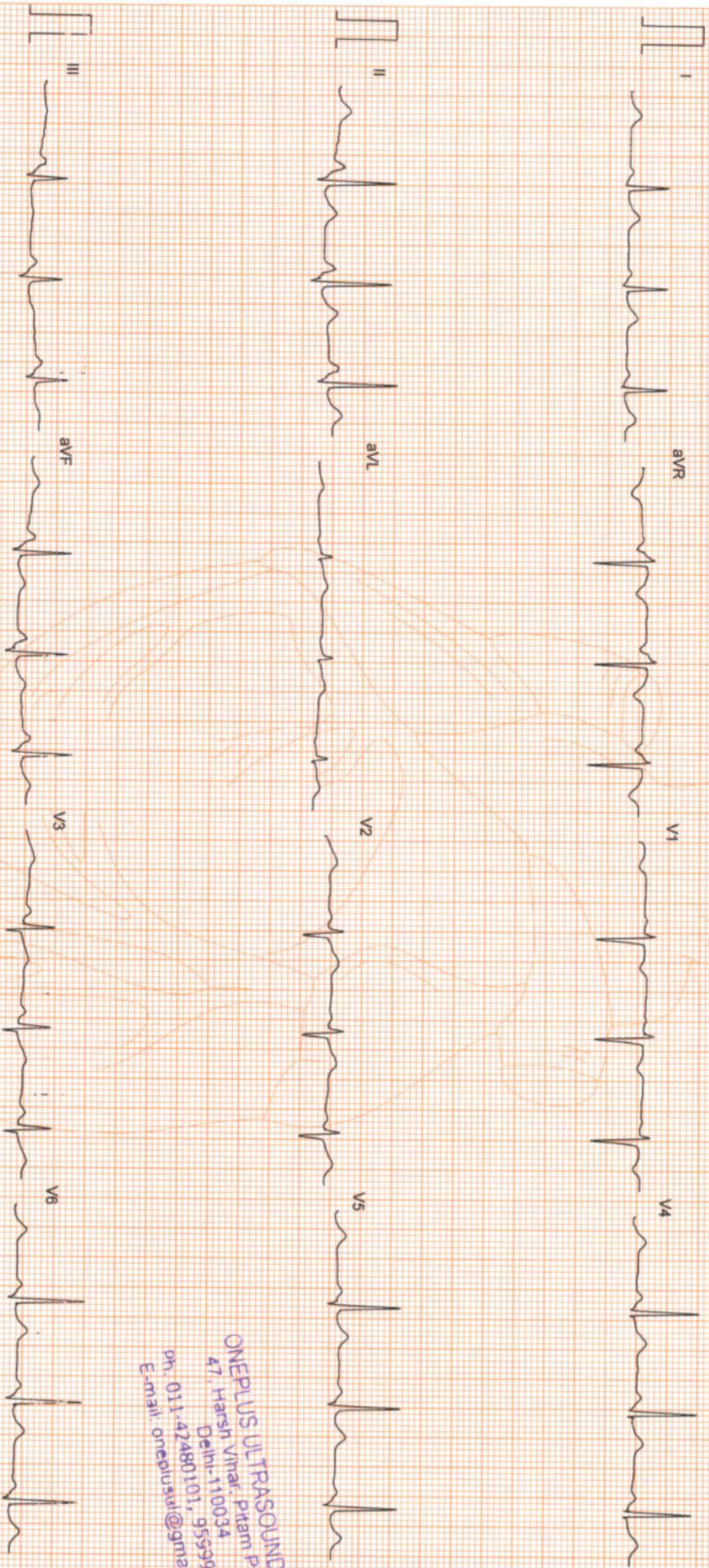
B.P. : 120/84 mmHg

ONEPLUS ULTRASOUND LAB

SUPINE
PRETEST

ST @ 10mm/mV
80ms PostJ

RAW E.C.G.



ONEPLUS ULTRASOUND LAB
 47, Harsh Vihar, Pitam Pura,
 Delhi-110034
 Ph. 011-42480101, 9559913051
 E-mail: oneplusul@gmail.com

Filtered

25mm/sec 10mm/mV

CardCom, INDIA Ph.:091-731-2620740, Telefax:091-731-2431214

ONEPLUS ULTRASOUND LAB

STANDING
PRETEST

ST @ 10mm/mV
80ms PostJ

Ms. KHUSHBOO KUMARI

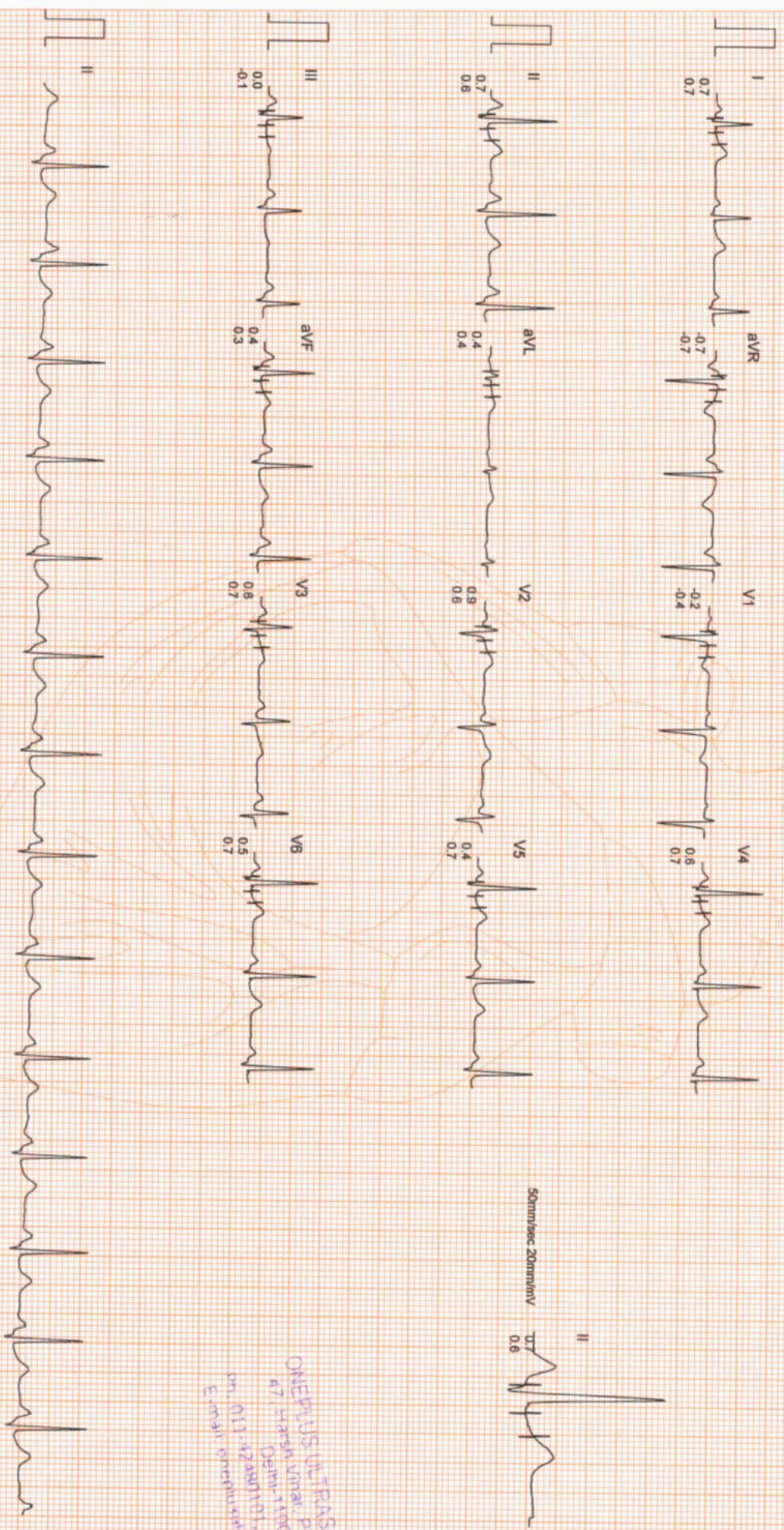
I.D. : 993

AGE/SEX : 36/F

RECORDED : 25-2-2023 11:11

RATE : 89 BPM
B.P. : 120/84 mmHg

LINKED MEDIUM



50mm/sec 20mm/mV

ONEPLUS ULTRASOUND LAB
47, Harsh Vihar, Patna-700034
Delhi-110034
Ph. 011-42481101, 9553913055
Email: oneplusul@gnail.com

ONEPLUS ULTRASOUND LAB

Ms. KHUSHBOO KUMARI

I.D. : 993

AGE/SEX : 36/F

RECORDED : 25-2-2023 11:11

RATE : 135 BPM

B.P. : 120/84 mmHg

BRUCE

EXERCISE 1

PHASE TIME : 2:59

STAGE TIME : 2:59

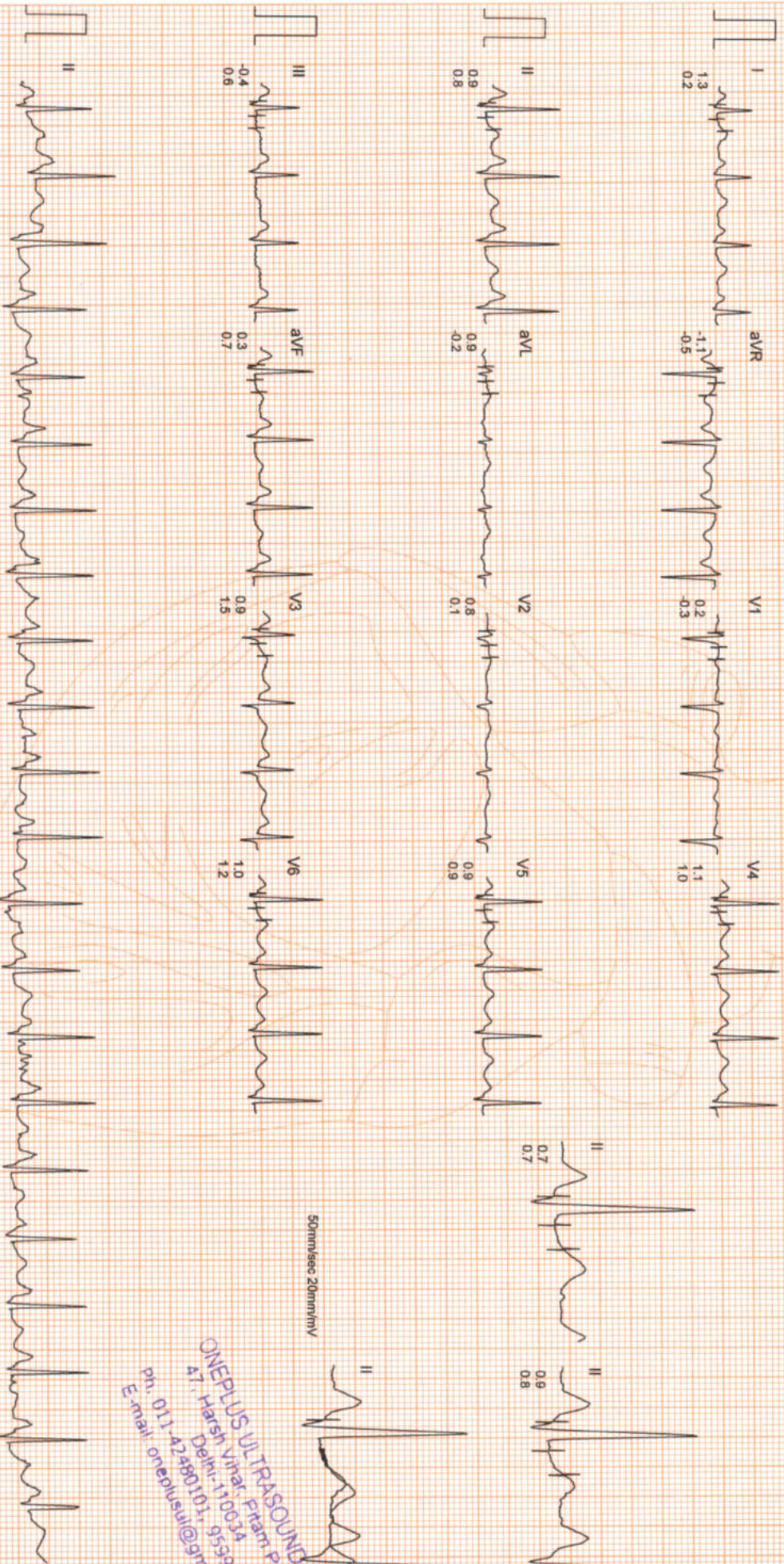
ST @ 10mm/mV

80ms PostJ

SPEED : 2.7 Km./Hr.

GRADE : 10.0 %

LINKED MEDIAN



50mm/Sec 20mm/mV

ONEPLUS ULTRASOUND LAB
47, Harsh Vihar, Pitam Pura,
Delhi-110034
Ph. 011-4288101, 9559913051
E-mail: oneplusul@gmail.com

Filtered

Computer Corrected Baseline

25mm/Sec 10mm/mV

CardiCom, INDIA Ph.: 091-731-2620740, TeleFax: 091-731-2431214

ONEPLUS ULTRASOUND LAB

Ms. KHUSHBOO KUMARI

I.D. : 993

AGE/SEX : 36/F

RECORDED : 25-2-2023 11:11

RATE : 151 BPM

B.P. : 130/88 mmHg

BRUCE

EXERCISE 2

PHASE TIME : 5:59

STAGE TIME : 2:59

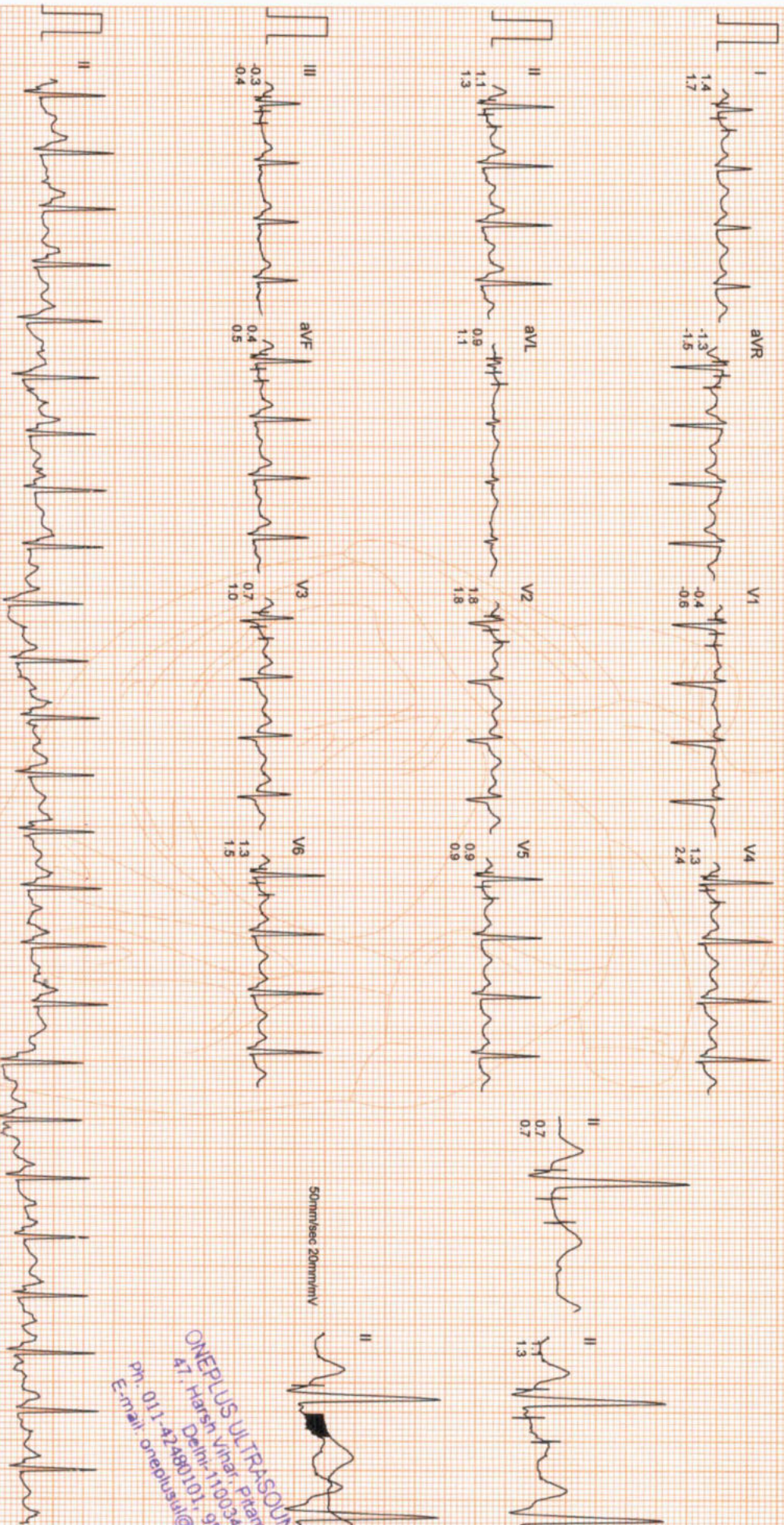
ST @ 10mm/mV

80ms PostJ

SPEED : 4.0 Km./Hr.

GRADE : 12.0 %

LINKED MEDIAN



50mm/sec 20mm/mV

ONEPLUS ULTRASOUND LAB
47 Harsh Vihar Pitam Pura
Delhi-110034
Ph: 011-42480101, 9559913051
E-mail: oneplusul@gmail.com

Filtered

Computer Corrected Baseline

25mm/sec 10mm/mV

CardiCom, INDIA Ph.:091-731-2620740, TeleFax:091-731-2431214

ONEPLUS ULTRASOUND LAB

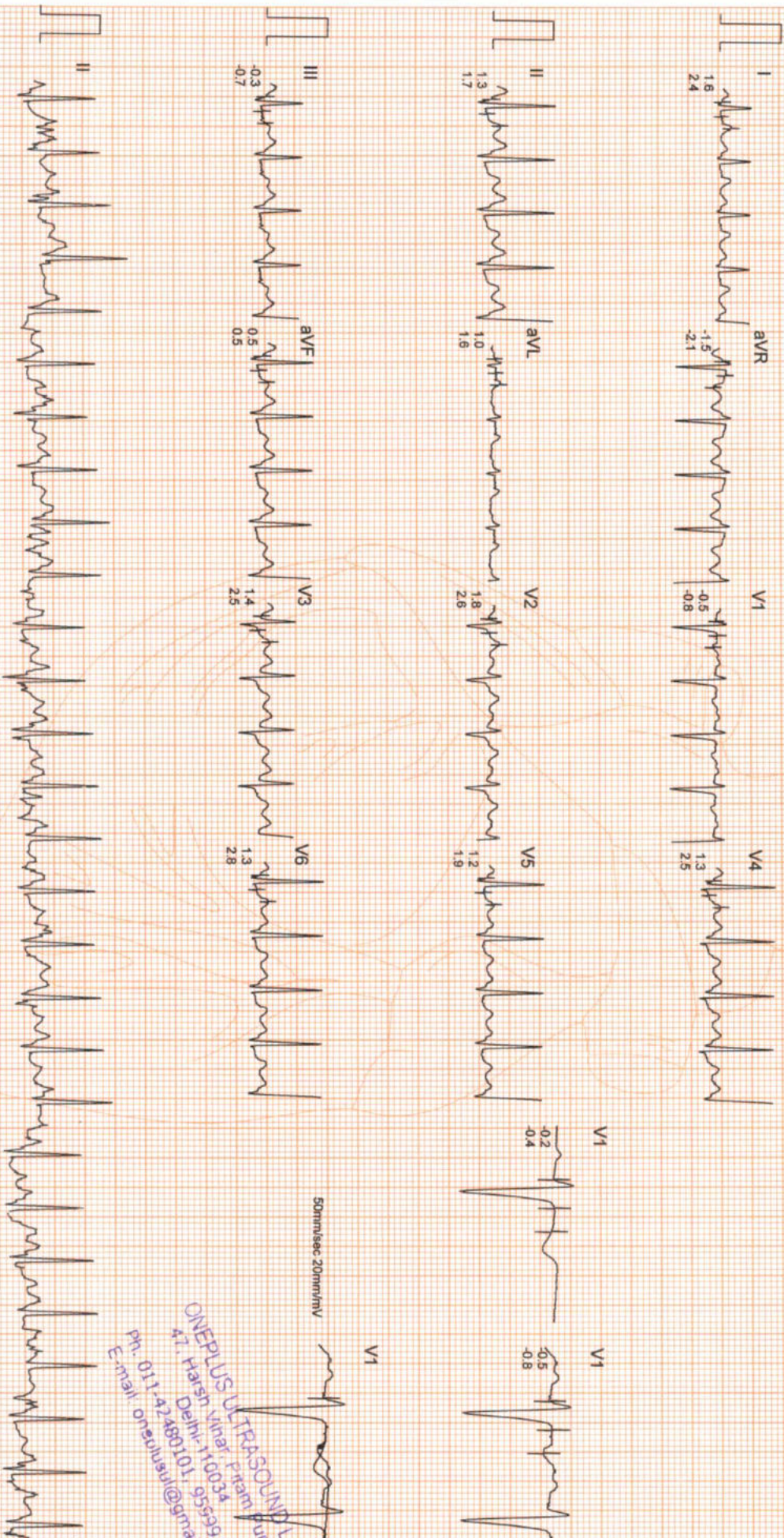
Ms. KHUSHBOO KUMARI
I.D. : 993
AGE/SEX : 36/F
RECORDED : 25-2-2023 11:11

RATE : 167 BPM
B.P. : 150/90 mmHg

BRUCE
EXERCISE 3
PHASE TIME : 7:29
STAGE TIME : 1:29

ST @ 10mm/mV
80ms PostJ
SPEED : 5.4 Km./HR.
GRADE : 14.0 %

LINKED MEDIAN



ONEPLUS ULTRASOUND LAB
47, Harsh Vihar, Farangpora,
Delhi-110034
Ph: 011-42480101, 9555915051
E-mail: onepplus@gmail.com

ONEPLUS ULTRASOUND LAB

Ms. KHUSHBOO KUMARI

I.D. : 993

AGE/SEX : 36/F

RECORDED : 25-2-2023 11:11

RATE : 165 BPM

B.P. : 150/90 mmHg

BRUCE

PEAK EXER

PHASE TIME : 7:30

STAGE TIME : 1:30

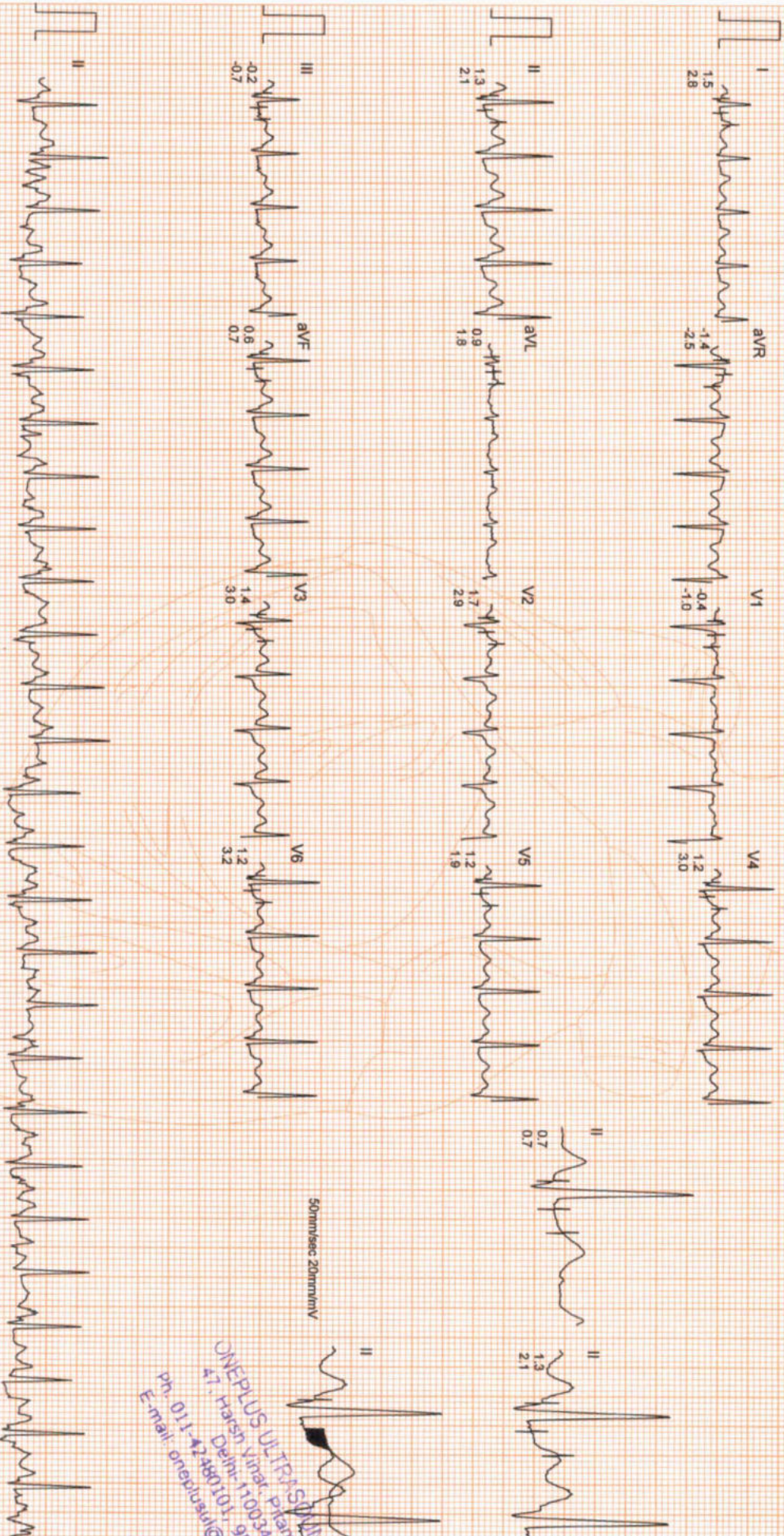
ST @ 10mm/mV

80ms PostJ

SPEED : 5.4 Km./Hr.

GRADE : 14.0 %

LINKED MEDIAN



50mm/sec 20mm/mV

ONEPLUS ULTRASOUND LAB
A-7, Harsh Vihar, Pitam Pura,
Delhi-110034
Ph: 011-2480101, 9539919051
E-mail: oneplusul@gmail.com

Filtered

Computer Corrected Baseline

25mm/sec 10mm/mV

CardiCom, INDIA Ph: 091-731-2620740, Telefax: 091-731-2431214

ONEPLUS ULTRASOUND LAB

Ms. KHUSHBOO KUMARI

I.D. : 993

AGE/SEX : 36/F

RECORDED : 25-2-2023 11:11

RATE : 101 BPM

B.P. : 122/84 mmHg

BRUCE

RECOVERY

PHASE TIME : 2:59

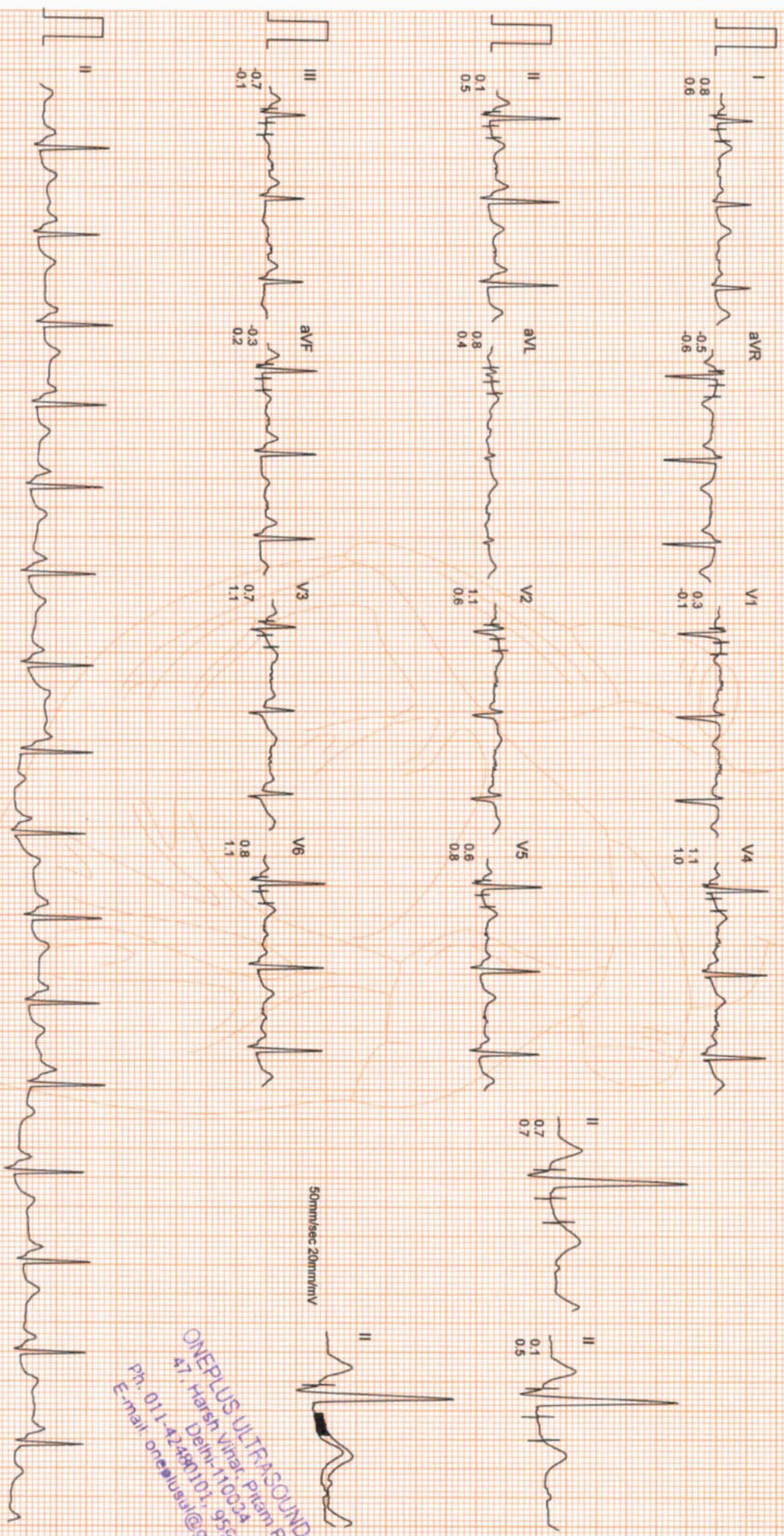
ST @ 10mm/mV

80ms PostJ

SPEED : 0.0 Km./Hr.

GRADE : 0.0 %

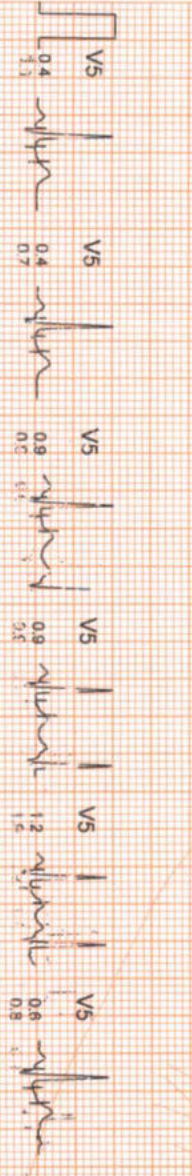
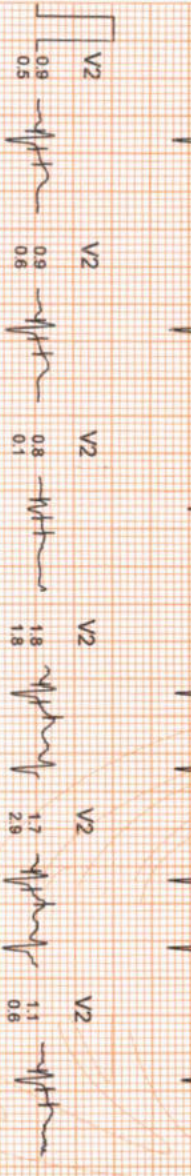
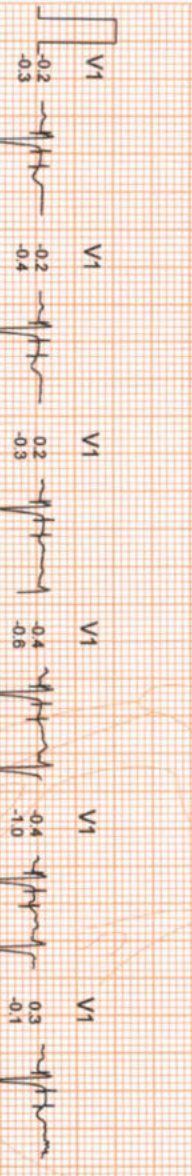
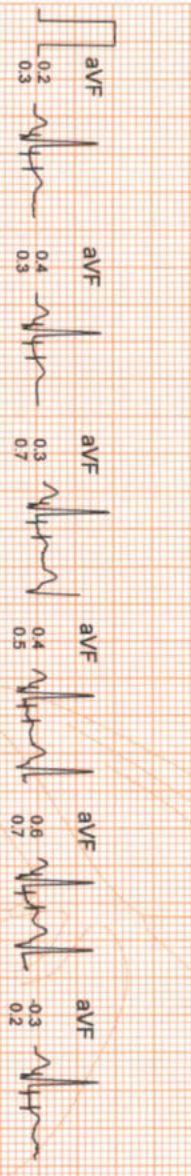
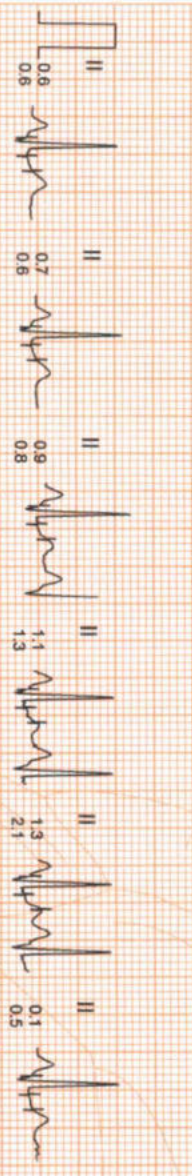
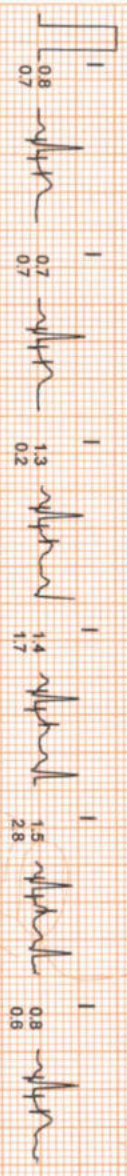
LINKED MEDIAN



ONEPLUS ULTRASOUND LAB
47, Harish Vihar, Pitam Pura,
Delhi-110034
Ph: 011-42491101, 95559613053
E-mail: oneplusul@gmail.com

ONEPLUS ULTRASOUND LAB

SUPINE	STANDING	STAGE 1	STAGE 2	PEAK EXERCISE	RECOVERY
0.0kmph 0.0% 92 bpm B.P. 120/84 80ms Postu	0.0kmph 0.0% 89 bpm B.P. 120/84 80ms Postu	2.59 2.59 2.7kmph 10.0% 135 bpm B.P. 120/84 80ms Postu	5.59 2.59 4.0kmph 12.0% 151 bpm B.P. 130/88 80ms Postu	7.30 1.30 5.4kmph 14.0% 165 bpm B.P. 150/90 80ms Postu	2.59 0.0kmph 0.0% 101 bpm B.P. 122/84 80ms Postu



ONEPLUS ULTRASOUND LAB
 47, Harsh Vihar, Pitam Pura,
 Delhi-110034
 Ph: 011-42480101, 9599913051
 E-mail: oneplusul@gmail.com

ONEPLUS ULTRASOUND LAB

STANDING

0.0kmph
0.0%
89 bpm
B.P. 120/84
80ms PostU

PEAK EXERCISE

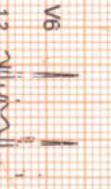
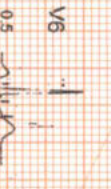
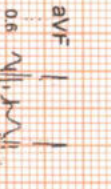
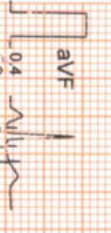
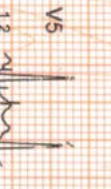
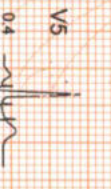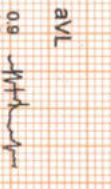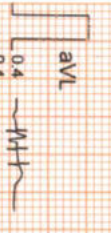
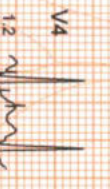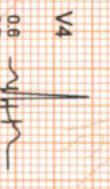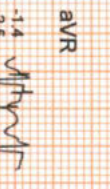

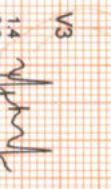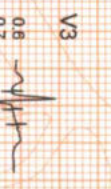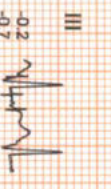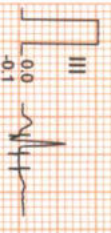
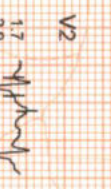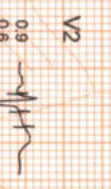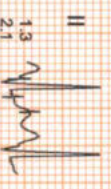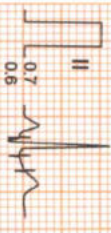
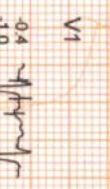
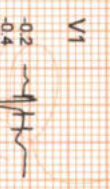

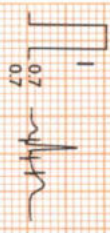
7.30
1.30
5.4kmph
14.0%
165 bpm
B.P. 150/90
90ms PostU

STANDING

0.0kmph
0.0%
89 bpm
B.P. 120/84
80ms PostU

PEAK EXERCISE

7.30
1.30
5.4kmph
14.0%
165 bpm
B.P. 150/90
80ms PostU





OnePLUS
Ultrasound Lab
— QUALITY FIRST... ALWAYS! —

Dr. Nitin Agarwal

Pathologist & Director
Ex. Sr. Res. MAMC
& Lok Nayak Hospital
Ex. Chief of Lab Dr. Lal Path Labs.

Dr. Pooja (Garg) Agarwal

Radiologist & Director
MAMC & Lok Nayak Hospital

To

The One Plus
ultrasound Lab
Harsh vihar

Dear sir/mam my self khushboo kumari (Ec no
74342 Bank of Baroda) I am
not provided stool for test
So stool test is not possible
through Lab.

khushboo kumari
28/02/2023

ONEPLUS ULTRASOUND LAB
47, Harsh Vihar, Pitam Pura,
Delhi-110034
Ph. 011-42480101, 9599913051
E-mail: oneplusul@gmail.com

47, Harsh Vihar, Pitampura, New Delhi-110034 | Ph.: 011-42480101, 9599913051
E-mail: oneplusul@gmail.com | Web.: www.oneplusul.in

Clinical correlation is essential for final diagnosis. • If test results are unsatisfactory please contact personally or on phone. • This report is for perusal of doctors only.
• All disputes Subject to Delhi Jurisdiction only. • Not for medicolegal purposes. • All congenital anomalies in a foetus may not be diagnosed in routine obstetric ultrasound.

Name	: Mrs. KHUSHBOO KUMARI	Age/Sex	: 36 YRS/Female
Ref. By	: Dr. MEDIWHEEL	Lab No	: 012302250010
Date	: 25-Feb-2023	Patient ID	: LSHHI109742

ULTRASOUND EXAMINATION----WHOLE ABDOMEN

Liver is normal in size and outline with normal echopattern. No abscess or mass lesion seen. Hepatic veins, portal vein, IVC and aorta are normal. Intrahepatic biliary radicles are not dilated. CBD is normal in caliber (4.3 mm).

Gall bladder is well distended with anechoic lumen. Wall thickness is normal.

Both kidneys are normal in size, shape, position, outline and echopattern. Corticomedullary differentiation is maintained. No pelvicalyceal dilation or calculus or mass lesion is seen.

Spleen is normal in size and echotexture. No mass lesion seen.

Pancreas is normal in size, outline and echotexture.

Urinary bladder is normal in shape and position. No evidence of intravesical stone or mass seen.

Uterus is normal in size (measures 9.3 x 3.6 x 2.8 cm), shape, position and echopattern. No mass seen.

Uterine cavity is empty. **Endometrial thickness** is 6.5 mm.

Both ovaries appear normal in size, shape and echopattern. No tubo-ovarian mass seen.

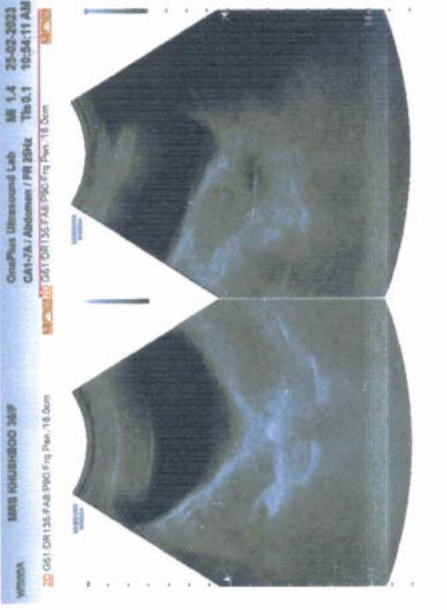
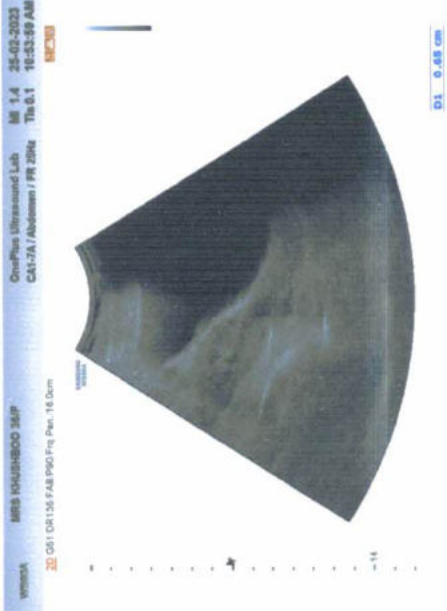
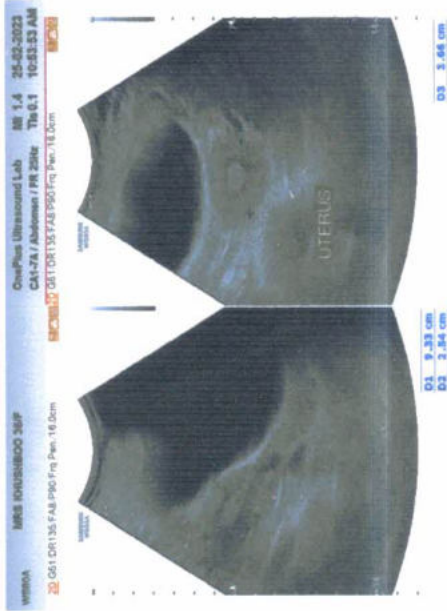
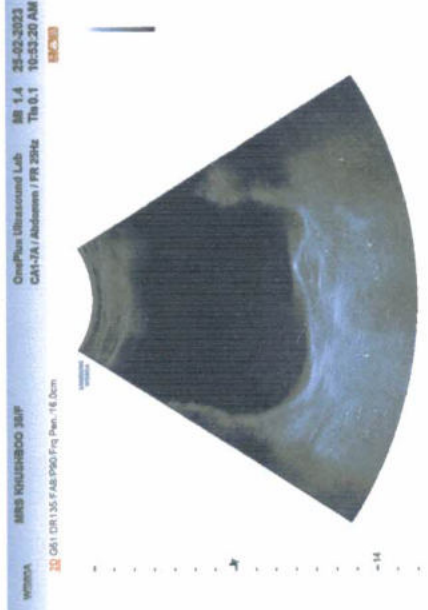
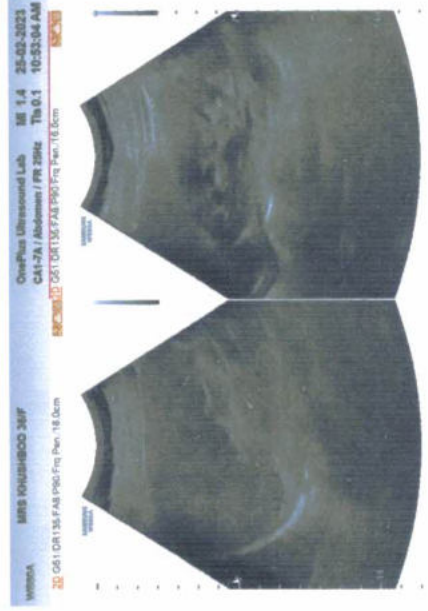
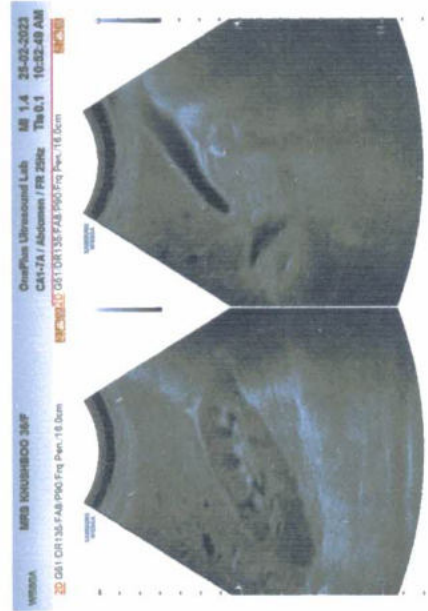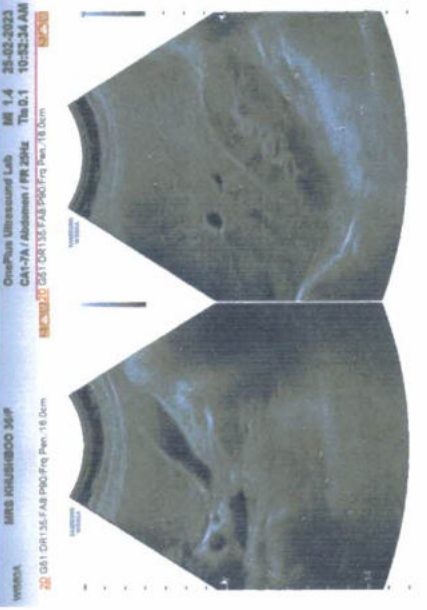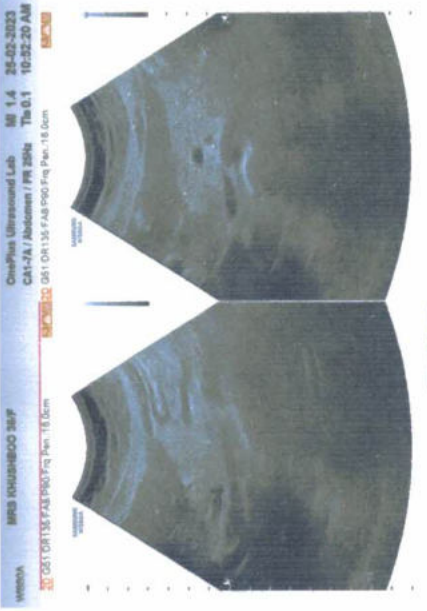
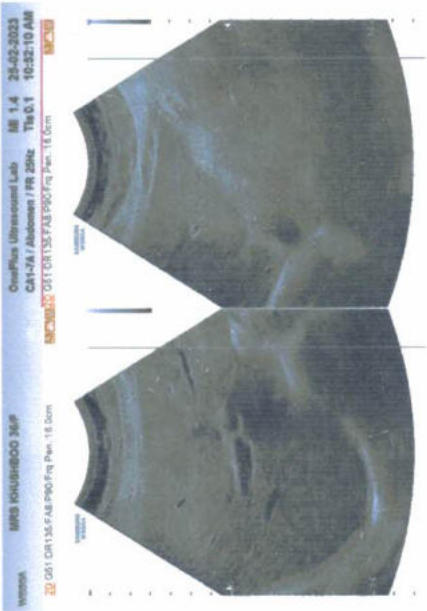No abnormal bowel wall thickening seen in right iliac fossa.
No free fluid seen anywhere in abdomen.

IMPRESSION: Normal study.

DR. POOJA GARG
RADIOLOGIST
REG NO- DMC/R/03398
Dr. Pooja Garg
M.B.B.S., D.M.R.D
Reg No. DMC/R/03398
Radiologist

Type By : darshita

47, Harsh Vihar, Pitampura, New Delhi-110034 | Ph.: 011-42480101, 9599913051
E-mail: oneplusul@gmail.com | Web.: www.oneplusul.in





OnePLUS
Ultrasound Lab
— QUALITY FIRST... ALWAYS! —

Dr. Nitin Agarwal

Pathologist & Director
Ex. Sr. Res. MAMC
& Lok Nayak Hospital
Ex. Chief of Lab Dr. Lal Path Labs.

Dr. Pooja (Garg) Agarwal

Radiologist & Director
MAMC & Lok Nayak Hospital

Name	: Mrs. KHUSHBOO KUMARI	Age/Sex	: 36 YRS/Female
Ref. By	: Dr. MEDIWHEEL	Lab No	: 012302250010
Date	: 25-Feb-2023	Patient ID	: LSHHI109742

X-ray-Chest PA view

Bony cage and soft tissues are normal.

Cardiothoracic ratio is normal.

Mediastinum is normal.


Both hila are normal.

Both costophrenic angles are clear.

Both domes of diaphragm are normal.

Lung fields are clear. No parenchymal lesion seen.

IMPRESSION: Normal Study.

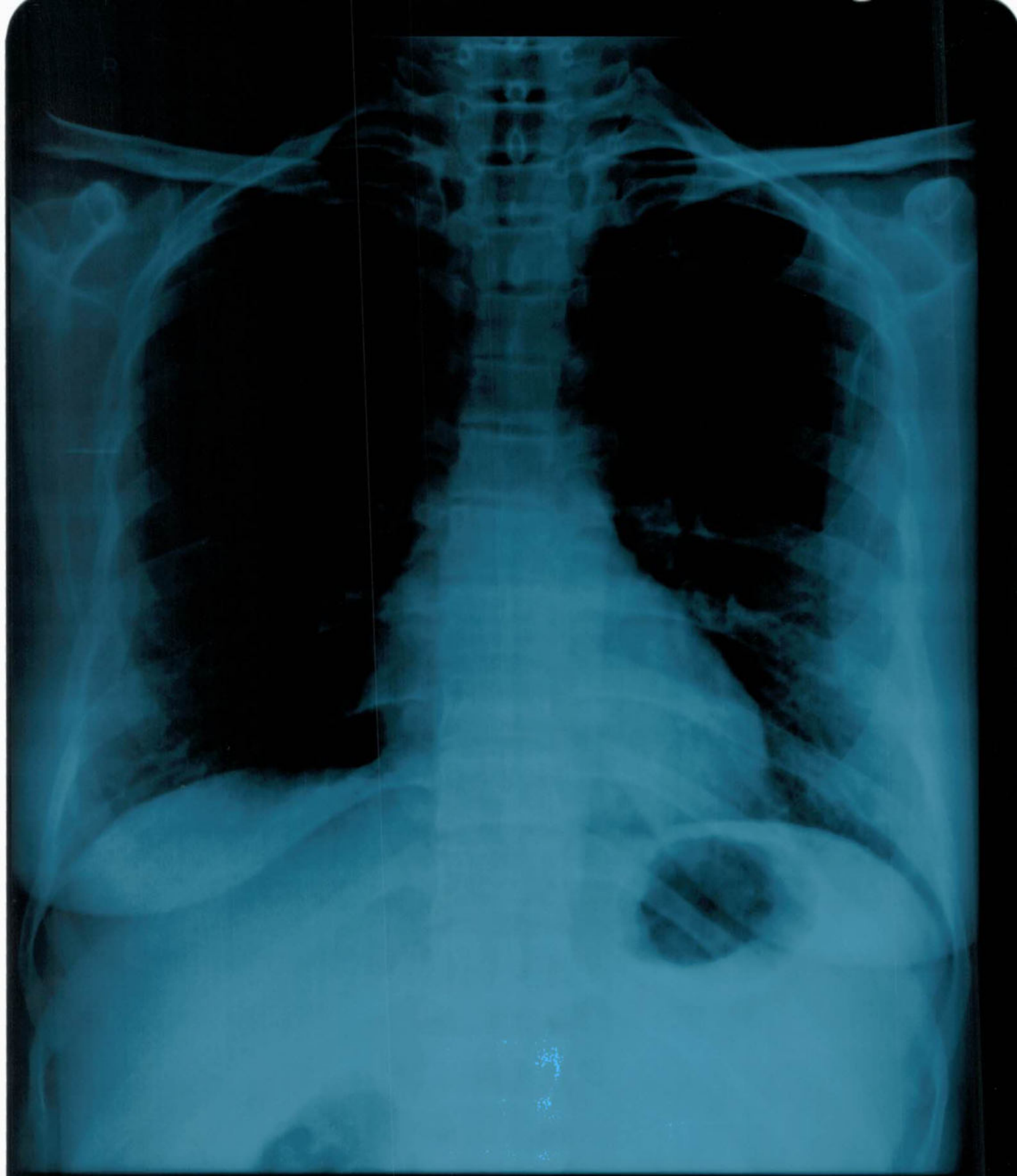
DR. POOJA GARG
RADIOLOGIST
REG NO- DMC/R/03398

Dr. POOJA GARG
M.B.B.S., D.M.R.D
Reg No. DMC/R/03398
Radiologist

Type By : pooja

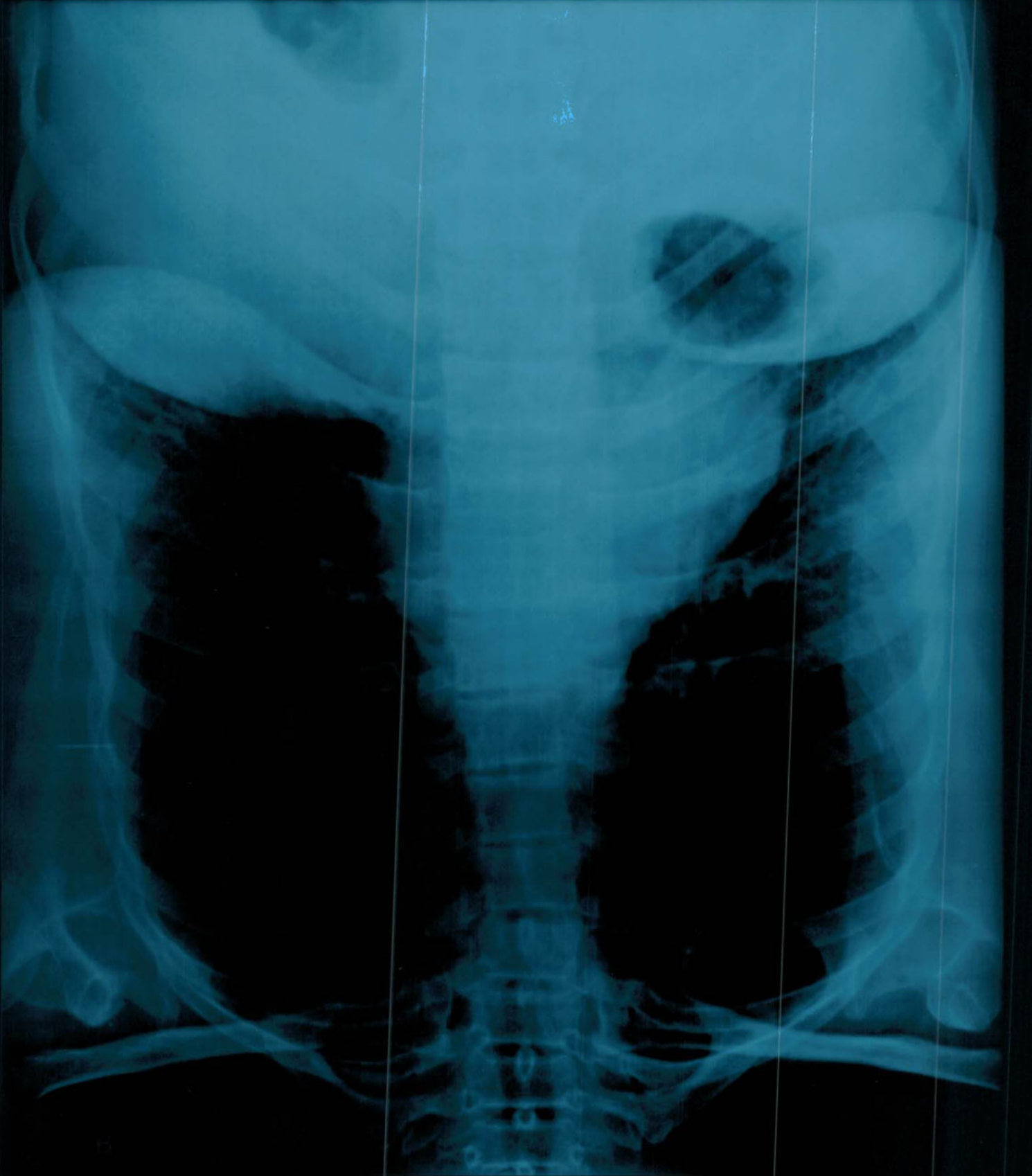47, Harsh Vihar, Pitampura, New Delhi-110034 | Ph.: 011-42480101, 9599913051

E-mail: oneplusul@gmail.com | Web.: www.oneplusul.in



MRS. KHUSHBOO KUMARI 36YRS 25/2/2023 F CHEST PA
ONEPLUS ULTRASOUND LAB.47-HARSH VIHAR PITAMPURA

ОИЕГЛС ПГТРАСОЛИД ГЛВ'АТ-НАРSH VИHAP'PITAM'PUBA
MPS KHUSHBOO KUMARI ZEYPS 221212022 E CHEST PA





OnePLUS Ultrasound Lab

QUALITY FIRST... ALWAYS!

Dr. Nitin Agarwal

Pathologist & Director
Ex. Sr. Res. MAMC
& Lok Nayak Hospital
Ex. Chief of Lab Dr. Lal Path Labs.

Dr. Pooja (Garg) Agarwal

Radiologist & Director
MAMC & Lok Nayak Hospital



NAME	:Mrs. KHUSHBOO KUMARI	Barcode No	:10138659
AGE/GENDER	:36 YRS/Female	SPECIMEN DATE	:25/Feb/2023 09:16AM
PATIENT ID	:109742	SPECIMEN RECEIVED	:25/Feb/2023 10:32AM
REFERRED BY	:Dr. MEDIWHEEL	REPORT DATE	:25/Feb/2023 03:46PM
CENTRE NAME	:ONEPLUS ULTRASOUND LAB	LAB NO.	:012302250010

Test Name	Result	Unit	Ref. Range
-----------	--------	------	------------

HAEMATOLOGY

Medi Wheel Health Checkup >40 Female

Glycosylated Hemoglobin (HbA1c)	5.0	%	Non Diabetic adults <5.7 Prediabetic (at risk) 5.7-6.4 Diabetes >6.4
--	-----	---	--

Estimated average blood glucose (eag) 97

Reference range (mg/dl):

90 - 120:Excellent control, 121 - 150:Good Control, 151 - 180:Average Control, 181 - 210:Action Suggested

>211:Panic value

BLOOD GROUP (ABO)

B

Rh typing

POSITIVE

NOTE :

- * Apart from major A,B,H antigens which are used for ABO grouping and Rh typing, many minor blood group antigens exist. Agglutination may also vary according to titre of antigen and antibody.
- * So before transfusion, reconfirmation of blood group as well as cross-matching is needed.
- * Presence of maternal antibodies in newborns, may interfere with blood grouping.
- * Auto agglutination (due to cold antibody, falciparum malaria, sepsis, internal malignancy etc.) may also cause erroneous result.

CBC

Haemoglobin	11.0	g/dl	11.5-15.0
Total Leucocyte Count	4100	/cumm	4000-10000
Differential leucocyte count			
Neutrophils	62.7	%	40-80
Lymphocyte	31.40	%	20-40
Monocytes	3.00	%	2-10
Eosinophils	2.0	%	1-6
Basophils	0.9	%	0-2
RBC Count	3.80	million/cumm	3.8-4.8

Checked By.

Dr. NITIN AGARWAL
DR. NITIN AGARWAL M B B S , MD (Path)
MBBS,MD(PATHOLOGIST) DMC/R/01436

47, Harsh Vihar, Pitampura, New Delhi-110034 | Ph.: 011-42480101, 9599913051

E-mail: onepusul@gmail.com | Web.: www.oneplusul.in

Page 1 of 6

Clinical correlation is essential for final diagnosis. • If test results are unsatisfactory please contact personally or on phone. • This report is for perusal of doctors only. • All disputes Subject to Delhi Jurisdiction only. • Not for medicolegal purposes. • All congenital anomalies in a foetus may not be diagnosed in routine obstetric ultrasound.



OnePLUS Ultrasound Lab

— QUALITY FIRST... ALWAYS! —

Dr. Nitin Agarwal
Pathologist & Director
Ex. Sr. Res. MAMC
& Lok Nayak Hospital
Ex. Chief of Lab Dr. Lal Path Labs.

Dr. Pooja (Garg) Agarwal
Radiologist & Director
MAMC & Lok Nayak Hospital



NAME	:Mrs. KHUSHBOO KUMARI	Barcode No	:10138659
AGE/GENDER	:36 YRS/Female	SPECIMEN DATE	:25/Feb/2023 09:16AM
PATIENT ID	:109742	SPECIMEN RECEIVED	:25/Feb/2023 10:32AM
REFERRED BY	:Dr. MEDIWHEEL	REPORT DATE	:25/Feb/2023 03:46PM
CENTRE NAME	:ONEPLUS ULTRASOUND LAB	LAB NO.	:012302250010

Test Name	Result	Unit	Ref. Range
PCV(Hematocrit)	36.5	%	36-46
MCV	97	fL	83-101
MCH	29.2	Pg	27-32
MCHC	30.1	G/dL	32-35
Platelet count	182000	/cumm	150000-450000
RDW-CV	14	%	11.4-14.0
ESR(WESTEGRENs METHOD)	10	mm/1hr	<20

BIOCHEMISTRY

<u>Blood sugar fasting</u>	97	mg/dL	70-110
<u>Blood sugar pp</u>	92	mg/dL	70.0-140.0
<u>Bun (blood urea nitrogen)</u>	11.80	mg/dl	7-18.7
<u>Uric acid, serum</u>	4.4	mg/dl	2.6-6.0
<u>Creatinine, serum</u>	0.70	mg/dl	0.50-1.0


LFT(LIVER FUNCTION TEST)

Bilirubin Total	0.68	mg/dl	0.1-1.2
Bilirubin Conjugated	0.38	mg/dl	0-0.4
Bilirubin Unconjugated	0.30	mg/dl	up to 0.7
SGOT (AST)	30	U/L	0-46
SGPT (ALT)	41	U/L	0-49
Alkaline phosphatase	102	U/L	35-104
Gamma glutamyl transpeptidase	22	U/L	5.0-32.0
Total Protein	7.4	gm/dl	6.60 - 8.70
Albumin serum	4.2	g/dL	3.0-5.2
Globulin	3.20	gm/dl	1.8-3.4
Albumin/Globulin Ratio	1.31		1.10 - 2.50

LIPID PROFILE

Cholesterol	118	mg/dl	50-200
Triglycerides	54	mg/dL	25-150

Checked By.


DR. NITIN AGARWAL
MBBS, MD (Path)
DMC/R/01436
MBBS, MD (PATHOLOGIST)

47, Harsh Vihar, Pitampura, New Delhi-110034 | Ph.: 011-42480101, 9599913051

E-mail: oneplusul@gmail.com | Web.: www.oneplusul.in

Page 2 of 6



OnePLUS Ultrasound Lab

QUALITY FIRST... ALWAYS!

Dr. Nitin Agarwal

Pathologist & Director
Ex. Sr. Res. MAMC
& Lok Nayak Hospital
Ex. Chief of Lab Dr. Lal Path Labs.

Dr. Pooja (Garg) Agarwal

Radiologist & Director
MAMC & Lok Nayak Hospital



NAME	:Mrs. KHUSHBOO KUMARI	Barcode No	:10138659
AGE/GENDER	:36 YRS/Female	SPECIMEN DATE	:25/Feb/2023 09:16AM
PATIENT ID	:109742	SPECIMEN RECEIVED	:25/Feb/2023 10:32AM
REFERRED BY	:Dr. MEDIWHEEL	REPORT DATE	:25/Feb/2023 03:46PM
CENTRE NAME	:ONEPLUS ULTRASOUND LAB	LAB NO.	:012302250010

Test Name	Result	Unit	Ref. Range
HDL Cholesterol	44	mg/dL	40 - 60
LDL cholesterol	63	mg/dL	< 130
VLDL cholesterol	10.8	mg/dL	5-40
Cholesterol/HDL Ratio	2.7		Low Risk 3.3-4.97 Average Risk 4.4-7.1 Moderate Risk 7.1-11.0 High Risk >11.0
LDL/HDL Ratio	1.4		0 - 3.55

According to ATP III and NCEP guidelines

Parameter	Normal	Desirable	Borderline	High
Total cholesterol	<200		200-239	240
Triglycerides	<150	150-199	200-499	500
LDL	Optimal <100 Near Optimal 100-129	130-159	160-180	190
HDL	<40 : LOW 60 : HIGH			

BUN/Creatinine ratio

Bun (blood urea nitrogen)	11.80	mg/dl	7-18.7
CREATININE	0.70	mg/dl	0.30-1.10
BUN/Creatinine ratio	16.86		10.0 - 20.0

ENDOCRINOLOGY

THYROID PROFILE(T3,T4,TSH)

Triiodothyronine total [t3]	0.86	ng/dl	0.52-1.9
Thyroxine total [t4]	7.90	µg/dl	4.8-11.6
TSH (Thyroid Stimulating Hormone)	4.00	µIU/ml	0.25-5.0

AGE WISE VARIATION IN TSH

Checked By.

Dr. Nitin Agarwal
MBBS, MD (Path)
DR. NITIN AGARWAL
MAMC/R/01436
MBBS, MD (PATHOLOGIST)

47, Harsh Vihar, Pitampura, New Delhi-110034 | Ph.: 011-42480101, 9599913051

E-mail: oneplusul@gmail.com | Web.: www.oneplusul.in

Page 3 of 6



OnePLUS
Ultrasound Lab

— QUALITY FIRST... ALWAYS! —

Dr. Nitin Agarwal

Pathologist & Director
Ex. Sr. Res. MAMC
& Lok Nayak Hospital
Ex. Chief of Lab Dr. Lal Path Labs.

Dr. Pooja (Garg) Agarwal

Radiologist & Director
MAMC & Lok Nayak Hospital



NAME	:Mrs. KHUSHBOO KUMARI	Barcode No	:10138659
AGE/GENDER	:36 YRS/Female	SPECIMEN DATE	:25/Feb/2023 09:16AM
PATIENT ID	:109742	SPECIMEN RECEIVED	:25/Feb/2023 10:32AM
REFERRED BY	:Dr. MEDIWHEEL	REPORT DATE	:25/Feb/2023 03:46PM
CENTRE NAME	:ONEPLUS ULTRASOUND LAB	LAB NO.	:012302250010

Test Name	Result	Unit	Ref. Range
AGE	TSH(μIU/ml)	AGE	TSH(μIU/ml)
1-4 weeks	1.00 - 19.0	16-20 yrs	0.25 - 5.0
1-12 mths	1.70 - 9.1	21 - 80 yrs	0.25 - 5.0
1-5 yrs	0.80 - 8.2	I st trimester	0.25 - 5.0
6-10 yrs	0.25 - 5.0	II nd trimester	0.50 - 5.0
11-15 yrs	0.25 - 5.0	II rd trimester	0.4 - 6.0

Reference ranges - Interpretation of Diagnostic tests - (Jacques Wallach)

1. Primary hypothyroidism is accompanied by depressed serum T3 and T4 values and elevated serum TSH level.
2. Primary hyperthyroidism is accompanied by elevated serum T3 and T4 levels along with depressed TSH values.
3. Slightly elevated T3 levels may be found in pregnancy and estrogen therapy, while depressed levels may be encountered in severe illness, renal failure and during therapy with drugs like propranolol and propyl thiouracil.
4. Although elevated TSH levels are nearly always indicative of primary hypothyroidism, and may be seen in secondary thyrotoxicosis

CLINICAL PATHOLOGY

URINE ROUTINE

Physical examination

Quantity	20	ML
Colour	PALE YELLOW	
Transparency	CLEAR	CLEAR
Sp.gravity	1.010	1.010-1.030
pH	6.50	
Reaction	ACIDIC	ACIDIC

Chemical examination

Urine protein	NIL	NIL
Urine sugar	NIL	NIL
Bilirubin, urine	NEGATIVE	NEGATIVE
Urobilinogen	NORMAL	NORMAL
Ketones	NEGATIVE	NEGATIVE

Microscopic examination

Checked By.

Dr. NITIN AGARWAL
M B B S, MD (Path)
DR. NITIN AGARWAL DMC/R/01436
MBBS, MD(PATHOLOGIST)

47, Harsh Vihar, Pitampura, New Delhi-110034 | Ph.: 011-42480101, 9599913051

E-mail: oneplusul@gmail.com | Web.: www.oneplusul.in

Page 4 of 6



OnePLUS Ultrasound Lab

— QUALITY FIRST... ALWAYS! —

Dr. Nitin Agarwal

Pathologist & Director
Ex. Sr. Res. MAMC
& Lok Nayak Hospital
Ex. Chief of Lab Dr. Lal Path Labs.

Dr. Pooja (Garg) Agarwal

Radiologist & Director
MAMC & Lok Nayak Hospital



NAME	:Mrs. KHUSHBOO KUMARI	Barcode No	:10138659
AGE/GENDER	:36 YRS/Female	SPECIMEN DATE	:25/Feb/2023 09:16AM
PATIENT ID	:109742	SPECIMEN RECEIVED	:25/Feb/2023 10:32AM
REFERRED BY	:Dr. MEDIWHEEL	REPORT DATE	:25/Feb/2023 03:46PM
CENTRE NAME	:ONEPLUS ULTRASOUND LAB	LAB NO.	:012302250010

Test Name	Result	Unit	Ref. Range
Pus cells.	1-2	/HPF	1-2
Epithelial cells	1-2	/HPF	0-5
R.B.C.	NIL	/HPF	NIL
Casts	NIL	/HPF	NIL
Crystals	NIL	/HPF	NIL
Bacteria	NIL	/HPF	NIL
Others.	NIL		NIL

Checked By.

DR. NITIN AGARWAL
MBBS,MD(PATHOLOGIST)

Dr NITIN AGARWAL
M B B S , MD (Path)
DMC/R/01436

47, Harsh Vihar, Pitampura, New Delhi-110034 | Ph.: 011-42480101, 9599913051

E-mail: oneplusul@gmail.com | Web.: www.oneplusul.in

Page 5 of 6



OnePLUS Ultrasound Lab

QUALITY FIRST... ALWAYS!

Dr. Nitin Agarwal
Pathologist & Director
Ex. Sr. Res. MAMC
& Lok Nayak Hospital
Ex. Chief of Lab Dr. Lal Path Labs.

Dr. Pooja (Garg) Agarwal
Radiologist & Director
MAMC & Lok Nayak Hospital



NAME	:Mrs. KHUSHBOO KUMARI	Barcode No	:10138659
AGE/GENDER	:36 YRS/Female	SPECIMEN DATE	:25/Feb/2023 09:16AM
PATIENT ID	:109742	SPECIMEN RECEIVED	:25/Feb/2023 10:32AM
REFERRED BY	:Dr. MEDIWHEEL	REPORT DATE	:27/Feb/2023 02:19PM
CENTRE NAME	:ONEPLUS ULTRASOUND LAB	LAB NO.	:012302250010

CYTOLOGY

PAP SMEAR

STATEMENT OF ADEQUACY : Satisfactory for evaluation.

GENERAL CATEGORISATION : Benign cellular changes.

DESCRIPTIVE DIAGNOSIS

1. Superficial squamous cells with intermediate and occasional metaplastic squamous cells.
2. Scanty polymorphonuclear leucocytes.
3. No epithelial cell abnormality.

COMMENTS :


NEGATIVE FOR INTRAEPITHELIAL LESION/MALIGNANCY.

P/OP/14/23

*** End Of Report ***

Checked By.

Dr. NITIN AGARWAL
MBBS, MD (Path)
DMC/R/01436


DR. NITIN AGARWAL
MBBS,MD(PATHOLOGIST)

47, Harsh Vihar, Pitampura, New Delhi-110034 | Ph.: 011-42480101, 9599913051
E-mail: oneplusul@gmail.com | Web.: www.oneplusul.in

Page 6 of 6