




Unique Identification Authority of India

செவ்வகம்:
 Plot No 46 A, 47, அரவின் காடம்,
 கோம்பே, கோம்பே - 641401

Address:
 Plot No 46 A, 47, Aravin Garden, Kadampal,
 Coimbatore,
 Tamil Nadu - 641401



4309 7831 4565
VID : 9127 8018 5877 4947

1847 | help@uidai.gov.in | www.uidai.gov.in



Government of India

செவ்வகம் குமார்
Aravind Kumar
 பிறப்பு நாள்/DOB: 05/03/1986
 -ஆண்/ MALE



Download Date: 26/07/2021

4309 7831 4565
VID : 9127 8018 5877 4947

உடனடி உதவிக். உடனடி உதவிக் உதவிக் உதவிக்

Handwritten signature in blue ink



ABI SCANS & LABS

A unit of Aarthi Scans and Labs

NAME	MR. ARAVIND KUMAR P	PATIENT ID	86476
ACCESSION NO	89987	AGE/GENDER	36Y/MALE
REFERRED BY	MEDIWHEEL	DATE	27 -FEB-2022

VISION TEST

VISUAL ACUITY (VA)

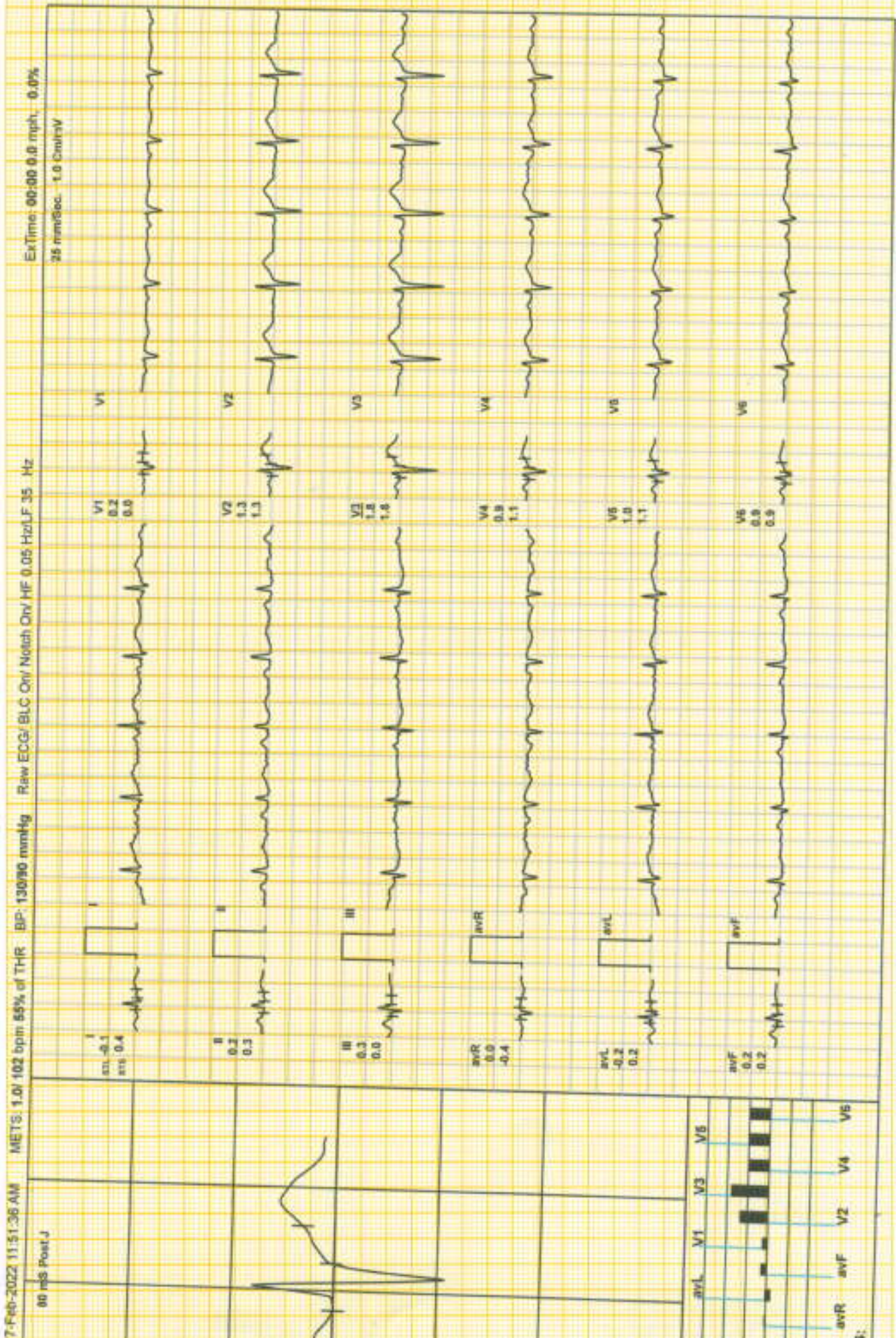
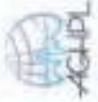If The Acuity Can Be Measures, Complete This Box Using Snellen acuities or snellen equivalents or NLP,LP,HM, or distance at which the patient sees the 20/100 letter.

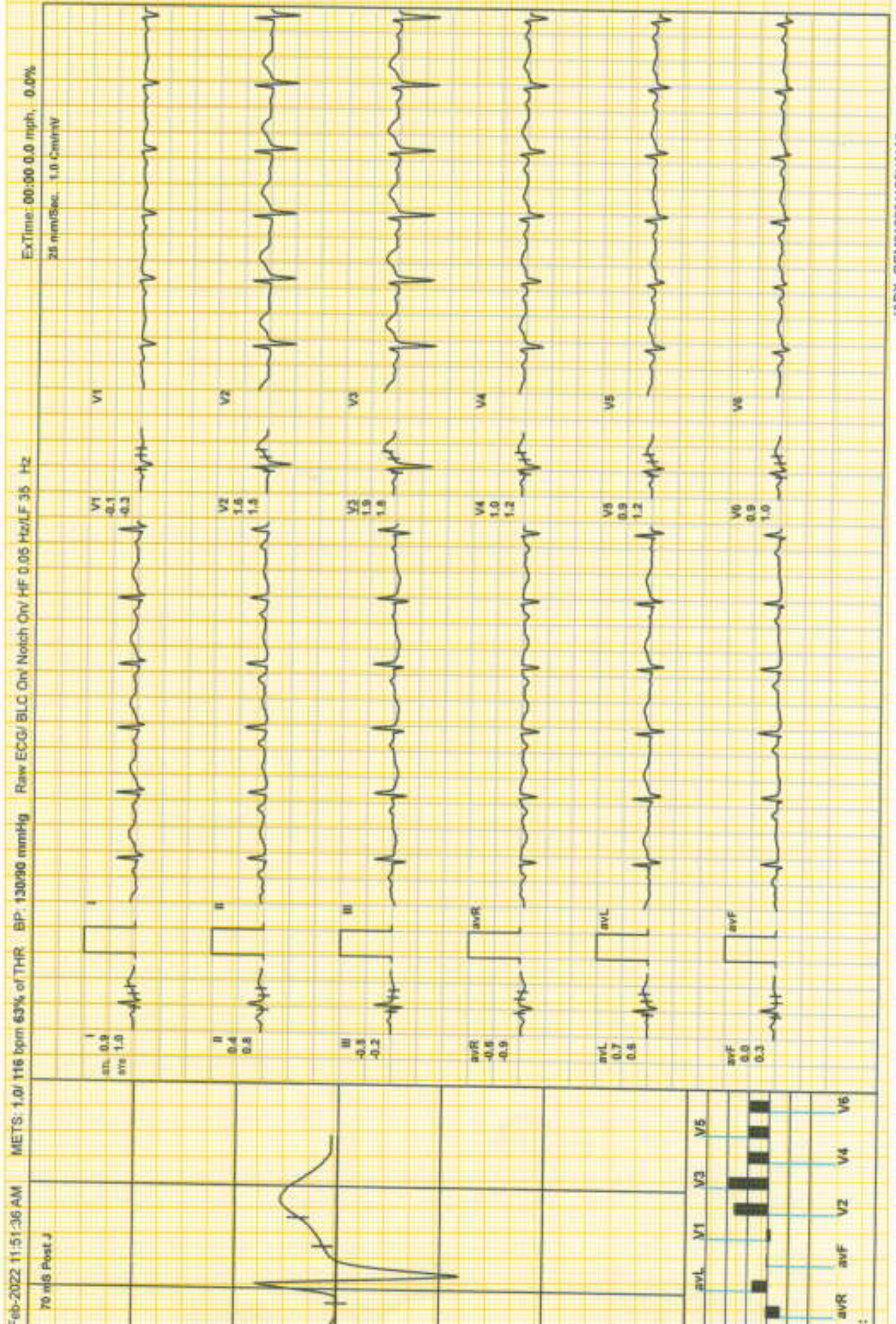
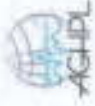WITH BEST CORRECTION

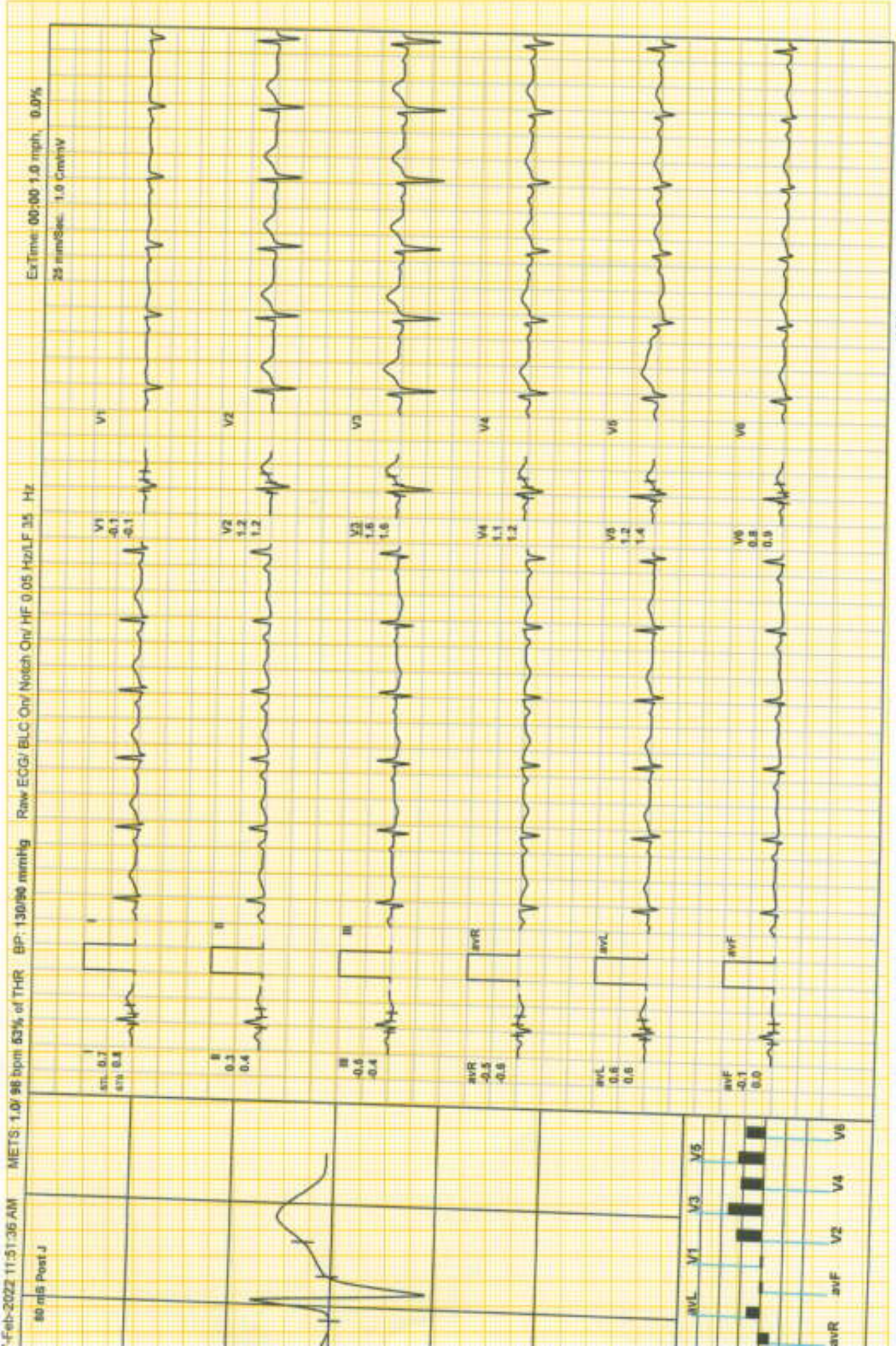
DISTANCE VISION	
Right	11/11
Left	11/11
Both	11/11

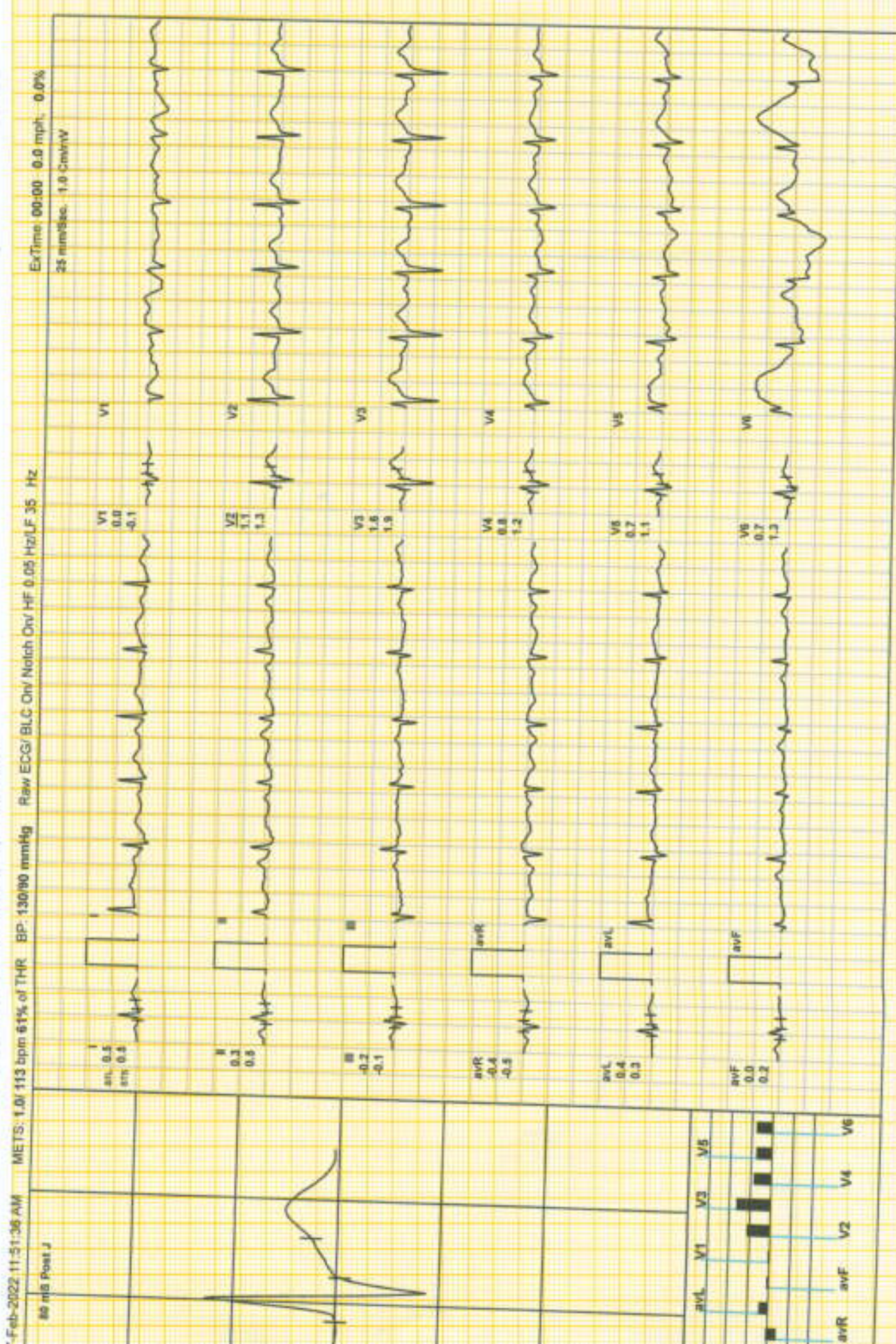
NEAR VISION	
Right	N6
Left	N6
Both	N6

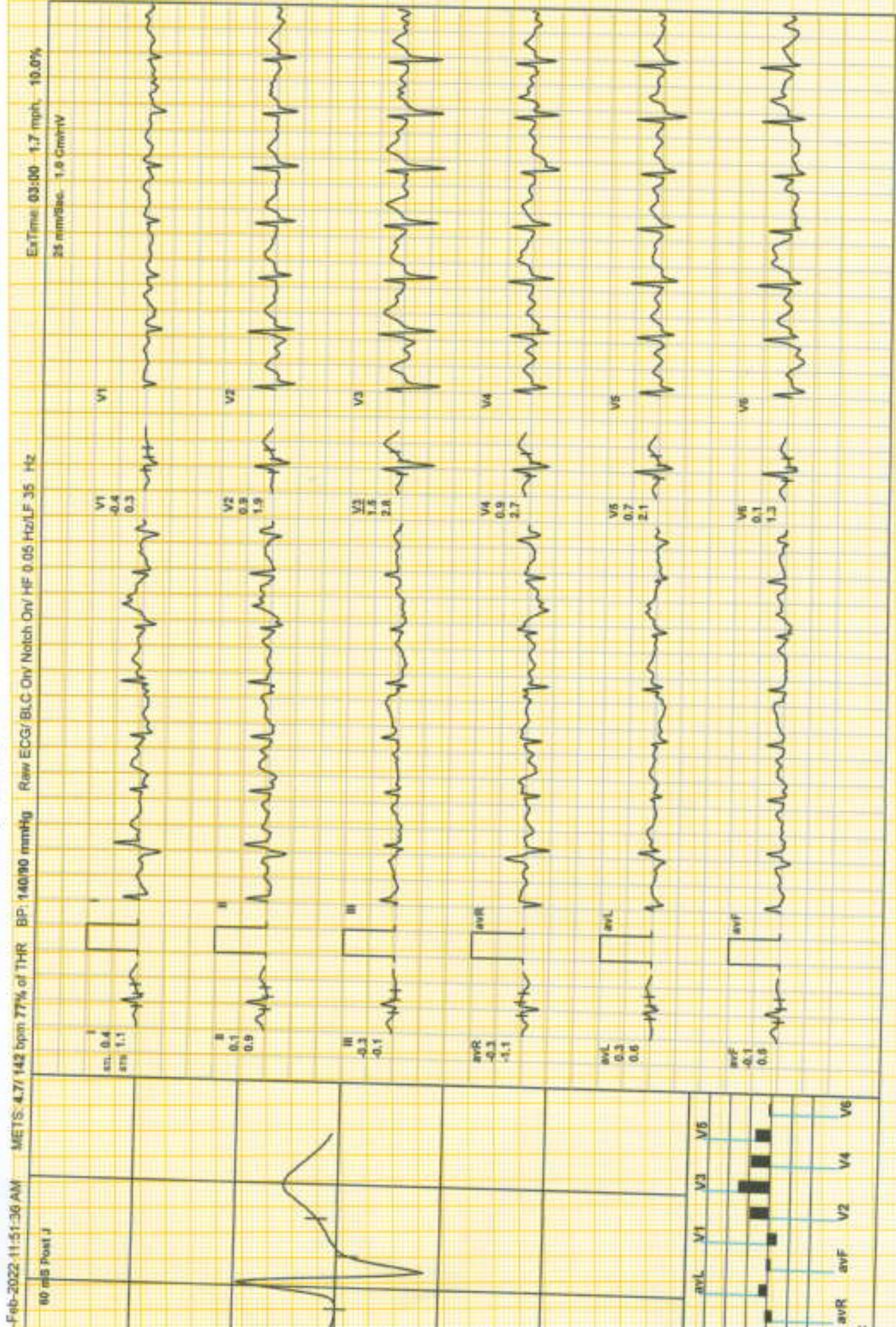
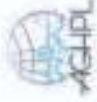COLOUR VISION	
BOTH	Normal







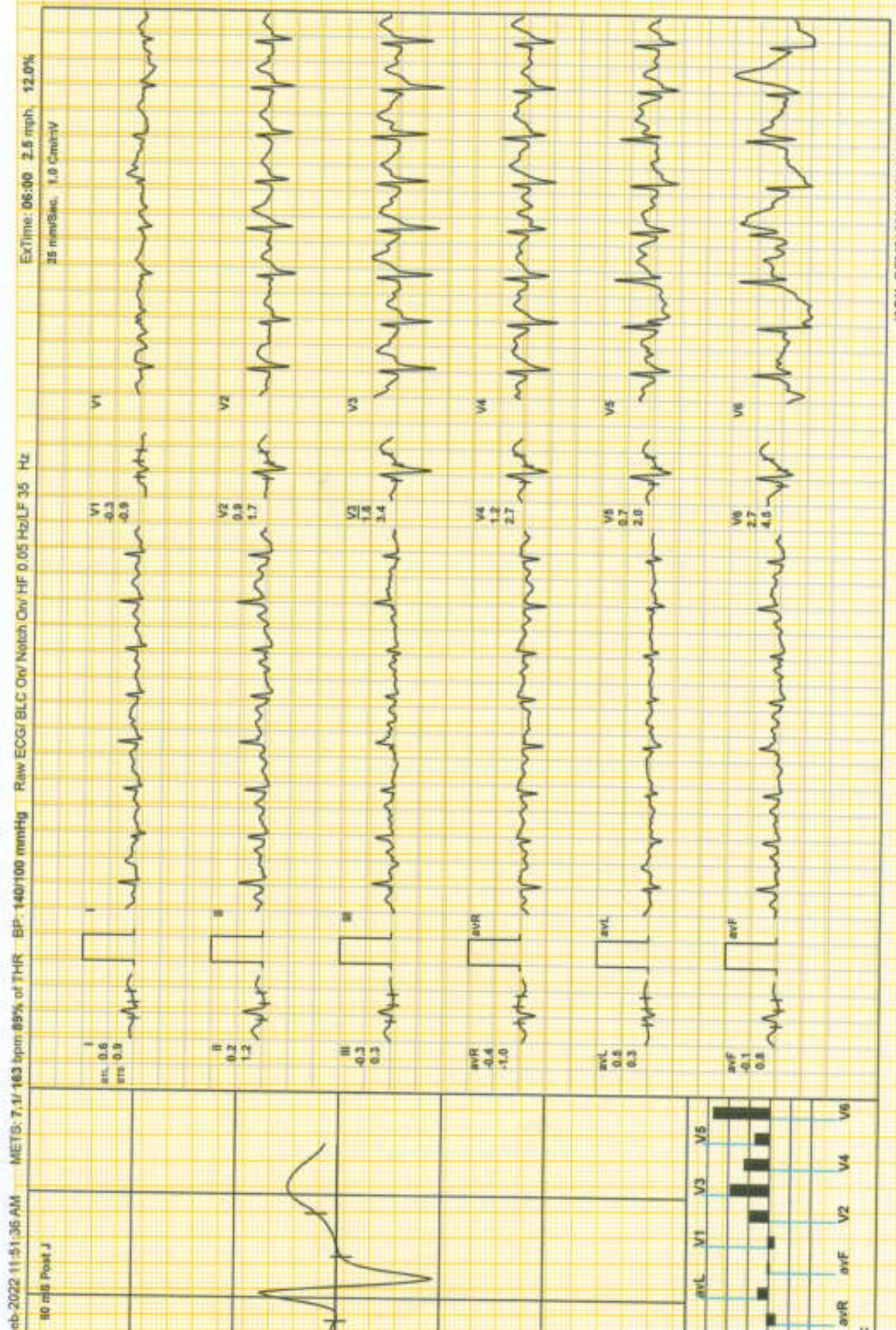
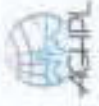



SCANS & LABS

163) / MR. ARAVIND KUMAR P / 36 Yrs / M / 177 Cms / 97 Kg / HR : 163

BRUCE : Stage 2 (03:00)



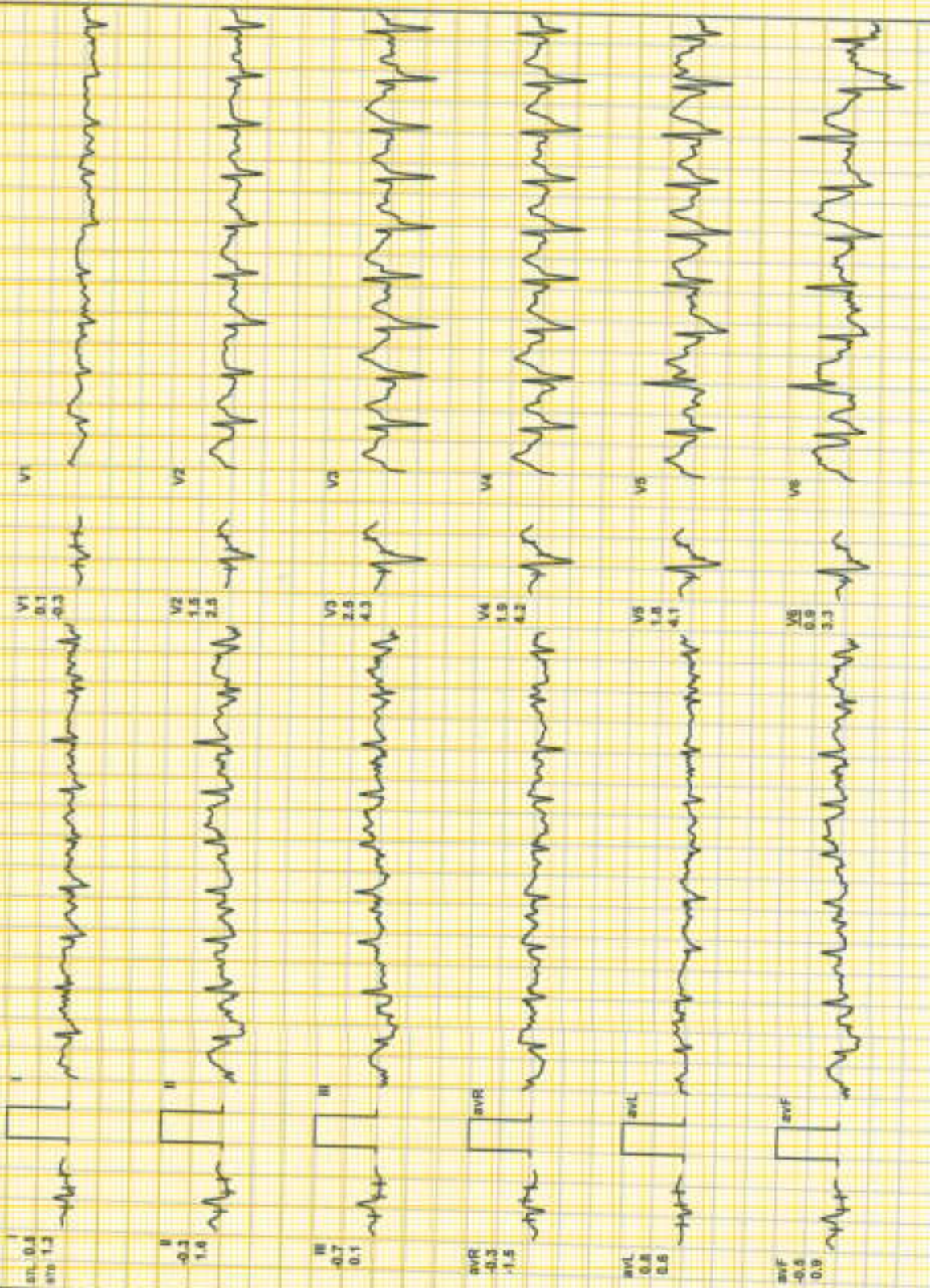
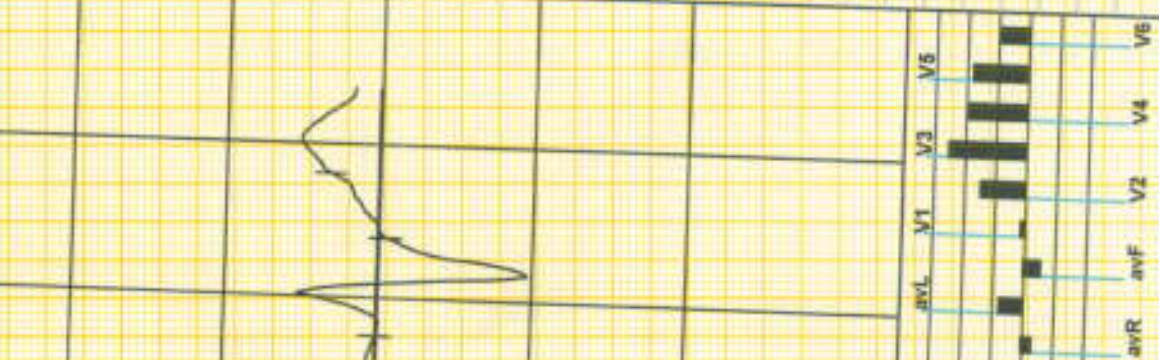

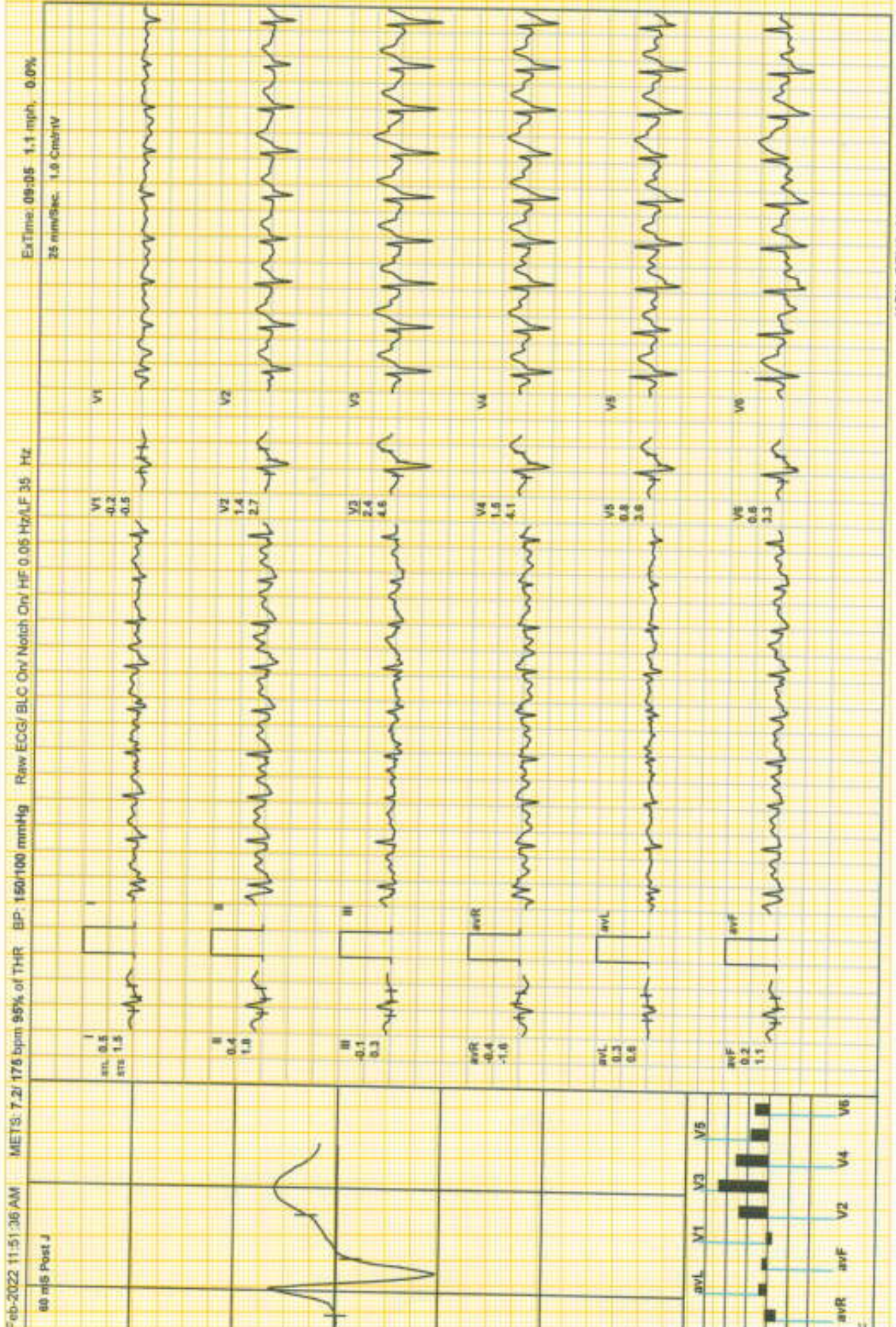
4-Feb-2022 11:31:36 AM

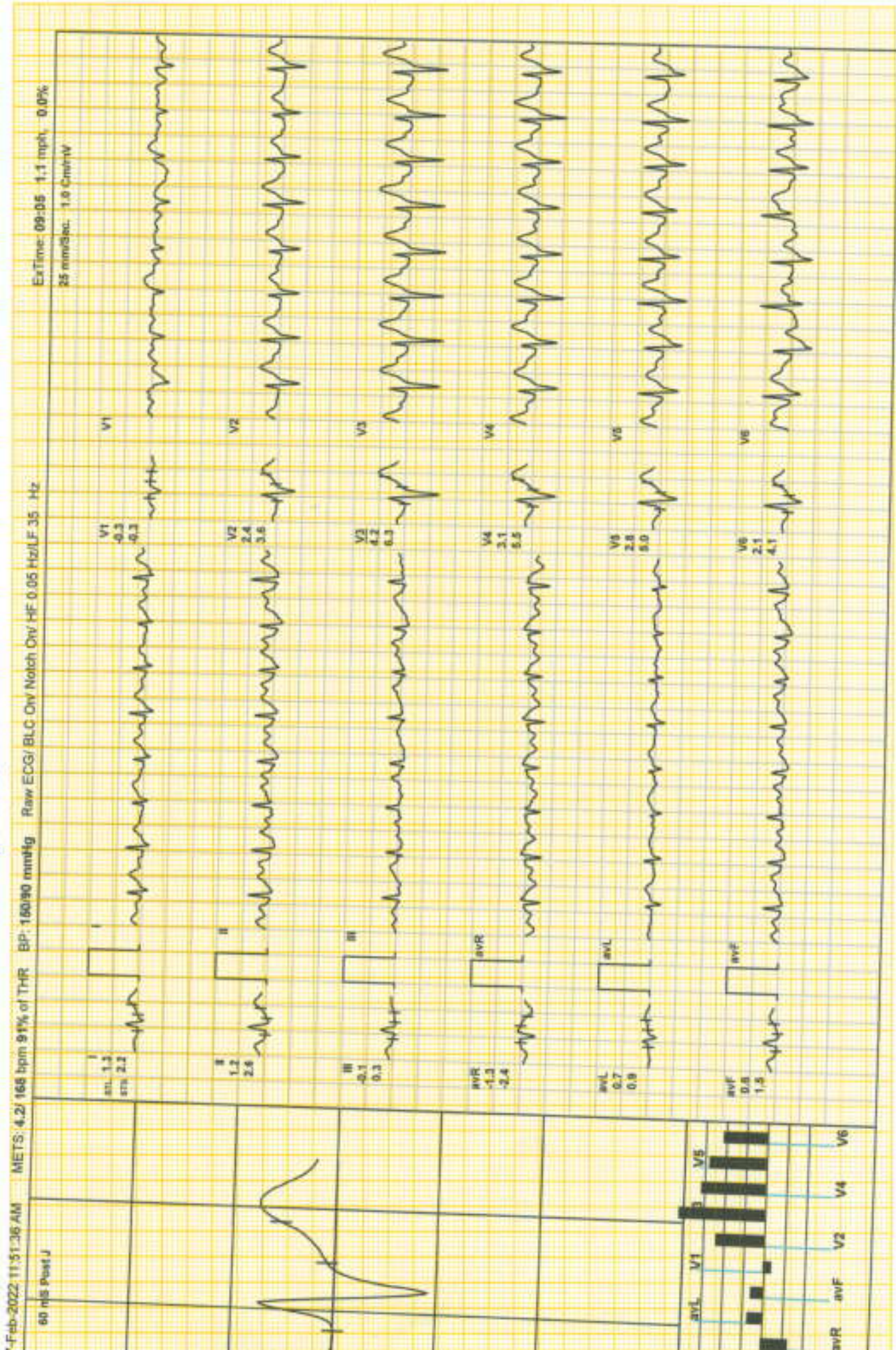
METS: 10.3/ 185 bpm 101% of THR BP: 160/100 mmHg Raw ECG/ BLC On/ Notch On/ HF 0.05 Hz/LF 35 Hz

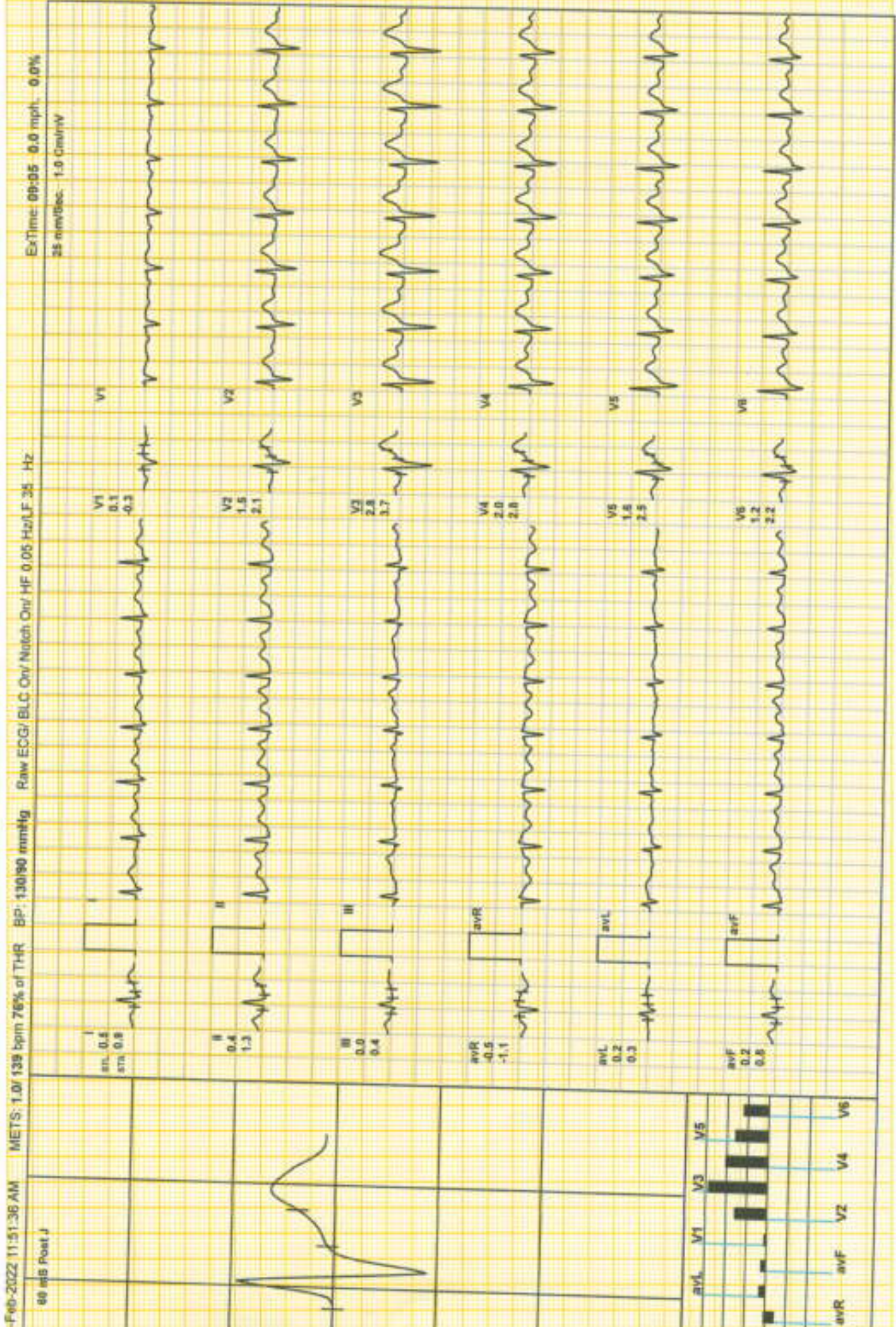
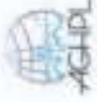60 m/s Post J

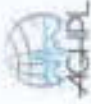ExTime 09:05 4.2 mph, 16.0%
25 mm/Sec. 1.0 cm/mV











163) / MR. ARAVIND KUMAR P / 36 Yrs / M / 177 Cms / 97 Kg Date: 27-Feb-2022 Refd By : MEDIWHEEL Examined By: ARTHI SCANS & LABS

Time	Duration	Speed(mph)	Elevation	METs	Rate	% THR	BP	Rpp	PVC	Comments
00:08	0:08	00.0	00.0	01.0	102	55 %	130/90	132	00	
00:36	0:28	00.0	00.0	01.0	116	63 %	130/90	150	00	
00:57	0:21	00.0	00.0	01.0	098	53 %	130/90	127	00	
01:51	0:54	01.0	00.0	01.0	113	61 %	130/90	146	00	
04:51	3:00	01.7	10.0	04.7	142	77 %	140/90	198	00	
07:51	3:00	02.5	12.0	07.1	163	89 %	140/100	228	00	
10:51	3:00	03.4	14.0	10.2	185	101 %	150/100	277	00	
10:56	0:05	01.1	00.0	10.3	185	101 %	150/100	277	00	
11:26	0:30	01.1	00.0	07.3	175	95 %	150/100	262	00	
11:56	1:00	01.1	00.0	04.3	168	91 %	150/90	251	00	
12:56	2:00	00.0	00.0	01.0	144	78 %	140/100	201	00	
13:56	3:00	00.0	00.0	01.0	139	76 %	130/90	180	00	
14:16	3:20	00.0	00.0	01.0	135	73 %	130/90	175	00	

GS :

- Exercise Time : 09:05
- Max HR Attained : 185 bpm 101% of Target 184
- Max BP Attained : 150/100
- Max Work Load Attained : 10.3 Good response to induced stress
- Test Objective : NOW CHECKUP ONLY
- Test End Reasons : Test Complete, Test Complete

HI SCANS & LABS
DB ROAD, RS PURAM, COIMBATORE

/ MR. ARAVIND KUMAR P / 36 Yrs / M / 177 Cms / 97 Kg Date: 27-Feb-2022 Refd By : MEDIWHEEL

REPORT



REPORT :

No Significant ST segment changes noted during exercise or recovery.

No angina /arrhythmia /S3/murmur.

Final Impression : Test Is Negative For Inducible Ischemia

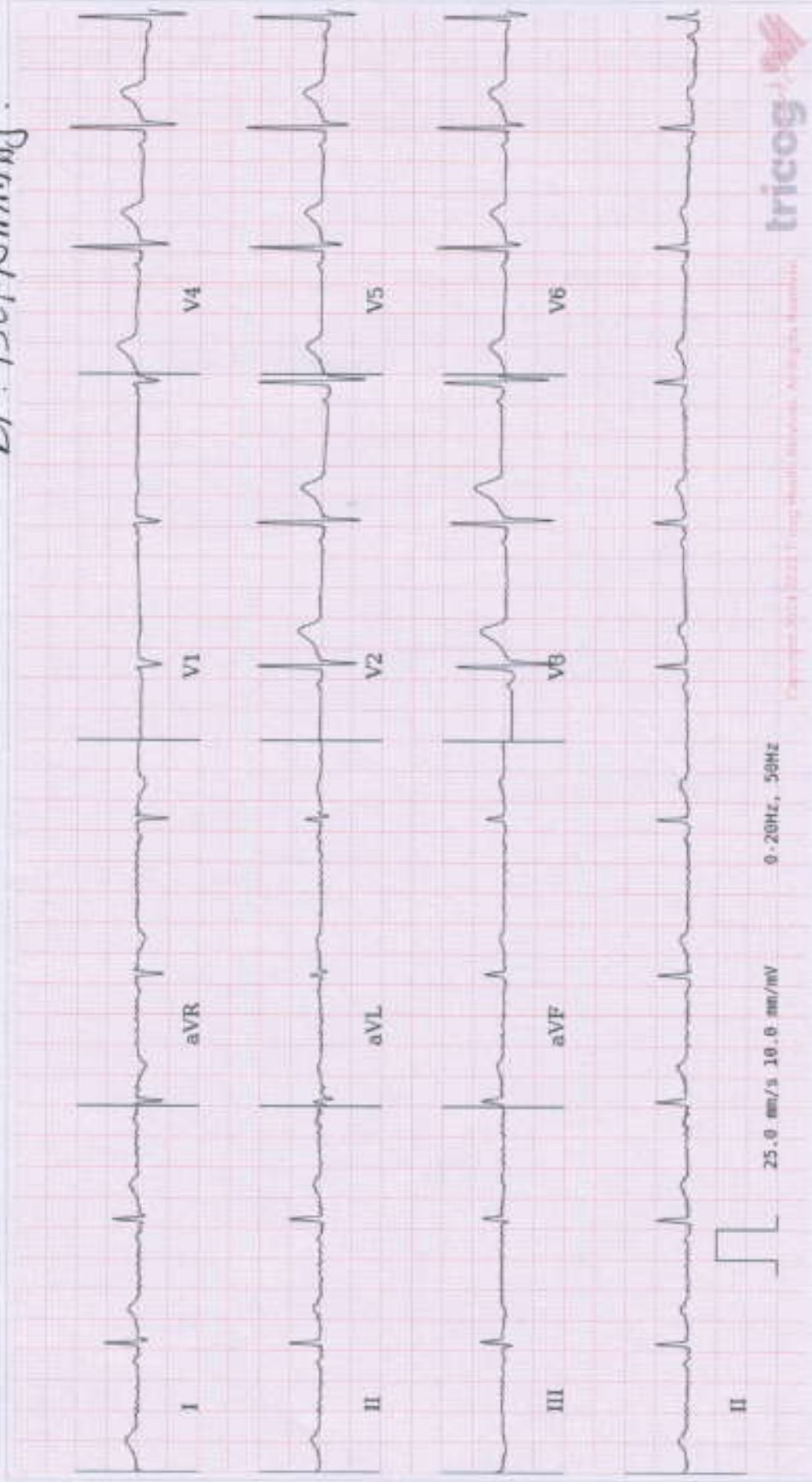
A handwritten signature in blue ink, consisting of a stylized 'K' and 'C' intertwined.

Dr. KARTHIC C.S.M.D.,PGD(CARDIOLOGY,UKR)
CONSULTANT CARDIOLOGIST.

Age / Gender: 36/Male
Patient ID: 000086476
Patient Name: MR. ARAVIND KUMAR P

Date and Time: 27th Feb 22 9:33 AM

BP: 130/90 mmHg



AP: 69bpm VR: 69bpm QRS: 70ms QT: 350ms QTc: 375ms PR: 124ms P-R-T: 16° 44° 18°

Within Normal Limits: Sinus Rhythm, Normal Axis, with Sinus Arrhythmia. Please correlate locally.





ABI SCANS & LABS

A unit of Aarthi Scans and Labs

Name	MR.ARAVIND KUMAR P	Patient ID	89987
Accession No	86476	Age/Gender	36Y / Male
Referred By	MEDIWHEEL	Date	27-Feb-2022

X-RAY - CHEST PA VIEW

OBSERVATION:

The trachea is central.

The mediastinal and cardiac silhouette are normal.

Cardiothoracic ratio is normal.

Cardiophrenic and costophrenic angles are normal.

Both hila are normal.

Lung zones are clear.

Bones of the thoracic cage are normal.

Soft tissues of the chest wall are normal.

IMPRESSION:

➤ No significant abnormality seen.

Dr. Abinaya R MDRD.,
Consultant Radiologist



ABI SCANS & LABS

A unit of Aarthi Scans and Labs

Name	MR.ARAVIND KUMAR P	Patient ID	86476
Accession No	89987	Age/Gender	36Y / Male
Referred By	Dr.MEDIWHEEL	Date	27-Feb-2022

USG REPORT - ABDOMEN AND PELVIS

LIVER:

Liver is normal in size (measures ~ 12.3 cm) and shows increased echotexture.

No focal liver lesion. No intra hepatic biliary radical dilatation seen.

GALL BLADDER:

Is adequately distended. No calculus or cholecystitis seen.

PANCREAS:

Appears normal in size and shows uniform echo texture. The pancreatic duct is normal. No calcifications are seen.

SPLEEN:

Appears normal in size and it shows uniform echo texture. It measures ~ 12 cm in long axis.

RIGHT KIDNEY:

Right kidney measures ~ 11.5 x 4.7 cm.

Calculus of size measuring ~ 3 mm noted in mid pole of right kidney.

The shape, size and contour of the right kidney appear normal.

Cortico medullary differentiation is within normal. No evidence of pelvicalyceal dilatation.

LEFT KIDNEY:

Left kidney measures ~ 11 x 4.7 cm.

Calculi (2 in no) seen, measuring ~ 4 mm in upper pole and 3 mm in mid pole of left kidney.

The shape, size and contour of the left kidney appear normal.



ABI SCANS & LABS

A unit of Aarthi Scans and Labs

Name	MR.ARAVIND KUMAR P	Patient ID	86476
Accession No	89987	Age/Gender	36Y / Male
Referred By	Dr.MEDIWHEEL	Date	27-Feb-2022

USG REPORT - ABDOMEN AND PELVIS

Cortico medullary differentiation is within normal. No evidence of pelvicalyceal dilatation.

URINARY BLADDER:

Is normal contour. No intra luminal echoes are seen.

PROSTATE:

Prostate appears normal, Measures ~ 2.9 x 3.1 x 3.2 cms (Vol - 15 cc).

RIGHT ILIAC FOSSA:

No focal fluid collections seen.

No evidence of hernia seen in anterior abdominal wall.

IMPRESSION:

- ❖ Grade I fatty liver.
- ❖ Non obstructive bilateral intra renal calculi.
- Suggested clinical correlation.


Dr. Abinaya Rajasekaran., MDRD.,
Radiologist

Thank you for the courtesy of this referral

Foot Note: Patient's identity is not verified. Report is not valid for medico legal purpose.

Dr. Abinaya Rajasekaran, MD
Reg. No: 119338.

ABI SCANS AND LABS

MR. ARAVIND KUMAR P /M 86476 27-Feb-2022 09:08:51 AM

