

M perlewi Sheorner

Age - 29 / F

Wt = 67.7kg.

Ht = 159cm

BWZ - 24.23

Weg

BWZ = 55.44

- 7:30 - $\frac{1}{2}$ liter / Green tea (tea + Biscuits) + $\frac{1}{2}$ liter + 3-4 small fruits (5+1)
- 9:00 AM - upma / Sprouts / daliya / poha (2) / oat / Sattu / Zola / dhokla + buttermilk.
- 11 AM - Fruits (100gm)
- 2 PM - roti (3) + Sabji + dal + Curd + Salad (150-200gm) (पनीर)
- 5-6 PM - tea + Biscuits (2)
- 9-10 PM - $\frac{1}{2}$ liter $\frac{1}{2}$ liter
- 10:30 PM - milk.

Dr. Suresh
25/03/23
8770802044

25/03/23

Mrs. Pallavi Sharma

Age - 29 y/f



Multiple root stump

Ady
extraction of root stump.

Dental checkup done.

Licensee: Gurjar Hospital & Endoscopy Centre Pvt. Ltd.

1, Scheme No. 44-B, Siddarth Nagar, BhanwarKuan Square,
A. B. Road, Indore (M.P.) 452 001

E-mail : ab.road@apolloclinic.com Visit us at : www.apolloclinic.com

TO BOOK AN APPOINTMENT

0731 4870 738

FOR SAMPLE COLLECTION

9893 110 657

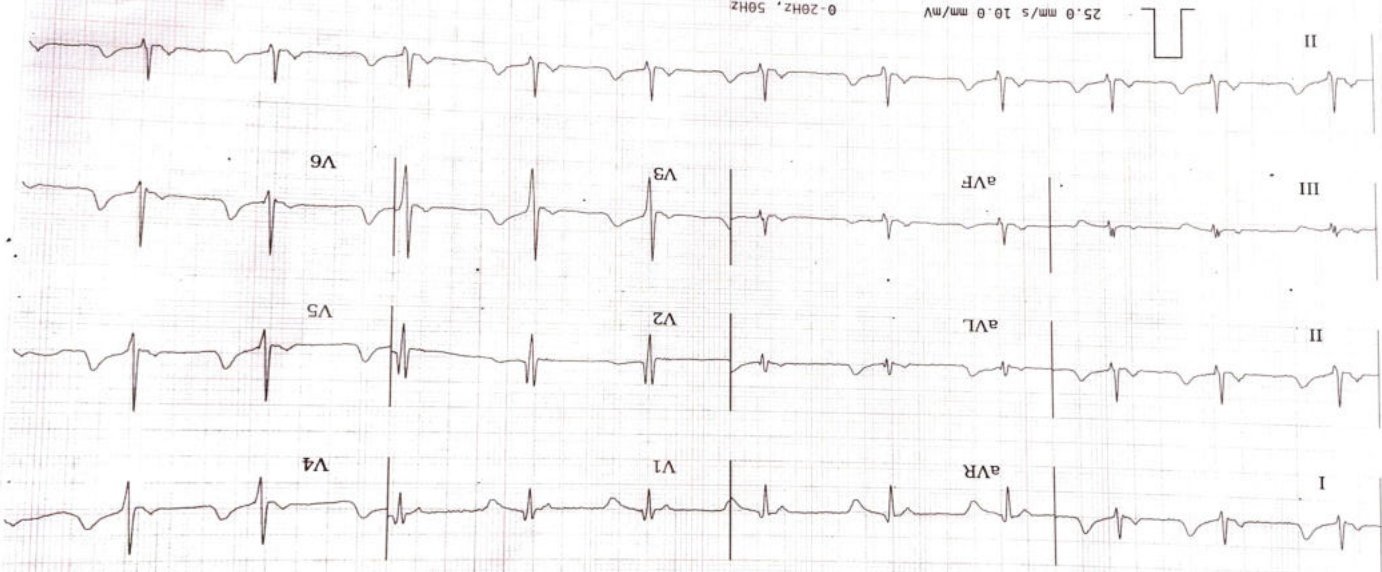
Patient Name:	MRS PALLAVI SHARMA	MR NO:	FABR.0000003099
VISIT NO. :	FABROPV0000003556	Age / Gender :	29Y / F
Conducted by :	DR PARAG CHANDAK.	Conducting Date :	25/03/2023

ECG REPORT

- The rhythm is sinus, Normal
- Heart Rate is 70 beats per minute.
- Normal P -47, R-44, T-22axis.
- Normal PRI -136 ms, QRS-90ms, QT -374ms, QTC- 403 uration
- No Pathological Q wave or ST-T changes seen.
- No evidence of chamber hypertrophy or enlargement seen.

IMPRESSION . NORMAL STUDY


DR. PARAG CHANDAK



ECG Within Normal Limits: Sinus Rhythm. Please correlate clinically.

AR: 70bpm VR: 70bpm QRS: 90ms QT: 374ms PRI: 136ms P-R-T: 47° 44° 22°

Patient's Name	MRS PALLAVI SHARMA				
Age / Sex	29 Yrs. /F	MOB NO	8319282609	Report Date:	25/03/2023
Ref. By	SELF			MR NO	FABR.0000003099

ECHOCARDIOGRAPHY

Study done in various view shows normal size left atrium. Pulmonary veins join LA.

Inter arterial septum is intact. Right atrium is normal size.

Tricuspid valves is structurally & functionally normal. Right ventricle is placed anteriorly & is normal. MPA is normal. Pulmonary valve cups are normal.

Mitral valve cups are normal in thickness & excursion.

M.V. orifices area during diastolic is normal. MV closure is complete.

Aortic valve is normal with normal opening.

LV wall thickness is normal. Segment LV contractility is fair thus over LVEF 62 %.

Pericardium is normal.

No visible vegetation/clots/intracardiac mass.

IMPRESSION:- 1. Normal LV function.

2. No RWMA LVEF 62 %

3. Normal Cardiac Valves.

4. Normal size cardiac chambers.

5. No LVDD.


DR VATSAL KAYAL
(DM CARDIOLOGY)

	Observed values	Normal values
MITRAL VALVE ANTERIOR LEAFLET		
Structure	Normal	
Excursion		
E.F. Slope		80-150
E.P.S.S.		
B.Bump		2-7
Posterior Leaflet		
Structure	Normal	
Excursion	Normal.	
TRICUSPID VALVE		
	Normal	
PULMONARY VALVE		
	Normal	
AORTIC VALVE		
Structure	Normal	
Cusp Opening		
Closure line	Central	
DIMENSION		
LVID Diastole	36.0 mm	37-56 mm (FLAT) 35-57 mm (LEFT LAT.)
LVID SYSTOLE	24.0 mm	24-42 mm
RVID		7-23 mm (FLAT) 9-26 mm (LEFT LAT.)
IVS Thickness	8.0 mm	6-11
LVPW	8.0 mm	6-11 mm
LA	27.0 mm	19-40 mm
AO	21.0 mm	20-37 mm

Licensee: Gurjar Hospital & Endoscopy Centre Pvt. Ltd.

1, Scheme No. 44-B, Siddarth Nagar, BhanwarKuan Square,
A. B. Road, Indore (M.P.) 452 001

E-mail : ab.road@apolloclinic.com, Visit us at : www.apolloclinic.com

TO BOOK AN APPOINTMENT
 **0731 4870 738**
FOR SAMPLE COLLECTION
 **9893 110 657**

LV function

LVEF

62 %

DOPPLER STUDY

	Peak Velocity (m/sec)	Peak PG (mm/Hg)	Regulation
MV	Normal	Normal	Trivial
AV	Normal	Normal	Absent
PV	Normal	Normal	Absent
TV	Normal	Normal	Trivial

Licensee: Gurjar Hospital & Endoscopy Centre Pvt. Ltd.

1, Scheme No. 44-B, Siddarth Nagar, BhanwarKuan Square,

A. B. Road, Indore (M.P.) 452 001

E-mail : ab.road@apolloclinic.com, Visit us at : www.apolloclinic.com

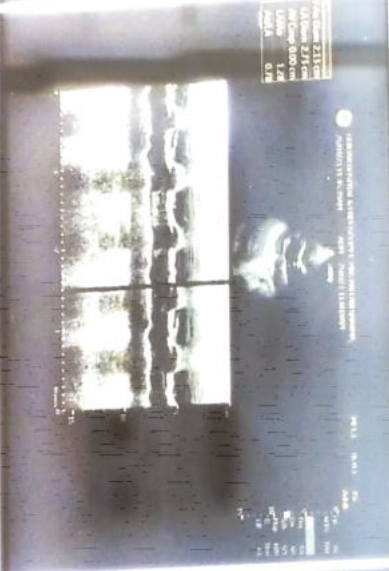TO BOOK AN APPOINTMENT
 **0731 4870 738**
 FOR SAMPLE COLLECTION
 **9893 110 657**

APOLLO CLINIC, INDORE

25 May 2018
Name: Mr. J. J.



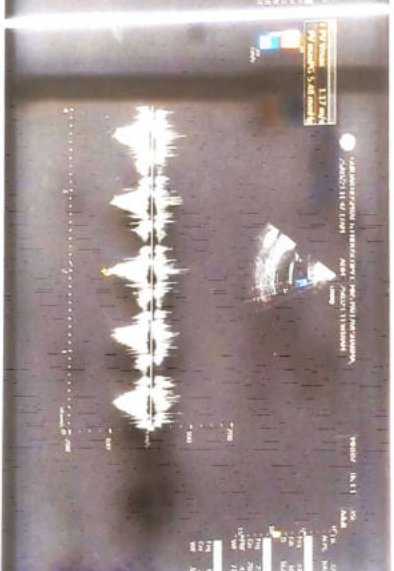
DATE: 21/05/18
TIME: 1.48
PREGNANT: 34 W 0 D
OP: 0.8



DATE: 21/05/18
TIME: 1.48
PREGNANT: 34 W 0 D
OP: 0.8



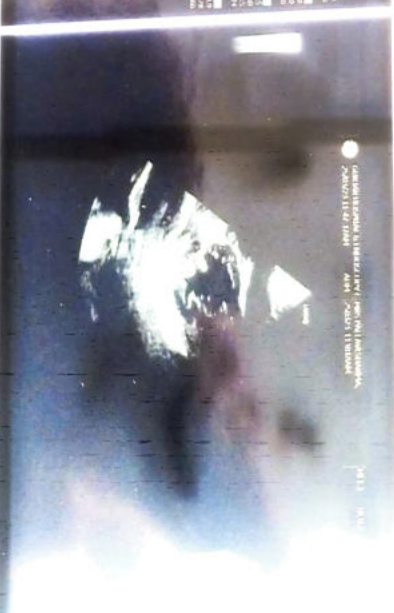
DATE: 21/05/18
TIME: 1.48
PREGNANT: 34 W 0 D
OP: 0.8



DATE: 21/05/18
TIME: 1.48
PREGNANT: 34 W 0 D
OP: 0.8



DATE: 21/05/18
TIME: 1.48
PREGNANT: 34 W 0 D
OP: 0.8



DATE: 21/05/18
TIME: 1.48
PREGNANT: 34 W 0 D
OP: 0.8



DATE: 21/05/18
TIME: 1.48
PREGNANT: 34 W 0 D
OP: 0.8



DATE: 21/05/18
TIME: 1.48
PREGNANT: 34 W 0 D
OP: 0.8



DATE: 21/05/18
TIME: 1.48
PREGNANT: 34 W 0 D
OP: 0.8

Mrs Pallavi Shasna



C/c by Dr A. Verma
(MS ENT)
9575650420

No ENT complaints
ENT examination - NAS

DR. ANJANEYA VERMA
MS ENT
Reg. No. MP-9152

Licensee: Gurjar Hospital & Endoscopy Centre Pvt. Ltd.
1, Scheme No. 44-B, Siddarth Nagar, BhanwarKuan Square,
A. B. Road, Indore (M.P.) 452 001
E-mail : ab.road@apolloclinic.com Visit us at : www.apolloclinic.com

TO BOOK AN APPOINTMENT
☎ 0731 4870 738

FOR SAMPLE COLLECTION
☎ 9893 110 657

CERTIFICATE OF MEDICAL FITNESS

This is to certify that I have conducted the clinical examination
of Pallavi sharma on 25/3/23

After reviewing the medical history and on clinical examination it has been found
that he/she is

	Tick
<ul style="list-style-type: none"> • Medically Fit 	<input type="checkbox"/>
<ul style="list-style-type: none"> • Fit with restrictions/recommendations <p>Though following restrictions have been revealed, in my opinion, these are not impediments to the job.</p> <p>1.....</p> <p>2.....</p> <p>3.....</p> <p>However, the employee should follow the advice/medication that has been communicated to him/her.</p> <p>Review after _____</p>	<input checked="" type="checkbox"/>
<ul style="list-style-type: none"> • Currently Unfit. Review after _____ recommended 	<input type="checkbox"/>
<ul style="list-style-type: none"> • Unfit 	<input type="checkbox"/>

Dr. 
Medical Officer
The Apollo Clinic
DR. PARAG CHANDAK
 MBBS, MD (MEDICINE)
 Reg. No. 18725

This certificate is not meant for medico-legal purposes

Alu Pallavi Shetima

29 yr



25/3/23

P2L2.

no weakness

2 wks

no menorrhagia

to

Ann $\frac{7 \text{ d.}}{26}$

2-3 pads / day.

R.

① - Tab Coartem 10 mg x 20 days

(5th day of cycle)
x 3 months.

② Tab Demokind Gold 100
x 3 months.

③ Symp Femis 07 10 ml 145
x 3 months.

Alu after 3 months.

Dr. KRATI MEHTA
M.B.B.S., M.S.
Obstetrician & Gynaecologist
Reg. No. MP-17626

krati

Licensee: Gurjar Hospital & Endoscopy Centre Pvt. Ltd.

1, Scheme No. 44-B, Siddarth Nagar, BhanwarKuan Square,
A. B. Road, Indore (M.P.) 452 001

E-mail : ab.road@apolloclinic.com Visit us at : www.apolloclinic.com

TO BOOK AN APPOINTMENT

0731 4870 738

FOR SAMPLE COLLECTION

9893 110 657

Patient Name : Mrs. PALLAVI SHARMA
 UHID/MR No. : FABR.000003099
 Visit Date : 25-03-2023 16:33
 Sample Collected on : 25-03-2023 16:42
 Ref Doctor : SELF

Age / Gender : 29Y/Female
 OP Visit No : FABROPV3570
 Reported on : 25-03-2023 16:50
 Specimen : Whole Blood (Edta)
 Pres Doctor: :


DEPARTMENT OF LABORATORY MEDICINE

TEST NAME	RESULT	BIOLOGICAL REFERENCE INTERVALS	UNITS
COMPLETE BLOOD COUNT			
TOTAL WBC COUNT: Method: Electrical Impedence	7,200	4000 - 11000	/cumm
HAEMOGLOBIN Method: Non Cyanide,SIs Based	11.9*	14 - 22	gm/dl
MCH. Method: Calculated	25.6*	27 - 32	pg
RBC COUNT Method: Electrical Impedence.	4.65	4.5 - 5.5	Mill/Cumm
HEMATOCRIT(PCV) Method: Cumulative Pulse	37.9	36 - 46	%
MCV Method: Calculated	81.5*	83 - 101 fl	fl
MCHC Method: Calculated	31.4*	31.5 - 34.5	%
PLATELET COUNT Method: Electrical Impedence	2.09	1.5-4 lakhs/ cu mm	Lac/cumm
NEUTROPHIL Method: Microscopy	60	40 - 80	%
LYMPHOCYTE Method: Microscopy	30	20 - 40	%
MONOCYTE Method: Microscopy	03	2 - 10	%
EOSINOPHIL. Method: Microscopy	07*	0 - 6	%
BASOPHIL Method: Microscopy	00	0 - 1	%
ESR Method: Westergren's Method	16	Male : <10 Female : < 12	mm/hr

End of the report

Results are to be correlated clinically

Lab Technician / Technologist
GHI0029


 DR. S.K SHARMA (V)
 MBBS MD
 MD PATHOLOGY

Patient Name : Mrs. PALLAVI SHARMA
UHID/MR No. : FABR.0000003099
Visit Date : 25-03-2023 09:56
Sample Collected on : 25-03-2023 13:10
Ref Doctor : SELF
Package Name : ARCOFEMI - MEDIWHEEL - FULL BODY ANNUAL PLUS
CHECK ADVANCED - FEMALE - 2D ECHO - PAN INDIA -
FY2324
Emp/Auth/TPA ID : MR.VISHAL GUPTA
Sponsor Name : ARCOFEMI HEALTHCARE LIMITED


Age : 29Y/Female
Gender : Female
OP Visit No. : FABROPV3556
Reported on : 25-03-2023 16:11
Specimen : Plasma(PP)
Expertise. Closer to you.
Pres Doctor:

DEPARTMENT OF LABORATORY MEDICINE

TEST NAME	RESULT	BIOLOGICAL REFERENCE INTERVALS	UNITS
GLUCOSE - (POST PRANDIAL) GLUCOSE POST PRANDIAL, Method: GOD-PAP	109.4	Normal: <140	mg/dl

End of the report

Results are to be correlated clinically

Lab Technician / Technologist
GHI0039


DR. S.K SHARMA (V)
MBBS MD
MD PATHOLOGY

Licensee: Gurjar Hospital & Endoscopy Centre Pvt. Ltd.

1, Scheme No. 44-B, Siddarth Nagar, BhanwarKuan Square,

A. B. Road, Indore (M.P.) 452 001

E-mail : ab.road@apolloclinic.com, Visit us at : www.apolloclinic.com

TO BOOK AN APPOINTMENT Page 1 of

 0731 4870 738

FOR SAMPLE COLLECTION

 9893 110 657

Patient's Name	MRS PALLAVI SHARMA				
Age / Sex	29Yrs. / F	Mob.No.	8319282609	Report Date:	25.03.2023
Ref. By	SELF			MR.NO.	FABR.0000003099

SONOGRAPHY OF BOTH BREAST:

Sonography of the both breast was performed using high frequency linear probe.

The skin complex and the subcutaneous fat lobules appear normal bilaterally.

The breast parenchyma is predominantly fibroglandular with no evidence of any focal lesion.

The nipple-areolar complex and the retroareolar region appear normal.

Underlying pectoralis muscle appears normal.

There are 1-2 lymph nodes with preserved central fatty hilum, seen in bilateral axilla, the largest measuring about 1.8 x 0.5 seen in right axilla.

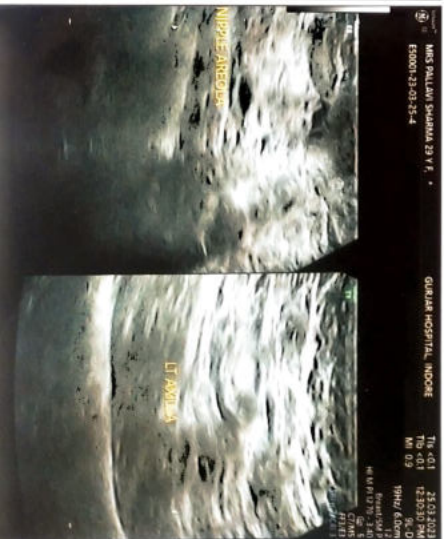
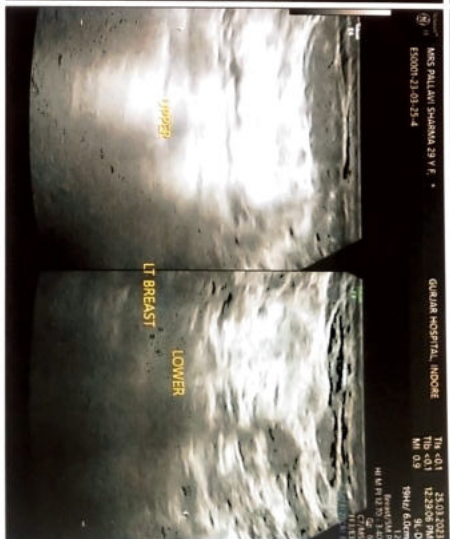
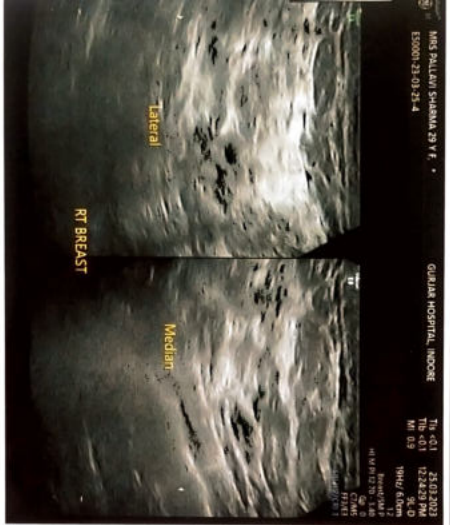
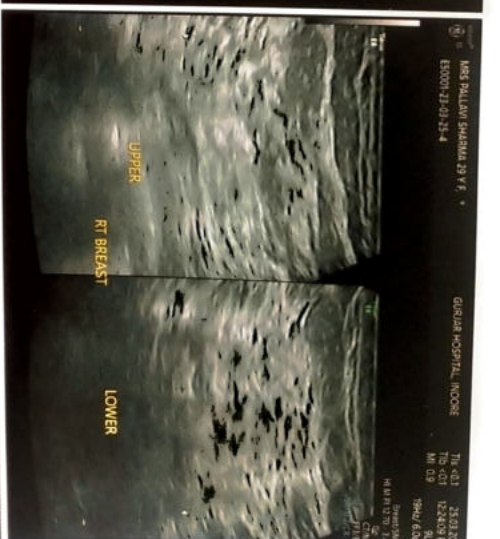
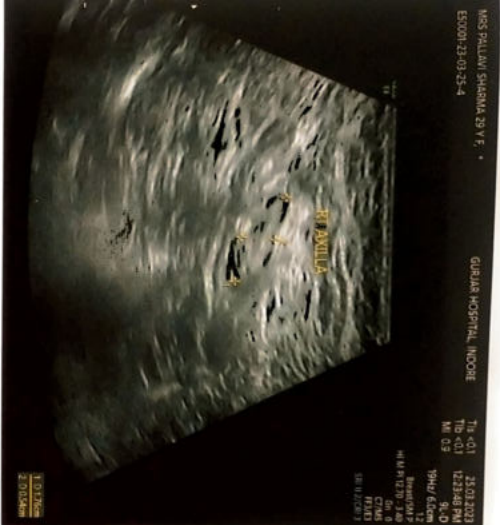
Impression: No significant abnormality is detected.

Advise - Clinico lab correlation & relevant other investigation.

Neetu Balwani
DR. NEETU BALWANI
M.B.B.S. D.N.B.
REG.NO-9035

APOLLO CLINIC, INDORE

123
MRS PALLAVI SHARMA 29 Y F



Pallavi Sharma
Age - 29y (F)

NO.: 869

[REF DATA]

UD:	12.00	CL:	-
<R>	SPH	CYL	AX
	+0.00	-0.75	84
	+0.00	-0.75	83
	+0.00	-0.75	81
AUE	+0.00	-0.75	83
<L>	SPH	CYL	AX
	+0.00	-0.50	66
	+0.00	-0.75	61
	+0.00	-0.50	64
AUE	+0.00	-0.50	64

PD = 55mm

C/O - D.O.V - 2 months
Dizziness

EVERVIEW Corp.
+82-2-757-3234

Vu < 6/9 E PH < 6/6
6/9 6/6

ACC < - 0.50 x 85° → 6/6 - N/6
- 0.50 x 70° → 6/6 - N/6

Colour vision < Normal
Normal

NCT < 12 mmHg
(@: 53PM) 12

Katung

Patient's Name	MRS PALLAVI SHARMA			Report Date:	25.03.2023
Age / Sex	29Yrs. / F	Mob.No.	8319282609	MR.NO.	FABR.0000003099
Ref. By	SELF				

SONOGRAPHY WHOLE ABDOMEN

Liver is slightly enlarged in size (16 cm in midclavicular span) with mild generalised increase in parenchymal echogenicity s/o grade I fatty infiltration. Portal vein is normal in caliber with normal hepatopetal flow. Intra hepatic biliary radicles and CBD are undilated. No focal lesion is seen.

Gall bladder is physiologically distended with evidence of small 4.6 mm focus seen along anterior wall suggesting ? GB Polyp. Wall thickness is normal.

Pancreas is normal in size and echotexture. Pancreatic duct is undilated. Spleen is normal in size (9.0 cms). Homogenous echotexture.

Both kidneys are normal in size, shape and position. Renal contours are smooth, parenchymal echogenicity is normal. Both renal pelvi-calyceal systems and both ureters are undilated.

Right kidney – 10.4 X 3.3 cms.

Left kidney – 11.0 X 4.8 cms.

No ascitis.

Urinary bladder has thin and smooth walls, Contents are anechoic.

Prevoid urine approx 350 cc.

Post void residual urine is insignificant, approx 25 cc.

Uterus is anteverted, slightly bulky in size, smooth in contour & shows normal echotexture . Uterine size measured 9.8 x 4.0 x 5.8 cms (vol.120 cc). Myometrial echostructure is homogenous.

Endometrial thickness measured (10 mms).

Cervix is normal in size, shape and outline. Echotexture is normal.

P.T.O.

Both ovaries are normal in size and echotexture.

Right ovary measures 2.7 x 1.7 cm.

Left ovary measures 3.5 x 2.1 cm.

Pouch of Douglas is clear.

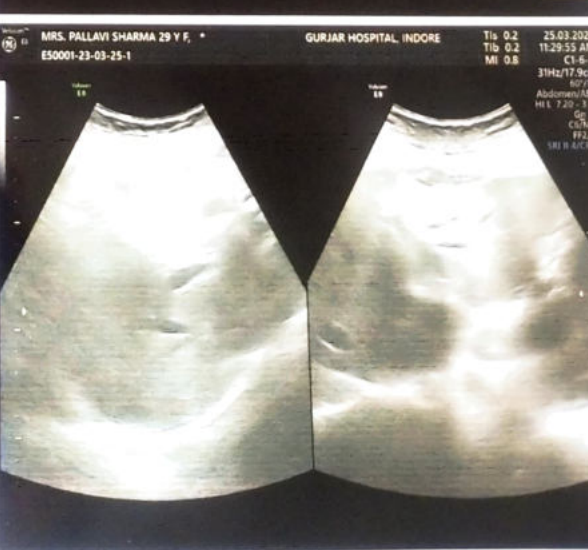
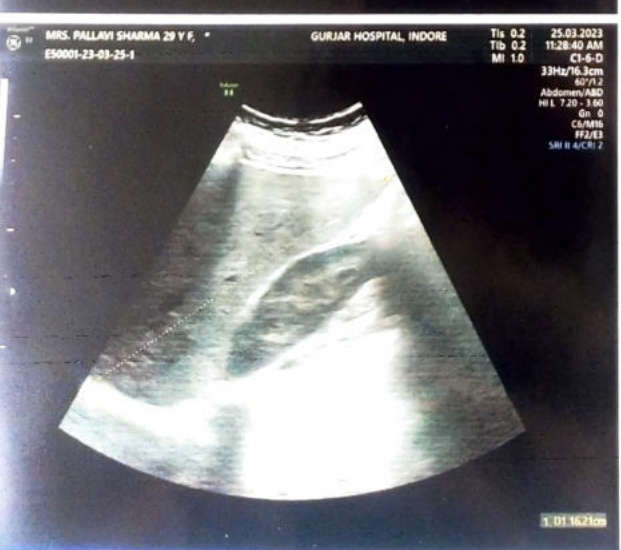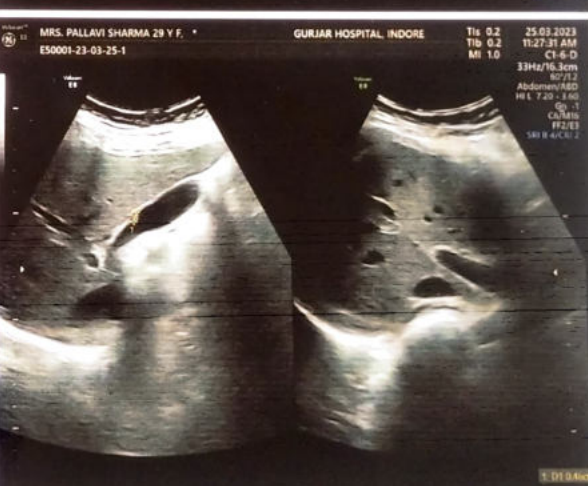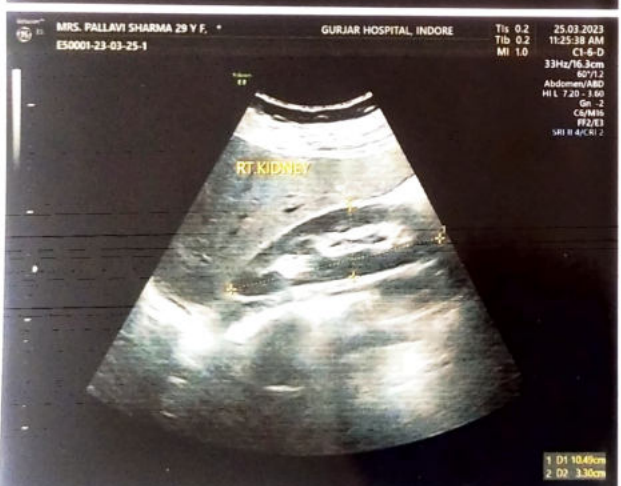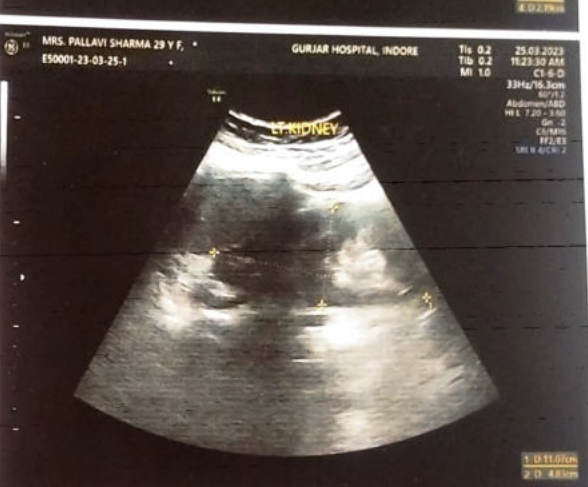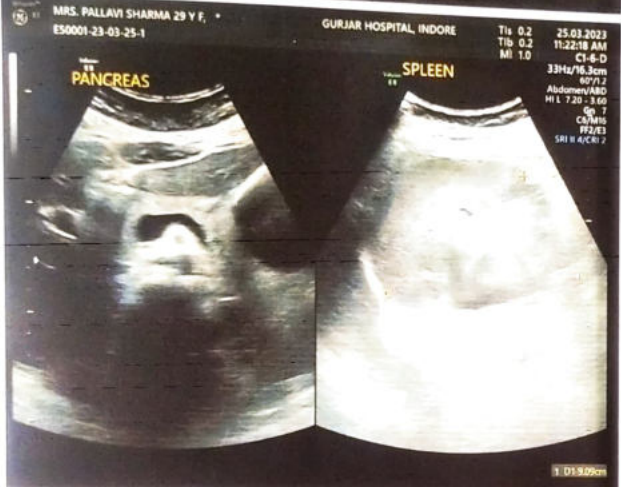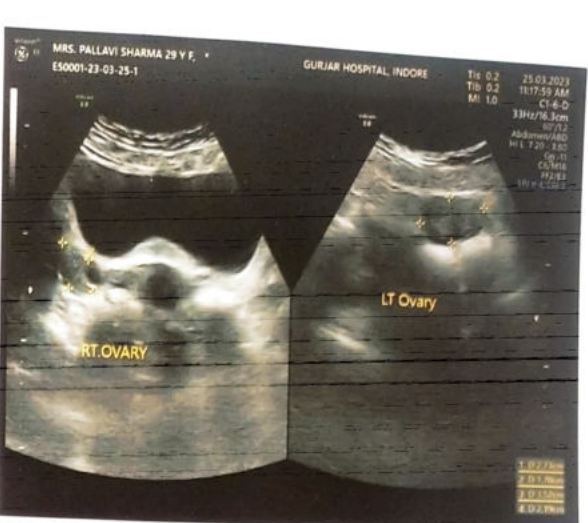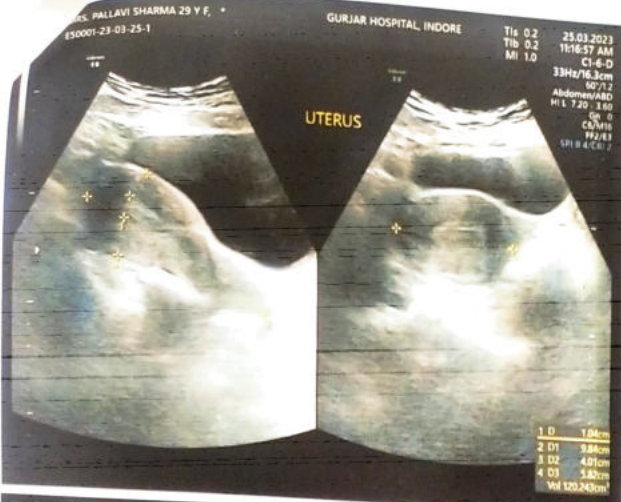IMPRESSION : 1) Mild Hepatomegaly with grade I fatty infiltration.

2) ? Small GB Polyp.

3) Slightly bulky Uterus.



DR. NEETU BALWANI
M.B.B.S. D.N.B.
REG.NO-9035



Name	Mrs. Pallavi Sharma 29Yrs				
Age/Sex	29Y/F	Patient ID	25032302	Referred By	DR P.CHANDAK
Study Date	2023-03-25 10:34	Report Date	2023-03-25 10:43		

Chest PA View

Observations

The lung fields are clear.

Both hila are normal.

Cardiophrenic and costophrenic angles are normal.

The trachea is central.

The mediastinal and cardiac silhouette are normal.

Cardiothoracic ratio is normal.

Bones of the thoracic cage are normal.

Soft tissues of the chest wall are normal.

Impression

Essentially normal study

Advice

Please correlate clinically

Name	Mrs. Pallavi Sharma 29Yrs				
Age/Sex	29Y/F	Patient ID	25032302	Referred By	DR P. CHANDAK
Study Date	2023-03-25 10:34	Report Date	2023-03-25 10:43		

Sushant

Dr. Sushant Mittal
MD radiodiagnosis
RMC 19070

Licensee: Gurjar Hospital & Endoscopy Centre Pvt. Ltd.

1, Scheme No. 44-B, Siddarth Nagar, BhanwarKuan Square,
A. B. Road, Indore (M.P.) 452 001

E-mail : ab.road@apolloclinic.com Visit us at : www.apolloclinic.com

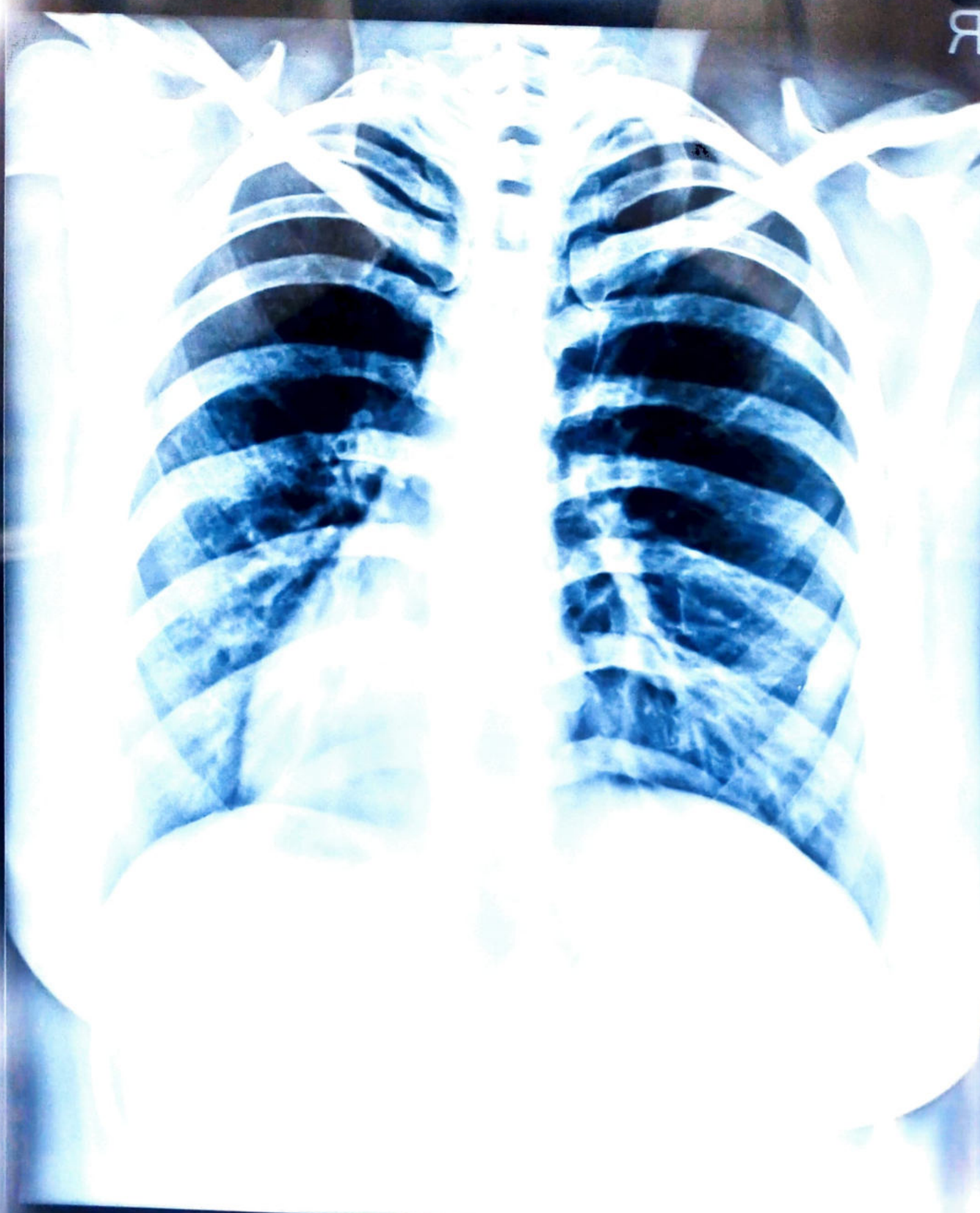TO BOOK AN APPOINTMENT

 **0731 4870 738**

FOR SAMPLE COLLECTION

 **9893 110 657**

R



Mrs. Pallavi Sharma 25yrs 25032302 F CHEST PA 25-Mar-23 10:34 AM
APOLLO CLINIC, INDORE [M.P.]