



# PANACEA HOSPITAL

B 36/44 F.K KABIR NAGAR, DURGAKUND  
TOLLFREE NO-18001233070.  
Whatsapp No - 8795832852  
www.piire.org



## OP Slip

Print Date : 15-Dec-2022 08:11AM



UHID No	:- UD-22230002926	OP No	:- OP-22230010996	OP Date	:- 15 Dec 2022 8:10AM
Patient Name	:- Mr SHAHNAWAZ TAUHEED	Age/Sex	:- 31 Y/Male	Mobile No	:- 8526624670
Father	:- TAUHEED ALAM	Department	:- DIABETES, ENDOCRINOLOGY & METABOLIC PHYSICIAN		
Pay Type	:- Cash	Consultant	:- Dr ASHUTOSH MISHRA (MD(MEDICINE), IMS, BHU)		
Token No	:- NOR. - 1	Paid/Bal	:- 0.00 / 500.00		
Patient Type	:- Normal				
Address	:- AWADH APARTMENT SHIVPUR, varanasi				

BP :- 130/80  
height :- 175.5  
Weight (kg) :- 95.9  
BMI :- 31.31

### Rx

SPO<sub>2</sub> - 99  
PR - 73  
NC - 43  
WC - 107  
RBS - 99  
PEFR - 510

Tab. Montems-fx  $\frac{1}{2}$   
0-  
Tab. Doxolm. (400)  $\frac{0}{2}$   
Avalal (60) AD  $\times \frac{10}{10}$   
↓  
SUNITHA

R/A 2 month

Printed By : Mr NITIN YADAV  
Created By : Mr NITIN YADAV

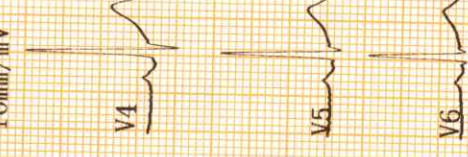
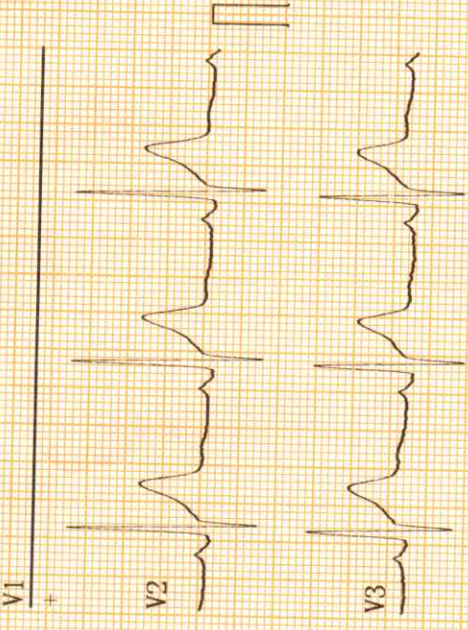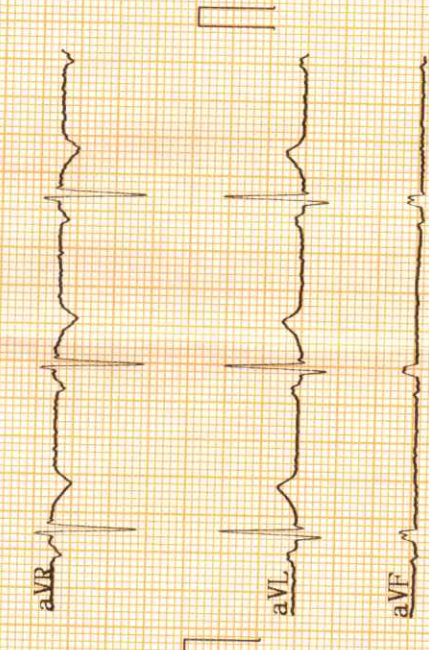
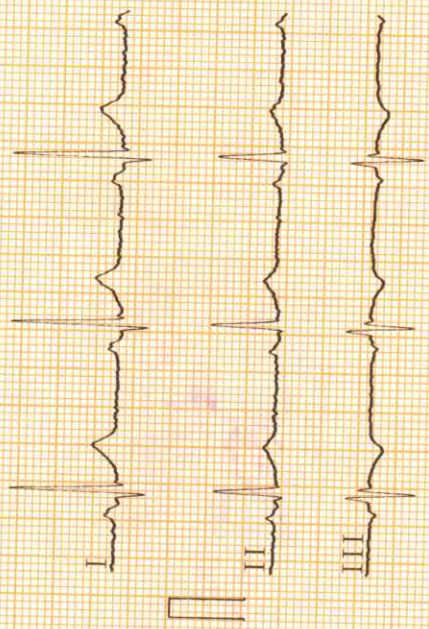BPL

AUTO 10mm/mV

10mm/mV

10mm/mV

10mm/mV



25mm/s AC50Hz + EMC35Hz

CARDIART



<< Conclusions >>

2022-12-27 08:35

10mm/mV

10mm/mV

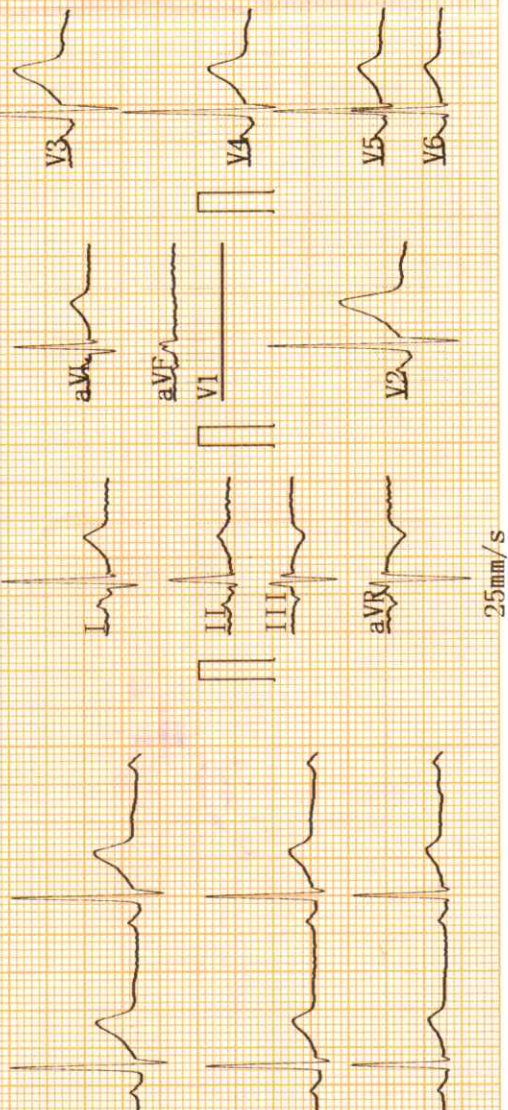
10mm/mV

25mm/s

ID :  
 Name :  
 Sex :  
 Height :  
 SYS :  
 DIA :  
 Age :  
 Weight : kg  
 HR : bpm : 67  
 PR Interval : ms : 159  
 P Duration : ms : 120  
 QRS Duration : ms : 78  
 T Duration : ms : 191  
 QT/QTc : ms : 354/373  
 P/QRS/T Axis : deg : 8.8/20.9/ 2.8  
 R(V5)/S(V1) : mV : 1.48/0.00  
 R(V5)+S(V1) : mV : 1.48

Normal Sinus Rhythm.  
 Longitudinal Left axis deviation,  
 old high lateral MI.  
 \*\*Report need physician confirm\*\*

*Dr. P. P. Mishra*  
**DR. P. P. MISHRA**  
 MCI Reg. No. 52033  
 MD (GENERAL MEDICINE)



Physician



# PANACEA HOSPITAL

*A shelter for many hearts A Home for many lives*

(An ISO 9001:2008 Certified Organisation)

Lab Attached with CMC Vellore Under EQAS Scheme

<b>Name</b>	MR.SHAHNAWAZ TAUHEED	<b>Sex /Age</b>	31/M	<b>Date</b>	15/12/2022
<b>Ref. by</b>	Dr.Pallavi Mishra(MD)	<b>BSA - m<sup>2</sup></b>		<b>Echo window</b>	fair

### Echo - Cardiography

MITRAL VALVE Doppler	AML - normal morphology MV Flow - E - 0.8 A-0.6 E/A=1.31	PML - normal morphology MVA - 3.0 cm <sup>2</sup> Mitral Regurgitation - No
TRICUSPID VALVE Doppler	Normal TV Flow -No	Tricuspid Regurgitation -No
PULMONARY VALVE Doppler	Normal PV Flow -No	Pulmonary Regurgitation - No
AORTIC VALVE Doppler	Trileaflet-No AV Flow - no	Aortic Regurgitation - no
MEASUREMENT	Aorta - 26.3 (20-38) mm IVS ed - 12.0 (6 -12) mm LVID ed - 50.8 (35 - 55) mm LVPW ed - 15.4 (6 -12) mm OA - 7 (> 5) mm	LA - 30.3 (24-32) mm IVS es -17.7 (6 - 12) mm LVID es - 35.4 (24 - 40) mm LVPW es - 13.7 (6 -12) mm EPSS - 5 (< 9) mm

**CONCLUSION**

All cardiac chamber dimensions are WNL  
 No valvular abnormalities  
 Good LV systolic function present Modified Simpson's method (4C, 2C) (LVEF-57%)  
 No diastolic dysfunction present (E/A = 1.31) by tissue Doppler (E/e'=7.8)  
 No RWMA  
 No pericardial effusion  
 Intact IAS / IV  
 No PAH  
 No intra cardiac mass /thrombus /vegetation

**IMPRESSION**      **Normal Echocardiogram**

Niraj Mishra  
Physician Assistant  
(PIIRE)

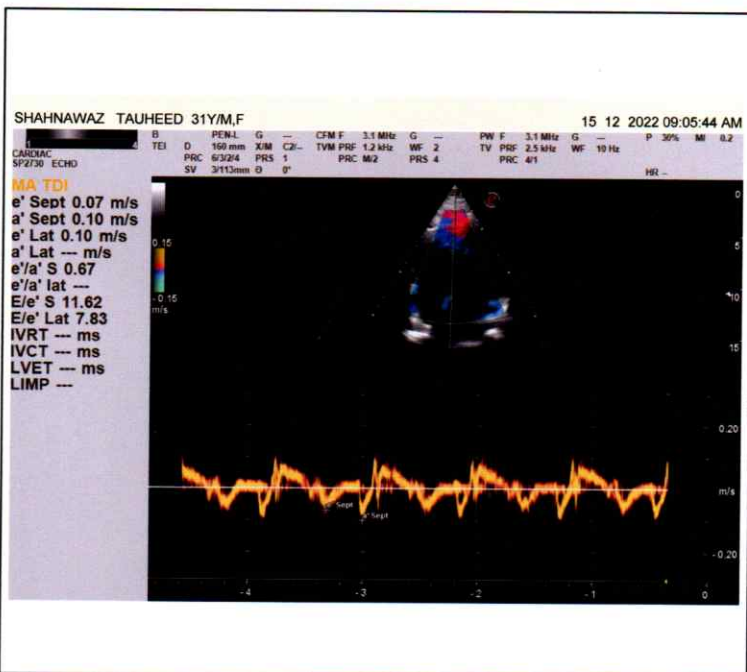
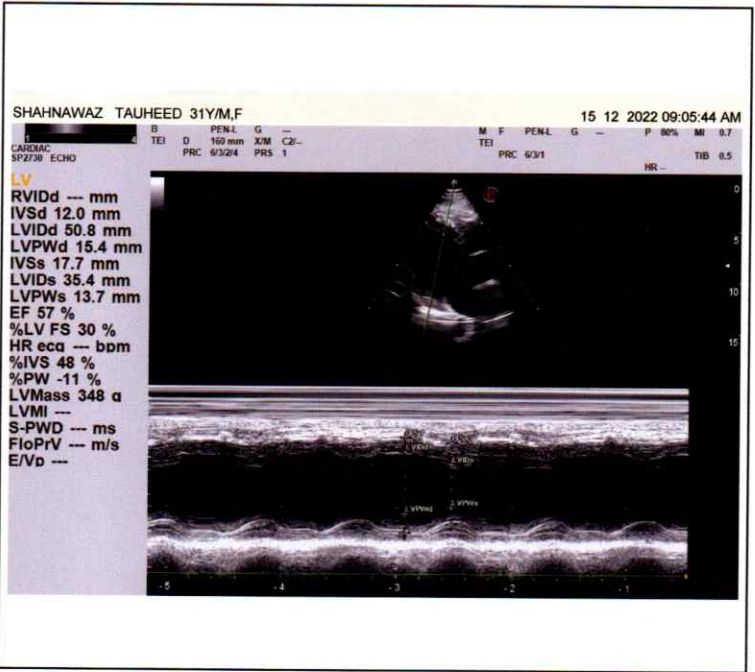
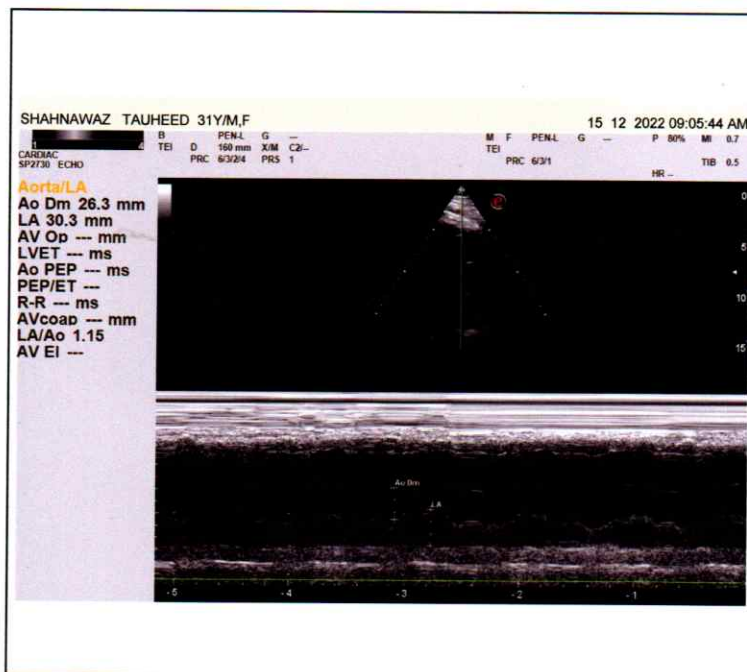
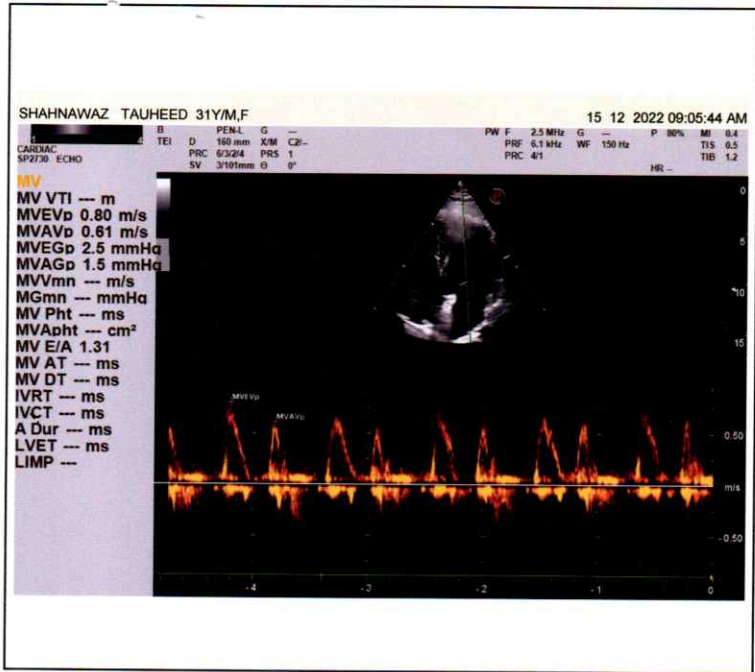
**DR. PALLAVI MISHRA**  
 MBBS, MD (GENERAL MEDICINE)  
 Dr. Pallavi Mishra 52033  
 MBBS, MD (MED) Lucknow  
 Echocardiography Specialist, MIAE  
 Non-invasive cardiologist  
 Women Cardiologist  
 Diabetocardiologist

**Address : Kabir Nagar (Near Sanjay Shiksha Niketan), Durgakund, Varanasi**

**Mobile : 9554572190 / 9453837595 / Recpri. 9389994334**

**E-mail : dramishra@gmail.com, drpallaviojha@gmail.com, Website: www.piore.org**





**Facilities:**  
 All clinical Biomedical & Hematology Investigations  
 including Bone Marrow Examination  
 VPT, Podiascan & Complete Foot Care (First Time in Purvanchal)  
 All Hormonal Investigation by Chemiluminescent Method  
 Visceral Fat by (AB-140) Ambulatory BP Monitoring  
 CGMS & Insulin Pump Available  
 PFT, 2D-ECHO (Color Doppler), Holter, TMT, Cardiac-3 available  
 VIA, VILI, Colposcopy available  
 Special Endocrinological Investigation Protocols.

ISO 9001:2008 Certified  
 Mobile: 9389994334, 9554572190, 9453837595



## Panacea Pathology Clinical Reference Lab

Persistence, Preparedness and Precision  
 EQAS (CMC Vellore Attached) & IQAS System  
 पूर्वांचल की सर्वोत्तम गुणवत्ता वाली पैथोलॉजी

PATIENT NAME : SHAHNAWAZ TAUHEED	AGE/GENDER : 31 YRS/MALE
REFD BY DR. : ARCO FEMI HEALTHCARE LTD.	RECEIVED DATE : 15-12-2022 (10:15 AM)
SAMPLE : BLOOD & URINE	REPORT DATE : 15-12-2022 (18:15 PM)

### PATHOLOGY REPORT

#### COMPLETE BLOOD COUNT (CBC)

TEST	LAB TEST VALUES	NORMAL RANGE
<b>HEMOGRAM</b>		
HEMOGLOBIN (FLOW CYTOMETRY)	16.1	13 – 16 gm/dl
TOTAL LEUCOCYTE COUNT (TLC)	5,900	4000 – 11000
RBC COUNT	5.31	3.5 – 5.5
PCV (HCT)	47.8	37 – 47
MCV	90.0	80 – 95
MCH	30.2	28 – 34
MCHC	33.7	30 – 36
PLATELET COUNT	1,71,000	1,50,000 – 4,00,000
E.S.R. (WINTROBE FIRST HOURS)	10.0	20 mm/1 <sup>st</sup> hr
<b>DIFFERENTIAL LEUCOCYTE</b>		
NEUTROPHILS	54	40 – 75%
LYMPHOCYTES	40	20 – 45%
EOSINOPHILS	03	1 – 6%
MONOCYTES	03	2 – 8%
BASOPHILS	00	< 2 %

#### RENAL & KIDNEY PROFILE, SERUM

TEST	LAB TEST VALUES	NORMAL RANGE
<b>RENAL FUNCTION TESTS</b>		
BLOOD UREA NITROGEN (BUN)	11.6	10 – 50 mg/dl
SERUM CREATININE	0.97	0.60 – 1.60 mg/dl
URIC ACID	3.96	3.60 – 7.70 mg/dl
ALKALINE PHOSPHATASE (ALP)	78.0	142 – 353 mg/dl
TOTAL PROTIENS	7.50	0 – 39 mg/dl
ALBUMIN	4.11	3.8 – 5.4 mg/dl
SERUM GLOBULIN	2.29	2.1 – 3.5 mg/dl
CALCIUM	9.80	8.80 – 10.20
PHOSPHORUS	3.42	2.50 – 5.00
SERUM SODIUM NA+	140.3	135.00 – 155.00 mEq/Ltr
SERUM POTASIUM K+	4.02	3.60 – 5.50 mEq/Ltr
ICALCIUM	1.15	1.10 – 1.35 mmol/L
SERUM CHLORIDE CL+	104.3	98.00 – 110.00 mEq/Ltr

PAGE 1

Lab Technician

M.D., Pathology

Timing : 8.00 a.m. to 9.00 p.m. (Sunday 8.00 a.m. to 3.00 p.m.)

This Report is not valid for medico legal purpose

**Note:** These tests have technical limitations. Clinico-pathological interpretation is necessary. In case of any disparity test may be repeated immediately.

Address : 36/44 FK Kabir Nagar, Durgakund, Varanasi – 221005

Email: [dramishra@gmail.com](mailto:dramishra@gmail.com), [drpallaviojha@gmail.com](mailto:drpallaviojha@gmail.com) Website: [panaceahospital.org](http://panaceahospital.org)

**Facilities:**  
 All clinical Biomedical & Hematology Investigations  
 including Bone Marrow Examination  
 VPT, Podiascan & Complete Foot Care (First Time in Purvanchal)  
 All Hormonal Investigation by Chemiluminescent Method  
 Visceral Fat by (AB-140) Ambulatory BP Monitoring  
 CGMS & Insulin Pump Available  
 PFT, 2D-ECHO (Color Doppler), Holter, TMT, Cardiac-3 available  
 VIA, VILI, Colposcopy available  
 Special Endocrinological Investigation Protocols.

ISO 9001:2008 Certified  
 Mobile: 9389994334, 9554572190, 9453837595



## Panacea Pathology Clinical Reference Lab

Persistence, Preparedness and Precision  
 EQAS (CMC Vellore Attached) & IQAS System  
 पूर्वांचल की सर्वोत्तम गुणवत्ता वाली पैथोलॉजी

PATIENT NAME : SHAHNAWAZ TAUHEED	AGE/GENDER : 31 YRS/MALE
REFD BY DR. : ARCO FEMI HEALTHCARE LTD.	RECEIVED DATE : 15-12-2022 (10:15 AM)
SAMPLE : BLOOD & URINE	REPORT DATE : 15-12-2022 (18:15 PM)

### PATHOLOGY REPORT

#### LIPID PROFILE, SERUM

TEST	LAB TEST VALUES	NORMAL RANGE
<b>BLOOD CHEMISTRY</b>		
TOTAL CHOLESTEROL (SERUM)	156.0	Desirable:- &lt; 200 mg/dl Borderline:- 200 – 239 mg/dl High:- &gt; 240 mg/dl
TRIGLYCERIDES (SERUM)	165.0	35 – 170 mg/dl
HDL CHOLESTEROL (SERUM)	42.0	35.30 – 79.50 mg/dl
LDL CHOLESTEROL (SERUM)	81.0	&lt; 130 mg/dl
VLDL	33.0	&lt; 40 mg/dl
NON HDL	71.6	0.00 – 100.00 mg/dl
CHOLESTROL/HDL RATIO	3.71	&lt; 3.0 Low Risk Ratio 3.0 – 5.0 Avg Risk &lt; 5.0 High Risk
LDL/HDL RATIO	1.92	&lt; 3 Ratio

#### GLYCOSYLATED HEMOGLOBIN (HBA1C)

TEST	LAB TEST VALUES	NORMAL RANGE
HBA1C	5.9	Normal : <5.97 % Good Control : 5.97 – 6.81% Fair Control : 6.81 – 7.65% Poor Control : >7.65%

#### THYROID PROFILE (T3, T4, TSH)

TEST	LAB TEST VALUES	NORMAL RANGE
<b>THYROID FUNCTION TEST</b>		
T3	0.96	0.60 – 1.81 ng/ml
T4	8.10	4.50 – 10.90 ug/dl
TSH	2.52	0.39 – 6.10 uIU/mL

PAGE 2

Lab Technician

M.D., Pathology

Timing : 8.00 a.m. to 9.00 p.m. (Sunday 8.00 a.m. to 3.00 p.m.)

This Report is not valid for medico legal purpose

**Note:** These tests have technical limitations. Clinico-pathological interpretation is necessary. In case of any disparity test may be repeated immediately.


Address : 36/44 FK Kabir Nagar, Durgakund, Varanasi – 221005

Email: [dramishra@gmail.com](mailto:dramishra@gmail.com), [drpallaviojha@gmail.com](mailto:drpallaviojha@gmail.com) Website: [panaceahospital.org](http://panaceahospital.org)



**Facilities:**  
 All clinical Biomedical & Hematology Investigations  
 including Bone Marrow Examination  
 VPT, Podiascan & Complete Foot Care (First Time in Purvanchal)  
 All Hormonal Investigation by Chemiluminescent Method  
 Visceral Fat by (AB-140) Ambulatory BP Monitoring  
 CGMS & Insulin Pump Available  
 PFT, 2D-ECHO (Color Doppler), Holter, TMT, Cardiac-3 available  
 VIA, VILI, Colposcopy available  
 Special Endocrinological Investigation Protocols.

ISO 9001:2008 Certified  
 Mobile: 9389994334, 9554572190, 9453837595



**Panacea Pathology**  
**Clinical Reference Lab**  
 Persistence, Preparedness and Precision  
 EQAS (CMC Vellore Attached) & IQAS System  
 पूर्वांचल की सर्वोत्तम गुणवत्ता वाली पैथोलॉजी

PATIENT NAME : SHAHNAWAZ TAUHEED	AGE/GENDER : 31 YRS/MALE
REFD BY DR. : ARCO FEMI HEALTHCARE LTD.	RECEIVED DATE : 15-12-2022 (10:15 AM)
SAMPLE : BLOOD & URINE	REPORT DATE : 15-12-2022 (18:15 PM)

### PATHOLOGY REPORT

#### LIVER PROFILE TEST, SERUM

TEST	LAB TEST VALUES	NORMAL RANGE
<b>BIO CHEMISTRY</b>		
TOTAL BILIRUBIN	0.78	0.0 – 1.1 mg/dl
DIRECT BILIRUBIN	0.22	0.0 – 0.2 mg/dl
INDIRECT BILIRUBIN	0.50	< 0.90 mg/dl
SGOT (AST)	25.0	0 – 52 mg/dl
SGPT (ALT)	23.0	0 – 39 mg/dl
GGT (GYT)	29.0	< 55 U/L

#### URINE ROUTINE EXAMINATION

TEST	LAB TEST VALUES	NORMAL RANGE
<b>PHYSICAL EXAMINATION</b>		
QUANTITY	30	ML
COLOUR	STRAW	PALE YELLOW
APPEARANCE	CLEAR	CLEAR
SPECIFIC GRAVITY	1.010	1.01 – 1.03
PH	5.5	4.7 – 7.5
<b>CHEMICAL EXAMINATION</b>		
GLUCOSE	Not Detected	Not Detected
PROTEIN	NIL	Not Detected
<b>MICROSCOPIC EXAMINATION</b>		
PUS CELLS	1-2	0-5
RBC	Not Detected	Not Detected
EPITHELIAL CELLS	1-2	0-5
CASTS	Not Detected	Not Detected
CRYSTALS	Not Detected	Not Detected
BACTERIA	Not Detected	Not Detected

#### BLOOD GROUP

TEST	LAB TEST VALUES
BLOOD GROUPING	
SAMPLE WHOLE BLOOD EDTA	"A" POSITIVE

PAGE 3

Lab Technician

M.D., Pathology

Timing : 8.00 a.m. to 9.00 p.m. (Sunday 8.00 a.m. to 3.00 p.m.)

This Report is not valid for medico legal purpose

**Note:** These tests have technical limitations. Clinico-pathological interpretation is necessary. In case of any disparity test may be repeated immediately.

Address : 36/44 FK Kabir Nagar, Durgakund, Varanasi – 221005

Email: [dramishra@gmail.com](mailto:dramishra@gmail.com), [drpallaviojha@gmail.com](mailto:drpallaviojha@gmail.com) Website: [panaceahospital.org](http://panaceahospital.org)



**Facilities:**  
All clinical Biomedical & Hematology Investigations  
including Bone Marrow Examination  
VPT, Podiascan & Complete Foot Care (First Time in Purvanchal)  
All Hormonal Investigation by Chemiluminescent Method  
Visceral Fat by (AB-140) Ambulatory BP Monitoring  
CGMS & Insulin Pump Available  
PFT, 2D-ECHO (Color Doppler), Holter, TMT, Cardiac-3 available  
VIA, VILI, Colposcopy available  
Special Endocrinological Investigation Protocols.

ISO 9001:2008 Certified  
Mobile: 9389994334, 9554572190, 9453837595



## Panacea Pathology Clinical Reference Lab

Persistence, Preparedness and Precision  
EQAS (CMC Vellore Attached) & IQAS System  
पूर्वांचल की सर्वोत्तम गुणवत्ता वाली पैथोलॉजी

PATIENT NAME : SHAHNAWAZ TAUHEED	AGE/GENDER : 31 YRS/MALE
REFD BY DR. : ARCO FEMI HEALTHCARE LTD.	RECEIVED DATE : 15-12-2022 (10:15 AM)
SAMPLE : BLOOD & URINE	REPORT DATE : 15-12-2022 (18:15 PM)

### FASTING/RANDOM BLOOD SUGER

TEST	LAB TEST VALUES	NORMAL RANGE
FBS/RBS		
FASTING BLOOD SUGER	73.0	110-125 mg/dl
RANDOM BLOOD SUGER	122.0	125-140 mg/dl

----- End of Report -----

Lab Technician

M.D., Pathology

Timing : 8.00 a.m. to 9.00 p.m. (Sunday 8.00 a.m. to 3.00 p.m.)

This Report is not valid for medico legal purpose

**Note:** These tests have technical limitations. Clinico-pathological interpretation is necessary. In case of any disparity test may be repeated immediately.

Address : 36/44 FK Kabir Nagar, Durgakund, Varanasi – 221005

Email: [dramishra@gmail.com](mailto:dramishra@gmail.com), [drpallaviojha@gmail.com](mailto:drpallaviojha@gmail.com) Website: [panaceahospital.org](http://panaceahospital.org)



Call Now - 1800-123-3070

# PANACEA HOSPITAL

*A shelter for many hearts A Home for many lives*

(An ISO 9001:2008 Certified Organisation)

Lab Attached with CMC Vellore Under EQAS Scheme

**NAME:** MR.SHAHNAWAZ TAUHEED

**AGE/SEX:** 31 YRS / MALE

**REF BY:** DR. ASHUTOSH MISHRA (MD)

**DATE:** 15/12/2022

## ULTRA SOUND WHOLE ABDOMEN REPORT

**Liver:** Normal in shape and size(11.0 cm) and shows smooth and regular margin.  
No diffuse/focal lesion seen.

**Gall bladder:** Partially distended with normal wall thickness and echo-free lumen.

**CBD diameter** Visualized part normal in course & caliber.

**Pancreas:** Normal in size, shape & echogenicity.  
Margins are smooth & regular.  
No diffuse/ focal lesion seen. Pancreatic tail obscured.

**Spleen:** Normal in size,(9.1 cm) shape & echogenicity.  
Margins are smooth & regular. No diffuse / focal lesion seen.  
Splenic vessels at hilum is normal.

**Kidney:** Right kidney: 11.2 X 4.3cm  
Left kidney: 11.7 X 5.2 cm  
Both normal in size, shape, echogenicity & position.  
Cortical-medullary differentiation is maintained.  
Pelvicalyceal system normal.  
No calculus/mass lesion seen.  
No hydronephrosis/ hydroureter seen.  
No suprarenal mass lesion.

**Address :** Kabir Nagar (Near Sanjay Shiksha Niketan), Durgakund, Varanasi

**Mobile :** 9554572190 / 9453837595 / Recpn. 9389994334

**E-mail :** dramishra@gmail.com, drpallaviojha@gmail.com, **Website:** www.piire.org





# PANACEA HOSPITAL

*A shelter for many hearts A Home for many lives*

(An ISO 9001:2008 Certified Organisation)

Lab Attached with CMC Vellore Under EQAS Scheme

**Urinary bladder:** Normally distended, wall thickness is normal.

No echogenic foci lumen or diverticula seen.

Both VUJ appears normal.

No E.R. calculus / mass lesion seen.

**Prostate:**

Normal in size, shape, & echogenicity.

No calcification or focal cystic lesion seen.

Capsular margins are smooth and regular.

Seminal vesicles appear normal in size, shape & echogenicity.

No diffuse /focal lesion seen.

**Others:**

No free fluid in peritoneal cavity.

No free fluid in bilateral pleural cavity.

**IMPRESSION:**

- **NO SIGNIFICANT SONOLOGICAL ABNORMALITY DETECTED.**

-----  
Please correlate clinically and further investigations.

*DR. Pallavi Mishra*  
**DR. PALLAVI MISHRA**

**MBBS, MD (GENERAL MEDICINE)**

**DR. PALLAVI MISHRA**

**MBBS MD(MED) Lucknow**

**Echocardiography specialist, MIAE**

**Non invasive cardiologist**

**Women cardiologist**

**Radiologist**

**Dr. Tusharika Rai**

**MBBS MS**

**NIRAJ MISHRA**

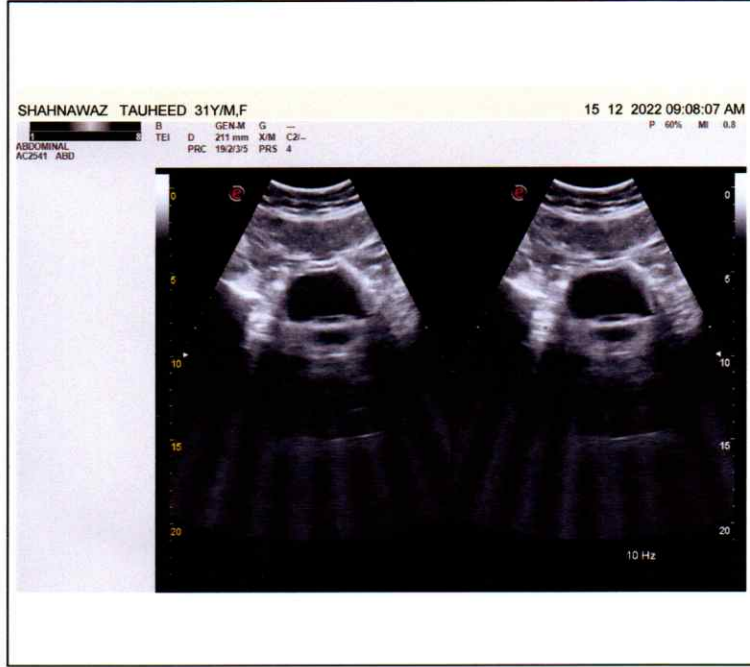
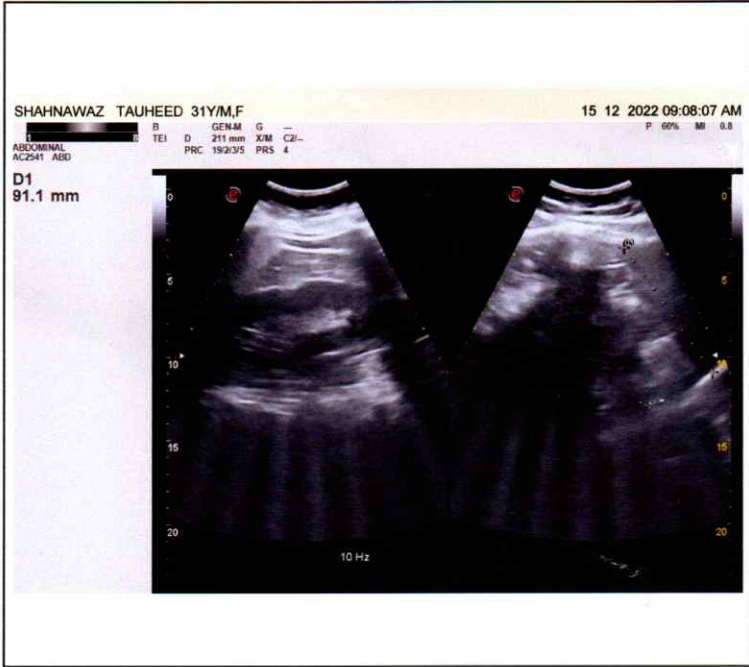
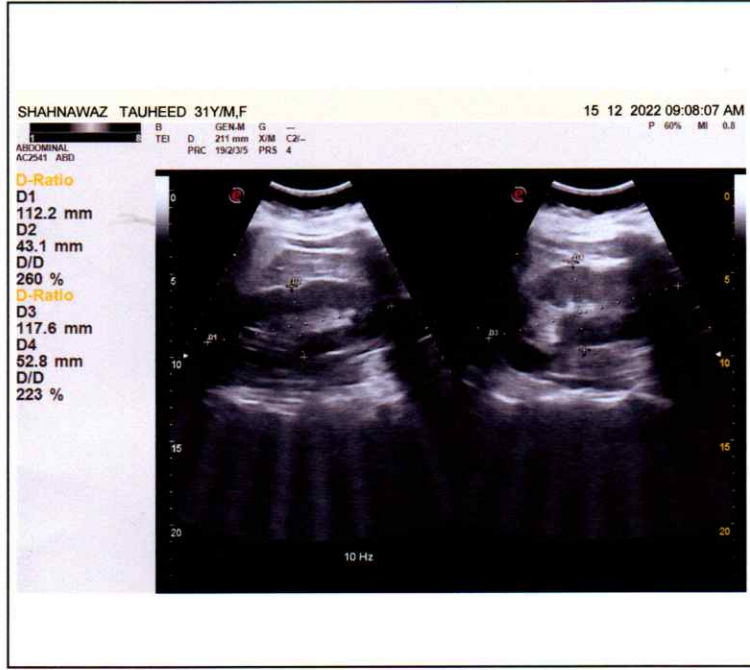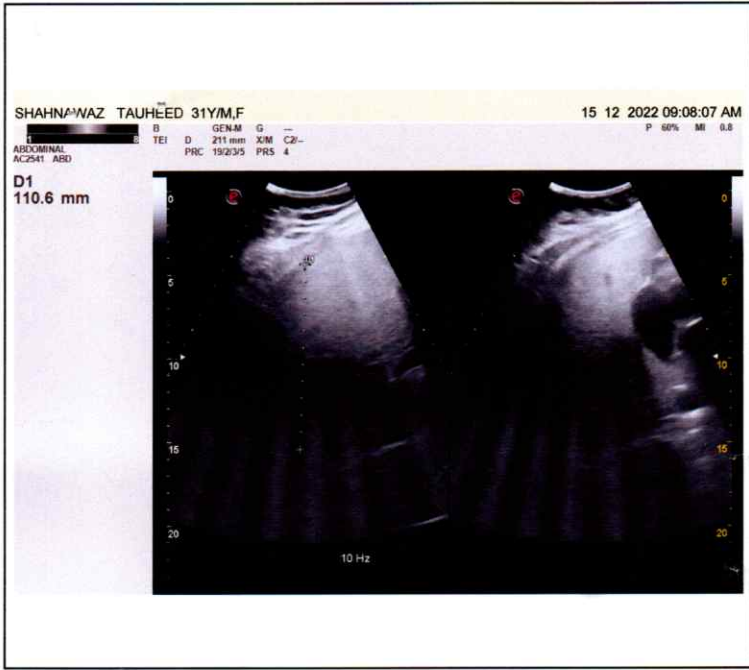**(Physician Assistant)**

**(PIIRE)**

**Address : Kabir Nagar (Near Sanjay Shiksha Niketan), Durgakund, Varanasi**

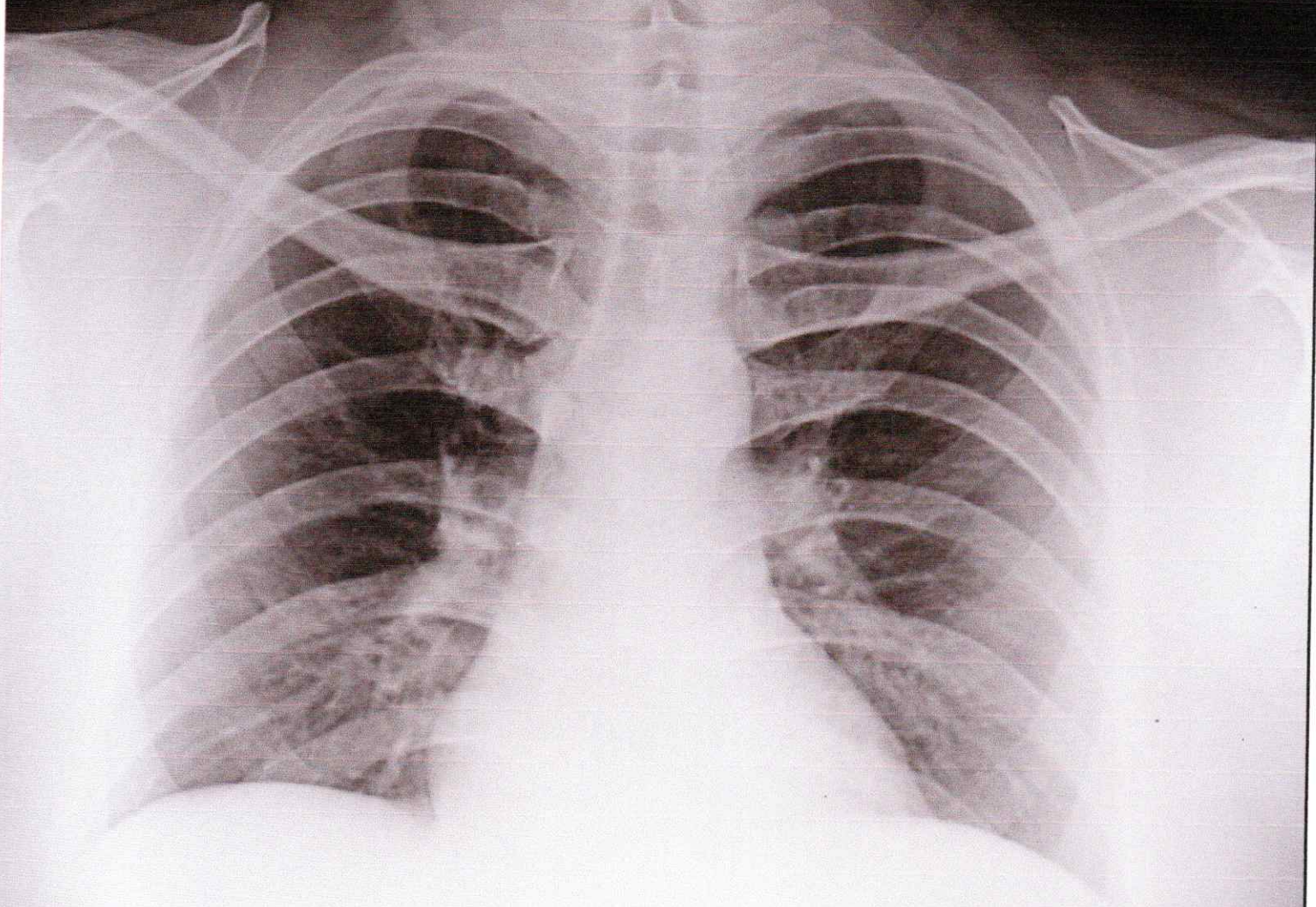
**Mobile : 9554572190 / 9453837595 / Recpn. 9389994334**

**E-mail: dramishra@gmail.com, drpallaviojha@gmail.com, Website: www.piire.org**





R



SHAHNAWAZ TAUHEED 31Y/M 2926 M CHEST P.A. 15-Dec-22 08:35 AM

PANACEA HOSPITAL, KABIR NAGAR, DURGAKUND, VARANASI





Call Now - 1800-123-3070

# PANACEA HOSPITAL

*A shelter for many hearts A Home for many lives*

(An ISO 9001:2008 Certified Organisation)

Lab Attached with CMC Vellore Under EQAS Scheme

**NAME:** MR.SHAHNAWAZ TAUHEED

**AGE/SEX:** 31 YRS / MALE

**REF BY:** DR.ASHUTOSH MISHRA(MD)

**DATE:** 15/12/2022

## X-RAY CHEST PA

### BOTH LUNG FIELDS AND PLEURAE:

Both lungs show normal bronchovascular pattern.

Right & left hila are normal

No focal mass or calcification is seen

There is no evidence of any fluid in the both the pleural cavities.

Both domes of diaphragms are normal in position.

### MEDIASTINUM:

Trachea is central in position.

Cardiac silhouette is of normal size and configuration.

No evidence of pericardial effusion.

No significant lymphadenopathy is seen.

Visualized skeleton is normal.

NO SIGNIFICANT RADIOGRAPHIC ABNORMALITY

**DR. ALPANA PATHAK**

**MD, RADIOLOGY**

**REG. NO. 46465**

**REPORTED BY**

**DR. ALPANA PATHAK**

**MBBS (HONS, GOLD MEDALIST) PMCH, PATNA  
MD RADIODIAGNOSIS (GOLD MEDALIST) IMS BHU  
EX-SR, IMS BHU, VARANASI**

**Address : Kabir Nagar (Near Sanjay Shiksha Niketan), Durgakund, Varanasi**

**Mobile : 9554572190 / 9453837595 / Recpn. 9389994334**

**E-mail : dramishra@gmail.com, drpallaviojha@gmail.com, Website: www.paire.org**