

**Facilities:**

All clinical Biomedical & Hematology Investigations including Bone Marrow Examination  
VPT, Podiascan & Complete Foot Care (First Time in Purvanchal)  
All Hormonal Investigation by Chemiluminescent Method  
Visceral Fat by (AB-140) Ambulatory BP Monitoring  
CGMS & Insulin Pump Available  
PFT, 2D-ECHO (Color Doppler), Holter, TMT, Cardiac-3 available  
VIA, VILI, Colposcopy available  
Special Endocrinological Investigation Protocols.



# Panacea Pathology

## Clinical Reference Lab

Persistence, Preparedness and Precision  
EQAS (CMC Vellore Attached) & IQAS System  
पूर्वांचल की सर्वोत्तम गुणवत्ता वाली पैथोलॉजी

PATIENT NAME : PINKY SINGH

AGE/GENDER : 32YRS/FEMALE

REFD BY DR. : ARCO FEMI HEALTHCARE LTD.

RECEIVED DATE : 28-01-2023(10:00AM)

SAMPLE : BLOOD &amp; URINE

REPORT DATE : 28-01-2023(06:00PM)

### PATHOLOGY REPORT

#### COMPLETE BLOOD COUNT (CBC)

TEST	LAB TEST VALUES	NORMAL RANGE
<b>HEMOGRAM</b>		
HEMOGLOBIN (FLOW CYTOMETRY)	11.0	13 – 16 gm/dl
TOTAL LEUCOCYTE COUNT (TLC)	4000	4000 – 11000
RBC COUNT	4.09	3.5 – 5.5
PCV (HCT)	35.3	37 – 47
MCV	86.4	80 – 95
MCH	27.0	28 – 34
MCHC	31.3	30 – 36
PLATELET COUNT	36,000	1,50,000 – 4,00,000
E.S.R. (WINTROBE FIRST HOURS)	26.0	20 mm/1 <sup>st</sup> hr
<b>DIFFERENTIAL LEUCOCYTE</b>		
NEUTROPHILS	44	40 – 75%
LYMPHOCYTES	52	20 – 45%
EOSINOPHILS	02	1 – 6%
MONOCYTES	03	2 – 8%
BASOPHILS	00	< 2%

#### RENAL & KIDNEY PROFILE, SERUM

TEST	LAB TEST VALUES	NORMAL RANGE
<b>RENAL FUNCTION TESTS</b>		
BLOOD UREA NITROGEN (BUN)	9.2	10 – 50 mg/dl
SERUM CREATININE	0.64	0.60 – 1.60 mg/dl
URIC ACID	4.0	3.60 – 7.70 mg/dl
ALKALINE PHOSPHATASE (ALP)	72.0	142 – 353 mg/dl
TOTAL PROTIENS	7.45	0 – 39 mg/dl
ALBUMIN	4.12	3.8 – 5.4 mg/dl
SERUM GLOBULIN	3.33	2.1 – 3.5 mg/dl
CALCIUM	9.0	8.80 – 10.20
PHOSPHORUS	3.04	2.50 – 5.00
SERUM SODIUM NA+	1.005	135.00 – 155.00 mEq/Ltr
SERUM POTASIMUM K+	4.12	3.60 – 5.50 mEq/Ltr
ICALCIUM	1.22	1.10 – 1.35 mmol/L
SERUM CHLORIDE CL+	101.3	98.00 – 110.00 mEq/Ltr

PAGE 1

Lab Technician

**PANACEA HOSPITAL**  
UNIT OF ARCO FEMI HEALTH CARE PVT. LTD.  
REG. NO.: AL-1500  
B.M.D. Pathology  
KABIR NAGAR  
DURGAKUND, VARANASI

Timing : 8.00 a.m. to 9.00 p.m. (Sunday 8.00 a.m. to 3.00 p.m.)

This Report is not valid for medico legal purpose

**Note:** These tests have technical limitations. Clinico-pathological interpretation is necessary. In case of any disparity test may be repeated immediately.

Address : 36/44 FK Kabir Nagar, Durgakund, Varanasi – 221005

Email: [dramishra@gmail.com](mailto:dramishra@gmail.com), [drpallaviojha@gmail.com](mailto:drpallaviojha@gmail.com) Website: [panaceahospital.org](http://panaceahospital.org)

Services:  
 Clinical Biomedical & Hematology Investigations  
 including Bone Marrow Examination  
 VPT, Podiascan & Complete Foot Care (First Time in Purvanchal)  
 All Hormonal Investigation by Chemiluminescent Method  
 Visceral Fat by (AB-140) Ambulatory BP Monitoring  
 CGMS & Insulin Pump Available  
 PFT, 2D-ECHO (Color Doppler), Holter, TMT, Cardiac-3 available  
 VIA, VILI, Colposcopy available  
 Special Endocrinological Investigation Protocols.

ISO 9001:2008 Certified  
 Mobile: 9389994334, 9554572190, 9453837595



# Panacea Pathology

## Clinical Reference Lab

Persistence, Preparedness and Precision  
 EQAS (CMC Vellore Attached) & IQAS System  
 पूर्वांचल की सर्वोत्तम गुणवत्ता वाली पैथोलॉजी

PATIENT NAME : PINKY SINGH

AGE/GENDER : 32 YRS/FEMALE

REFD BY DR. : ARCO FEMI HEALTHCARE LTD.

RECEIVED DATE : 28-01-2023(10:00AM)

SAMPLE : BLOOD & URINE

REPORT DATE : 28-01-2023(06:00PM)

### PATHOLOGY REPORT

#### LIPID PROFILE, SERUM

TEST	LAB TEST VALUES	NORMAL RANGE
<b>BLOOD CHEMISTRY</b>		
TOTAL CHOLESTEROL (SERUM)	178.0	Desirable:- < 200 mg/dl Borderline:- 200 – 239 mg/dl High:- > 240 mg/dl
TRIGLYCERIDES (SERUM)	145.0	35 – 170 mg/dl
HDL CHOLESTEROL (SERUM)	40.0	35.30 – 79.50 mg/dl
LDL CHOLESTEROL (SERUM)	109.0	< 130 mg/dl
VLDL	229.0	< 40 mg/dl
CHOLESTROL/HDL RATIO	0.22	< 3.0 Low Risk Ratio 3.0 – 5.0 Avg Risk > 5.0 High Risk
LDL/HDL RATIO	0.36	< 3 Ratio

#### BLOOD GROUP

TEST	LAB TEST VALUES
<b>BLOOD GROUP ABO &amp; RH FACTOR</b>	
BLOOD GROUP	"AB"
RH FACTOR	POSITIVE

#### GLYCOSYLATED HEMOGLOBIN (HBA1C)

TEST	LAB TEST VALUES	NORMAL RANGE
HBA1C	5.4	Normal : <5.97 % Good Control : 5.97 – 6.81% Fair Control : 6.81 – 7.65% Poor Control : >7.65%

#### THYROID PROFILE (T3, T4, TSH)

TEST	LAB TEST VALUES	NORMAL RANGE
<b>THYROID FUNCTION TEST</b>		
T3	1.20	0.60 – 1.81 ng/ml
T4	7.42	4.50 – 10.90 ug/dl
TSH	2.20	0.39 – 6.10 uIU/mL

PAGE 2

Lab Technician

**PANACEA HOSPITAL**  
 (A UNIT OF ARCO FEMI HEALTH CARE PVT. L)  
 REG. NO.: AL-1500  
 M.D. Pathology  
 B.M. NAGAR  
 DURGAKUND, VARANASI

Timing : 8.00 a.m. to 9.00 p.m. (Sunday 8.00 a.m. to 3.00 p.m.)

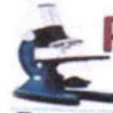This Report is not valid for medico legal purpose

**Note:** These tests have technical limitations. Clinico-pathological interpretation is necessary. In case of any disparity test may be repeated immediately.

Address : 36/44 FK Kabir Nagar, Durgakund, Varanasi – 221005

Email: [dramishra@gmail.com](mailto:dramishra@gmail.com), [drpallaviojha@gmail.com](mailto:drpallaviojha@gmail.com) Website: [panaceahospital.org](http://panaceahospital.org)

Services:  
 Clinical Biomedical & Hematology Investigations  
 including Bone Marrow Examination  
 VPT, Podiascan & Complete Foot Care (First Time in Purvanchal)  
 All Hormonal Investigation by Chemiluminescent Method  
 Visceral Fat by (AB-140) Ambulatory BP Monitoring  
 CGMS & Insulin Pump Available  
 PFT, 2D-ECHO (Color Doppler), Holter, TMT, Cardiac-3 available  
 VIA, VILI, Colposcopy available  
 Special Endocrinological Investigation Protocols.



# Panacea Pathology

## Clinical Reference Lab

Persistence, Preparedness and Precision  
 EQAS (CMC Vellore Attached) & IQAS System  
 पूर्वांचल की सर्वोत्तम गुणवत्ता वाली पैथोलॉजी

PATIENT NAME : PINKY SINGH

AGE/GENDER : 32 YRS/FEMALE

REFD BY DR. : ARCO FEMI HEALTHCARE LTD.

RECEIVED DATE : 28-01-2023(10:00AM)

SAMPLE : BLOOD & URINE

REPORT DATE : 28-01-2023(06:00PM)

## PATHOLOGY REPORT

### LIVER PROFILE TEST, SERUM

TEST	LAB TEST VALUES	NORMAL RANGE
<b>BIO CHEMISTRY</b>		
TOTAL BILIRUBIN	0.70	0.0 – 1.1 mg/dl
DIRECT BILIRUBIN	0.25	0.0 – 0.2 mg/dl
INDIRECT BILIRUBIN	0.45	< 0.90 mg/dl
SGOT (AST)	28.0	0 – 52 mg/dl
SGPT (ALT)	22.0	0 – 39 mg/dl
GGT (GYT)	18.0	< 55 U/L

### URINE ROUTINE EXAMINATION

TEST	LAB TEST VALUES	NORMAL RANGE
<b>PHYSICAL EXAMINATION</b>		
QUANTITY	29	ML
COLOUR	STRAW	PALE YELLOW
APPEARANCE	CLEAR	CLEAR
SPECIFIC GRAVITY	1.005	1.01 – 1.03
PH	6.5	4.7 – 7.5
<b>CHEMICAL EXAMINATION</b>		
GLUCOSE	Not Detected	Not Detected
PROTEIN	NIL	Not Detected
<b>MICROSCOPIC EXAMINATION</b>		
PUS CELLS	1-2	0-5
RBC	Not Detected	Not Detected
EPITHELIAL CELLS	2-3	0-5
CASTS	Not Detected	Not Detected
CRYSTALS	Not Detected	Not Detected
BACTERIA	Not Detected	Not Detected

### RANDOM/FASTING BLOOD SUGAR

TEST	LAB TEST VALUES	NORMAL RANGE
<b>RBS/FBS</b>		
RANDOM BLOOD SUGAR	110.0	125-140 mg/dl
FASTING BLOOD SUGAR	103.0	70-125 mg/dl

----- End of Report -----

Lab Technician

PANACEA HOSPITAL

A UNIT OF AAROHAN HEALTH CARE PVT. LTD.

REG. NO. 1500

M.D. Pathology

B.36/44, B-4, KABIR NAGAR

DURGAKUND, VARANASI

Timing : 8.00 a.m. to 9.00 p.m. (Sunday 8.00 a.m. to 3.00 p.m.)

This Report is not valid for medico legal purpose

**Note:** These tests have technical limitations. Clinico-pathological interpretation is necessary. In case of any disparity test may be repeated immediately.

Address : 36/44 FK Kabir Nagar, Durgakund, Varanasi – 221005

Email: [dramishra@gmail.com](mailto:dramishra@gmail.com), [drpallaviojha@gmail.com](mailto:drpallaviojha@gmail.com) Website: [panaceahospital.org](http://panaceahospital.org)



# PANACEA HOSPITAL

B 36/44 F.K KABIR NAGAR, DURGAKUND  
TOLLFREE NO-18001233070.  
Whatsapp No - 8795832852  
www.piire.org



## OP Slip

Print Date : 28-Jan-2023 10:59AM

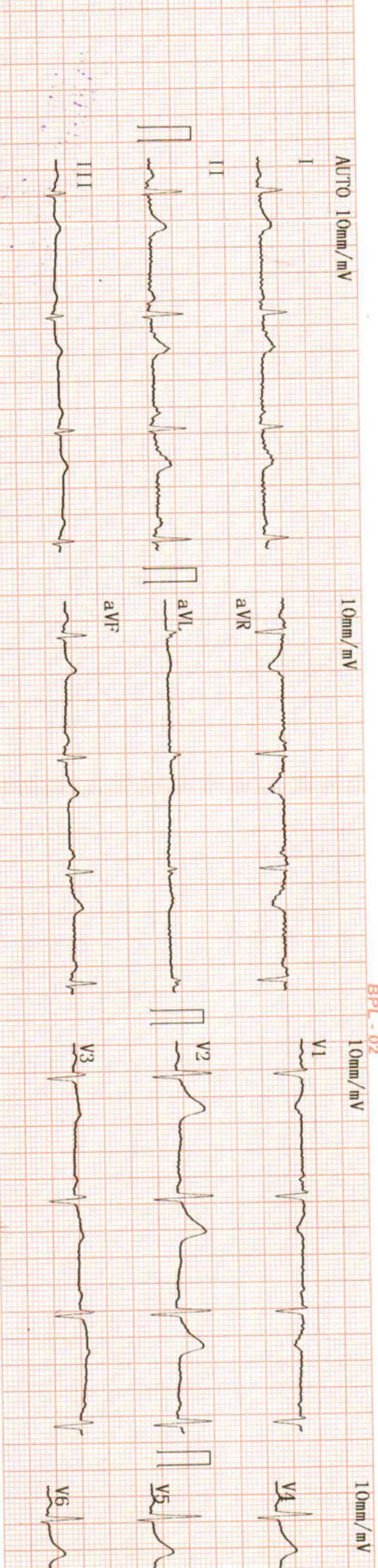


UHID No	:- UD-22230003443	OP No	:- OP-22230012736	OP Date	:- 28 Jan 2023 10:59AM
Patient Name	:- Mrs PINKI SINGH BOB	Age/Sex	:- 32 Y/Female	Mobile No	:- 9598786955
Husband	:- AMIT KUMAR SINGH	Department	:- GYNAECOLOGY		
Pay Type	:- Cash	Consultant	:- Dr VANDANA SINGH (MBBS,MS)		
Token No	:- NOR. - 2	Paid/Bal	:- 0.00 /30.00		
Patient Type	:- Normal				
Address	:- PRYAGRAJ,Allahabad				

BP :- 100/70 Rx  
height :-  
Weight (kg) :- 55  
BMI :-  
SpO2! 99  
PR! 110

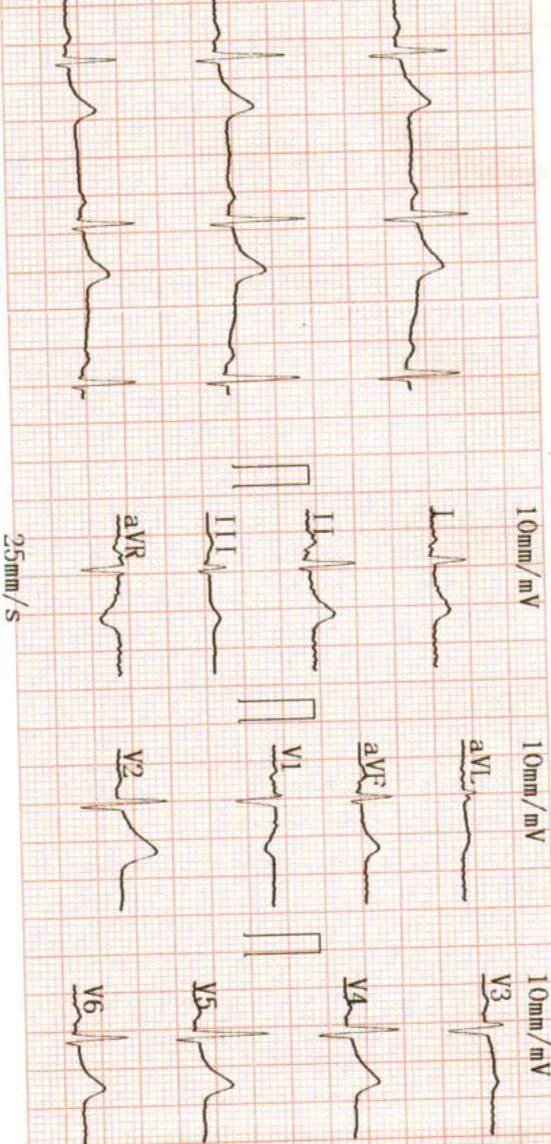
Printed By : Mr NITIN YADAV  
Created By : Mr NITIN YADAV

CARDIAPHI  
25mm/s AC50Hz EMG35Hz



BPL-02

CARDIART



2023-01-28 13:18

BPL-02

ID :  
 Name : **Pinky Singh**  
 Sex :  
 Height :  
 SYS :  
 DIA :  
 HR :  
 PR Interval :  
 P Duration :  
 QRS Duration :  
 T Duration :  
 QT/QTc :  
 P/QRS/T Axis :  
 R(V5)/S(V1) :  
 R(V5)+S(V1) :

Age : **30Y**  
 Weight : kg

<< Conclusions >>

Normal Sinus Rhythm  
 Cardiac electric axis normal.

\*\*Report need physician confirm\*\*

Physician

**DR. PALLAVI MISHRA**  
 MBB.S-MD (GENERAL MEDICINE)  
 MCI Reg. No. 52033



# PANACEA HOSPITAL

*A shelter for many hearts A Home for many lives*

(An ISO 9001:2008 Certified Organisation)

Lab Attached with CMC Vellore Under EQAS Scheme

Name	MRS.PINKI SINGH	Sex /Age	33/F	Date	28/01/2023
Ref. by	Dr.Pallavi Mishra(MD)	BSA - m <sup>2</sup>		Echo window	fair

## Echo - Cardiology


MITRAL VALVE Doppler	AML - normal morphology MV Flow - E - 0.9 A-0.5 E/A=1.77	PML - normal morphology MVA - 3.0 cm <sup>2</sup> Mitral Regurgitation - <b>No</b>
TRICUSPID VALVE Doppler	Normal TV Flow -No	Tricuspid Regurgitation - <b>No</b>
PULMONARY VALVE Doppler	Normal PV Flow -No	Pulmonary Regurgitation - No
AORTIC VALVE Doppler	Trileaflet-No AV Flow - no	Aortic Regurgitation - no
MEASUREMENT	Aorta - 24.0 (20-38) mm IVS ed - 12. (6 -12) mm LVID ed - 36.6 (35 - 55) mm LVPW ed - 12.6 (6 -12) mm OA - 7 (> 5) mm	LA - 24.0 (24-32) mm IVS es -15.4 (6 - 12) mm LVID es - 25.7 (24 - 40) mm LVPW es - 14.8 (6 -12) mm EPSS - 6 (< 9) mm

**CONCLUSION**

All cardiac chamber dimensions are WNL  
 No valvular abnormalities  
 Good LV systolic function present Modified Simpson's method (4C, 2C) (LVEF-58%)  
 No diastolic dysfunction present (E/A = 1.77) by tissue Doppler (E/e'=6.2)  
 No RWMA  
 No pericardial effusion  
 Intact IAS / IV  
 No PAH  
 No intra cardiac mass /thrombus /vegetation

## IMPRESSION

### Normal Echocardiogram

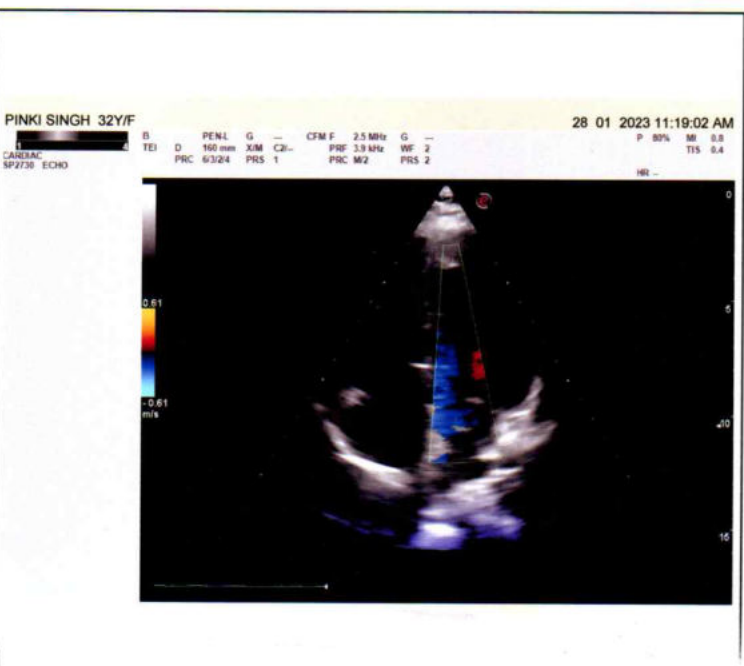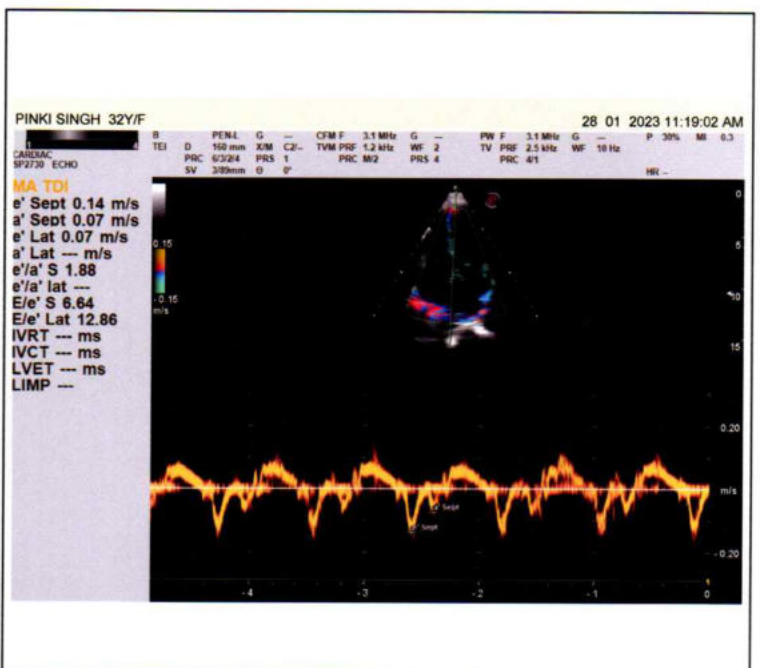
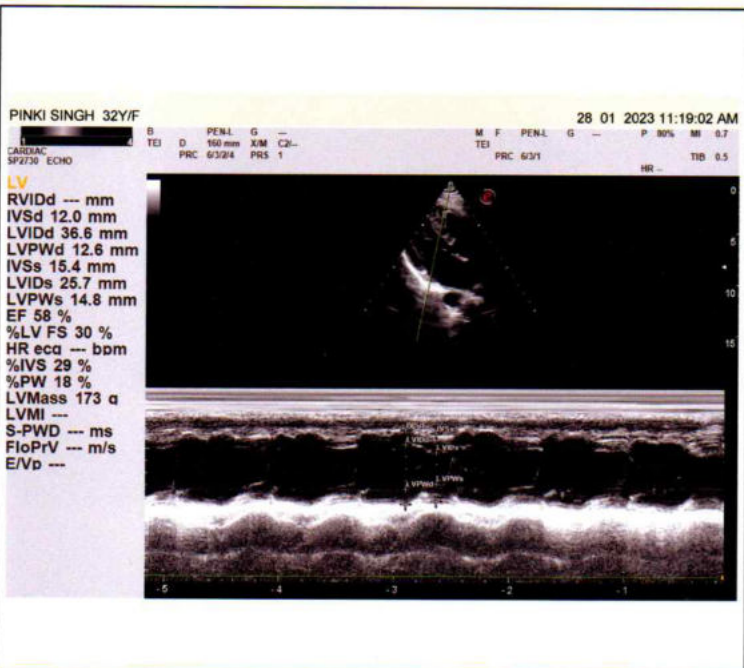
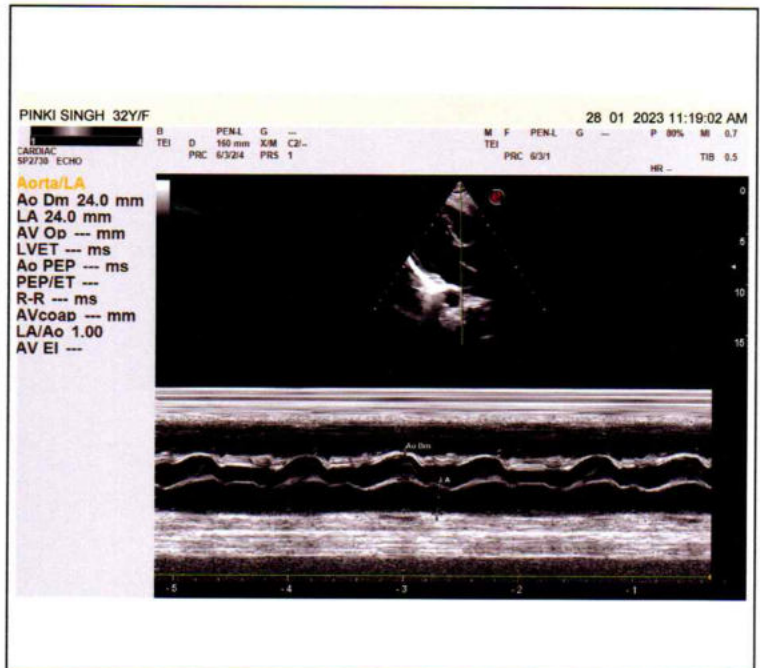
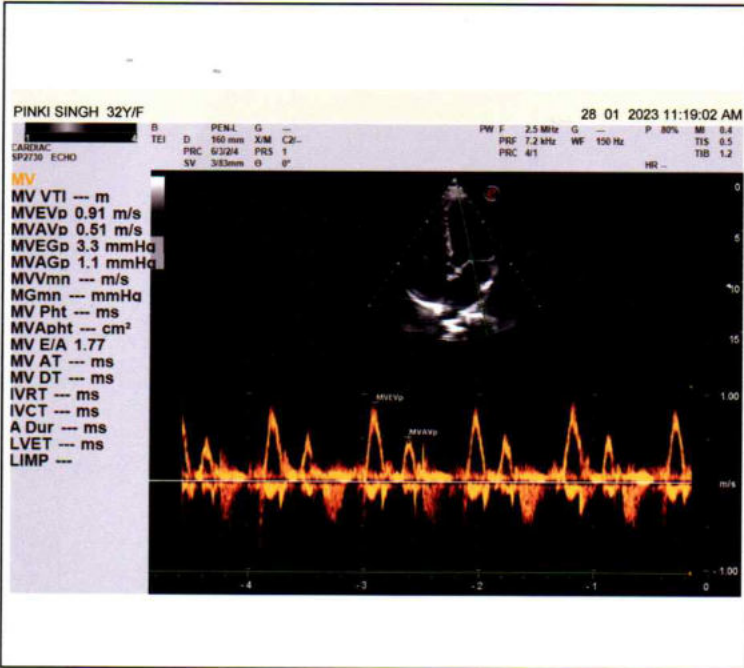
  
 Niraj Mishra  
 Physician Assistant  
 (PIIRE)

  
 Dr. Pallavi Mishra  
 MBBS, MD (MED) Lucknow  
 Echocardiography Specialist, MIAE  
 Non-invasive cardiologist  
 Women Cardiologist  
 Diabetocardiologist

Address : Kabir Nagar (Near Sanjay Shiksha Niketan), Durgakund, Varanasi

Mobile : 9554572190 / 9453837595 / Recpn. 9389994334

E-mail : dramishra@gmail.com, drpallaviojha@gmail.com, Website: www.piire.org







# PANACEA HOSPITAL

*A shelter for many hearts A Home for many lives*

(An ISO 9001:2008 Certified Organisation)

Lab Attached with CMC Vellore Under EQAS Scheme

**NAME:** MRS. PINKI SINGH

**AGE/SEX:** 33 YRS / FEMALE

**REF BY:** DR. ASHUTOSH MISHRA (MD)

**DATE:** 28 /01/2023

## ULTRA SOUND FOR ABDOMEN REPORT

- Liver:** Normal in shape and size(11.6cm) and shows smooth and regular margin.  
No diffuse/focal lesion seen.
- Gall bladder** Contracted.
- CBD** Visualized part normal in course & caliber.
- Pancreas:** Normal in size, shape & echogenicity.  
Margins are smooth & regular.  
No diffuse/ focal lesion seen. Pancreatic tail obscured.
- Spleen:** Normal in size(10.1 cm) shape & echogenicity.  
Margins are smooth & regular. No diffuse / focal lesion seen.  
Splenic vessels at hilum is normal.
- Kidney:** Right kidney: 8.9 X 3.9cm  
Left kidney: 9.5 X 4.0 cm  
Normal cortical echogenicity with well maintained Cortical-medullary differentiation.  
Pelvicalyceal system normal.  
No calculus/mass lesion seen.  
No hydronephrosis/ hydroureter seen.

**Address :** Kabir Nagar (Near Sanjay Shiksha Niketan), Durgakund, Varanasi

**Mobile :** 9554572190 / 9453837595 / Recpn. 9389994334

**E-mail :** dramishra@gmail.com, drpallaviojha@gmail.com, Website: www.piire.org



# PANACEA HOSPITAL

*A shelter for many hearts A Home for many lives*

(An ISO 9001:2008 Certified Organisation)

Lab Attached with CMC Vellore Under EQAS Scheme

- Urinary bladder:** Normally distended, wall thickness is normal.  
No echogenic foci lumen or diverticula seen.  
Both VUJ appears normal.  
No E.R. calculus / mass lesion seen.
- Uterus:** Uterus normal in size shape, & echogenicity.  
Margins are smooth & regular.  
Endometrial thickness within normal limits .
- Ovary:** Right ovary normal in size and shows normal morphology.  
Left ovary normal in size and shows normal morphology.
- Others:** No free fluid in peritoneal cavity.  
No free fluid in bilateral pleural cavity.

**IMPRESSION:**

- NO SIGNIFICANT SONOLOGICAL ABNORMALITY DETECTED.

Please correlate clinically and further investigations.

*Pallavi*  
**DR. PALLAVI MISHRA**  
MBBS,MD (GENERAL MEDICINE)  
SI Reg.No. 52033

**DR. PALLAVI MISHRA**  
MBBS MD(MED) Lucknow

Echocardiography specialist, MIAE  
Non invasive cardiologist  
Women cardiologist

*[Signature]*  
**Radiologist**

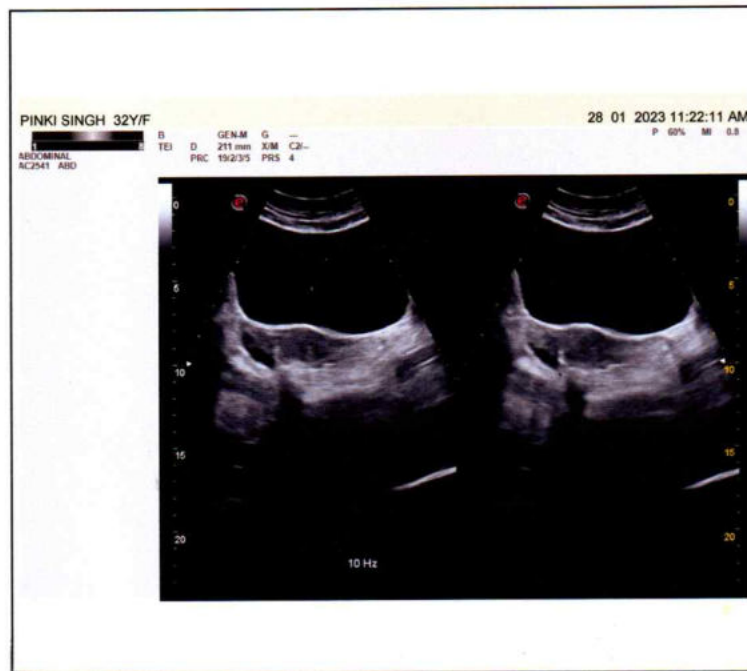
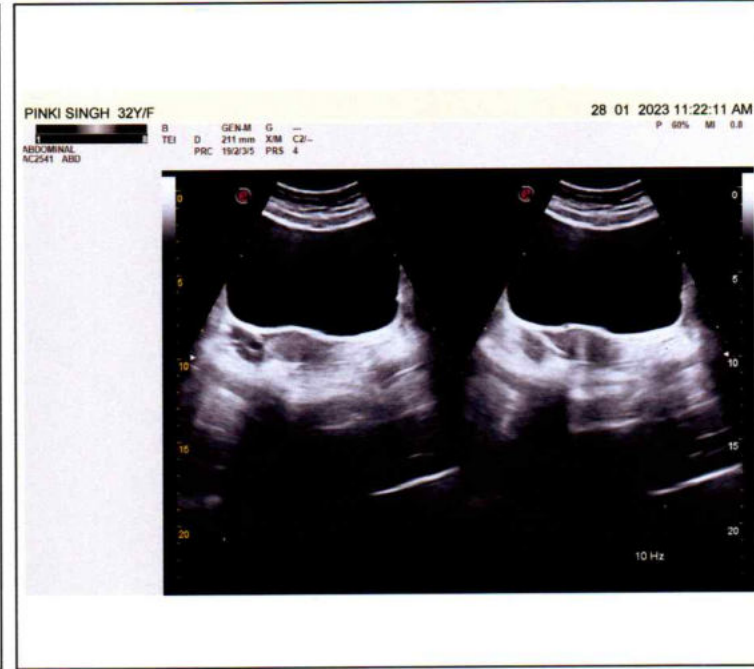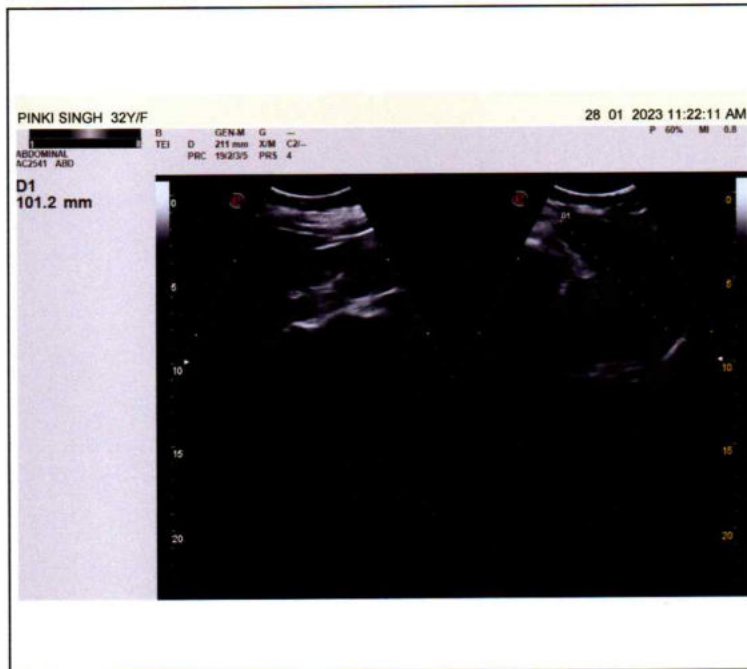
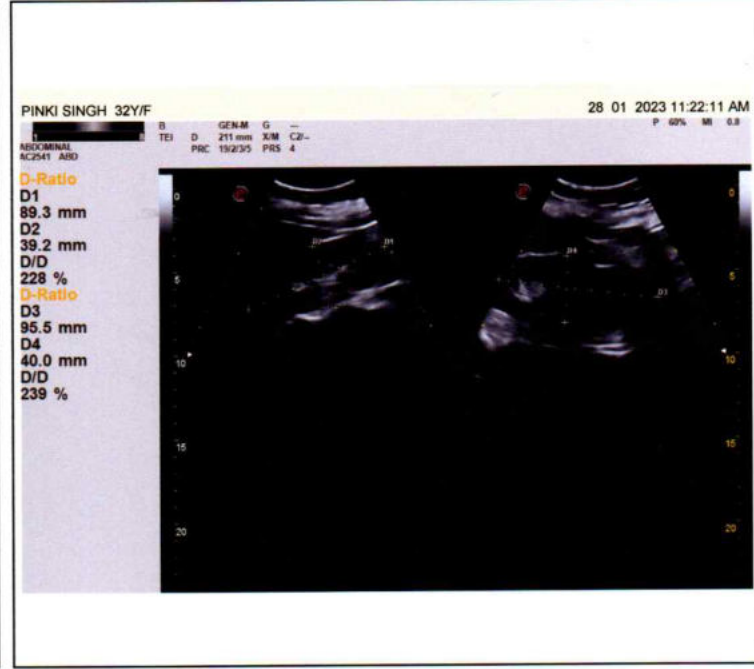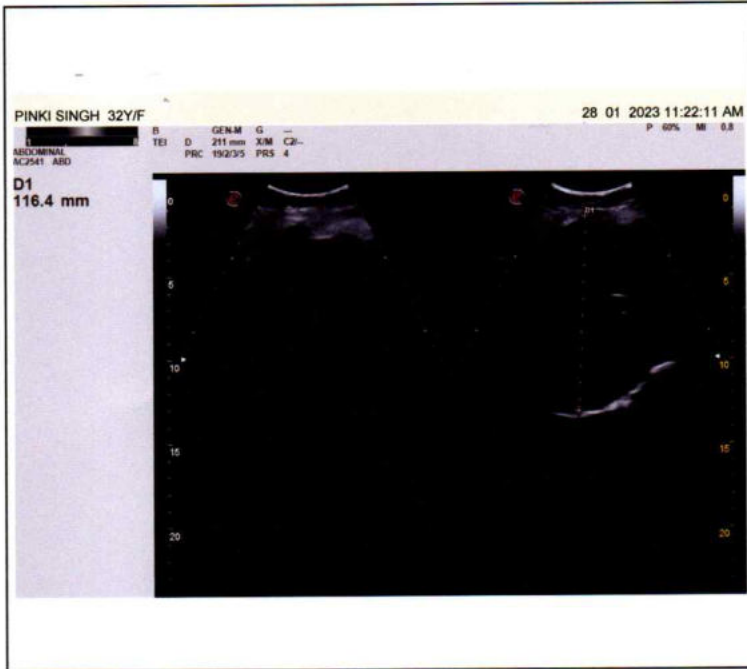
**Dr.Tusharika Rai**  
MBBS MS

- Note: (1) This report is not valid for medico-legal purposes.  
(2) In case of any discrepancy due typing error, please get it Rectified immediately.

**Address : Kabir Nagar (Near Sanjay Shiksha Niketan), Durgakund, Varanasi**

**Mobile : 9554572190 / 9453837595 / Recpn. 9389994334**

**E-mail : dramishra@gmail.com, drpallaviojha@gmail.com, Website: www.piire.org**





# PANACEA HOSPITAL

*A shelter for many hearts A Home for many lives*

(An ISO 9001:2008 Certified Organisation)  
Lab Attached with CMC Vellore Under EQAS Scheme

**NAME:** MRS. PINKI SINGH

**AGE/SEX:** 33 YRS / FEMALE

**REF BY:** DR. ASHUTOSH MISHRA (MD)

**DATE:** 28 /01/2023

## X-RAY CHEST PA

### BOTH LUNG FIELDS AND PLEURAE:

Both lungs show normal bronchovascular pattern.

Right & left hila are normal

No focal mass or calcification is seen

There is no evidence of any fluid in the both the pleural cavities.

Both domes of diaphragms are normal in position.

### MEDIASTINUM:

Trachea is central in position.

Cardiac silhouette is of normal size and configuration.

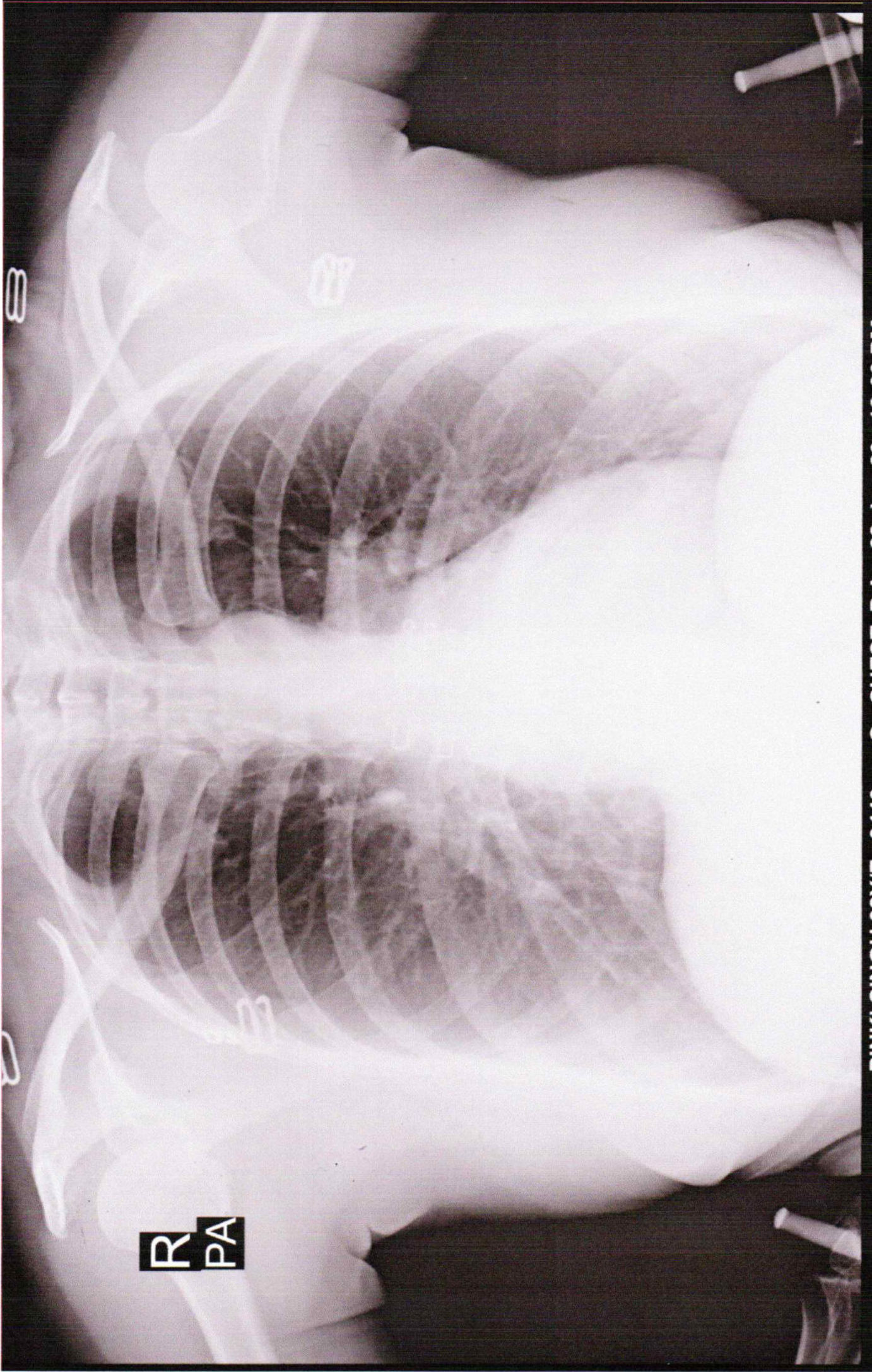
No evidence of pericardial effusion.

No significant lymphadenopathy is seen.

Visualized skeleton is normal.

-----  
NO SIGNIFICANT RADIOGRAPHIC ABNORMALITY.

  
Radiologist



R  
PA

PINKI SINGH 32Y/F 3443 O CHEST P.A. 28-Jan-23 12:00 PM

PANACEA HOSPITAL, KABIR NAGAR, DURGAKUND, VARANASI