



# Park Hospital

GROUP SUPER SPECIALITY HOSPITAL



Paid Amount : 0.00  
Due Amount : 1800.00

Total Amount	:	1800.00
Cancel Amount	:	0.00
Discount Amount	:	0.00
Net Amount	:	1800.00

Cert. No. MC-4830

Cert. No. H-2016-0369

SARITA  
Authorisation Signature

(This is only professional opinion and not the diagnosis, Please correlate clinically)

Q Block South City 11, Sohna Road, Main Sector-47, Gurgaon, Haryana  
Ph.: 0124-4900000 (100 Lines) Fax : 0124-2218733 E-mail : parkmedicenters@gmail.com

**PARK GROUP OF HOSPITALS** : West Delhi • South Delhi • Gurgaon • Karnal • Panipat • Hodal • Ambala • Behror

the **health** care providers

the **health** care providers



LETTER OF APPROVAL / RECOMMENDATION

To,

The Coordinator,  
Mediwheel (Arcofemi Healthcare Limited)  
Helpline number: 011- 41195959

Dear Sir / Madam,

**Sub: Annual Health Checkup for the employees of Bank of Baroda**

This is to inform you that the following employee wishes to avail the facility of Cashless Annual Health Checkup provided by you in terms of our agreement.

PARTICULARS	EMPLOYEE DETAILS
NAME	MS. KOMAL
EC NO.	183056
DESIGNATION	SINGLE WINDOW OPERATOR A
PLACE OF WORK	PANT NAGAR, SIDCUL
BIRTHDATE	26-01-1997
PROPOSED DATE OF HEALTH CHECKUP	01-08-2021
BOOKING REFERENCE NO.	21S183056100001792E

This letter of approval / recommendation is valid if submitted along with copy of the Bank of Baroda employee id card. This approval is valid from **31-07-2021** till **31-03-2022** The list of medical tests to be conducted is provided in the annexure to this letter. Please note that the said health checkup is a **cashless facility** as per our tie up arrangement. We request you to attend to the health checkup requirement of our employee and accord your top priority and best resources in this regard. The EC Number and the booking reference number as given in the above table shall be mentioned in the invoice, invariably.

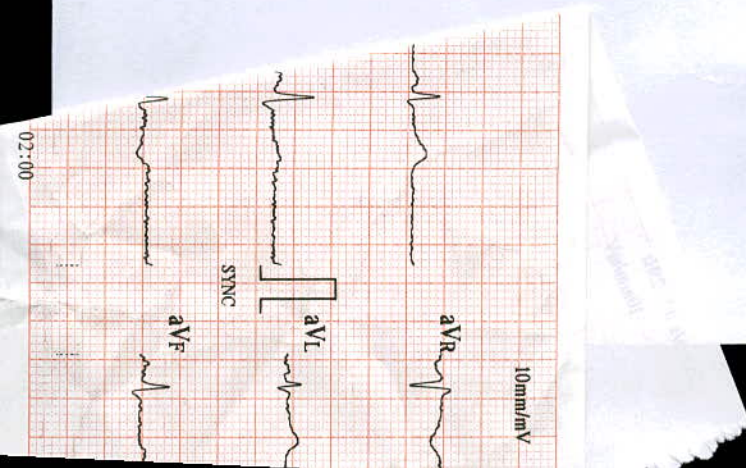
We solicit your co-operation in this regard.

Yours faithfully,

Sd/-

**Chief General Manager**  
**HRM Department**  
**Bank of Baroda**

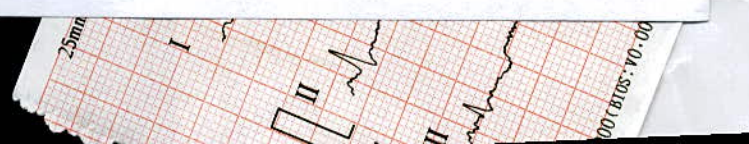
(Note: This is a computer generated letter. No Signature required. For any clarification, please contact Mediwheel (Arcofemi Healthcare Limited))







**SUGGESTIVE LIST OF MEDICAL TESTS**

<b>FOR MALE</b>	<b>FOR FEMALE</b>
CBC	CBC
ESR	ESR
Blood Group & RH Factor	Blood Group & RH Factor
Blood and Urine Sugar Fasting	Blood and Urine Sugar Fasting
Blood and Urine Sugar PP	Blood and Urine Sugar PP
Stool Routine	Stool Routine
<b>Lipid Profile</b>	<b>Lipid Profile</b>
Total Cholesterol	Total Cholesterol
HDL	HDL
LDL	LDL
VLDL	VLDL
Triglycerides	Triglycerides
HDL / LDL ratio	HDL / LDL ratio
<b>Liver Profile</b>	<b>Liver Profile</b>
AST	AST
ALT	ALT
GGT	GGT
Bilirubin (total, direct, indirect)	Bilirubin (total, direct, indirect)
ALP	ALP
Proteins (T, Albumin, Globulin)	Proteins (T, Albumin, Globulin)
<b>Kidney Profile</b>	<b>Kidney Profile</b>
Serum creatinine	Serum creatinine
Blood Urea Nitrogen	Blood Urea Nitrogen
Uric Acid	Uric Acid
HBA1C	HBA1C
Routine urine analysis	Routine urine analysis
USG Whole Abdomen	USG Whole Abdomen
<b>General Tests</b>	<b>General Tests</b>
X Ray Chest	X Ray Chest
ECG	ECG
2D/3D ECHO / TMT	2D/3D ECHO / TMT
Stress Test	Thyroid Profile (T3, T4, TSH)
PSA Male (above 40 years)	Mammography (above 40 years) and Pap Smear (above 30 years).
Thyroid Profile (T3, T4, TSH)	Dental Check-up consultation
Dental Check-up consultation	Physician Consultation
Physician Consultation	Eye Check-up consultation
Eye Check-up consultation	Skin/ENT consultation
Skin/ENT consultation	Gynaec Consultation






 भारत सरकार  
GOVERNMENT OF INDIA




कोमल  
Komal  
जन्म तिथि/ DOB: 26/01/1997  
महिला / FEMALE



9737 6503 0478

आधार-मेरा आधार, मेरी पहचान


 AADHAAR


भारतीय विशिष्ट पहचान प्राधिकरण  
UNIQUE IDENTIFICATION AUTHORITY OF INDIA

पता:-  
आत्मजा/चरण सिंह,  
गोविंदपुर, मरगूबपुर  
दीदाहेरी, हरिद्वार,  
उत्तराखंड - 247667

Address:  
D/O: Charan Singh, Govindpur,  
Margoobpur Deedaheri,  
Haridwar,  
Uttarakhand - 247667

9737 6503 0478

 1947  
1800 300 1947

 help@uidai.gov.in





NAME	: MRS. KOMAL	DATE	: 12/3/22
Age Sex	: 25Years / Female	Inpatient No	:
PERFORMED BY	: Dr. ELA MADAAN	UHID	: 797348

## TRANS THORACIC ECHO CARDIOGRAPHY REPORT

### MITRAL VALVE

**Morphology** AML: Normal / Thickening / Calcification / Flutter / Vegetation / Non significant Prolapse / SAM  
PML: Normal / Thickening / Calcification / Prolapse / Paradoxical Motion / Fixed.  
Subvalvular deformity: Present / Absent

**Doppler** Normal / Abnormal  
Mitral Stenosis Present / Absent  
Mitral Regurgitation; Absent / Normal / Mild / Trace / Moderate / Severe.

### TRICUSPID VALVE

**Morphology** Normal / Atresia / Thickening / Calcification / Prolapse / Vegetation / Doming.  
**Doppler** Normal / Abnormal  
Tricuspid Stenosis: Present / Absent.  
Tricuspid Regurgitation; Absent / Normal / Mild / Trace / Moderate / Severe.

### PULMONARY VALVE

**Morphology** Normal / Atresia / Thickening / Calcified / Doming / Vegetation.  
**Doppler** Normal / Abnormal.  
Pulmonary stenosis : Present / Absent  
Pulmonary regurgitation : Present / Absent

### AORTIC VALVE

**Morphology** Normal / Thickened / Mildly / Calcified / Flutter / Vegetation / Restricted / Opening  
No. of Cusps 1 / 2 / 3 / 4  
**Doppler** Normal / Abnormal  
Aortic Stenosis : Present / Absent  
Aortic regurgitation : Present / Absent / Mild / Trace

(This is only professional opinion and not the diagnosis. Please correlate clinically.)

Q Block South City 11, Sohna Road, Main Sector-47, Gurgaon, Haryana  
Ph.: 0124-4900000 (100 Lines) Fax : 0124-2218733 E-mail : parkmedicenters@gmail.com

**PARK GROUP OF HOSPITALS : SOUTH DELHI • WEST DELHI • GURUGRAMA • FARIDABAD • PANIPAT • SONIPAT**





<u>Measurements</u>	<u>Normal Values</u>	<u>Measurements</u>	<u>Normal Value</u>
IVSD : 0.9cm	(0.6-1.1cm))	LA : 3.8cm	(1.9-4.0cm)
LVID : 3.4cm	(3.7-5.6cm)	LVOT : 1.4cm	
LVPW : 0.8cm	(0.6-1.1cm)	AORTA : 2.3cm	(2.0-3.7cm)
EF : 60%	(55% - 80%)	IVSmotion :	<b>Normal / Flat / Paradoxical</b>

Any Other

### CHAMBERS:-

LV **Normal** / Enlarged / **Clear** / Thrombus /

Contraction Normal LV shows concentric LVH, no gradient across LVOT /Inetic / Intra capillary  
Regional wall motion abnormality: **Absent**/ Present

LA **Normal** / Enlarged / Clear / Thrombus / Myxoma; **LAA: Clear** / Thrombus

RA **Normal** / **Clear** / Thrombus, Dilated.

RV **Normal** / Enlarged / **Clear** / Thrombus / Hypertrophied/ Dilated.

PERICARDIUM **Normal** / Thickening / Calcification / Effusion.

### COMMENTS & SUMMARY:-

- All cardiac chambers dimensions are with in normal limits.
- Global LVEF 60%
- No RWMA(regional wall motion abnormality at rest)
- NORMAL LV FUNCTION
- NO MR / NO MS
- NO AR / NO AR
- TRACE TR
- GOOD RV FUNCTION
- IAS/IVS. No Flow seen across IAS/IVS.
- No Thrombus/Mass in any chamber.
- No Pericardial Effusion.

Please correlate clinically

Dr. Ela Madaan  
MBBS, PGDCC  
Fellowship in Non Invasive  
Cardiology

Dr. BINAY KUMAR  
M.D.(Medicine) D.M (Cardiology).  
Interventional cardiology.

(This is only professional opinion and not the diagnosis. Please correlate clinically.)

Q Block South City 11, Sohna Road, Main Sector-47, Gurgaon, Haryana  
Ph.: 0124-4900000 (100 Lines) Fax : 0124-2218733 E-mail : parkmedicenters@gmail.com

PARK GROUP OF HOSPITALS : SOUTH DELHI • WEST DELHI • GURUGRAMA • FARIDABAD • PANIPAT • SONIPAT





				Pateint Type - OPD	
Patient Name	:	Mrs.KOMAL	IP/OP No	:	
Age/ Sex	:	25 Years Female	Req No	:	797348
Unit name	:	RMO	Report Date/Time	:	12/03/2022
Consultant Nm	:	RMO	Patient's Phone	:	
Reqdt/Reqtm	:	12/03/2022	Payer Name	:	MEDIWHEEL PVT LTD

X-RAY TEST REPORT

**X-RAY CHEST P.A. VIEW**

The lungs on the either side show equal translucency.

No focal lung lesion is seen.

The pleural spaces are normal.

Both hila are normal in size, have equal density and bear normal relationship.

The heart and trachea are central in position and no mediastinal abnormality is visible.

The cardiac size is normal for patient age and view.

The domes of the diaphragms are normal in position, and show smooth outline.

**IMPRESSION : NORMAL STUDY.**

**To be correlated clinically**

DR. SAKET RUPRAMKA  
MBBS, MD  
CONSULTANT RADIOLOGIST

DR. MANJEET SEHRAWAT  
MBBS, MD, PDCC  
CONSULTANT RADIOLOGIST

DR. BINOD CHOUDHARY  
MBBS, MD  
CONSULTANT RADIOLOGIST

DR. ANSHU SHARMA  
MBBS, MD  
CONSULTANT RADIOLOGIST

*(This is only professional opinion and not the diagnosis. Please correlate clinically.)*

**Gurgaon** : Q Block, South City-II, Sohna Road, Sector - 47, Gurugram-122002, (Haryana)  
**Faridabad** : J-Block, Sector - 10, Near Court, Faridabad - 121004, (Haryana)

• Helpline : 0124-4900000  
• Helpline : 0129-4200000





UHID Number :	Date Of Requestion :	12/03/2022	10:35AM
Requisition No. : 797348	IP No :	Date of Collection :	12-MAR-22 11:32AM
Name : Mrs.KOMAL	Sample Receiving Date :	12-MAR-22	
Age / Gender : 25 Years Female	Reporting Date :	12-Mar-2022	01:42PM
Referred By : RMO	Payer Name :	MEDIWHEEL PVT LTD	
Station : Direct	Ward :		

**LAB SERVICES - HAEMATOLOGY  
TEST REPORT**

**LFT (LIVER FUNCTION TEST)**

Specimen Test	Results	Units	Reference Interval	Method
BILIRUBIN TOTAL	0.9	mg/dl	0 -- 1.2	Diazotized Sulphanilic Acid
BILIRUBIN DIRECT	0.4	mg/dl	0 -- 0.3	Diazotized Sulphanilic Acid
BILIRUBIN INDIRECT	0.5	mg/dl	0 -- 0.9	Diazotized Sulphanilic Acid
SGOT	16	IU/L	5 -- 35	IFCC WPP
SGPT	16	IU/L	5 -- 40	IFCC WPP
Alkaline Phosphatase	117	IU/L	35 -- 135	IFCC Kinetic IFCC Kinetic
Total Protein	6.5	g/dL	6.0 -- 8.3	Biuret Diazotized
ALBUMIN	3.5	g/dl	3.2 -- 5.0	Photometric Coloumn Test
GLOBULIN	3.0	gm/dl	1.5 -- 3.6	Calculated
A/G Ratio	1.1		0.9 -- 2	Calculated IFCC

-----End of Report-----

Dr.Sneha Panwar Pathologist	Dr.Krishna Veni MD Pathologist	Dr.Nikita Agrawal MD Pathologist	Dr.Sonia kumari MD Pathologist	Dr. PRADIP KUMAR Microbiologist	Dr. Kriti Microbiologist
--------------------------------	-----------------------------------	-------------------------------------	-----------------------------------	------------------------------------	-----------------------------

(This is only professional opinion and not the diagnosis, Please correlate clinically) Lab Tech.

Q Block South City 11, Sohna Road, Main Sector-47, Gurgaon, Haryana  
Ph.: 0124-4900000 (100 Lines) Fax : 0124-2218733 E-mail : parkmedicenters@gmail.com

**PARK GROUP OF HOSPITALS : West Delhi • South Delhi • Gurgaon • Karnal • Panipat • Hodal • Ambala • Behror**





UHID Number :	Date Of Requestion :	12/03/2022	10:35AM
Requisition No. : 797348	IP No :	Date of Collection :	12-MAR-22 11:32AM
Name : Mrs.KOMAL	Sample Receiving Date :	12-MAR-22	
Age / Gender : 25 Years Female	Reporting Date :	12-Mar-2022	01:42PM
Referred By : RMO	Payer Name :	MEDIWHEEL PVT LTD	
Station : Direct	Ward :		

**LAB SERVICES - BIOCHEMISTRY  
TEST REPORT**

KFT (RENAL PROFILE)

Specimen Test	Results	Units	Reference Interval	Method
BLOOD UREA	21	mg/dl	13 -- 45	Urease GLDH
Creatinine.	0.7	mg/dl	0.6 -- 1.4	Modified JAFFEs
SERUM URIC ACID	4.6	mg/dl	3.6 -- 7.2	Uricase
SERUM SODIUM	136	mmol/Lt	135 -- 155	Electrolyte Analyzer
S.POTASSIUM	4.4	mmol/Lt	3.4 -- 5.6	ISE Ectrolyte Analyzer
S. CALCIUM	8.7	mg/dl	8.4 -- 10.4	Arsenazo III -End Point
PHOSPHORUS	4.0	mg/dl	2.5 -- 4.5	Ammonium Molybdate

-----End of Report-----

Dr.Sneha Panwar Pathologist	Dr.Krishna Veni MD Pathologist	Dr.Nikita Agrawal MD Pathologist	Dr.Sonia kumari MD Pathologist	Dr. PRADIP KUMAR Microbiologist	Dr. Kriti Microbiologist
--------------------------------	-----------------------------------	-------------------------------------	-----------------------------------	------------------------------------	-----------------------------

(This is only professional opinion and not the diagnosis, Please correlate clinically) Lab Tech.  
 Q Block South City 11, Sohna Road, Main Sector-47, Gurgaon, Haryana  
 Ph.: 0124-4900000 (100 Lines) Fax : 0124-2218733 E-mail : parkmedicenters@gmail.com

PARK GROUP OF HOSPITALS :West Delhi • South Delhi • Gurgaon • Karnal • Panipat • Hodal • Ambala • Behror





UHID Number	:	Date Of Requestion	:	12/03/2022	10:35AM
Requisition No.	: 797348	IP No	:	Date of Collection	: 12-MAR-22 11:32AM
Name	: Mrs.KOMAL	Sample Receiving Date	:	12-MAR-22	
Age / Gender	: 25 Years Female	Reporting Date	:	12-Mar-2022	01:44PM
Referred By	: RMO	Payer Name	:	MEDIWHEEL PVT LTD	
Station	: Direct	Ward	:		

**LAB SERVICES - BIOCHEMISTRY  
TEST REPORT**

**LIPID PROFILE**

Specimen Test	Results	Units	Reference Interval	Method
CHOLESTROL	200	mg/dl	60 -- 220	Trinders Method end Method
TRIGLYCERIDES	146	mg/dl	60 -- 165	GPO Trinder
HDL-CHOL.	64	mg/dl	35 -- 70	Homogeneous
VLDL-CHOL	29	mg/dl	10 -- 40	Calculated
LDL - CHOLESTEROL	107	mg/dl	-- < 130	
L.D.L / H.D.L. Ratio	1.6		--	calculated
Total Cholesterol/HDL Ratio	3.1		0 -- 4.5	Calculated

-----End of Report-----

Dr.Sneha Panwar Pathologist      Dr.Krishna Veni MD Pathologist      Dr.Nikita Agrawal MD Pathologist      Dr.Sonia kumari MD Pathologist      Dr. PRADIP KUMAR Microbiologist      Dr. Kriti Microbiologist

(This is only professional opinion and not the diagnosis, Please correlate clinically) Lab Tech.

Q Block South City 11, Sohna Road, Main Sector-47, Gurgaon, Haryana  
Ph.: 0124-4900000 (100 Lines) Fax : 0124-2218733 E-mail : parkmedicenters@gmail.com

PARK GROUP OF HOSPITALS : West Delhi • South Delhi • Gurgaon • Karnal • Panipat • Hodal • Ambala • Behror





UHID Number	:	Date Of Requisition	:	12/03/2022	10:35AM
Requisition No.	: 797348	IP No	:	Date of Collection	: 12-MAR-22 11:32AM
Name	: Mrs.KOMAL	Sample Receiving Date	:	12-MAR-22	
Age / Gender	: 25 Years Female	Reporting Date	:	12-Mar-2022 01:41PM	
Referred By	: RMO	Payer Name	:	MEDIWHEEL PVT LTD	
Station	: Direct	Ward	:		

**LAB SERVICES - HAEMATOLOGY  
TEST REPORT**

Specimen Test	Results	Units	Reference Interval	Method
CBC				
HB	10.7	gm/dl	11.5 -- 17	Colorimetry
TLC.	6700	cell/cumm	4000 -- 11000	Electrical Impedance
NEUTROPHILS	69	%	40 -- 75	Flow Cytometry
LYMPHOCYTES	22	%	20 -- 45	Flow Cytometry
MONOCYTES	06	%	2 -- 10	Flow Cytometry
EOSINOPHIL	03	%	1 -- 4	Flow Cytometry
BASOPHIL	00	%	0 -- 1	Electrical Impedance
TOTAL RBC COUNT	4.0	Millions/cumm	3.5 -- 5.5	Electrical Impedance
PCV	36.0	%	36 -- 46	Calculated
MCV	89.0	fl	76 -- 96	Measured
MCH	26.5	pg	27 -- 32	Calculated
MCHC	29.7	gm/dl	30 -- 36	Calculated
RDW	13.1	%	11 -- 14	Calculated
PLATELET COUNT	173	1000/cumm	150 -- 450	Electrical Impedance

-----End of Report-----

Dr.Sneha Panwar Pathologist	Dr.Krishna Veni MD Pathologist	Dr.Nikita Agrawal MD Pathologist	Dr.Sonia kumari MD Pathologist	Dr. PRADIP KUMAR Microbiologist	Dr. Kriti Microbiologist
--------------------------------	-----------------------------------	-------------------------------------	-----------------------------------	------------------------------------	-----------------------------

(This is only professional opinion and not the diagnosis, Please correlate clinically) Lab Tech.

Q Block South City 11, Sohna Road, Main Sector-47, Gurgaon, Haryana  
Ph.: 0124-4900000 (100 Lines) Fax : 0124-2218733 E-mail : parkmedicenters@gmail.com

**PARK GROUP OF HOSPITALS : West Delhi • South Delhi • Gurgaon • Karnal • Panipat • Hodal • Ambala • Behror**





Cert. No. MC - 4830



Cert. No. H-2016-0369

UHID No :  
 Requisition No. : 797348  
 Patient Name : Mrs.KOMAL  
 Age : 25 Years / Female  
 Requisition Type : OPD  
 Doctor Name : RMO

Requestion Date : 12/03/2022  
 Sample Date : 12/03/2022 11:32 AM  
 Sample Receiving : 12/03/2022 11:32 AM  
 Report Date : 12/03/2022 06:25 PM  
 IP Bill No./Bed No. :  
 Ref.By/Company : MEDIWHEEL PVT LTD  
 Floor Name :

INVESTIGATION

RESULTS

REF.RANGE / UNITS

Specimen Type :-Urine

**URINE ROUTINE AND MICROSCOPY**

Method:- Chemical Examination is perfomes by Regent Strip

PHYSICAL CHARACTERSTICS

Quantity	30ml	
Colour	Pale yellow	Pale Yellow
Turbidity	Clear	
Specific gravity	1.025	1.003--1.030
PH	6.5	4.7---7.0

CHEMICAL EXAMINATION

Urobilnogen	Normal	Normal
Protein	NIL	Nil
Blood	NIL	Nil
Ketone	NIL	Nil
Bilirubin	NIL	
Glucose	Nil	Nil

MICRO.EXAMINATION

Pus Cells	2-3	/HPF	0--3
RBC	NIL	/HPF	NIL
Epithelial cells	2-3	/HPF	0---5
Cast	NIL		Nil
Crystals	Nil		Nil

OTHERS

Dr.Nikita Agrwal  
 Pathologist

-----End Of Report-----

Dr.Pradip Kumar  
 Microbiologist

(This is only professional opinion and not the diagnosis, Please correlate clinically)

Q Block South City 11, Sohna Road, Main Sector-47, Gurgaon, Haryana

Ph.: 0124-4900000 (100 Lines) Fax : 0124-2218733 E-mail : parkmedicenters@gmail.com

PARK GROUP OF HOSPITALS : West Delhi • South Delhi • Gurgaon • Karnal • Panipat • Hodal • Ambala • Behror





Cert. No. MC - 4830



Cert. No. H-2016-0369

UHID Number :	Date Of Requestion :	12/03/2022	10:35AM
Requisition No. : 797348	IP No :	Date of Collection :	12-MAR-22 11:32AM
Name : Mrs.KOMAL	Sample Receiving Date :	12-MAR-22	
Age / Gender : 25 Years Female	Reporting Date :	12-Mar-2022	01:43PM
Referred By : RMO	Payer Name :	MEDIWHEEL PVT LTD	
Station : Direct	Ward :		

**LAB SERVICES - HAEMATOLOGY  
TEST REPORT**

ESR (WESTERGREN)

Specimen Test	Results	Units	Reference Interval	Method
BLOOD GROUP ABO Rh	"B"POSITIVE		--	
ESR	28	mm/hr	0 -- 12	Westergren

-----End of Report-----

Dr.Sneha Panwar Pathologist	Dr.Krishna Veni MD Pathologist	Dr.Nikita Agrawal MD Pathologist	Dr.Sonia kumari MD Pathologist	Dr. PRADIP KUMAR Microbiologist	Dr. Kriti Microbiologist
--------------------------------	-----------------------------------	-------------------------------------	-----------------------------------	------------------------------------	-----------------------------

H= High L=Low P=Panic

Page 1 of 1

MOHIT

Lab Tech.

(This is only professional opinion and not the diagnosis, Please correlate clinically)

Q Block South City 11, Sohna Road, Main Sector-47, Gurgaon, Haryana

Ph.: 0124-4900000 (100 Lines) Fax : 0124-2218733 E-mail : parkmedicenters@gmail.com

**PARK GROUP OF HOSPITALS : West Delhi • South Delhi • Gurgaon • Karnal • Panipat • Hodal • Ambala • Behror**

the **health** care providers

the **health** care providers





UHID Number :	Date Of Requestion :	12/03/2022	10:35AM
Requisition No. : 797348	IP No :	Date of Collection :	12-MAR-22 11:32AM
Name : Mrs.KOMAL	Sample Receiving Date :	12-MAR-22	
Age / Gender : 25 Years Female	Reporting Date :	12-Mar-2022 05:15PM	
Referred By : RMO	Payer Name :	MEDIWHEEL PVT LTD	
Station : Direct	Ward :		

**LAB SERVICES - SEROLOGY IMMUNOLOGY  
TEST REPORT**

THYROID PROFILIE

Specimen Test	Results	Units	Reference Interval	Method
TSH	2.32	uIU/mL	0.35 -- 5.5	CLIA
T4	8.9	ug/dl	5.01 -- 12.45	CLIA
T3	1.28	ng/ml	0.60 -- 1.81	CLIA

-----End of Report-----

Dr.Sneha Panwar Pathologist    Dr.Krishna Veni MD Pathologist    Dr.Nikita Agrawal MD Pathologist    Dr.Sonia kumari MD Pathologist    Dr. PRADIP KUMAR Microbiologist    Dr. Kriti Microbiologist





UHID Number :	Date Of Requestion :	12/03/2022	10:35AM
Requisition No. : 797348	IP No :	Date of Collection :	12-MAR-22 11:32AM
Name : Mrs.KOMAL	Sample Receiving Date :	12-MAR-22	
Age / Gender : 25 Years Female	Reporting Date :	12-Mar-2022	04:38PM
Referred By : RMO	Payer Name :	MEDIWHEEL PVT LTD	
Station : Direct	Ward :		

**LAB SERVICES - BIOCHEMISTRY  
TEST REPORT**

BLOOD SUGAR 2 HR. PP

**Specimen**

Test	Results	Units	Reference Interval	Method
BLOOD SUGAR 2 HR. PP	111	mg/dl	80 -- 140	GOD-POD

-----End of Report-----

Dr.Sneha Panwar Pathologist	Dr.Krishna Veni MD Pathologist	Dr.Nikita Agrawal MD Pathologist	Dr.Sonia kumari MD Pathologist	Dr. PRADIP KUMAR Microbiologist	Dr. Kriti Microbiologist
--------------------------------	-----------------------------------	-------------------------------------	-----------------------------------	------------------------------------	-----------------------------

(This is only professional opinion and not the diagnosis, Please correlate clinically)

Lab Tech.

Q Block South City 11, Sohna Road, Main Sector-47, Gurgaon, Haryana  
Ph.: 0124-4900000 (100 Lines) Fax : 0124-2218733 E-mail : parkmedicenters@gmail.com

**PARK GROUP OF HOSPITALS : West Delhi • South Delhi • Gurgaon • Karnal • Panipat • Hodal • Ambala • Behror**





UHID No :  
 Requisition No. : 797348  
 Patient Name : Mrs.KOMAL  
 Age : 25 Years / Female  
 Requisition Type : OPD  
 Doctor Name : RMO

Requestion Date : 12/03/2022  
 Sample Date : 12/03/2022 11:32 AM  
 Sample Receiving : 12/03/2022 11:32 AM  
 Report Date : 12/03/2022 06:28 PM  
 IP Bill No./Bed No. :  
 Ref.By/Company : MEDIWHEEL PVT LTD  
 Floor Name :

INVESTIGATION

RESULTS

REF.RANGE / UNITS

STOOL ROUTINE & MICROSCOPY

PHYSICAL EXAMINATION

COLOUR : BROWNISH  
 CONSISTENCY : SEMI SOLID  
 BLOOD : ABSENT  
 MUCUS : ABSENT

CHEMICAL EXAMINATION

REACTION : ALKALINE

MICROSCOPIC EXAMINATION

PUS CELLS : 1-2 /HPF  
 RBCs : NIL /HPF  
 OVA : NIL  
 CYST : NIL  
 OTHERS : NIL

Method- Chemical Examination done by Littmus Paper

.....End Of Reort.....

Dr.Nikita Agrwal  
 Pathologist

Dr.Pradip kumar  
 Microbiologist

Dr.jatin rao  
 Microbiologist

(This is only professional opinion and not the diagnosis, Please correlate clinically)

Q Block South City 11, Sohna Road, Main Sector-47, Gurgaon, Haryana

Ph.: 0124-4900000 (100 Lines) Fax : 0124-2218733 E-mail : parkmedicenters@gmail.com

PARK GROUP OF HOSPITALS : West Delhi • South Delhi • Gurgaon • Karnal • Panipat • Hodal • Ambala • Behror





UHID Number	:		Date Of Requestion	:	12/03/2022	10:35AM
Requisition No.	:	797348	IP No	:		
Name	:	Mrs.KOMAL	Date of Collection	:	12-MAR-22	11:32AM
Age / Gender	:	25 Years Female	Sample Receiving Date	:	12-MAR-22	
Referred By	:	RMO	Reporting Date	:	12-Mar-2022	01:43PM
Station	:	Direct	Payer Name	:	MEDIWHEEL PVT LTD	
			Ward	:		

**LAB SERVICES - BIOCHEMISTRY  
TEST REPORT**

BLOOD SUGAR FASTING				
Specimen Test	Results	Units	Reference Interval	Method
BLOOD SUGAR FASTING	83	mg/dl	70 -- 110	GOD-POD

-----End of Report-----

Dr.Sneha Panwar Pathologist	Dr.Krishna Veni MD Pathologist	Dr.Nikita Agrawal MD Pathologist	Dr.Sonia kumari MD Pathologist	Dr. PRADIP KUMAR Microbiologist	Dr. Kriti Microbiologist
--------------------------------	-----------------------------------	-------------------------------------	-----------------------------------	------------------------------------	-----------------------------

(This is only professional opinion and not the diagnosis, Please correlate clinically) Lab Tech.  
 Q Block South City 11, Sohna Road, Main Sector-47, Gurgaon, Haryana  
 Ph.: 0124-4900000 (100 Lines) Fax : 0124-2218733 E-mail : parkmedicenters@gmail.com

**PARK GROUP OF HOSPITALS : West Delhi • South Delhi • Gurgaon • Karnal • Panipat • Hodal • Ambala • Behror**





Patient Name	: Mrs.KOMAL	IP/OP No	:
Age/ Sex	: 25 Years Female	Req No	: 797348
Unit name	: RMO	Report Date/Time	: 12/03/2022
Consultant Nm	: RMO	Patient's Phone	:
Reqdt/Reqtm	: 12/03/2022	Payer Name	: MEDIWHEEL PVT LTD

ULTRA SOUND TEST REPORT

Test Name - USG WHOLE ABDOMEN

**USG Whole Abdomen**

The real time, B mode, gray scale sonography of the abdominal organs was performed.

**LIVER** : The liver is normal in size, 13.0cm shape and echotexture. No evidence of any focal lesion. IHBR is not dilated.

**GALL BLADDER** : The gall bladder is well distended . No evidence any calculus or mass seen.  
GB wall thickness with in normal limits.No evidence of pericholecystic fluid is seen.

**BILE DUCT** :The common bile duct is normal in caliber. No evidence of calculus is noted in common bile duct.

**SPLEEN** :The spleen is normal in size 9.8cm and shape.Its echotexture is homogeneous.No evidence of focal lesion is noted.

**PANCREAS** :The pancreas is normal in size, shape, contours and echotexture.No evidence of solid or cystic mass lesion is noted.MPD is not dilated. No evidence of peripancreatic collection.

**KIDNEYS** :The bilateral kidneys are normal in size and echotexture. Cortico-medullary differentiation is maintained.There is no evidence of obvious calculus or hydronephrosis.

**URINARY BLADDER** :The urinary bladder is well distended.It shows uniformly thin walls and sharp mucosa.No evidence of calculus is seen. No evidence of mass or diverticulum is noted.

**UTERUS**: The uterus is anteverted. It measures 6.7x4.9x3.9 cms. in the longitudinal, anteroposterior and transverse dimensions respectively. The uterine margins is smooth and does not reveal any contour abnormalities. The uterine myometrium shows homogeneous echotexture.

No evidence of leiomyoma is noted. No solid or cystic mass lesion is noted.

The endometrial echo is in the midline and measures 7.6mm.

Right ovary is normal in size shape and echotexture.

**A cyst of size 31x29mm noted in left ovary.**

No evidence of ascites or interbowel free fluid is seen.

No evidence of obvious retroperitoneal or mesantric lymphadenopathy is seen.

**IMPRESSION- Left ovarian simple cyst**

To be correlated clinically.

DR. SAKET RUPRAMKA  
MBBS, MD  
CONSULTANT RADIOLOGIST

DR.MANJEET SEHRAWAT  
MBBS, MD, PDCC  
CONSULTANT RADIOLOGIST

DR. BINOD CHOUDHARY  
MBBS, MD  
CONSULTANT RADIOLOGIST

DR. ANSHU K SHARMA  
MBBS, MD  
CONSULTANT RADIOLOGIST

(This is only professional opinion and not the diagnosis. Please correlate clinically.)

Gurgaon : Q Block, South City-II, Sohna Road, Sector - 47, Gurugram-122002, (Haryana)  
Faridabad : J-Block, Sector - 10, Near Court, Faridabad - 121004, (Haryana)

• Helpline : 0124-4900000  
• Helpline : 0129-4200000