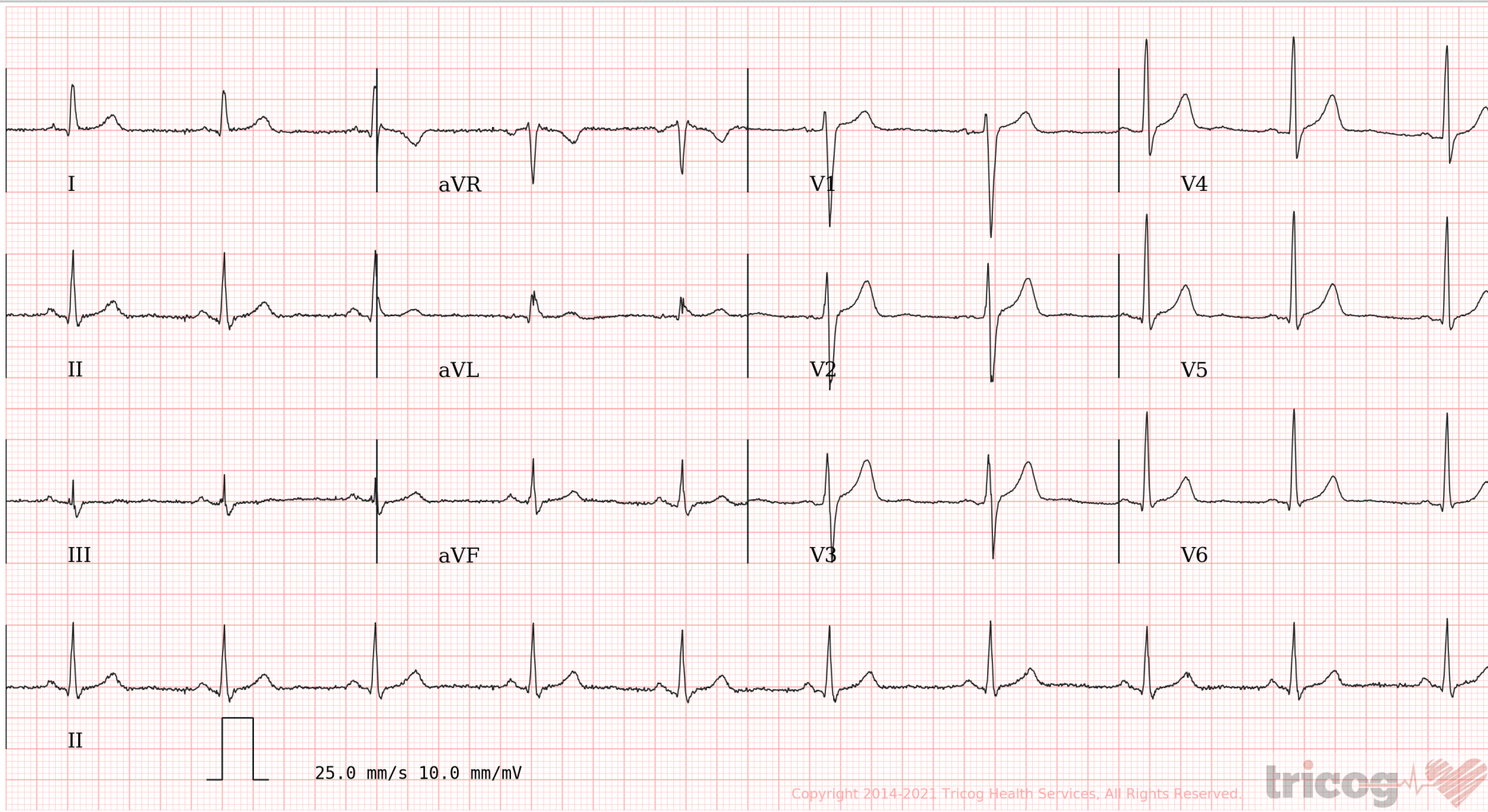


Patient Name: SORAGAVI SANTOSH SUBHASRADDI  
Patient ID: 2120532620

Date and Time: 24th Jul 21 10:00 AM



Age **36** NA **9**  
years months days

Gender **Male**

Heart Rate **61 bpm**

**Patient Vitals**

BP: NA  
Weight: NA  
Height: NA  
Pulse: NA  
Spo2: NA  
Resp: NA  
Others: \_\_\_\_\_

**Measurements**

QSRD: 112 ms  
QT: 390 ms  
QTc: 392 ms  
PR: 140 ms  
P-R-T: 67° 42° 38°

**ECG Within Normal Limits: Sinus Rhythm, Normal Axis. Please correlate clinically.**

REPORTED BY

*Anand Motwani*

Dr. Anand N Motwani  
M.D (General Medicine)  
Reg No 39329 M.M.C

Disclaimer: 1) Analysis in this report is based on ECG alone and should be used as an adjunct to clinical history, symptoms, and results of other invasive and non-invasive tests and must be interpreted by a qualified physician. 2) Patient vitals are as entered by the clinician and not derived from the ECG.

