

Package Details

Patient Name : Ms Sravanthi Jetti C, 20100000023973, female, 37y 6m
Package Name : EHP Mediwheel Full Body Health checkup Below 40 Female
Start Date : 25/02/2023 09:10 End Date : 26/02/2023 09:10
Generated By: Hemanth Kumar
Generated On : 25-02-2023 09:10

Service Name	Ordered Date	Service Center	Consultant	Qty	Explicit
✓ PAP SMEAR	25/02/2023 09:10 AM	CYTOLOGY	Dr. Sharma Vasant Kumar	1	No
✓ CONSULTATION - FIRST VISIT	25/02/2023 09:10 AM	OPD-2F	Dr. Sharma Vasant Kumar	1	No
✓ CONSULTATION - FIRST VISIT	25/02/2023 09:10 AM	OPD-2F	Dr. Jyoti Rajesh	1	No
✓ USG ABDOMEN	25/02/2023 09:10 AM	ULTRA SOUND-2F	Dr. Sharma Vasant Kumar	1	No
✓ ECHO COLOR DOPPLER	25/02/2023 09:10 AM	ECHO-2F	Dr. Sharma Vasant Kumar	1	No
✓ XRAY CHEST PA	25/02/2023 09:10 AM	X-RAY	Dr. Sharma Vasant Kumar	1	No
✓ TREADMILL TEST	25/02/2023 09:10 AM	OPD-2F	Dr. Sharma Vasant Kumar	1	No
✓ ECG	25/02/2023 09:10 AM	OPD-2F	Dr. Sharma Vasant Kumar	1	No
✓ BLOOD UREA NITROGEN (BUN)	25/02/2023 09:10 AM	BIOCHEMISTRY	Dr. Sharma Vasant Kumar	1	No
✓ URIC ACID	25/02/2023 09:10 AM	BIOCHEMISTRY	Dr. Sharma Vasant Kumar	1	No
✓ LIVER FUNCTION TEST (LFT)	25/02/2023 09:10 AM	BIOCHEMISTRY	Dr. Sharma Vasant Kumar	1	No
✓ SERUM CREATININE	25/02/2023 09:10 AM	BIOCHEMISTRY	Dr. Sharma Vasant Kumar	1	No
✓ THYROID PROFILE (T3, T4, TSH)	25/02/2023 09:10 AM	BIOCHEMISTRY	Dr. Sharma Vasant Kumar	1	No
✓ LIPID PROFILE (CHOL, TRIG, HDL, LDL, VLDL)	25/02/2023 09:10 AM	BIOCHEMISTRY	Dr. Sharma Vasant Kumar	1	No
✓ HBA1C	25/02/2023 09:10 AM	BIOCHEMISTRY	Dr. Sharma Vasant Kumar	1	No
✓ URINE FOR SUGAR (FASTING)	25/02/2023 09:10 AM	CLINICAL PATHOLOGY	Dr. Sharma Vasant Kumar	1	No
✓ URINE FOR SUGAR (POST PRANDIAL)	25/02/2023 09:10 AM	CLINICAL PATHOLOGY	Dr. Sharma Vasant Kumar	1	No
✓ FASTING BLOOD SUGAR (FBS)	25/02/2023 09:10 AM	BIOCHEMISTRY	Dr. Sharma Vasant Kumar	1	No
✓ POST PRANDIAL BLOOD SUGAR (PPBS)	25/02/2023 09:10 AM	BIOCHEMISTRY	Dr. Sharma Vasant Kumar	1	No
✓ BLOOD GROUP & RH TYPING	25/02/2023 09:10 AM	NARAYANA HRUDAYALAYA BLOOD CENTRE	Dr. Sharma Vasant Kumar	1	No
✗ STOOL ROUTINE EXAMINATION	25/02/2023 09:10 AM	CLINICAL PATHOLOGY	Dr. Sharma Vasant Kumar	1	No
✓ URINE ROUTINE & MICROSCOPY	25/02/2023 09:10 AM	CLINICAL PATHOLOGY	Dr. Sharma Vasant Kumar	1	No

BP - 130/80
 PR - 80/min
 Wt - 77.3
 Ht - 158cm
 111



Service Name	Ordered Date	Service Center	Consultant	Qty	Explicit
✓ COMPLETE BLOOD COUNT (CBC)	25/02/2023 09:10 AM	HEMATOLOGY	Dr. Sharma Vasant Kumar	1	No
✓ ERYTHROCYTE SEDIMENTATION RATE (ESR)	25/02/2023 09:10 AM	HEMATOLOGY	Dr. Sharma Vasant Kumar	1	No



25-02-2023 09:10

Health Check up Booking Confirmed Request(bobE27292),Package Code-
PKG10000249, Beneficiary Code-76209

Mediwheel <wellness@mediwheel.in>

Thu 2/16/2023 8:50 AM

To: Info Sarjapur <info.sarjapur@narayanahealth.org>

Cc: mediwheelwellness@gmail.com <mediwheelwellness@gmail.com>

Attention: This email originated outside of Narayana Health domain. Links and attachments cannot be verified as authentic. Do not share personal/organisational data including passwords or act based on the content of the email, unless you have verified the authenticity of the sender and email address thoroughly.

011-41195959

Email:wellness@mediwheel.in

Hi Narayana Multispeciality Clinic ,

Diagnostic/Hospital Location :83/3 Doddakanneli,Sarjapur,Main Road , Near Wipro Gate-
560035,City:Bangalore

We have received the confirmation for the following booking .

Beneficiary Name : PKG10000249

Beneficiary Name : MS. JETTI C SRAVANTHI

Member Age : 35

Member Gender : Female

Member Relation : Employee

Package Name : Mediwheel Metro Full Body Health Checkup Female Below 40

Location : BENGALURU,Karnataka-560038

Contact Details : 8639730793

Booking Date : 30-01-2023

Appointment Date : 25-02-2023

Instructions to undergo Health Check:

1. Please ensure you are on complete fasting for 10-To-12-Hours prior to check.
2. During fasting time do not take any kind of medication, alcohol, cigarettes, tobacco or any other liquids (except Water) in the morning.
3. Bring urine sample in a container if possible (containers are available at the Health Check centre).
4. Please bring all your medical prescriptions and previous health medical records with you.
5. Kindly inform the health check reception in case if you have a history of diabetes and cardiac problems.

For Women:

1. Pregnant Women or those suspecting are advised not to undergo any X-Ray test.
2. It is advisable not to undergo any Health Check during menstrual cycle.

We request you to facilitate the employee on priority.

Employee Name	Mr. Sravanthi jetti c
---------------	-----------------------

Employee ID	179327
-------------	--------

Age	37 y4
-----	-------

Gender	Female
--------	--------

Date	25/02/2023
------	------------

Name of center	NH SARJAPUR
----------------	-------------


City	Bangalore
------	-----------

BASIC PARAMTERS:

Height (in mts)	158 cm
Weight (in Kgs)	77.3 kg
BMI	

Waist circumference (in cms)	93
Hip circumference (in cms)	111
Waist-to-hip ratio	

Systolic BP	130
Diastolic BP	80



TRANS-THORACIC ECHO REPORT

Patient MRN : 20100000023973

Date : 25.02.2023

Patient Name : Ms.SRAVANTHI JETTI C

Age/Gender : 37 yrs/Female

M-MODE / 2D MEASUREMENTS

LVEF (>55)% : 60%	LVID(d) (40-56)mm : 43mm	LVID (s) mm : 30mm
TAPSE (>16) mm : 20mm	IVS (d) (6-10)mm : 10mm	LV-EDV ml : --
LA (<39) mm : 28mm	PWD (d) (6-10)mm : 9mm	LV-ESV ml : --
RA (<44)mm : 30mm	RV (<35) mm : 26mm	BSA m ² :-

DOPPLER MEASUREMENTS

MITRAL VALVE : E/A - 0.8/0.5 M/S, NORMAL LV DIASTOLIC FUNCTION, MR-TRIVIAL

AORTIC VALVE : PG -5 MMHG/AR-TRIVIAL

TRICUSPID VALVE : TR -TRIVIAL

PULMONARY VALVE : PG -2 MMHG

PA PRESSURE : PASP-18 MMHG/ NORMAL PA PRESSURE.

FINDINGS

SITUS SOLITUS, LEVOCARDIA, AV AND VA CONCORDANT, NORMAL GREAT ARTERY RELATIONSHIP

VALVES

MITRAL : NORMAL

AORTIC : NORMAL

TRICUSPID : NORMAL

PULMONARY : NORMAL

CHAMBERS

LV : NORMAL SIZED, NORMAL LV SYSTOLIC FUNCTION.

RV : NORMAL SIZED, NORMAL RV FUNCTION.

RWMA : NO RWMA

LVOT : NORMAL

LEFT ATRIUM : NORMAL SIZED

RIGHT ATRIUM : NORMAL SIZED

SEPTAE

IVS : INTACT

IAS : INTACT

ARTERIES & VEINS

AORTA : AORTIC ANNULUS- 20 MM, ASCENDING AORTA- 25 MM,
NORMAL ARCH NORMAL SIZED.

PULMONARY ARTERY : NORMAL

IVC, SVC & CS : IVC – 13 MM, NORMAL SIZED, COLLAPSING, NORMAL RA PRESSURE.

PULMONARY VEINS : NORMAL

PERICARDIUM : NORMAL

VEGETATION / THROMBUS / TUMOR: NIL

OTHER FINDINGS:

SINUS RHYTHM-82 BPM

NO PREVIOUS ECHO REPORT

CONCLUSION

NORMAL CHAMBER DIMENSIONS

NORMAL PA PRESSURE

NO RWMA

NORMAL LV SYSTOLIC FUNCTION

LVEF:- 60%


CHANDANA V
CARDIAC SONOGRAPHER

ID: 201-23973
Name: MRS. SRAVANTHI
Age: 37 Years
Gender: Female

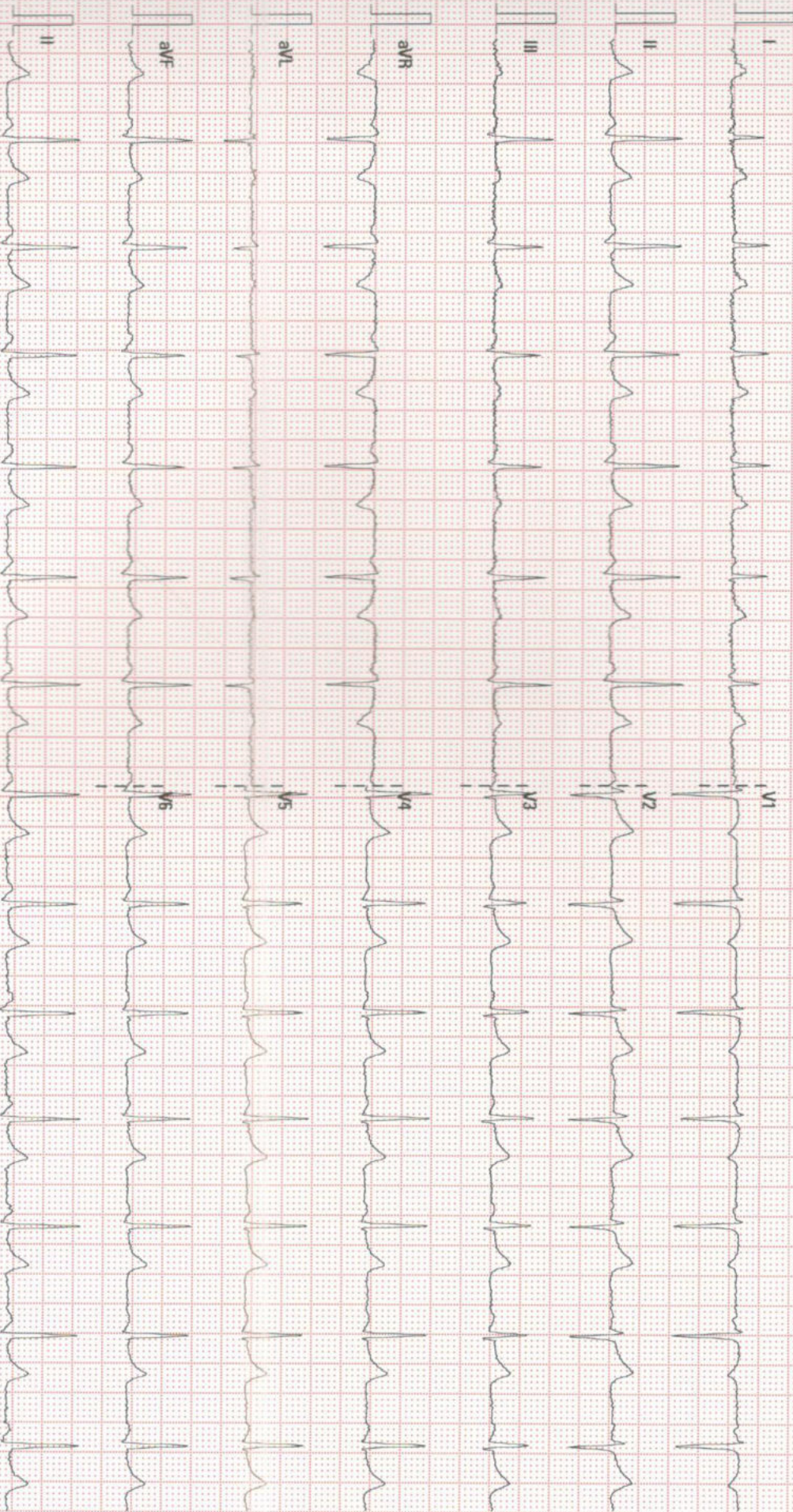
25-02-2023 09:43:22

Vent. Rate 82 bpm
PR Interval 114 ms
QRS Duration 78 ms
QT/QTc Interval 378/417 ms
P/QRS/T Axes 58/66/50 deg
RV5/SV1 1.088/1.062 mV
RV5 + SV1 2.150 mV

Dr. Chodges

Sinus rhythm
Normal ECG

Unconfirmed Diagnosis



25 mm/s

10 mm/mV

50 Hz

BDR 35 Hz

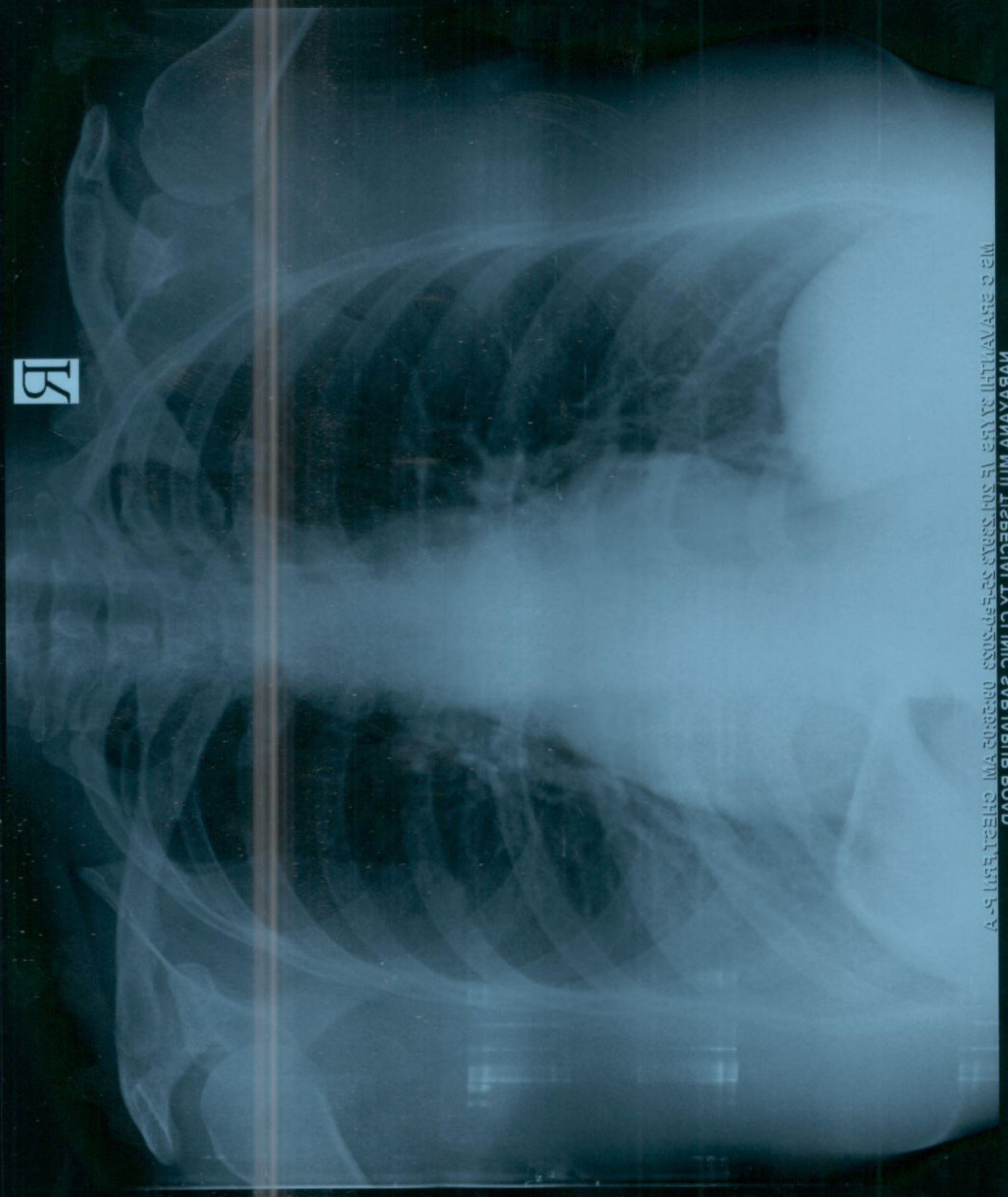
NARAYANA MSC - SARGAPUR

02.04.00.V28.4.1

SN-FM-58 003398

DR. G. SRIVANILINI B.A.M.S. (P) M.D. (A) SPECIALIST CHEST ILLS P. A.
NARAYANA MULI SPECIALTY CLINIC, SARLABUR ROAD

R



Patient Name : Mrs.SRAVANTHI JETTI

Patient ID : 201-23973

Age : 37Years

Sex : Female

Referring Doctor : PKG

Date : 25 .02.2023

ULTRASOUND ABDOMEN AND PELVIS

FINDINGS:

Liver is normal in size (14.5cm) and echopattern. No intra or extra hepatic biliary duct dilatation. No focal lesions.

Portal vein is normal in size, course and caliber. **CBD** is not dilated.

Gall bladder shows hyperechoic polyp along upper body measures , 5.5mm, without evidence of calculi and pericholecystic fluid.Wall thickness is normal.

Pancreas to the extent visualized, appears normal in size, contour and echogenicity

Spleen is normal in size (9.9cm), shape, contour and echopattern. No evidence of mass or focal lesions.

Right Kidney is normal in size (measures 9 cm in length & 1.4 cm in parenchymal thickness), position, shape and echopattern. Corticomedullary differentiation is maintained. No evidence of calculi or hydronephrosis.

Left Kidney is normal in size (measures 9.2 cm in length & 1.5 cm in parenchymal thickness), position, shape and echopattern. Corticomedullary differentiation is maintained. No evidence of calculi or hydronephrosis.

Retroperitoneum – Obscured by bowel gas.

Urinary Bladder is well distended. Wall thickness is normal. No evidence of calculi, mass or mural lesion.

Uterus is anteverted and normal in size, measures 8.9 x 4 x 5.9cm. There is a posterior wall intramural myoma measuring 2.1 x 1.8cm indistinct the endometrium anteriorly.

Endometrium measures –3.7 mm. Endometrial cavity is empty.

Both ovaries are normal in size and echopattern.

Right ovary: measures 2.1 cm. **Left ovary:** measures 1.7 x 1.5 cm.

Both adnexa: Normal. No mass is seen.

There is no ascites or pleural effusion.

IMPRESSION:

- GALL BLADDER POLYP AS DESCRIBED
- POSTERIOR WALL INTRAMURAL MYOMA AS DESCRIBED.


Dr. Ananthalakshmi.S

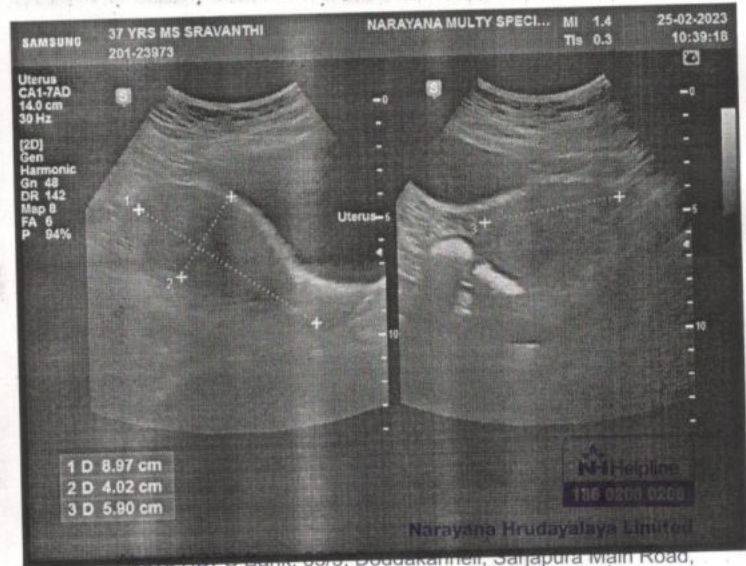
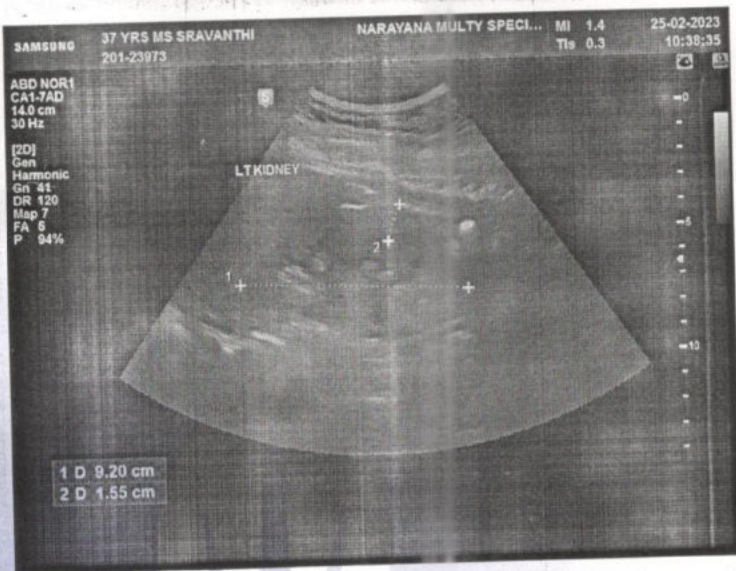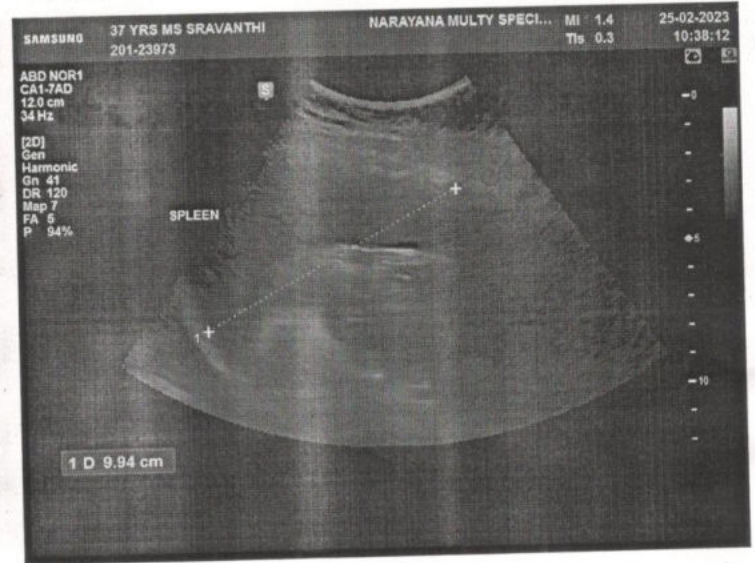
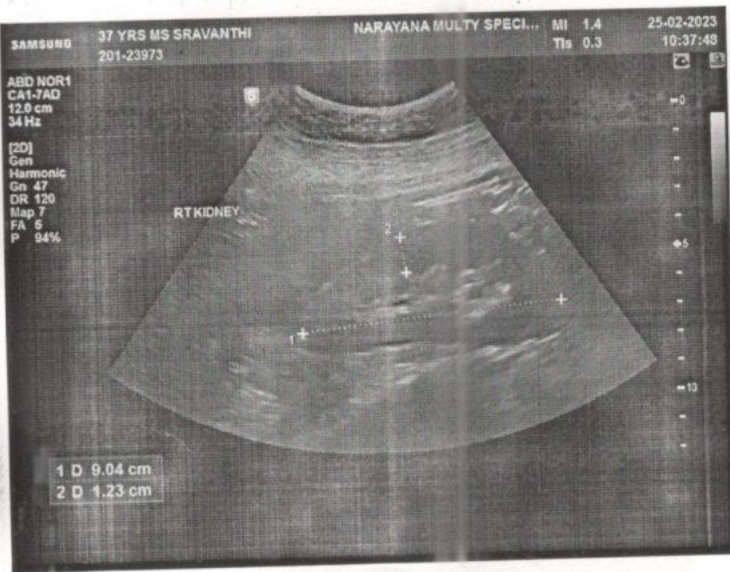

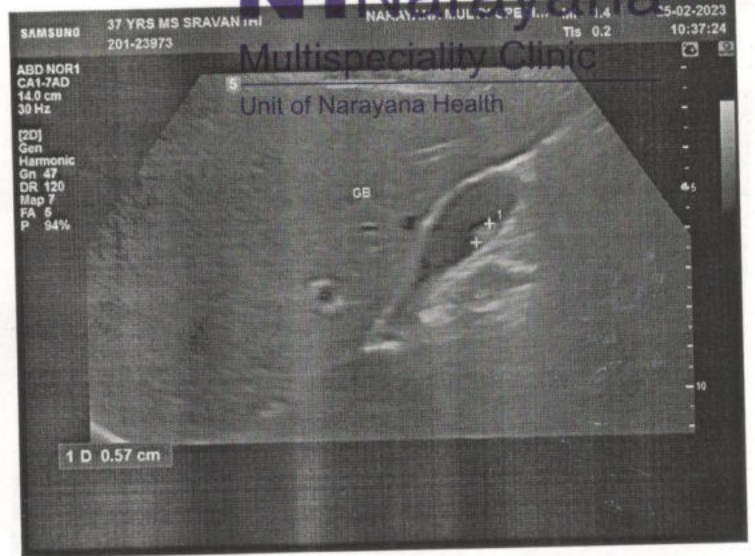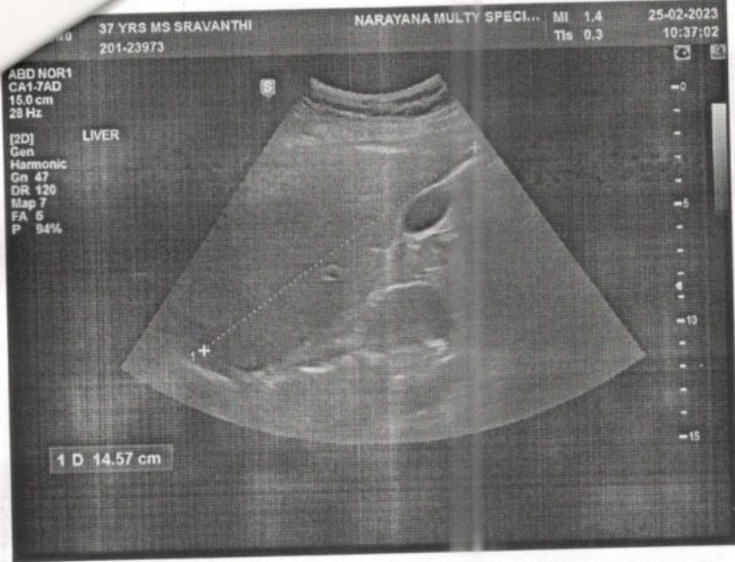sonolog 131 0208 0208

Narayana Hrudayalaya Limited

Above HDFC Bank, 83/3, Doddakanneli, Sarjapura Main Road,

Varthur Hobli, Bangalore - 560035

Tel: + 91 88844 31319. Email: info.sarjapura@narayanahealth.com



Narayana Hrudayalaya Limited

TO WHOMSOEVER IT MAY CONCERN

I hereby give a consent 201-23973 (Patient Name) Mrs. Sravathi.
(MRN No) that I have not taken service Stool routine pap smear.
(ECG/ECHO/Doppler/TMT/X-Ray/Investigation/Consultation against
Package/Health Checkup) Mediwheel pkg (Package Name/HC
Name) against Invoice number 2010-2301001770
dated 25/2/2023.

Sravathi
Patient Sign

Permi
Dept Sign

3/16/23 B.K
Unit Head Sign/Seal

8639230793
Mobile Number

349939
EC Number

316370
EC Number

