

DAKSH HOSPITAL

396 - 397, Gandhi Nagar, Scheme No. 8, ALWAR -301001

Ref. No.

Date.....

MEDICAL EXAMINATION REPORT

Mediwheel (BOB)

Name: Mr Hemant Kumar

Age: 37 yrs Sex: Male

Date: 08/04/2023

General Physical Examination

Height : 175 cm

Weight 89 kg

Pulse : 68/mnt


BP 124/86

Temp. : AF

Respiration 16/mnt: clear

BMI : 22.5

Systemic Exam:- NADDental Check up :- NADEye check-up :- NADSkin Check up:- NADENT Check up:- NADGynae Check up:- NILImpression:- Dyslipidemia, EosinophiliaRecommendation:- PBR / Electrolyte / Life style modification


 Dr. Mukesh Kumar Gupta
 MD Gen. Medicine
 Reg. No 5423/16262

डॉ० मुकेश गुप्ता
 M.D. F.C.C.S.
 फिजिशियन एवं मधुमेह रोग विशेषज्ञ
 दक्ष हॉस्पिटल, अलवर
 रजि. नं. 5423/16262

Results

Run Date 08/04/2023 11:10:59 AM

Operator DAKSH

Last Name

Sample ID 5

First Name MR. HEMANT

Department

Gender Male

Age

Physician DR. MUKESH GUPTA M.D

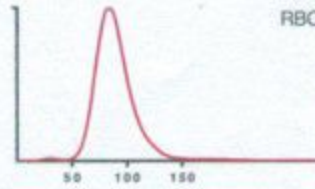
Patient ID AUTO_PID12898

Type Man

Date of birth

Sample comments

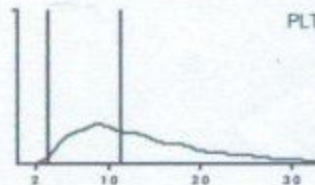
				Range
RBC	5.24 *	10 ⁶ /μL		3.80 - 5.50
HGB	15.1	g/dL		13.0 - 17.0
HCT	49.2 *	%		39.0 - 52.0
MCV	93.8 *	μm ³		76.0 - 100.0
MCH	28.9	pg		26.0 - 34.0
MCHC	30.8 L	g/dL		32.0 - 35.0
RDW-CV	17.2 H	%		11.0 - 16.0
RDW-SD	59.4 H	μm ³		37.0 - 49.0



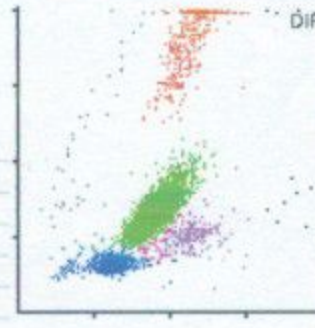
Recommended actions

- Slide review
- Susp. Pathologies
- Anisocytosis
- Macroplatelets

				Range
PLT	221 *	10 ³ /μL		150 - 450
PCT	0.29 *	%		0.15 - 0.40
MPV	12.9 H*	μm ³		8.0 - 11.0
PDW	25.0 H*	μm ³		11.0 - 22.0
P-LCC	116	10 ³ /μL		44 - 140
P-LCR	52.7 h	%		18.0 - 50.0



			Range		Range
WBC	6.23	10 ³ /μL	3.50 - 10.00		
	#			%	
NEU	4.26		1.60 - 7.00	68.6	40.0 - 75.0
LYM	1.21		1.00 - 3.00	19.6	20.0 - 45.0
MON	0.10		0.20 - 0.80	1.6	2.0 - 10.0
EOS	0.55 h		0.00 - 0.50	8.8 h	1.0 - 6.0
BAS	0.08		0.00 - 0.15	1.4 h	0.0 - 1.0
LIC	0.03		0.00 - 0.10	0.5	0.0 - 1.0



Handwritten signature

डॉ० मुकेश गुप्ता

M.D. F.C.C.S.

फिजिशियन एवं मधुमेह रोग विशेषज्ञ

दक्ष हॉस्पिटल, अलवर

रजि. नं.- 5423/16262

Date :-08/04/2023

Name :- MR. HEMANT KUMAR

Age & Sex :- 37Yrs/ male

Refd. :- Dr Mukesh Gupta M.D.

	TEST NAME	RESULT	REFERENCE RANGE
	ESR	13	00 -20 mm/hrs
	Blood Group & Rh Factor	B " POSITIVE	
	HbA1C	4.4	4 - 5.6%
	Blood Sugar (F)	85.1	< 70 - 100 mg/dl
	Blood Sugar (PP)	102.1	< 140 mg/dl
	Urine Sugar (F)	NIL	-
	Urine Sugar (PP)	NIL	-
LIVER	S.Bilirubin Total	1.20	0.30 - 1.20 mg/dl
	S.Bilirubin Direct	0.40	0.10 - 0.30 mg/dl
	S.Bilirubin Indirect	0.80	0.30 - 0.90 mg/dl
	S.G.O.T.	35	u/l
	S.G.P.T.	44	u/l
	S.Alk. Phosp.	199	u/l
	G.G.T.	23	5 - 40 u/l
	Total Protein	7.0	6.5 - 8.5 gm/dl
	Albumin	3.9	3.8 - 5.4 gm/dl
	Globulin	3.1	2.3 - 3.5 gm/dl
	A/G Ratio	1.2	-
	AST/ALT Ratio	0.7	-
KIDNEY	Blood Urea	29.2	15 -45 mg/dl
	S.Creatinine	1.2	0.60 - 1.30 mg/dl
	BUN	16.0	6 -24 mg/dl
	S.Uric Acid	5.4	M 3.1 - 7.0, F 2.5 - 5.6 mg/dl
	BUN/Creatinine Ratio	1.3	-
LIPID PROFILE	Total Cholesterol	225.1	Up to 200 mg/dl
	S.HDL	47.1	30 - 70 mg/dl
	S.LDL	145.1	Up to 170 mg/dl
	S.VLDL	33.1	5.0 - 40 mg/dl
	S. Triglycerides	165.1	Up to 170 mg/dl
	LDL/HDL Ratio	3	-
	Total Cholesterol/ HDL Ratio	4.7	-
THYROID	T3	98.1	1.2 - 2.8 nmol/L
	T4	9.5	77 -155 nmol/L
	TSH	2.9	0.30 - 5.0 mU/L

URINE EXAMINATION
Microscopic Examination :

General/Chemical Examination:			RBC	Absent
	Colour	Pale Yellow	WBC	0 - 1
	Reaction	Acidic	Epithelial Cells	Absent
	Specific Gravity	QNS	Cast	Absent
	Appearance	Clear	Crystal	Absent
	Albumin	Nil	Spermatozoa	Absent
	Sugar	Nil	Amorphous Sediments	Absent
			Other	Absent

X-RAY CHEST

NORMAL STUDY

STOOL EXAMINATION
Microscopic Examination :

General/ Chemical Examination:			RBC	-
	Colour	-	WBC	-
	Consistency	-	Ova & Parasites	-
	PH	-		
	Reducing Substances	-		

डॉ. मुकेश गुप्ता

M.D. F.C.C.S.

Doctor

फिजिशियन एवं मधमेह रोग विशेषज्ञ

TECHNOLOGIST

All investigations have their own limitations regarding the sensitivity & specificity of individual assay procedures, isolated laboratory investigations never confirm the final diagnosis of the disease. They only help in arriving at a diagnosis in conjunction with clinical presentation and other related investigations. Report is not valid for medico-legal purpose subject to ALWAR jurisdiction only.



दक्ष हॉस्पिटल

396, गाँधी नगर स्कीम नं.8, अलवर (राज०) ☎ 0144-2703340

Sonography / 2D Echo Cardiography / Doppler Report

2D/ ECHO REPORT

Name: - MR. HEMANT KUMAR

Age: -37 Yrs

Date: - 8-Apr-23

Reg. No.:- Alw/2009/04
BO3 HELATH CHECK UP

PROCEDURES:

M-MODE/2D/DOPPLER/COLOR/CONTRASTB.A.S. M²

MEASUREMENT:		DOPPLER:	
AOD	22	NORMAL (20- 37mm)	NORMAL (cm/sec.)
LA	20	(19- 40mm)	MV 0.8 (0.8- 1.3) MR No
AVO	19	(12- 25mm)	AV 1.1 (1.2- 1.8) AR No
RVDd.	12	(03- 09mm)	TV 0.6 (0.3- 0.8) TR No
LVDd	48	(37- 56mm)	PV 0.8 (0.7- 1.1) PR No
LVDs	26	(22- 40mm)	MITRAL VALVE-
IVS d	11	(06- 12mm)	AML Normal
IVS s	12		PML Normal
PWd	7	(05- 10mm)	AORTIC VALVE Normal
LV FUNCTION		TV & PV are normal.	
M- E- S Separation		<0.9cm	
Minor		24.42%	
LV Ejection Fraction	68%	65 +/- 12%	

LV WALL MOTION: NO RWMA
ALL CARDIAC CHAMBERS ARE NORMAL
ALL VALVES ARE NORMAL
NO CLOT, VEGETATION, PERICARDIAL EFFUSION

FINAL DIAGNOSIS: NORMAL STUDY

Adv: - Follow up/ review at higher center for confirmation

Note:- Please Correlate clinically. Due to technical limitations as well as inaccuracies inherent in the laboratory and statistical analysis of biological process. Diagnostic accuracy of ECHO is up to 95% only
Report is not valid for medico-legal purpose.


Dr. Madhush Kumar Gupta
PHYSICIAN
Physician & Sonologist
RM 5423/16262



"भ्रूण लिंग परीक्षण की शिकायत
104 टोल फ्री सेवा पर भी की
जा सकती है।"

भ्रूण लिंग परीक्षण की शिकायत 104 टोल फ्री सेवा पर भी की जा सकती है।



दक्ष हॉस्पिटल

396, गाँधी नगर स्कीम नं.8, अलवर (राज०) ☎ 0144-2703340

Sonography / 2D Echo Cardiography / Doppler Report

Name: MR. HEMANT KUMAR /M/37 YRS
BOB HELATH CHECK UP

Date: 8-Apr-23

U.S.G. OF ABDOMEN & PELVIS

LIVER

Liver is normal in size shape with normal echo-texture. Intra hepatic biliary radicals are not dilated.
No evidence of focal or diffuse lesion.

GALL BLADDER

Gall bladder is normally **distended**. Lumen clear. Wall thickness normal. CBD normal

PANCREAS

Pancreas is normal in size, shape & echo-texture.

SPLEEN

Normal in size with normal shape & echo- texture.

BOTH KIDNEY

Both kidneys are normal in size shape and echo- texture.

PROSTATE is normal shape, size & echo texture..

URINARY BLADDER is normally **distended**, lumen appear clear.

Advice- X Ray KUB / URINE EXAM

Please correlate clinically. USG accuracy is 95 % due to technical limitations as well as inaccuracies inherent in the laboratory and statistical analysis biological process.

This report is not valid for medico-legal cases.


Dr. Muresh Kumar Gupta
SONOLOGIST
Physician & Sonologist
RM 5423/16262



"भ्रूण लिंग परीक्षण की शिकायत
104 टोल फ्री सेवा पर भी की
जा सकती है"

भ्रूण लिंग परीक्षण की शिकायत 104 टोल फ्री सेवा पर भी की जा सकती है।

ID: 583

08-04-2023 13:21:04

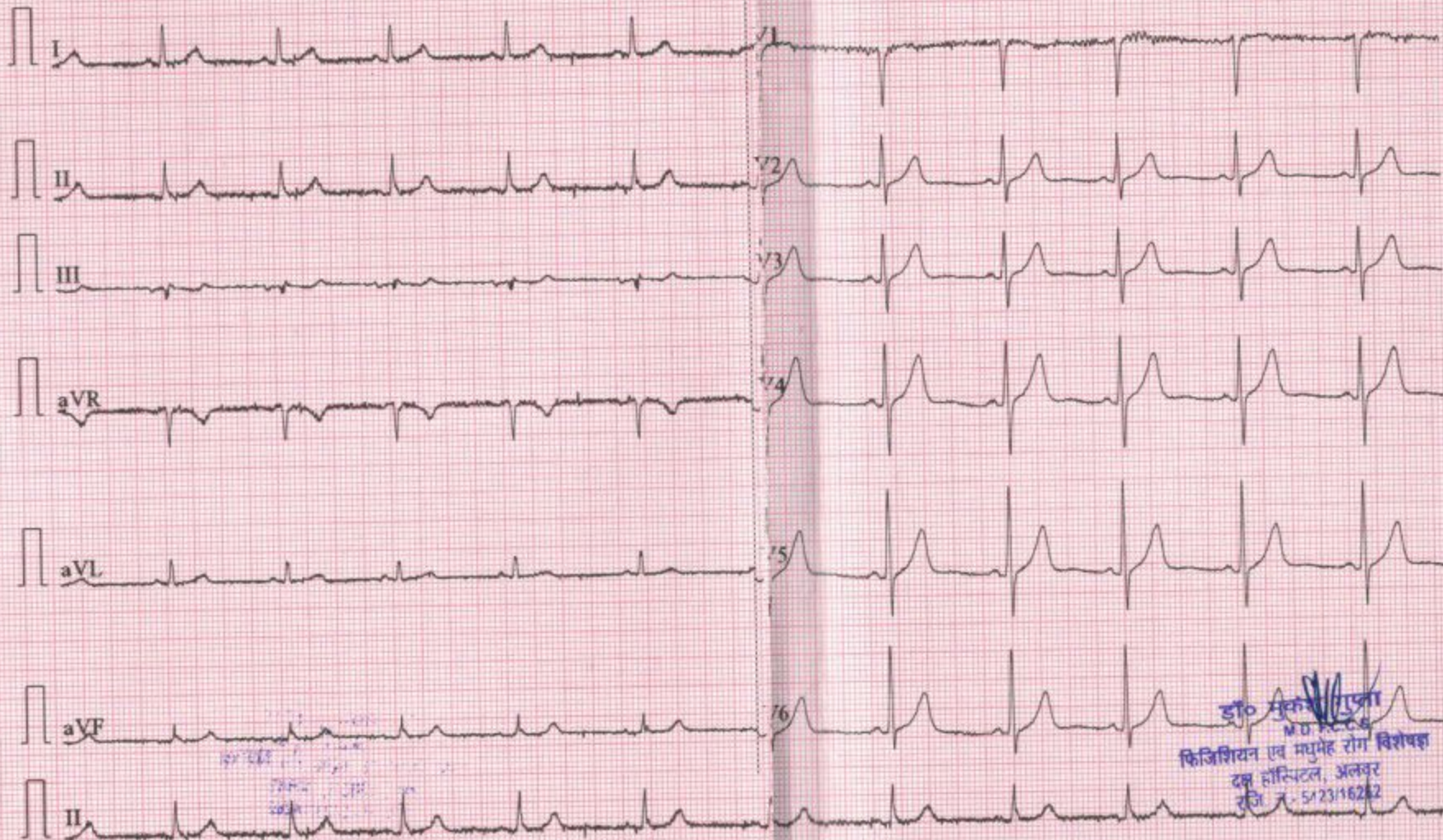
male Years
Req. No. :

HR : 69 bpm
 P : 80 ms
 PR : 108 ms
 QRS : 76 ms
 QT/QTcBz : 366/392 ms
 P/QRS/T : 13/26/39 °
 RV5/SV1 : 1.606/0.926 mV

Diagnosis Information:

Sinus rhythm
 Short PR interval
 Borderline ECG

Report Confirmed by:



डॉ० मुकेश गुप्ता
 M.D. (CCU)
 फिजिशियन एवं मधुमेह रोग विशेषज्ञ
 दक्ष हॉस्पिटल, अलवर
 रजि नं-512316282

R

