

MER- MEDICAL EXAMINATION REPORT

Date of Examination	24-06-2023		
NAME	MR. PRASHANT KUMAR MOKHENTY		
AGE	45	Gender	Male
HEIGHT(cm)	163 cm	WEIGHT (kg)	73 kg
B.P.	130/80		
ECG	Normal		
X Ray	Normal		
Vision Checkup	-		
Present Ailments	-		
Details of Past ailments (If Any)	-		
Comments / Advice : <input checked="" type="checkbox"/> She / <input checked="" type="checkbox"/> He is Physically Fit	fit		

BMI = 27.5 kg/m² (overweight)

Signature with Stamp of Medical Examiner

Dr. Mukesh Dubey
 (MBBS DCP)
 Registration No.-10632

Panel Medical Examiner
 Triveni Diagnostic & Research Centre
 Agrawal Plaza, B-7, H.I.G. Main Road,
 INDORE



भारत सरकार



भारतीय विशिष्ट पहचान प्राधिकरण

भारत सरकार

Unique Identification Authority of India

Government of India

Enrollment No.: 0648/00788/50454


To,
Prasant Kumar Mohanty,
First Floor 43 Hanuman Nagar Near Navchandi Mandir
Khandwa
Khandwa Khandwa Khandwa
Madhya Pradesh 450001
9479258963

23/06/2013

Ref: 1132 / 270 / 127719 / 128163 / P



SB906865588FH



आपका आधार क्रमांक / Your Aadhaar No. :

4823 5783 0510

मेरा आधार, मेरी पहचान



भारत सरकार
Government of India



Prasant Kumar Mohanty
DOB: 28/12/1977
Male



4823 5783 0510

मेरा आधार, मेरी पहचान

Panel Medical Examiner
Triveni Diagnostic & Research Centre
Agrawal Plaza, B-7, H.I.G Main Road,
INDORE

TRIVENI DIAGNOSTIC & RESEARCH CENTRE
Agrawal Plaza, B-7, H.I.G Main Road,
INDORE

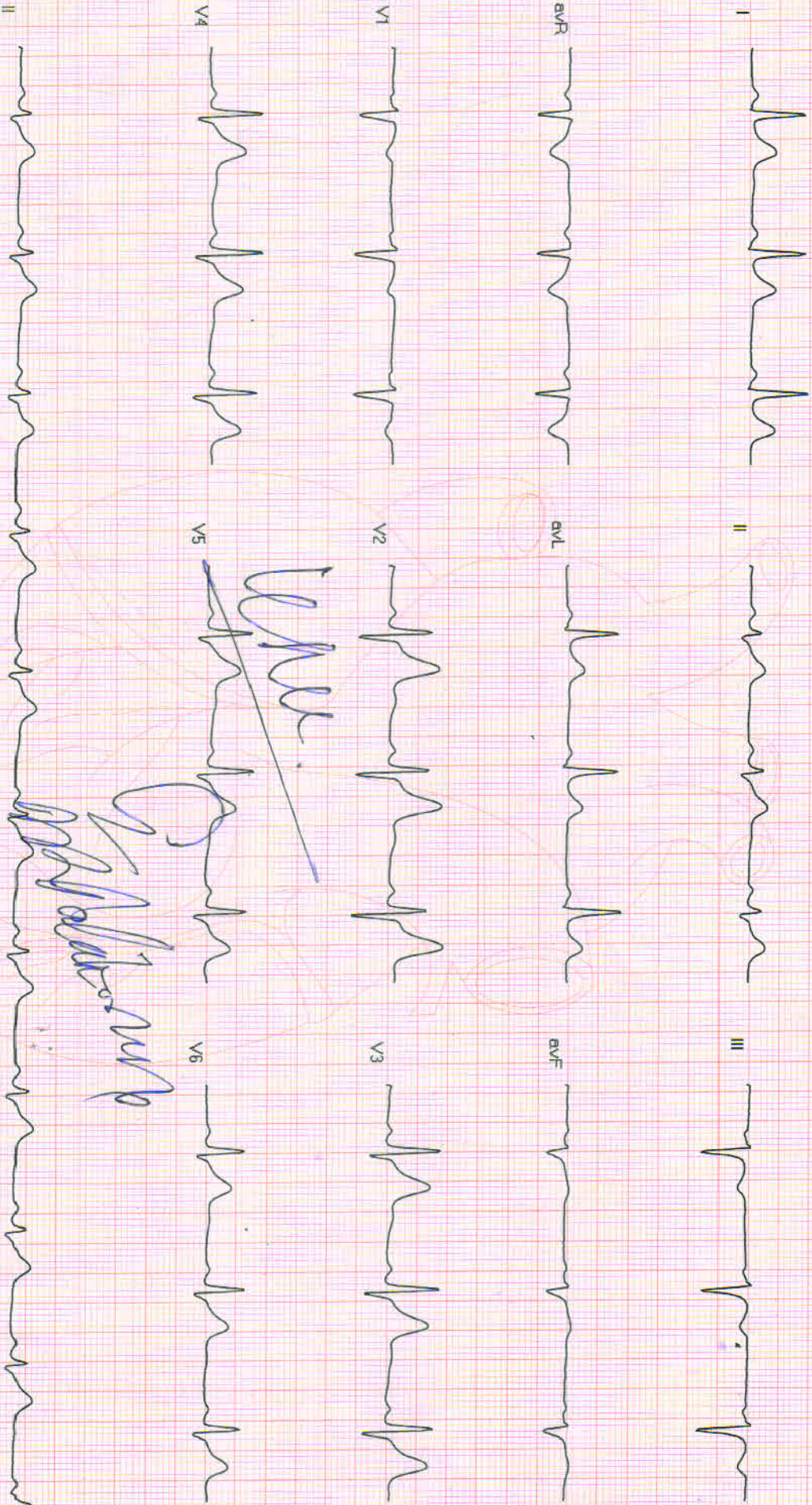
FOO

TRIVENI DIAGNOSTICS & RESEARCH CENTRE

2532 / MR PRASHANT KUMAR MOHANTY / 45 Yrs / M / Non Smoker

Heart Rate : 64 bpm / Tested On : 24-Jun-23 10:33:04 / HF 0.05 Hz - LF 20 Hz / Notch 50 Hz / Sn 1.00 Cm/mV / Sw 25 mm/s

ECG



Normal

Prashant Mohanty

Panel Medical Examiner

Triveni Diagnostic & Research Centre
Agrawal Plaza, B-7, H.G. Main Road,

INDORE
Reported By:



Triveni Diagnostic Centre

Reg No. : 73394 VISITID : 000077703
PATIENT NAME : Mr. PRASHANT KUMAR MOHANTY SPEC. NO : 1905400966
AGE/SEX : 45 YEARS/MALE SAMP. DATE : 24/06/2023 12:03:00
REF. BY : Dr. ARCOFEMI HEALTHCARE LIMITED RESULT DATE : 26/06/2023 08:57:52

HEMATOLOGY

CBC (COMPLETE BLOOD COUNT)

NAME OF TEST	RESULT VALUE	REFERENCE RANGE	UNIT
HAEMOGLOBIN	13	13.5 - 18	gm/dl
TOTAL RBC COUNT	5.01	4 - 6.5	mill/cummm
HAEMATOCRIT (PCV)	41.5	41.5 - 50.4	%
MEAN CORPUS VOL(MCV)	82.83	80 - 96	f l
MEAN CORPUS HB (MCH)	25.95	27.5 - 33.2	picograms
MEAN CORPUS HB CONC (MCHC)	31.33	33.4 - 35.5	%
RDW	13.8	11.5 - 15.5	%
PDW	15.1	-	f l
MPV	11.6	-	f l
PCT	0.24	-	%
P-LCR	35.8	-	%
TOTAL WBC	7400	4000 - 11000	/cumm
PLATELET COUNT	2.06	1.5 - 4.0	Lacs/cumm
DIFFERENTIAL COUNT			
NEUTROPHILS	62	40 - 70	%
LYMPHOCYTES	32	20 - 40	%
MONOCYTES	02	1 - 8	%
EOSINOPHILS	04	0 - 6	%
BASOPHILS	00	0 - 1	%
ABSOLUTE NEUTROPHILS	4.61	2 - 7	X1000/cumm
ABSOLUTE LYMPHOCYTES	2.42	1 - 3	X1000/cumm
ABSOLUTE MONOCYTE	0.14	0.2 - 1	X1000/cumm
ABSOLUTE EOSINOPHIL	0.28	0.02 - 0.5	X1000/cumm
ABSOLUTE BASOPHIL	00	0.02 - 0.1	X1000/cumm
ESR	08	0 - 20	mm at end of 1
MP (MALARIA PARASITE)	.	-	

METHOD:- By five part automated analyzer (sysmex XS1000 i) Japan

DR. MUKESH DUBEY
MBBS DCP (DIRECTOR)

DR. VIJAY BHURIYA
MBBS DMRD

DR. YOGESH PAWDE
M. D. (CONS. PATHOLOGIST)

DR. P.S. TRIPATHI
M.D. (RADIO DIAGNOSIS)

DR. SANJAY YADAV
CON. MICROBIOLOGIST

Report Checked By:

Address : Agrawal Plaza, B-7, HIG Main Road, Indore Ph. : 0731-4289992-3
Website : www.trivenidiagnostic.com email : trivenidiagnostic@yahoo.co.in

Page 1 of 1



Triveni Diagnostic Centre

Reg No. : 73394 VISITID : 0000077703
PATIENT NAME : Mr. PRASHANT KUMAR MOHANTY SPEC. NO : 1905400961
AGE/SEX : 45 YEARS/MALE SAMP. DATE : 24/06/2023 12:03:00
REF. BY : Dr. ARCOFEMI HEALTHCARE LIMITED RESULT DATE : 26/06/2023 09:01:23

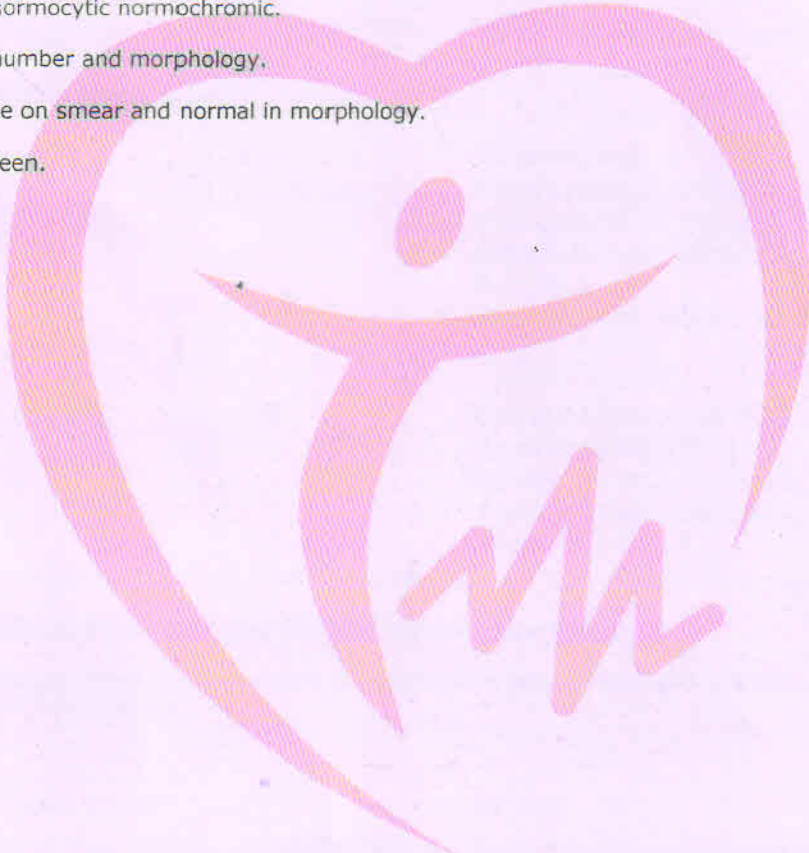
NAME OF TEST	RESULT VALUE		REFERENCE RANGE	UNIT
	IN RANGE	OUT RANGE		

PERIPHERAL SMEAR EXAMINATION

PERIPHERAL SMEAR

REMARKS :

Rbcs show They are normocytic normochromic.
Wbcs are normal in number and morphology.
Platelets are adequate on smear and normal in morphology.
No hemoparasite is seen.



DR. MUKESH DUBEY
(MBBS, DCP) (DIRECTOR)

DR. VIJAY BHURIYA
MBBS DMRD

DR. YOGESH PAWDE
M. D. (CONS. PATHOLOGIST)

DR. P.S. TRIPATHI
M.D. (RADIO DIAGNOSIS)

DR. SANJAY YADAV
CON. MICROBIOLOGIST

Report Checked By :

Address : Agrawal Plaza, B-7, HIG Main Road, Indore Ph. : 0731-4289992-3
Website : www.trivenidiagnostic.com email : trivenidiagnostic@yahoo.co.in

Page 1 of 1



Triveni Diagnostic Centre

Reg No. : 73394 VISITID : O000077703
PATIENT NAME : Mr. PRASHANT KUMAR MOHANTY SPEC. NO : 1905400962
AGE/SEX : 45 YEARS/MALE SAMP. DATE : 24/06/2023 12:03:00
REF. BY : Dr. ARCOFEMI HEALTHCARE LIMITED RESULT DATE : 26/06/2023 08:58:30

DEPARTMENT OF PATHOLOGY

NAME OF TEST	RESULT VALUE	REFERENCE RANGE	UNIT
FBS			
FBS	87	70 - 110	mg / dl

RESULT REMARKS : Test done by -"Roche COBAS- ENTEGRA 400 PLUS "fully bichemistry analyser .

HBA1 C (GLYCOSYLATED HEAMOGLOBIN)

HBA1 C (GLYCOSYLATED HEAMOGLOBIN)	5.1	Normal: 4-6 Good cntrol:6.1-7.0 Fair control :7.0-8.2 Unsatisfactory control: 8.0-10.2 Poor control: Above 10.0	%
-----------------------------------	-----	--	---

MEAN PLASMA GLUCOSE (MPG)	100	Exelent Control:90-120 Good Control:121-150 Avrege Control:151-180 Action Suggested:181-210 Panic value :>211	mg/dL
---------------------------	-----	---	-------

RESULT REMARKS : Test done by -"Roche COBAS- ENTEGRA 400 PLUS "fully bichemistry analyser .

METHOD BY: Turbidimetric inhibition immunoassay(TINIA)

Average blood glucose value is calculated from HBA1C value and indicates average blood sugar level over past three months.

PPBS

PPBS (POST PRANDIAL BLOOD SUGAR)	137	70 - 140	mg / dl
----------------------------------	-----	----------	---------

RESULT REMARKS : Test done by -"Roche COBAS- ENTEGRA 400 PLUS "fully bichemistry analyser .

Report Checked By :

Page 1 of 2



Triveni Diagnostic Centre

Reg No. : 73394 VISITID : 000077703
PATIENT NAME : Mr. PRASHANT KUMAR MOHANTY SPEC. NO : 1905400964
AGE/SEX : 45 YEARS/MALE SAMP. DATE : 24/06/2023 12:03:00
REF. BY : Dr. ARCOFEMI HEALTHCARE LIMITED RESULT DATE : 26/06/2023 09:00:30

DEPARTMENT OF PATHOLOGY

NAME OF TEST	RESULT VALUE	REFERENCE RANGE	UNIT
BLOOD GROUP			
BLOOD GROUP	"O"	-	
RH FACTOR	Positive	-	
RESULT REMARKS :			
GAMA GT			
GGT (GAMMA GLUTAMYL TRANSFERASE)	24	8 - 52	U / L
RESULT REMARKS :			
URINE SUGAR			
URINE SUGAR	Nil	-	
RESULT REMARKS :			

DR. MUKESH DUBEY
(MBBS. DCP) (DIRECTOR)

DR. VIJAY BHURIYA
MBBS DMRD

DR. YOGESH PAWDE
M. D. (CONS. PATHOLOGIST)

DR. P.S. TRIPATHI
M.D. (RADIO DIAGNOSIS)

DR. SANJAY YADAV
CON. MICROBIOLOGIST

Report Checked By :

Page 1 of 1



Triveni Diagnostic Centre

Reg No. : 73394 VISITID : O000077703
PATIENT NAME : Mr. PRASHANT KUMAR MOHANTY SPEC. NO : 1905400962
AGE/SEX : 45 YEARS/MALE SAMP. DATE : 24/06/2023 12:03:00
REF. BY : Dr. ARCOFEMI HEALTHCARE LIMITED RESULT DATE : 26/06/2023 09:03:00

NAME OF TEST	RESULT VALUE		REFERENCE RANGE	UNIT
	IN RANGE	OUT RANGE		

LFT (LIVER FUNCTION TEST)

TOTAL BILIRUBIN	0.75		0.2 - 1.3	mg/dL
DIRECT BILIRUBIN	0.41		0.2 - 0.65	mg / dl
INDIRECT BILIRUBIN	0.34		0.2 - 0.8	mg / dl
SGOT(AST)	18		0 - 40	U / L
SGPT(ALT)	14		0 - 40	U / L
ALKALINE PHOSPHATASE	85		37 - 143	U / L
PROTEINS	6.92		6 - 8.3	g / dl
ALBUMIN	4.40		3.5 - 5	gm/dl
GLOBULIN	2.52		1.9 - 3.5	g / dl
A.G.RATIO	1.74		0.5 - 2	mg / dl
PT (PROTHROMBIN TIME)		15	-	seconds
CONTROL		14	-	seconds
(INR) INTERNATIONALNARMLISED RATIO		1.07	-	seconds

REMARKS :

METHOD: BY COBAS INTEGRA 400 PLUS.

DR. MUKESH DUBEY
(MBBS, DCP) (DIRECTOR)

DR. VIJAY BHURIYA
MBBS DMRD

DR. YOGESH PAWDE
M. D. (CONS. PATHOLOGIST)

DR. P.S. TRIPATHI
M.D. (RADIO DIAGNOSIS)

DR. SANJAY YADAV
CON. MICROBIOLOGIST

Report Checked By :

Address : Agrawal Plaza, B-7, HIG Main Road, Indore Ph. : 0731-4289992-3
Website : www.trivenidiagnostic.com email : trivenidiagnostic@yahoo.co.in

Page 1 of 1



Triveni Diagnostic Centre

Reg No. : 73394
PATIENT NAME : Mr. PRASHANT KUMAR MOHANTY
AGE/SEX : 45 YEARS/MALE
REF. BY : Dr. ARCOFEMI HEALTHCARE LIMITED

VISITID : 0000077703
SPEC. NO : 1905400962
SAMP. DATE : 24/06/2023 12:03:00
RESULT DATE : 26/06/2023 09:00:53

IMMUNO ASSAY

NAME OF TEST	RESULT VALUE	REFERENCE RANGE	UNIT
PSA TOTAL PSA (TOTAL)	0.28	0-4 Normal 4-10 Borderline >10 High	ng/ml

RESULT REMARKS : Method by- Electro Chemiluminescence Assay Technology.
Note:
Normal PSA does not exclude prostatic carcinoma.
DISTRIBUTION OF PSA VALUES IN BPH AND PROSTATE CARCINOMA

PSA	BPH	CARCINOMA
0-4	74	7
4-10ng/ml	20	17
>10ng/ml	6	76

RENAL PROFILE			
UREA	21	10 - 40	mg / dl
CREATININE	0.79	0.7 - 1.4	mg / dl
SERUM SODIUM	142.1	135 - 155	mmol/L
SERUM POTASIUM	4.2	3.5 - 5.5	mmol/L

RESULT REMARKS :

DR. MUKESH DUBEY
(MBBS, DCP) (DIRECTOR)

DR. VIJAY BHURIYA
MBBS DMRD

DR. YOGESH PAWDE
M. D. (CONS. PATHOLOGIST)

DR. P.S. TRIPATHI
M.D. (RADIO DIAGNOSIS)

DR. SANJAY YADAV
CON. MICROBIOLOGIST

Report Checked By :

Address : Agrawal Plaza, B-7, HIG Main Road, Indore Ph. : 0731-4289992-3
Website : www.trivenidiagnostic.com email : trivenidiagnostic@yahoo.co.in

Page 1 of 1



Triveni Diagnostic Centre

Reg No. : 73394 VISITID : 0000077703
PATIENT NAME : Mr. PRASHANT KUMAR MOHANTY SPEC. NO : 1905400962
AGE/SEX : 45 YEARS/MALE SAMP. DATE : 24/06/2023 12:03:00
REF. BY : Dr. ARCOFEMI HEALTHCARE LIMITED RESULT DATE : 26/06/2023 08:59:39

IMMUNO ASSAY

T3, T4 TSH

NAME OF TEST	RESULT VALUE	REFERENCE RANGE	UNIT
T3 (TRIIODOTHYRONINE)	0.63	Adults:- 0.60-1.58 Children:- 0-3 days:- 0.96- 2.92 1-11 months 0.81-2.81 1-5 years 0.83-2.52 6-10 years 0.92-2.19 11-15years 0.83-2.15	ng/ml
T4 (THYROXINE)	5.5	Adults:- 5.01-11.0 Children:- 0-3 days 11.80-22.60 4-30 days not Established 1-2 weeks 9.80-16.60 1-4 months 7.20-14.40 4-12 months 7.80-16.50	ug/dl
TSH (THYROID STIMULATING HORMONE)	1.45	Adults:- 0.38-4.31 Children:- 0-3 days:- 1.0-39.0 4-30 days:- 0.43-16.1 2-12 months:- 0.62-8.05 2-6 years:- 0.54-4.53 7-11 years:- 0.66-4.14 12-19 years:- 0.53-3.59	uIU/ml

Method: By AIA-360 (TOSOH) fully automated electro chemiluminescence immunoassay

INTERPRETATION: Suppressed TSH values are seen in hyperthyroid patients with the exception of hyperthyroidism caused by a TSH producing pituitary tumors. In addition TSH is suppressed in individuals treated with the exogenous thyroid hormones. Elevated TSH values are seen in primary hypothyroidism with the exception of hypothyroidisms caused by pituitary disorders. Note: Total T3 and T4 values may also be altered in other conditions due to changes in serum proteins or binding sites pregnancy, drugs (Androgens, Estrogens, O C pills, Phenyton) nephrosis etc. In such cases free T3 and T4 give corrected values.

DR. MUKESH DUBEY
MBBS DCP (DIRECTOR)

DR. VIJAY BHURIYA
MBBS DMRD

DR. YOGESH PAWDE
M. D. (CONS. PATHOLOGIST)

DR. P.S. TRIPATHI
M.D. (RADIO DIAGNOSIS)

DR. SANJAY YADAV
CON. MICROBIOLOGIST

Report Checked By:

Address : Agrawal Plaza, B-7, HIG Main Road, Indore Ph. : 0731-4289992-3
Website : www.trivenidiagnostic.com email : trivenidiagnostic@yahoo.co.in



Triveni Diagnostic Centre

Reg No. : 73394 VISITID : 0000077703
PATIENT NAME : Mr. PRASHANT KUMAR MOHANTY SPEC. NO : 1905400963
AGE/SEX : 45 YEARS/MALE SAMP. DATE : 24/06/2023 12:03:00
REF. BY : Dr. ARCOFEMI HEALTHCARE LIMITED RESULT DATE : 26/06/2023 09:03:40

CLINICAL-PATHOLOGY

URINE EXAMINATION

NAME OF TEST	RESULT VALUE	REFERENCE RANGE	UNIT
<u>PHYSICAL EXAMINATION</u>			
QUANTITY	30	-	ml
COLOUR	Pale Yellow	-	
APPEARANCE	Clear	-	
REACTION	Acidic	-	
Specific Gravity	1.010	-	
<u>CHEMICAL EXAMINATION</u>			
ALBUMIN	Nil	-	
URINE SUGAR	Nil	-	
Ketone Bodies	Nil	-	
BLOOD	Nil	-	
Bile Pigment	Nil	-	
Bile Salts	Nil	-	
<u>MICROSCOPIC EXAMINATION</u>			
Pus Cells	2-3/hpf	2 - 5	/hpf
Epithelial Cells	1-2/hpf	5 - 10	
RBCs	Nil	-	/hpf
Casts	Nil	-	
Crystals	Nil	-	
Spermatozoa	Nil	-	
Bacteria	Nil	-	
Others		-	

DR. MUKESH DUBEY
(MBBS, DCP) (DIRECTOR)

DR. VIJAY BHURIYA
MBBS DMRD

DR. YOGESH PAWDE
M. D. (CONS. PATHOLOGIST)

DR. P.S. TRIPATHI
M.D. (RADIO DIAGNOSIS)

DR. SANJAY YADAV
CON. MICROBIOLOGIST

Report Checked By:

Address : Agrawal Plaza, B-7, HIG Main Road, Indore Ph. : 0731-4289992-3
Website : www.trivenidiagnostic.com email : trivenidiagnostic@yahoo.co.in

Page 1 of 1



Triveni Diagnostic Centre

Reg. No. : 73394 Visit ID : O000077703
Patient Name : Mr. PRASHANT KUMAR MOHANTY
Age / Sex : 45 YEARS / MALE Order Date : 24/06/23 11:41AM
Ref. By : Dr. ARCOFEMI HEALTHCARE LIMITED Report Date : 24/06/23 11:54AM

SONOGRAPHY

USG WHOLE ABDOMEN(MALE)

Liver is normal in size (13.4 cm), shape and echotexture. No focal parenchymal lesion noted. Portal vein is of normal caliber. There is no evidence of dilatation of Intra and extra hepatic biliary radicals.

Gall bladder appears normal. Does not show any sludge or calculus. Its walls are smooth and normal in wall thickness.

Pancreas is normal in size, shape and shows normal echogenicity, no localised solid or cystic mass is identified in pancreas. Pancreatic duct is not dilated.

Spleen is normal in size (11.2 cm), and shows normal echogenicity, no localised or cystic mass is identified in spleen.

Approx 11 mm size calculus is seen in the left lower ureter causing mild hydroureteronephrosis.

Few calculi seen in both kidney largest measuring 5.1 mm in left and 4.2 mm in right kidney.

Right renal PC system & proximal appears mildly dilated ? mid /lower ureteric calculus. (Lower ureter is not visualized in present scan due to gaseous artifacts).

Both kidneys are normal in size (Rt. 10.2 x 5.0 cm & Lt. 10.5 x 6.5 cm), shape and echotexture.

Visualised bowel loops appear normal.

No evidence of any adenopathy or ascitis.

Urinary bladder is adequately filled with anechoic contents. The wall appears thin with smooth mucosa.

Prostate appears normal in size , shape and echotexture.

IMPRESSION:-Left lower ureteric calculus causing mild hydroureteronephrosis.

Bilateral renal calculi.

Right mild hydronephrosis with proximal hydroureter ? mid/ lower ureteric calculus.

Advfollow up.

DR. MUKESH DUBEY

(MBBS, DCP)

DR. VIJAY BHURIYA

MBBS DMRD

DR. AMIT SHANKHWAR

M.D. RADIO DIAGNOSIS

DR. P.S. TRIPATHI

M.D. (RADIO DIAGNOSIS)

DR. SANJAY YADAV

CONSULTANT MICROBIOLOGIST

Note: This report is not valid for medico legal purpose.

Page 1 of 1

Address : Agrawal Plaza, B-7, HIG Main Road, Indore Ph. : 0731-4289992-3
Website : www.trivenidiagnostic.com email : trivenidiagnostic@yahoo.co.in



Triveni Diagnostic Centre

Name :- Mr. Prashant Kumar Mohanty

Age:- 45 Yrs / Male

Ref. By: -Dr . Health Check Up

Date: - 24/ 6 /2023

ECHOCARDIOGRAPHYREPORT


INTERPRETATION:- Normal 2-D Echo / Dopplar.

No LV RWMA seen.

LVEF IS 65%.

2 IMAGING M Mode examination revealed normal movement of both mitral leaflets during diastole. No SAM or mitral valve prolapsed is seen. Aortic cups are normal and enclosure line is central. Tricuspid valve is normal. Pulmonary valve is normal. Aortic root is normal in size. Dimension of left atrium and left ventricles are normal.

3. Dimaging in PLAX.SAX and apical views revealed a normal left ventricle. Movement of septum anterior, posterior, inferior and lateral walls is normal. Global LVEF 65%, mitral valve opening is normal. No evidence of mitral valve prolapsed is seen. Aortic valve has three cups and its opening is not restricted. Right atrium & right ventricle are normal sized. Tricuspid valve leaflets move normally. Pulmonary valve is normal. Interatrial and intraventricular septa are intact. No intracardiac mass or thrombus is seen. No pericardial pathology is observed.


Dr. Rahul Talati
MBBS MD
Cardiologist

Valve

Aortic root diameter	2.9cms	2.0-3.7cm<2.2cm/M2
Aortic valve opening	1.8cms	1.5-2.6cm
Right ventricular dimension	2.1cms	0.7-2.5cm<2.2cm/M2
Left atrium dimension	3.4cms	1.9-4.0cm<2.2cm/M2

Left ventricular ED dimension	4.4cms	3.7-5.6cm<3.2cm/M2
Left ventricular ES dimension	2.7cms	2.2-4.0cm
Intraventricular ED septal thickness	1.1cms	0.6-1.2 cm
Left vent ED PW thickness	1.1cms	0.5- 1.0 cm
IVS/LVPW	<N	<1.3

INDICES OF LEFT VENTRICLE FUNCTION:

Mitral E – septal separation	.5	cms <0.9 cm
LV Ejection Fraction	65%	60 %- 80%

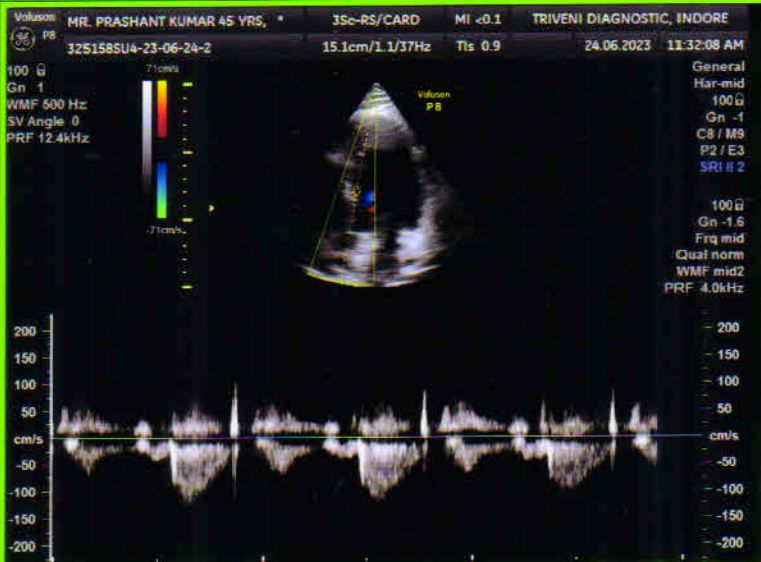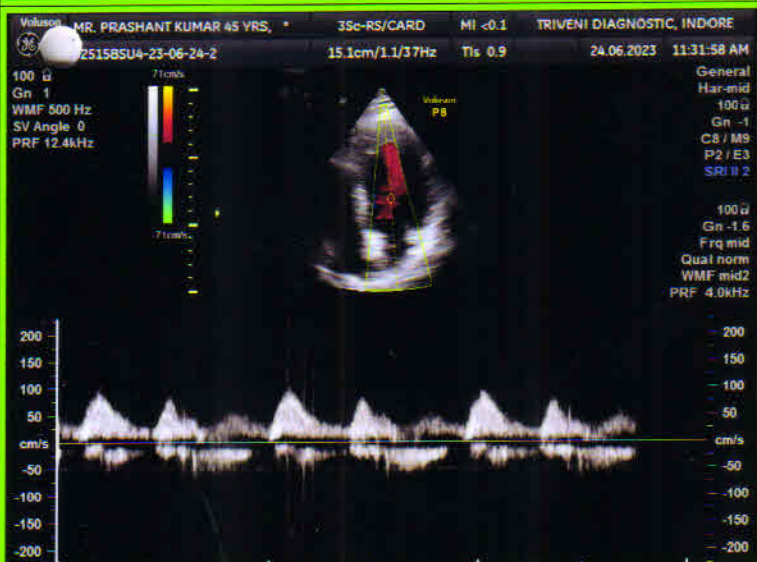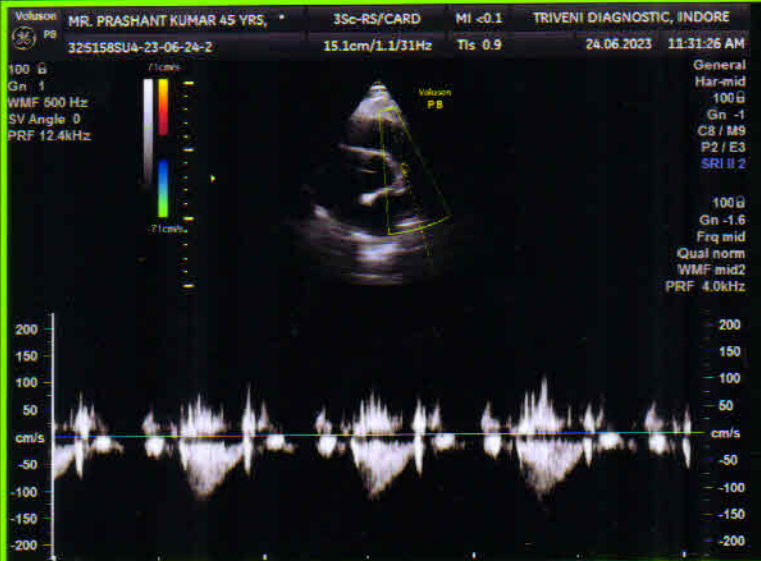
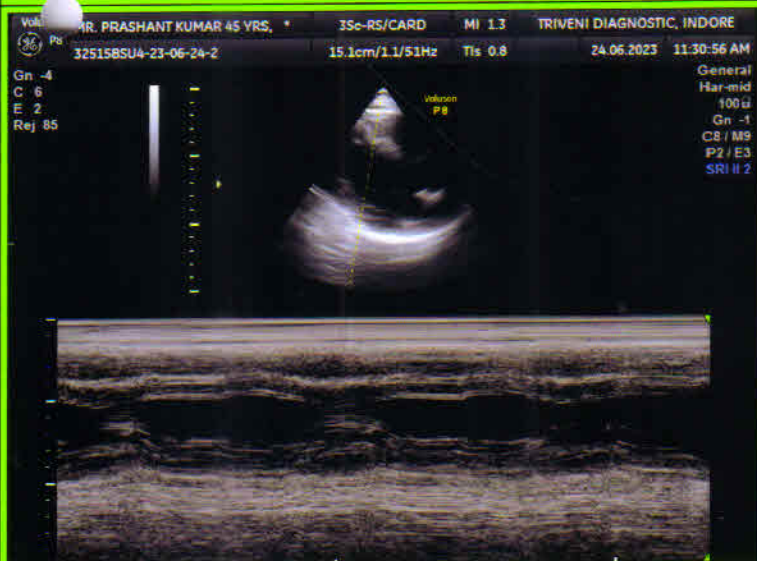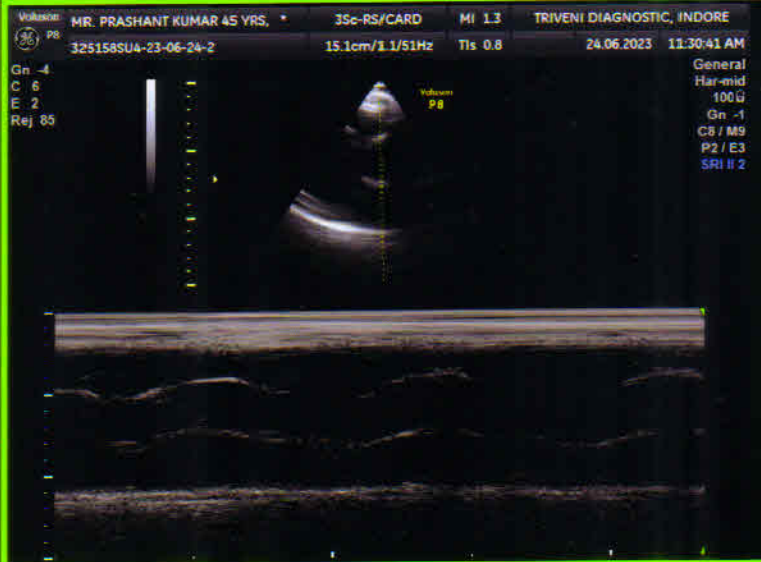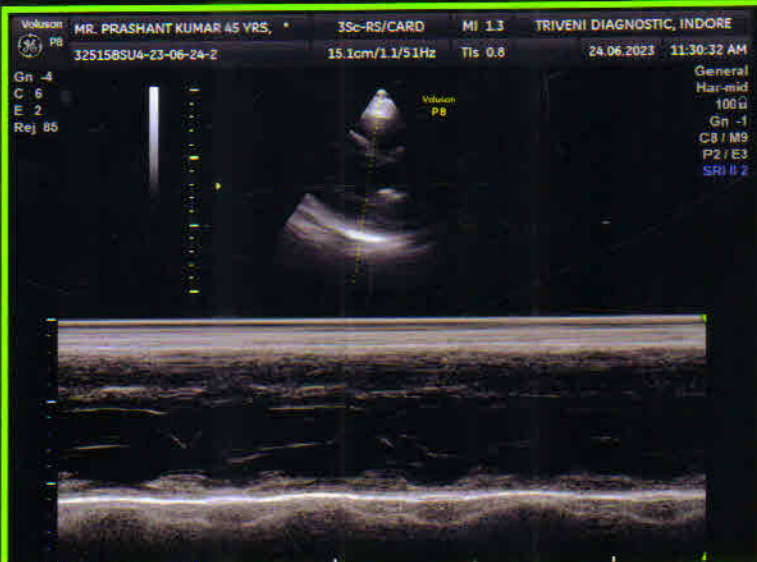
COLOR DOPPER

	PV(m/sec)	PG(mm of Hg)	Regurgitation
AV	1.3	6.2	NIL
MV	0.8	2.75	NIL
TV	N	N	NIL
PV	1	4	NIL

TRIVENI DIAGNOSTI & RESEARCH CENTER

2023

MR. PRASHANT KUMAR 45 YRS / M





Triveni Diagnostic Centre

Reg. No. : 73394 Visit ID : 0000077703
Patient Name : Mr. PRASHANT KUMAR MOHANTY
Age / Sex : 45 YEARS / MALE Order Date : 24/06/23 11:41AM
Ref. By : Dr. ARCOFEMI HEALTHCARE LIMITED Report Date : 24/06/23 11:51AM

X-RAY X-RAY CHEST PA

Trachea is central.

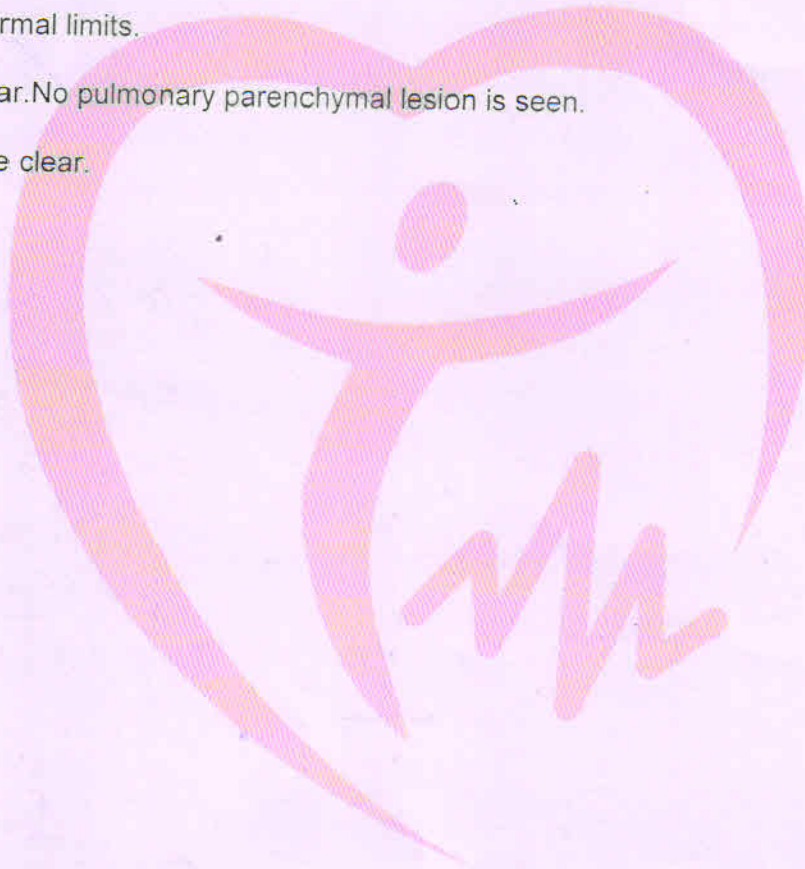
Bony rib cage and soft tissue wall of the thorax are normal.

Cardiac size is within normal limits.

Both lungs fields are clear.No pulmonary parenchymal lesion is seen.

Costo-phrenic angles are clear.

Kindly correlate.



DR. MUKESH DUBEY
(MBBS, DCP)


DR. VIJAY BHURIYA
MBBS DMRD

DR. AMIT SHANKHWAR
M.D. RADIO DIAGNOSIS

DR. P.S. TRIPATHI
M.D. (RADIO DIAGNOSIS)

DR. SANJAY YADAV
CONSULTANT MICROBIOLOGIST

Note: This report is not valid for medico legal purpose.

Address : Agrawal Plaza, B-7, HIG Main Road, Indore Ph. : 0731-4289992-3
Website : www.trivenidiagnostic.com email : trivenidiagnostic@yahoo.co.in

Page 1 of 1



Triveni Diagnostic Centre

Reg. No. : 73394 Visit ID : 000077703
Patient Name : Mr. PRASHANT KUMAR MOHANTY
Age / Sex : 45 YEARS / MALE Order Date : 24/06/23 11:41AM
Ref. By : Dr. ARCOFEMI HEALTHCARE LIMITED Report Date : 24/06/23 11:51AM

X-RAY X-RAY CHEST PA

Trachea is central.

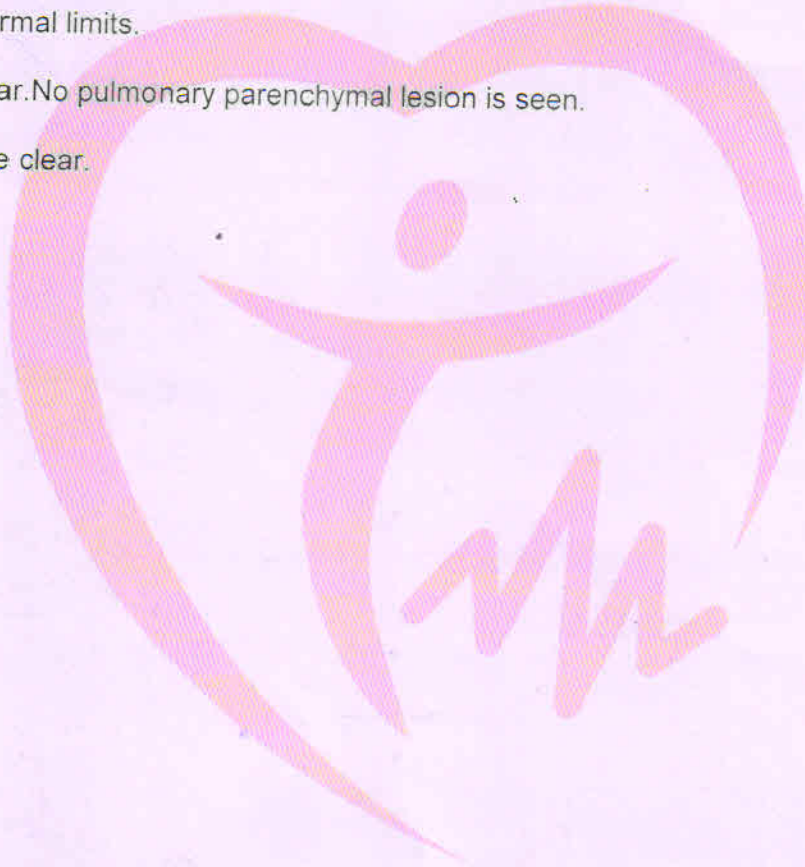
Bony rib cage and soft tissue wall of the thorax are normal.

Cardiac size is within normal limits.

Both lungs fields are clear.No pulmonary parenchymal lesion is seen.

Costo-phrenic angles are clear.

Kindly correlate.



DR. MUKESH DUBEY
(MBBS, DCP)

DR. VIJAY BHURIYA
MBBS DMRD

DR. AMIT SHANKHWAR
M.D. RADIO DIAGNOSIS

DR. P.S. TRIPATHI
M.D. (RADIO DIAGNOSIS)

DR. SANJAY YADAV
CONSULTANT MICROBIOLOGIST

Note: This report is not valid for medico legal purpose.

Address : Agrawal Plaza, B-7, HIG Main Road, Indore Ph. : 0731-4289992-3
Website : www.trivenidiagnostic.com email : trivenidiagnostic@yahoo.co.in

Page 1 of 1