

Patient Name : Mr.AKSHAY TAKKAR	Collected : 23/Oct/2024 08:46AM
Age/Gender : 30 Y 0 M 1 D/M	Received : 23/Oct/2024 01:25PM
UHID/MR No : CJPN.0000098621	Reported : 23/Oct/2024 01:48PM
Visit ID : CJPNOPV210373	Status : Final Report
Ref Doctor : Self	Sponsor Name : ARCOFEMI HEALTHCARE LIMITED
Emp/Auth/TPA ID : 9920144559	

DEPARTMENT OF BIOCHEMISTRY

ARCOFEMI - MEDIWHEEL - PMC PACK H - PAN INDIA - FY2324

Test Name	Result	Unit	Bio. Ref. Interval	Method
GLUCOSE, FASTING , NAF PLASMA	120	mg/dL	70-100	HEXOKINASE


Comment:

As per American Diabetes Guidelines, 2023

Fasting Glucose Values in mg/dL	Interpretation
70-100 mg/dL	Normal
100-125 mg/dL	Prediabetes
≥126 mg/dL	Diabetes
<70 mg/dL	Hypoglycemia

Note:

- 1.The diagnosis of Diabetes requires a fasting plasma glucose of > or = 126 mg/dL and/or a random / 2 hr post glucose value of > or = 200 mg/dL on at least 2 occasions.
2. Very high glucose levels (>450 mg/dL in adults) may result in Diabetic Ketoacidosis & is considered critical.


Dr Priya Murthy
 M.B.B.S.,M.D(Pathology)
 Consultant Pathologist




Patient Name : Mr.AKSHAY TAKKAR	Collected : 23/Oct/2024 08:46AM
Age/Gender : 30 Y O M 1 D/M	Received : 23/Oct/2024 12:37PM
UHID/MR No : CJPN.0000098621	Reported : 23/Oct/2024 01:04PM
Visit ID : CJPNOPV210373	Status : Final Report
Ref Doctor : Self	Sponsor Name : ARCOFEMI HEALTHCARE LIMITED
Emp/Auth/TPA ID : 9920144559	

DEPARTMENT OF BIOCHEMISTRY

ARCOFEMI - MEDIWHEEL - PMC PACK H - PAN INDIA - FY2324

Test Name	Result	Unit	Bio. Ref. Interval	Method
ALANINE AMINOTRANSFERASE (ALT/SGPT) , SERUM	31	U/L	<50	IFCC



Dr Priya Murthy
M.B.B.S.,M.D(Pathology)
Consultant Pathologist



Patient Name : Mr.AKSHAY TAKKAR	Collected : 23/Oct/2024 08:46AM
Age/Gender : 30 Y O M 1 D/M	Received : 23/Oct/2024 01:02PM
UHID/MR No : CJPN.0000098621	Reported : 23/Oct/2024 01:36PM
Visit ID : CJPNOPV210373	Status : Final Report
Ref Doctor : Self	Sponsor Name : ARCOFEMI HEALTHCARE LIMITED
Emp/Auth/TPA ID : 9920144559	


DEPARTMENT OF CLINICAL PATHOLOGY

ARCOFEMI - MEDIWHEEL - PMC PACK H - PAN INDIA - FY2324

Test Name	Result	Unit	Bio. Ref. Interval	Method
COMPLETE URINE EXAMINATION (CUE) , URINE				
PHYSICAL EXAMINATION				
COLOUR	AMBER		PALE YELLOW	Scattering of light
TRANSPARENCY	Clear		CLEAR	Scattering of light
pH	5.0		5-7.5	Bromothymol Blue
SP. GRAVITY	1.022		1.002-1.030	Bromothymol Blue
BIOCHEMICAL EXAMINATION				
URINE PROTEIN	NEGATIVE		NEGATIVE	PROTEIN ERROR OF INDICATOR
GLUCOSE	NEGATIVE		NEGATIVE	GOD-POD
URINE BILIRUBIN	NEGATIVE		NEGATIVE	Diazonium Salt
URINE KETONES (RANDOM)	NEGATIVE		NEGATIVE	Sodium nitro prusside
UROBILINOGEN	NORMAL		NORMAL (0.1-1.8mg/dl)	Diazonium salt
NITRITE	NEGATIVE		NEGATIVE	Sulfanilic acid
LEUCOCYTE ESTERASE	NEGATIVE		NEGATIVE	Diazonium salt
CENTRIFUGED SEDIMENT WET MOUNT AND MICROSCOPY				
PUS CELLS	3	/hpf	0-5	Automated Image based microscopy
EPITHELIAL CELLS	0	/hpf	< 10	Automated Image based microscopy
RBC	0	/hpf	0-2	Automated Image based microscopy
CASTS	NEGATIVE	/lpf	0-2 Hyaline Cast	Automated Image based microscopy
CRYSTALS	NEGATIVE	/hpf	Occasional-Few	Automated Image based microscopy

Comment:

All urine samples are checked for adequacy and suitability before examination. All abnormal chemical examination are rechecked and verified by manual methods. Microscopy findings are reported as an average of 10 high power fields.


Dr. Rajalakshmi D
M.B.B.S,M.D
Consultant Pathologist


Dr. Vidya Aniket Gore
M.B.B.S,M.D(Pathology)
Consultant Pathologist



Patient Name	: Mr. Akshay Takkar	Age	: 30Yrs 2Days
UHID	: C.JPN.0000098621	OP Visit No.	: C.JPNOPV210373
Printed On	: 23-10-2024 10:00 AM	Advised/Pres Doctor	: --
Department	: Cardiology	Qualification	: --
Referred By	: Self	Registration No.	: --
Employeer Id	: 9920144559		

DEPARTMENT OF CARDIOLOGY

ECG

Observation :-

1. Normal Sinus Rhythm.
2. Heart rate is 72 beats per minutes.
3. No pathological Q wave or ST-T changes seen.
4. Normal P,QRS,T waves and axis.
5. No evidence of chamber, hypertrophy or enlargement seen.

Impression:

NORMAL RESTING ECG.

---End Of The Report---

Dr. SHIVAKUMAR M P
MBBS MD
24348
Cardiology

Name : Mr. Akshay Takkar

Age : 30Y 0M 1D

UHID : CJPN.0000098621

Address : J P Nagar Bangalore Karnataka INDIA 560078

sex : Male



CJPN.0000098621

Plan : ARCOFEMI MEDIWHEEL PMC CREDIT PAN
INDIA OP AGREEMENT

OP No: CJPNOPV210373

Bill No: CJPN-OCR-75593

Date: Oct 23rd, 2024, 8:42 AM

Sno.	Service Type/Service Name	Department	
1	ARCOFEMI - MEDIWHEEL - PMC PACK H - PAN INDIA - FY2324		
✓1	COMPLETE URINE EXAMINATION	Clinical Pathology	<input type="checkbox"/>
✓2	BILIRUBIN, TOTAL - SERUM	Biochemistry	<input type="checkbox"/>
✓3	ALANINE AMINOTRANSFERASE (ALT/SGPT), SERUM	Biochemistry	<input type="checkbox"/>
✓4	FITNESS BY GENERAL PHYSICIAN	Consultation	<input type="checkbox"/>
✓5	X-RAY CHEST PA	X Ray Radiology	<input type="checkbox"/>
✓6	BLOOD GROUP ABO AND RH FACTOR	Blood Bank	<input type="checkbox"/>
✓7	ECG	Cardiology	<input type="checkbox"/>
✓8	CREATININE, SERUM	Biochemistry	<input type="checkbox"/>
✓9	BUN/CREATININE RATIO	Biochemistry	<input type="checkbox"/>
10	GLUCOSE, POST PRANDIAL (PP), 2 HOURS (POST MEAL) 11.05 AM	Biochemistry	<input type="checkbox"/>
✓11	GLUCOSE, FASTING	Biochemistry	<input type="checkbox"/>
✓12	OPHTHAL BY GENERAL PHYSICIAN - Grant	Consultation	<input type="checkbox"/>
✓13	HEMOGRAM + PERIPHERAL SMEAR	Haematology	<input type="checkbox"/>
✓14	PERIPHERAL SMEAR	Haematology	<input type="checkbox"/>

✓ Physio - 04.

✓ Radio - 27.

✓ Dental - 15

✓ Diet - 18.

BP . 133/84 mmHg

PR . 68 b/m

Height . 175cm

Weight . 95.2kg

IL No. : KA03 20190005020
NAME : AKSHAY THAKKAR
D.O.B : 22/06/1994
VALID TILL : 11/03/2039(NT)



DOI : 12/03/2019
B.G. :

FORM - 7
(See Rule 10(2))

VALID THROUGHOUT INDIA
COV: MCWG 12/03/2019

COV: 12-03-2019

Signature : PRAMOD THAKKAR
ADDRESS : NO 12 4TH CROSS 5TH MAIN
ROADSAMPANGIRAM NAGAR WILSON
GARDEN BANGALORE,KA 560027



Signature

gn. Of Holder

Signature
Sign. Licencing Authority
BENGALURU(E)

ಕರ್ನಾಟಕ ರಾಜ್ಯ ಕರ್ನಾಟಕಾ ಸ್ಟೇಟ್

INDIAN UNION MOTOR DRIVING LICENCE



ಪಾರಿಷತ್
TRANSPORT DEPARTMENT

Name: Akshay Kumar

Age: 30

Height :	Weight :	BMI :	Waist Circum :
Temp :	Pulse :	Resp :	B.P :

General Examination / Allergies History

Clinical Diagnosis & Management Plan

Normal

Un: 6/c No

m: 2/c No

Colour vision test normal

RE plano 6/c
LE plano 6/c

Ref: normal No.

Follow up date:

After 6 months



Doctor Signature

CERTIFICATE OF MEDICAL FITNESS

This is to certify that I have conducted the clinical examination
of Mr. May Talwar on 23/10/24 ^{3:00 pm}

After reviewing the medical history and on clinical examination it has been found that he/she is

	Tick
<ul style="list-style-type: none"> • Medically Fit ✓ 	✓
<ul style="list-style-type: none"> • Fit with restrictions/recommendations <p>Though following restrictions have been revealed, in my opinion, these are not impediments to the job.</p> <p>1.....</p> <p>2.....</p> <p>3.....</p> <p>However the employee should follow the advice/medication that has been communicated to him/her.</p> <p>Review after _____</p>	
<ul style="list-style-type: none"> • Currently Unfit. <p>Review after _____ recommended</p>	
<ul style="list-style-type: none"> • Unfit 	

Dr. M.P. Shiva Kumar
M.B.S., M.D (GEN. MED.), FRD
 Consultant - Physician & Di
 Mob : 9759533913, 9902957039
 KMC - 24344


Medical Officer

This certificate is not meant for medico-legal purposes

Patient Name	: Mr. Akshay Takkar	Age	: 30Yrs 1Days
UHID	: CJP.N.0000098621	OP Visit No.	: CJPNOPV210373
Printed On	: 23-10-2024 10:43 AM	Advised/Pres Doctor	: --
Department	: Radiology	Qualification	: --
Referred By	: Self	Registration No.	: --
Employee Id	: 9920144559		

DEPARTMENT OF RADIOLOGY

X-RAY CHEST PA VIEW

Lung fields are clear.

Cardio thoracic ratio is normal.

Apices, costo and cardio phrenic angles are free.

Cardio vascular shadow and hila show no abnormal feature.

Bony thorax shows no significant abnormality.

Domes of diaphragm are well delineated.

IMPRESSION: NO SIGNIFICANT ABNORMALITY DETECTED.

---End Of The Report---



Dr. ABID HUSSAIN GULLENPET
MBBS, DMRD, FRCR
26066
Radiology

Mr akshay
ID: cjpns621

30 Years 175 in Male
95.0 lb

23.10.2024 9:10:20

Apollo Clinic
J.P. Nagar
Bangalore

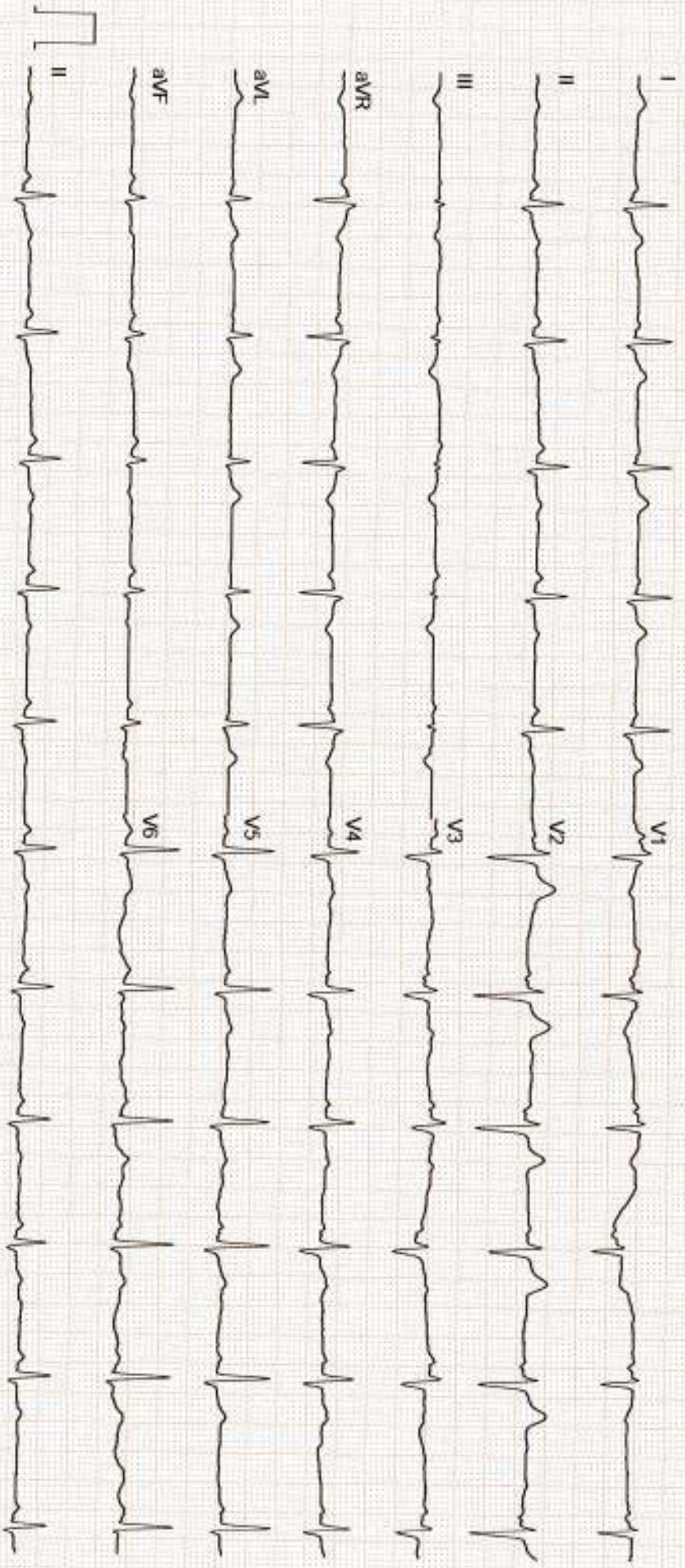
Aravind CC

67 bpm
133 / 84 mmHg

QRS	92 ms
QT / QTcBaz	358 / 378 ms
PR	130 ms
P	102 ms
RR / PP	894 / 895 ms
P / QRS / T	60 / 25 / 0 degrees

Normal sinus rhythm
Normal ECG

WNL

GE MAC2000 1-1 12SL™ V241

25 mm/s 10 mm/mV

ADS 0.56-20 Hz 50 Hz 2x5x6_25_R1

Unconfirmed