

CID# : 2208525584 SID# : 177805060832
Name : MRS.SAROJ JAIN Registered : 26-Mar-2022 / 09:49
Age / Gender : 34 Years/Female Collected : 26-Mar-2022 / 09:49
Consulting Dr. : - Reported : 27-Mar-2022 / 08:50
Reg.Location : Kandivali East (Main Centre) Printed : 28-Mar-2022 / 10:09

PHYSICAL EXAMINATION REPORT

History and Complaints:

Hypothyroid since 2 yrs.

EXAMINATION FINDINGS:

Height (cms):	154 cms	Weight (kg):	57 kgs
Temp (0c):	Afebrile	Skin:	Normal
Blood Pressure (mm/hg):	110/70	Nails:	Normal
Pulse:	72/min	Lymph Node:	Not palpable

Systems

Cardiovascular: Normal
Respiratory: Normal
Genitourinary: Normal
GI System: Normal
CNS: Normal

IMPRESSION:

*wbc - 6-8 pus cells
TSH 6.48*

ADVICE:

*lots of liquids
Endocrinologist opinion*

CID# : 2208525584 SID# : 177805060832
Name : MRS.SAROJ JAIN Registered : 26-Mar-2022 / 09:49
Age / Gender : 34 Years/Female Collected : 26-Mar-2022 / 09:49
Consulting Dr. : - Reported : 27-Mar-2022 / 08:50
Reg.Location : Kandivali East (Main Centre) Printed : 28-Mar-2022 / 10:09

CHIEF COMPLAINTS:

- | | |
|--|-----|
| 1) Hypertension: | No |
| 2) IHD | No |
| 3) Arrhythmia | No |
| 4) Diabetes Mellitus | No |
| 5) Tuberculosis | No |
| 6) Asthama | No |
| 7) Pulmonary Disease | No |
| 8) Thyroid/ Endocrine disorders | Yes |
| 9) Nervous disorders | No |
| 10) GI system | No |
| 11) Genital urinary disorder | No |
| 12) Rheumatic joint diseases or symptoms | No |
| 13) Blood disease or disorder | No |
| 14) Cancer/lump growth/cyst | No |
| 15) Congenital disease | No |
| 16) Surgeries | No |
| 17) Musculoskeletal System | No |

PERSONAL HISTORY:

- | | |
|---------------|-----|
| 1) Alcohol | No |
| 2) Smoking | No |
| 3) Diet | Veg |
| 4) Medication | Yes |

*** End Of Report ***

SUBURBAN DIAGNOSTICS (INDIA) PVT. LTD.
Row House No. 3, Aangan,
Thakur Vkiage, Kandivali (east),
Mumbai - 400101.
Tel : 61700000


Dr. Jagruti Dhale
MBBS
Consultant Physician
Reg. No. 69548

ADDRESS: 2nd Floor, Aston, Sundervan Complex, Above Mercedes Showroom, Andheri West - 400053

HEALTHLINE - MUMBAI: 022-6170-0000 | **OTHER CITIES:** 1800-266-4343

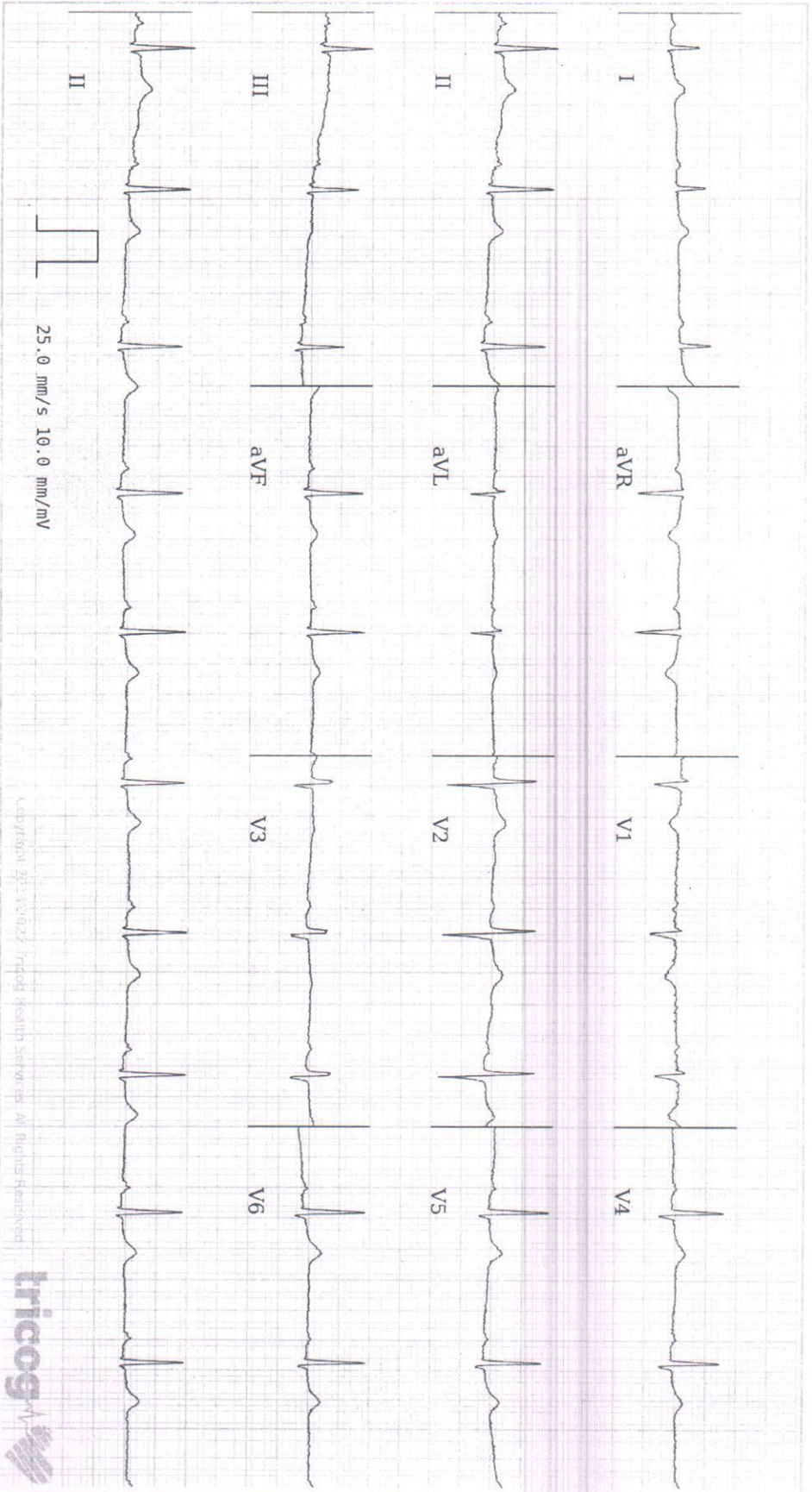
Page:2 of 2

For Feedback - customerservice@suburbandiagnosics.com | **www.suburbandiagnosics.com**

SUBURBAN DIAGNOSTICS - KANDIVALI EAST

Patient Name: SAROJ JAIN
Patient ID: 2208525584

Date and Time: 26th Mar 22 12:46 PM



Age 34 6 17
years months days

Gender Female

Heart Rate 63bpm

Patient Vitals

BP: 110/70 mmHg

Weight: 57 kg

Height: 154 cm

Pulse: NA

Spo2: NA

Resp: NA

Others:

Measurements

OSRD: 78ms

QT: 400ms

QTc: 409ms

PR: 172ms

P-R-T: 52° 69° 41°

ECG Within Normal Limits: Sinus Rhythm, Normal Axis. Please correlate clinically.

SUBURBAN DIAGNOSTICS (INDIA) PVT. LTD.

Row House No. 3, Aangan,
Thakur Village, Kandivali (east),
Mumbai - 400101.

Tel : 61700000

DR AKHIL PARULEKAR

MBBS, MD, MEDICINE, DNB Cardiology

Cardiologist
2012082483

Copyright ©: 2022 Tricog Health Services. All Rights Reserved



Disclaimer: 1) Analysis in this report is based on ECG alone and should be used as an adjunct to clinical history, symptoms, and results of other invasive and non-invasive tests and must be interpreted by a qualified physician. 2) Patient vitals are as entered by the technician and not derived from the ECG.

DENTAL CHECK - UP

Name:- *Saroj Jain*

CID : *2208525584* Sex / Age : *F / 34*

Occupation:-

Date: *26/3/2022*

Chief complaints:- *NO complaints*

Medical / dental history:- *NO relevant history*

GENERAL EXAMINATION:

1) Extra Oral Examination:

- a) TMJ: *Normal movements*
- b) Facial Symmetry: *Bilateral asymmetries*

2) Intra Oral Examination:

- a) Soft Tissue Examination: *Normal*
- b) Hard Tissue Examination: *a) mild attrition seen*
- c) Calculus: *+*
- Stains: *+* b) *fts Evaluate on O.P.G (xray)*

18	17	16	15	14	13	12	11	21	22	23	24	25	26	27	28
48	47	46	45	44	43	42	41	31	32	33	34	35	36	37	38

	Missing	#	Fractured
○	Filled/Restored	RCT	Root Canal Treatment
○	Cavity/Caries	RP	Root Piece

Advised: *a) Scaling & Polishing [cleaning]*

DR. BHUMIK PATEL
(B.D.S) A - 23378

Provisional Diagnosis: *- NIL*
SUBURBAN DIAGNOSTICS (INDIA) PVT. LTD.
Row House No. 3, Aangan,
Thakur Village, Kandivali (east),
Mumbai - 400101.
Tel : 61700000

DR. Bhumik Patel
[Signature]

ADDRESS: 2nd Floor, Aston, Sundervan Complex, Above Mercedes Showroom, Andheri West - 400053

HEALTHLINE - MUMBAI: 022-6170-0000 | OTHER CITIES: 1800-266-4343

For Feedback - customerservice@suburbandiagnosics.com | www.suburbandiagnosics.com

Date: 26/3/22

CID: 2208525584

Name: Mrs Saroj Jain

Sex/Age: F/34

EYE CHECK UP

Chief complaints: Routine checkup

Systemic Diseases: TSH 002 yrs

Past history: no H/O Ocular surgery

Unaided Vision: 6/6 6/6P

Aided Vision: - -

Refraction: Emmb. Normal

	(Right Eye)				(Left Eye)			
	Sph	Cyl	Axis	Vn	Sph	Cyl	Axis	Vn
Distance	-Plane →			6/6	±	0.50	180	6/6
Near				1/6				2/6

Colour Vision: Normal / Abnormal

Remark: Vn within normal limit

Kajal H.
KAJAL NAGRECHA
 OPTOMETRIST

SUBURBAN DIAGNOSTICS (INDIA) PVT. LTD.
 Row House No. 3, Aangan,
 Thakur Village, Kandivali (east),
 Mumbai - 400101.
 Tel : 61700000

ADDRESS: 2nd Floor, Aston, Sundervan Complex, Above Mercedes Showroom, Andheri West - 400053

HEALTHLINE - MUMBAI: 022-6170-0000 | OTHER CITIES: 1800-266-4343

For Feedback - customerservice@suburbandiagnosics.com | www.suburbandiagnosics.com

CID#	: 2208525584	SID#	: 177805060832
Name	: MRS.SAROJ JAIN	Registered	: 26-Mar-2022 / 09:49
Age / Gender	: 34 Years/Female	Collected	: 26-Mar-2022 / 09:49
Consulting Dr.	: -	Reported	: 26-Mar-2022 / 12:48
Reg.Location	: Kandivali East (Main Centre)	Printed	: 26-Mar-2022 / 15:19

X-RAY CHEST PA VIEW

The lung fields are clear with no parenchymal lesion.

The cardiothoracic ratio is maintained and the cardiac outline is normal

The domes of the diaphragm are normal.

The cardio and costophrenic angles are clear.

Bony thorax is normal.

IMPRESSION:

No significant abnormality detected.

*** End Of Report ***

Khilji F.R.A

Dr.Faizur Khilji
MBBS, Consultant Radiologist

ADDRESS: 2nd Floor, Aston, Sundervan Complex, Above Mercedes Showroom, Andheri West - 400053

HEALTHLINE - MUMBAI: 022-6170-0000 | **OTHER CITIES:** 1800-266-4343

For Feedback - customerservice@suburbandiagnosics.com | www.suburbandiagnosics.com

CID#	: 2208525584	SID#	: 177805060832
Name	: MRS.SAROJ JAIN	Registered	: 26-Mar-2022 / 09:49
Age / Gender	: 34 Years/Female	Collected	: 26-Mar-2022 / 09:49
Consulting Dr.	: -	Reported	: 26-Mar-2022 / 18:13
Reg.Location	: Kandivali East (Main Centre)	Printed	: 26-Mar-2022 / 18:17

USG WHOLE ABDOMEN

LIVER :

The liver is normal in size (12.2 cm), shape and smooth margins. It shows normal parenchymal echo pattern. The intra hepatic biliary and portal radical appear normal. No evidence of any intra hepatic cystic or solid lesion seen. The main portal vein and CBD appears normal.

GALL BLADDER :

The gall bladder is physiologically distended and appears normal. No evidence of gall stones or mass lesions seen

PANCREAS :

The pancreas head, body and partial tail is visualised and appears normal. No evidence of solid or cystic mass lesion. Rest of the pancreas is obscured due to bowel gas shadows.

KIDNEYS :

Both the kidneys are normal in size, shape and echotexture.
No evidence of any calculus, hydronephrosis or mass lesion seen.
Right kidney measures 9.2 x 4.1 cm.
Left kidney measures 9.9 x 5.0 cm.

SPLEEN :

The spleen is normal in size (10.1 cm) and echotexture.No evidence of focal lesion is noted.
There is no evidence of any lymphadenopathy or ascites.

URINARY BLADDER :

The urinary bladder is well distended and reveal no intraluminal abnormality.

UTERUS (TAS):

The uterus is retroverted and appears normal. It measures 6.3 x 4.1 x 4.8 cm in size.
The endometrial thickness is 9.3 mm.

ADDRESS: 2nd Floor, Aston, Sundervan Complex, Above Mercedes Showroom, Andheri West - 400053

HEALTHLINE - MUMBAI: 022-6170-0000 | **OTHER CITIES:** 1800-266-4343

For Feedback - customerservice@suburbandiagnosics.com | www.suburbandiagnosics.com

CID#	: 2208525584	SID#	: 177805060832
Name	: MRS.SAROJ JAIN	Registered	: 26-Mar-2022 / 09:49
Age / Gender	: 34 Years/Female	Collected	: 26-Mar-2022 / 09:49
Consulting Dr.	: -	Reported	: 26-Mar-2022 / 18:13
Reg.Location	: Kandivali East (Main Centre)	Printed	: 26-Mar-2022 / 18:17

OVARIES (TAS):

Both the ovaries are well visualised and appears normal.
There is no evidence of any ovarian or adnexal mass seen.
Right ovary = 2.8 x 2.6 x 1.3 cms (Volume is 4.9 cc).
Left ovary = 2.6 x 2.8 x 2.0 cms (Volume is 7.5 cc).
Dominant follicle is noted in right ovary measuring 18 mm.

IMPRESSION :

No significant abnormality is seen.

Suggestion: Clinicopathological correlation.

Note: Investigations have their limitations. Solitary radiological investigations never confirm the final diagnosis. They only help in diagnosing the disease in correlation to clinical symptoms and other related tests. USG is known to have inter-observer variations. Further / Follow-up imaging may be needed in some cases for confirmation / exclusion of diagnosis. Patient was explained in detail verbally about the USG findings, USG measurements and its limitations. In case of any typographical error in the report, patient is requested to immediately contact the centre for rectification. Please interpret accordingly. All safety precautions were taken before, during and after the USG examination in view of the ongoing Covid 19 pandemic.

*** End Of Report ***



DR.VIVEK SINGH
MD.RADIO-DIAGNOSIS
RADIOLOGIST

ADDRESS: 2nd Floor, Aston, Sundervan Complex, Above Mercedes Showroom, Andheri West - 400053

HEALTHLINE - MUMBAI: 022-6170-0000 | **OTHER CITIES:** 1800-266-4343

For Feedback - customerservice@suburbandiagnosics.com | www.suburbandiagnosics.com