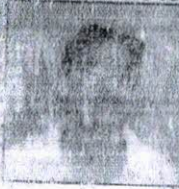



...ent-National Capital Territory of Delhi  
 licence to drive vehicles throughout India



LICENCE NO : P07072005346755 N  
 NAME : YASHPAL SINGH  
 Son of : SH BHOPAL SINGH  
 ADDRESS : F-253 POCKET-1 PH-I  
 MAYUR VIHAR-I  
 DELHI 110091  
 DT. OF BIRTH : 20/12/1983  
 VEHICLE CLASS : MCYL 15/07/2005  
 LMV(NT) 15/07/2005

*Yashpal Singh*  
 (Holder's Signature)  
 DT. OF ISSUE : 15/07/2005  
 VALIDITY : 14/07/2025  
 P.NO. : NA

  
 Sign. Of Licensing Authority

*Signature*

Dr. NITIN AGARWAL  
MBBS, MD  
Regn. No. DMC R-1436



*Yashpal Singh*

ONEPLUS  
47, Har...  
Ph. 011-42480101 955-913951  
E-mail: oneplusul@gmail.com



Dr. NITIN AGARWAL  
MBBS, MD  
Regn. No. DMC-R-1436

Yashpal

ONEPLUS ULTRA 2014 HAS  
47, Harsh Vihar, Gurgaon  
Delhi 122002  
Ph: 011-42991234  
E-mail: [oneplus@oneplus.com](mailto:oneplus@oneplus.com)

12-12-2021

One Plus Ultrasound Lab

Harsh Vihar, Pitampura

Subject - <sup>Unable to per do</sup>  
Stool Routine test

Sir,

This is to inform you that I (YASHPAL SINGH)  
with booking Ref no. - 21D97071100005274E cannot undergo  
Stool Routine test due to stomach pain & I can't visit  
to bang here. So request you to kindly exempt this  
test from Annual Health checkup for me.

Regards

YASHPAL SINGH

(Bank of Baroda  
Emp Code - 94071)

(Yashpal Singh)



Dr. NITISH AGARWAL  
MBBS, MD  
Regn. No. DMC-R-1436

ONEPLUS ULTRASOUND LAB  
47, Harsh Vihar, Pitampura,  
Delhi-110034  
Ph. 011-42090000, 011-42090051  
E-mail: oneplus@oneplus.com



**OnePLUS**  
Ultrasound Lab  
— QUALITY FIRST... ALWAYS! —

**Dr. Nitin Agarwal**  
Pathologist & Director  
Ex. Sr. Res. MAMC  
& Lok Nayak Hospital  
Ex. Chief of Lab Dr. Lal Path Labs.


**Dr. Pooja (Garg) Agarwal**  
Radiologist & Director  
MAMC & Lok Nayak Hospital

<b>Name</b>	: Mr. YASHPAL SINGH	<b>Age/Sex</b>	: 37 YRS/Male
<b>Ref. By</b>	: Dr. MEDIWHEEL	<b>Lab No</b>	: 012112120007
<b>Date</b>	: 12-Dec-2021	<b>Patient ID</b>	: LSHHI88473

### X-ray-Chest PA view

Bony cage and soft tissues are normal.  
Cardiothoracic ratio is normal.  
Mediastinum is normal.  
Both hila are normal.  
Both costophrenic angles are clear.  
Both domes of diaphragm are normal.  
Lung fields are clear. No parenchymal lesion seen.

**IMPRESSION: Normal Study.**

  
**DR. POOJA GARG**  
**RADIOLOGIST**  
**REG NO- DMC/R/03398**

**Dr. POOJA GARG**  
**M.B.B.S., D.M.R.D**  
**Reg No DMC/R/03398**  
**Radiologist**

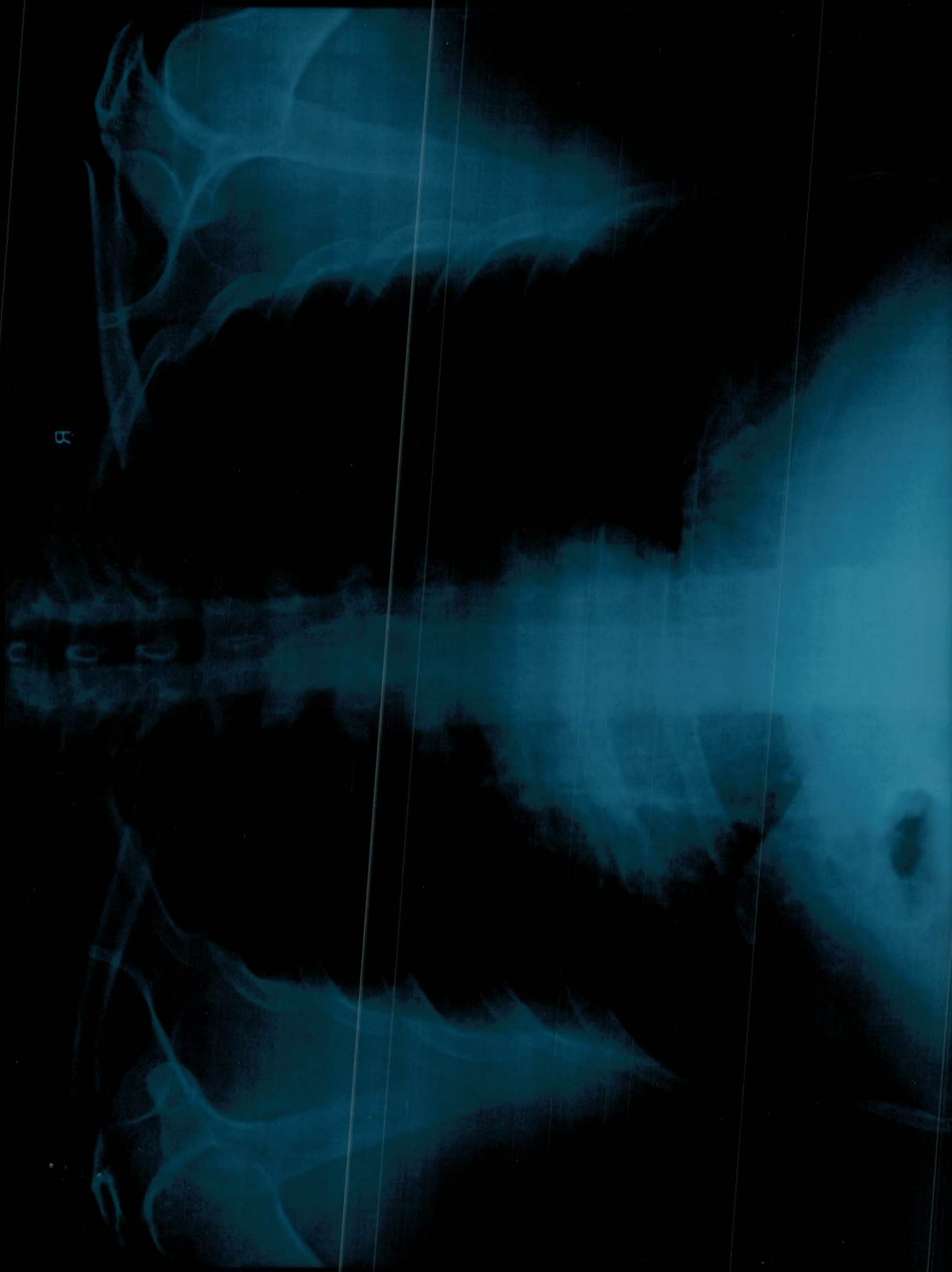
Type By : darshita

47, Harsh Vihar, Pitampura, New Delhi-110034 | Ph.: 011-42480101, 9599913051  
E-mail: [oneplusul@gmail.com](mailto:oneplusul@gmail.com) | Web.: [www.oneplusul.in](http://www.oneplusul.in)

R

MR YASHPAL SINGH 37 YRS 12/12/2021 M CHEST PA VIEW 12/12/2021  
ONEPI IIS III TRASOUND I AB 47-HARSH VIHAR PITAMPURA

СНЕБЛІІС ІІІ ІВАСОІІІІІ І ВВАЗ-НВРСН АНВР ПІТВМРІВР  
MR YASHRAT SINGH 32 YRS 15/15/5051 W CHEST PA VIEW 15/15/5051



R



**OnePLUS**  
Ultrasound Lab  
— QUALITY FIRST... ALWAYS! —

**Dr. Nitin Agarwal**  
Pathologist & Director  
Ex. Sr. Res. MAMC  
& Lok Nayak Hospital  
Ex. Chief of Lab Dr. Lal Path Labs.

**Dr. Pooja (Garg) Agarwal**  
Radiologist & Director  
MAMC & Lok Nayak Hospital

<b>Name</b>	: Mr. YASHPAL SINGH	<b>Age/Sex</b>	: 37 YRS/Male
<b>Ref. By</b>	: Dr. MEDIWHEEL	<b>Lab No</b>	: 012112120007
<b>Date</b>	: 12-Dec-2021	<b>Patient ID</b>	: LSHHI88473

**ULTRASOUND EXAMINATION----WHOLE ABDOMEN**

**Liver** is borderline enlarged in size (15.5 cm) and normal in outline with altered echopattern. Diffuse increase in echogenicity of liver parenchyma is noted, suggestive of fatty infiltration (grade II). Intrahepatic biliary radicles are not dilated. No abscess or mass lesion seen. Hepatic veins, portal vein, IVC and aorta are normal. CBD is normal in caliber.

**Gall bladder** is well distended with anechoic lumen. Wall thickness is normal.

**Both kidneys** are normal in size, shape, position, outline and echopattern. Corticomedullary differentiation is maintained. No pelvicalyceal dilation or mass lesion is seen.

**Spleen** is normal in size and echotexture. No mass lesion seen.

**Pancreas** is normal in size, outline and echotexture.

**Urinary bladder** is normal in shape and position. No evidence of intravesical stone or mass seen.

**Prostate** is normal in size, shape and echopattern.

**Prostate measures** 3.9 x 3.7 x 3.4 cm. **Weight of prostate is 25 grams.**

No abnormal bowel wall thickening seen in right iliac fossa.

No free fluid seen anywhere in abdomen.

**IMPRESSION:**

- Fatty infiltration of liver (grade II) with borderline hepatomegaly.

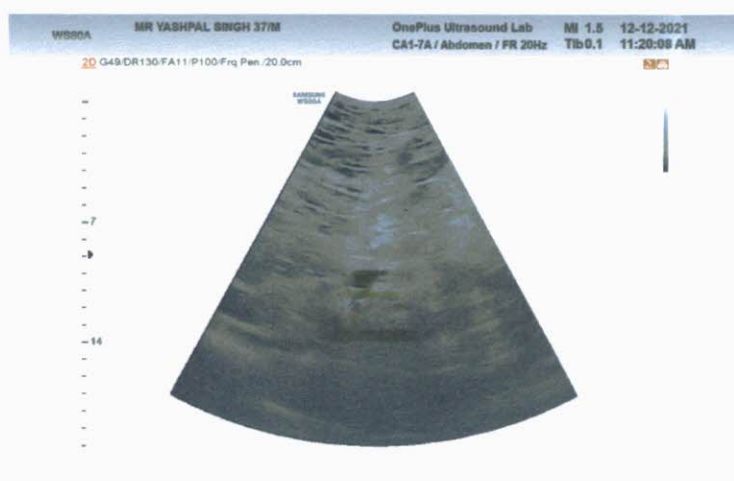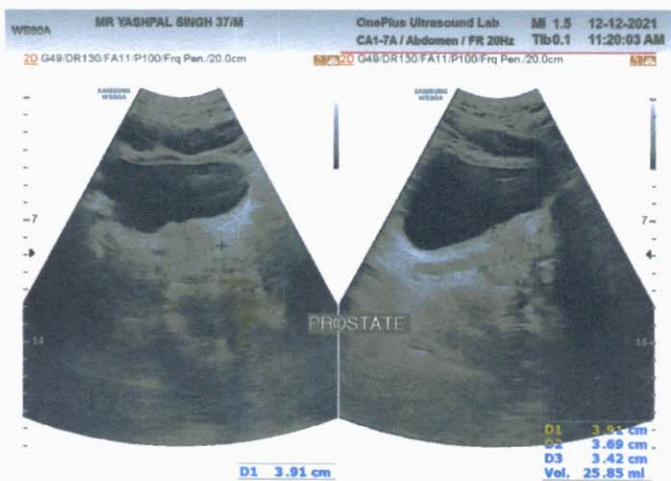
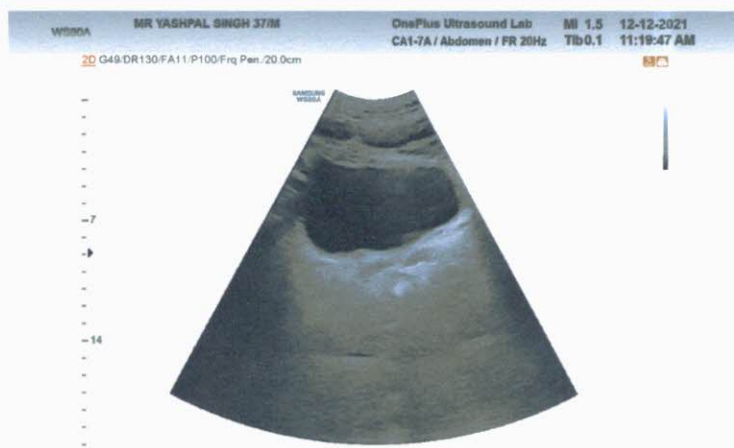
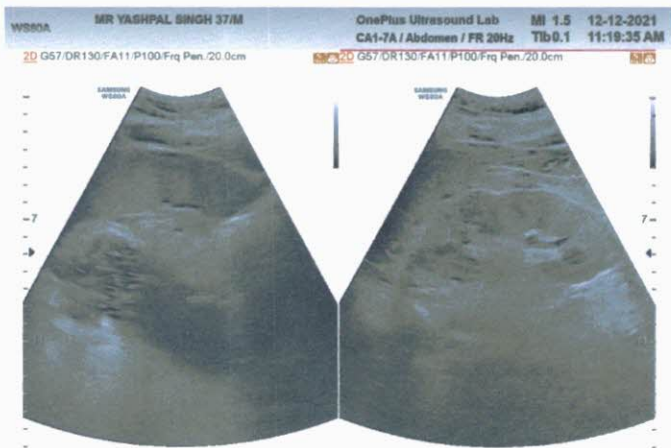
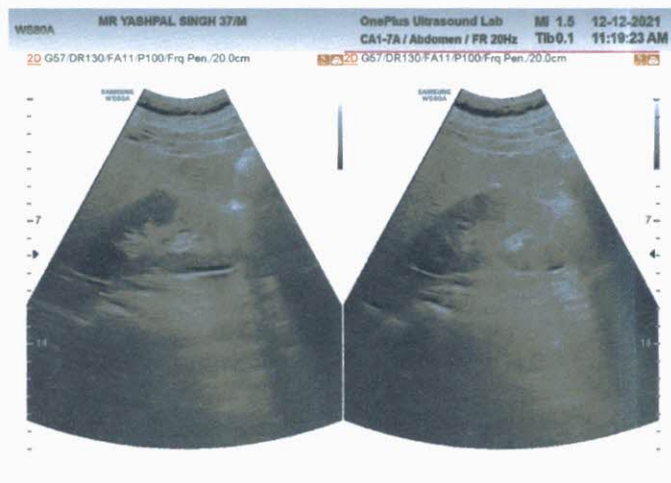
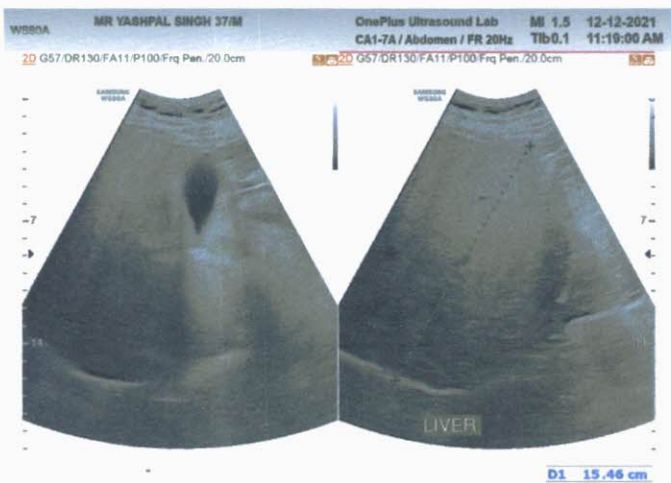
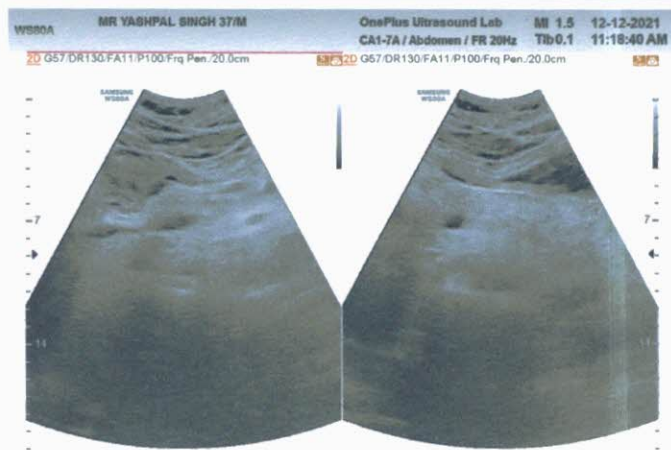
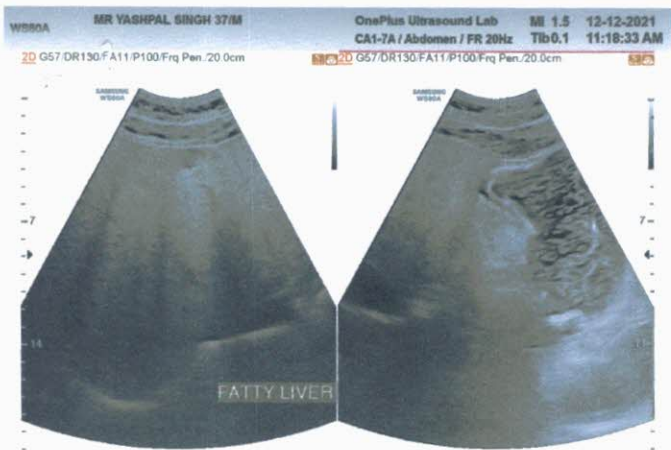
**DR. POOJA GARG**  
RADIOLOGIST  
REG NO- DMC/R/03398

Dr. POOJA GARG  
M.B.B.S., D.M.R.D  
Reg No. DMC/R/03398  
Radiologist

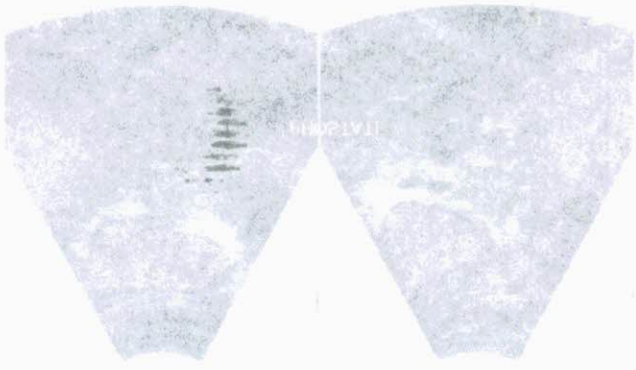
Type By : darshita

47, Harsh Vihar, Pitampura, New Delhi-110034 | Ph.: 011-42480101, 9599913051


E-mail: oneplusul@gmail.com | Web.: www.oneplusul.in



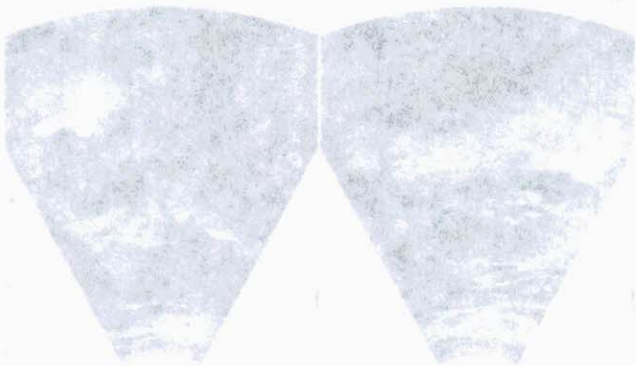




NAME: [illegible] DATE: [illegible] TIME: [illegible] LOCATION: [illegible]




NAME: [illegible] DATE: [illegible] TIME: [illegible] LOCATION: [illegible]




NAME: [illegible] DATE: [illegible] TIME: [illegible] LOCATION: [illegible]



NAME: [illegible] DATE: [illegible] TIME: [illegible] LOCATION: [illegible]



NAME: [illegible] DATE: [illegible] TIME: [illegible] LOCATION: [illegible]



NAME: [illegible] DATE: [illegible] TIME: [illegible] LOCATION: [illegible]



NAME: [illegible] DATE: [illegible] TIME: [illegible] LOCATION: [illegible]



NAME: [illegible] DATE: [illegible] TIME: [illegible] LOCATION: [illegible]



Today's world is a global village



# ONEPLUS ULTRASOUND LAB

47, HARSH VIHAR, PITAMPURA, DELHI- 110034

MR. YASHPAL SINGH  
 Age : 37/M  
 Ref. by : MEDIWHEEL  
 Indication 1 :  
 Indication 2 :  
 Indication 3 :  
 COMMENTS : Normal ECG.

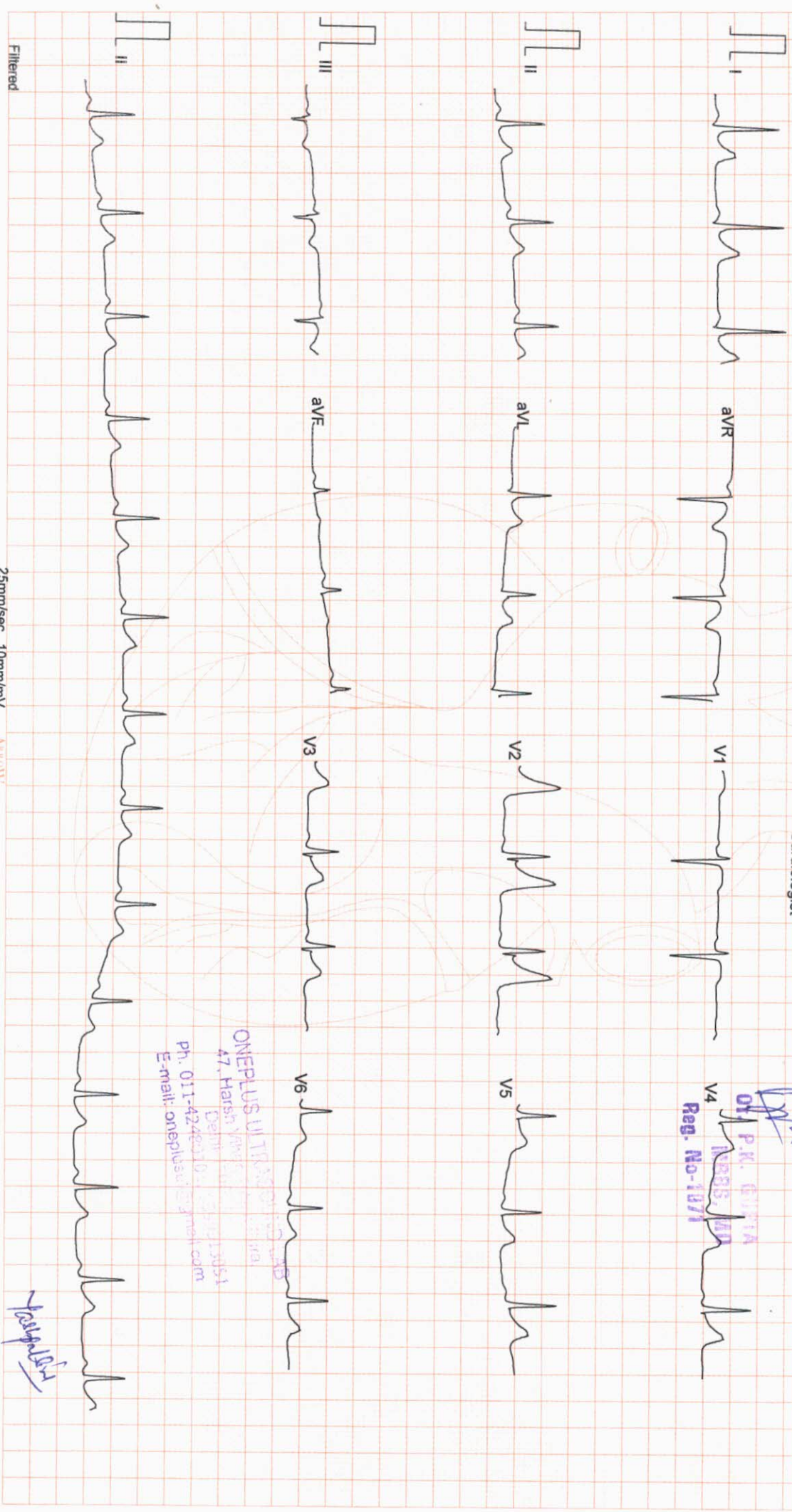
ID : 1835  
 H/Wt : 168/80  
 Recorded : 12-12-2021 10:46  
 Medication 1 :  
 Medication 2 :  
 Medication 3 :

BP : 84  
 P Axis : 65 deg  
 QRS Axis : 11 deg  
 T Axis : 10 deg

P duration : 86 msec  
 PR duration : 116 msec  
 QRS duration : 103 msec  
 QT interval : 296 msec  
 QTc interval : 338 msec

Unconfirmed Report Reviewed By: *[Signature]*  
 Cardiologist

*[Signature]*  
 Dr. P. R. GUPTA  
 Reg. No-1071



ONEPLUS ULTRASOUND LAB  
 47, Harsh Vihar, Pitampura, Delhi-110034  
 Ph. 011-4246310, 42463151  
 E-mail: oneplusultrasound@gmail.com

25mm/sec 10mm/mV

CardiCom, INDIA

*[Signature]*

# ONEPLUS ULTRASOUND LAB

47, HARSH VIHAR PITAMPURA DELHI 110034

ID : 988

HWt : 168/80

Recorded : 12-12-2021 11:32

Mr. YASHPAL SINGH  
 Age/Sex : 37/M  
 Ref. by : MEDIWHEEL  
 Indication1 :  
 Indication2 :  
 Indication3 :

TREADMILL TEST SUMMARY REPORT  
 Protocol: BRUCE  
 History:  
 Medication1 :  
 Medication2 :  
 Medication3 :

PHASE	PHASE TIME	STAGE TIME	SPEED (Km./Hr.)	GRADE (%)	H.R. (BPM)	B.P. (mmHg)	RPP X100	II	ST LEVEL (mm) V2	V5	METS
STANDING SUPINE					81	136/86	110	0.6	3.8	0.9	
STAGE 1	2:59	2:59	2.70	10.00	120	136/86	110	0.6	3.8	1.0	
STAGE 2	5:59	2:59	4.00	12.00	115	146/88	163	0.7	3.3	1.3	4.80
STAGE 3	8:59	2:59	5.40	14.00	136	158/90	214	0.5	3.4	1.3	7.10
STAGE 4	9:44	0:44	6.70	16.00	157	170/92	266	0.2	2.9	1.4	10.00
PEAK EXER	9:47	0:47			160	170/92	272	0.2	2.2	1.2	10.98
RECOVERY	2:59	2:59	0.00	0.00	102	138/88	140	0.1	2.1	0.6	11.05

### RESULTS

Exercise Duration : 9:47 Minutes  
 Max Heart Rate : 160 bpm 87 % of target heart rate 183 bpm  
 Max Blood Pressure : 170/92 mmHg  
 Max Work Load : 11.05 METS  
 Reason of Termination :

*Stop for idk idk*

ONEPLUS ULTRASOUND LAB  
 47, Harsh Vihar Pitampura,  
 Delhi-110034  
 Ph. 011-426013051  
 E-mail: onepus@oneplusultrasound.com

*[Signature]*  
 Cardiologist  
 Reg. No-1071

*[Signature]*

# ONEPLUS ULTRASOUND LAB

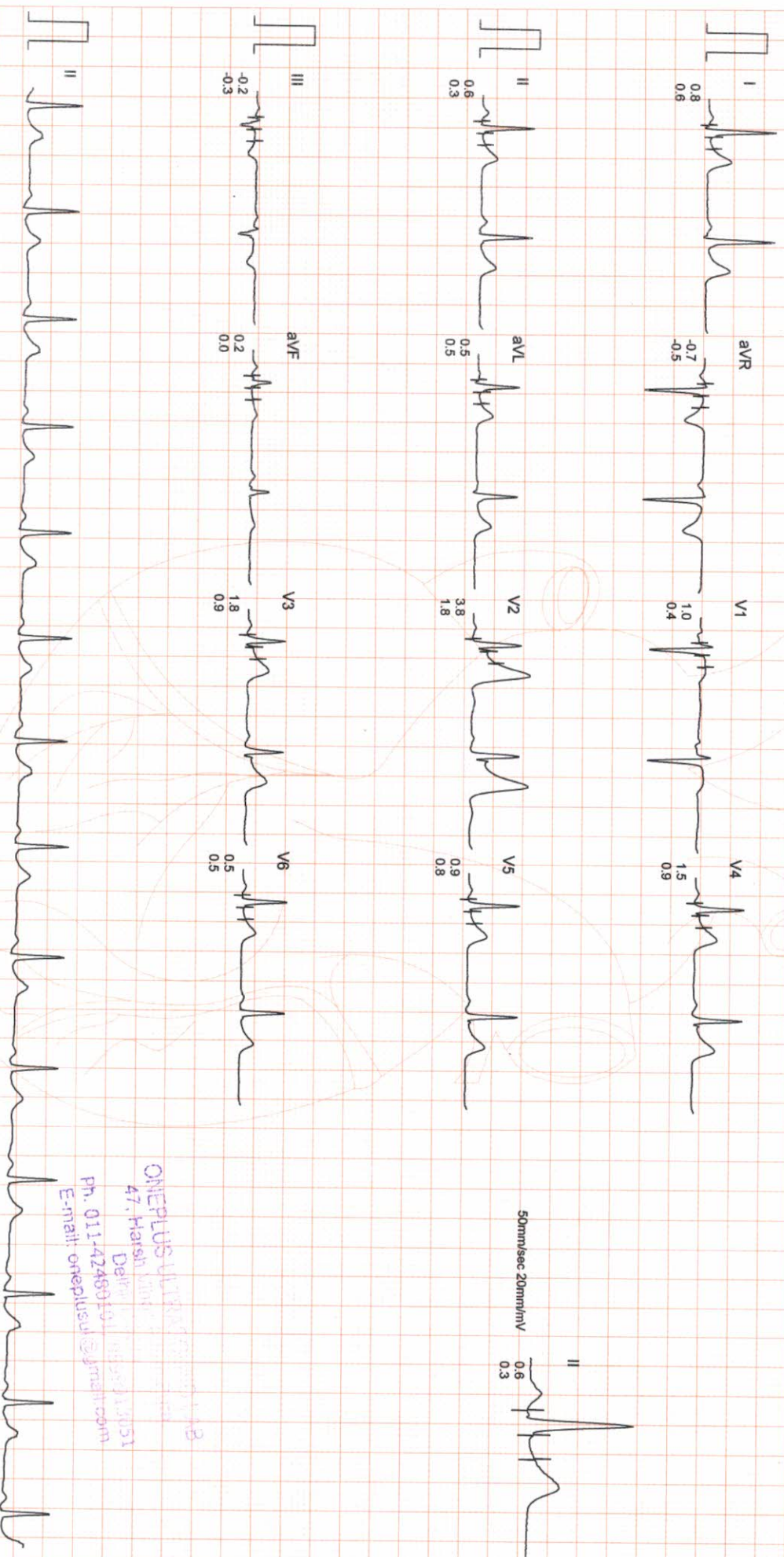
STANDING  
PRETEST

ST @ 10mm/mv  
80ms PostJ

Mr. YASHPAL SINGH  
I.D. : 988  
AGE/SEX : 37/M  
RECORDED : 12-12-2021 11:32

RATE : 81 BPM  
B.P. : 136/86 mmHg

LINKED MEDIAN



ONEPLUS ULTRASOUND LAB  
47, Harsh, Indira Nagar  
Delhi 110014  
Ph. 011-42480101, 011-42480102  
E-mail: onepiusul@jmail.com

# ONEPLUS ULTRASOUND LAB

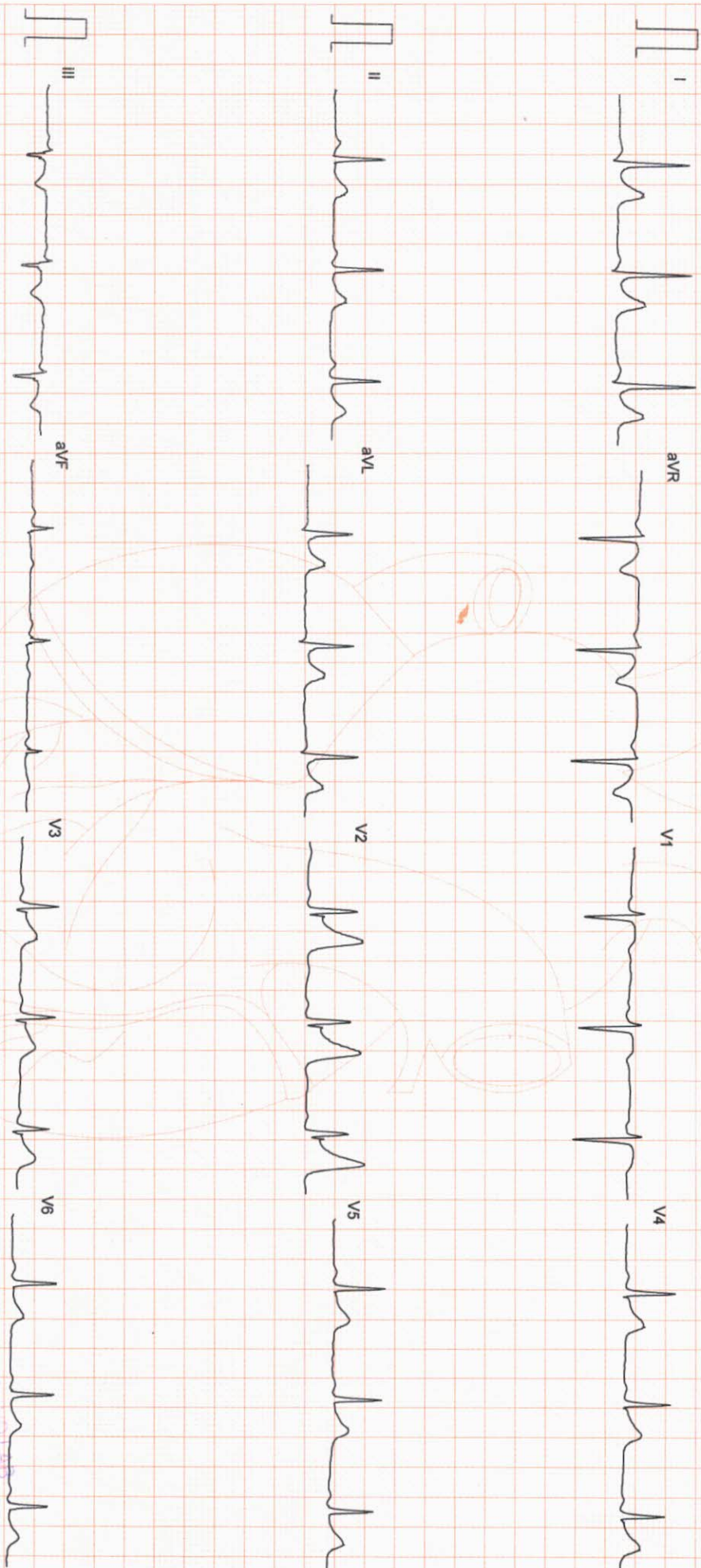
SUPINE  
PRETEST

ST @ 10mm/mV  
80ms PostJ

MR. YASHPAL SINGH  
I.D. : 988  
AGE/SEX : 37/M  
RECORDED : 12-12-2021 11:32

RATE : 81 BPM  
B.P. : 136/86 mmHg

RAW E.C.G



Filtered

25mm/sec 10mm/mV

Arrows

CardiCom, INDIA Ph.:091-731-2620740, TeleFax:091-731-2431214

ONEPLUS ULTRASOUND LAB  
47, Harsh Vihar, Indraprastha,  
Delhi-110028  
Ph. 011-42440101, 9539913051  
E-mail: oneplusul@gmail.com

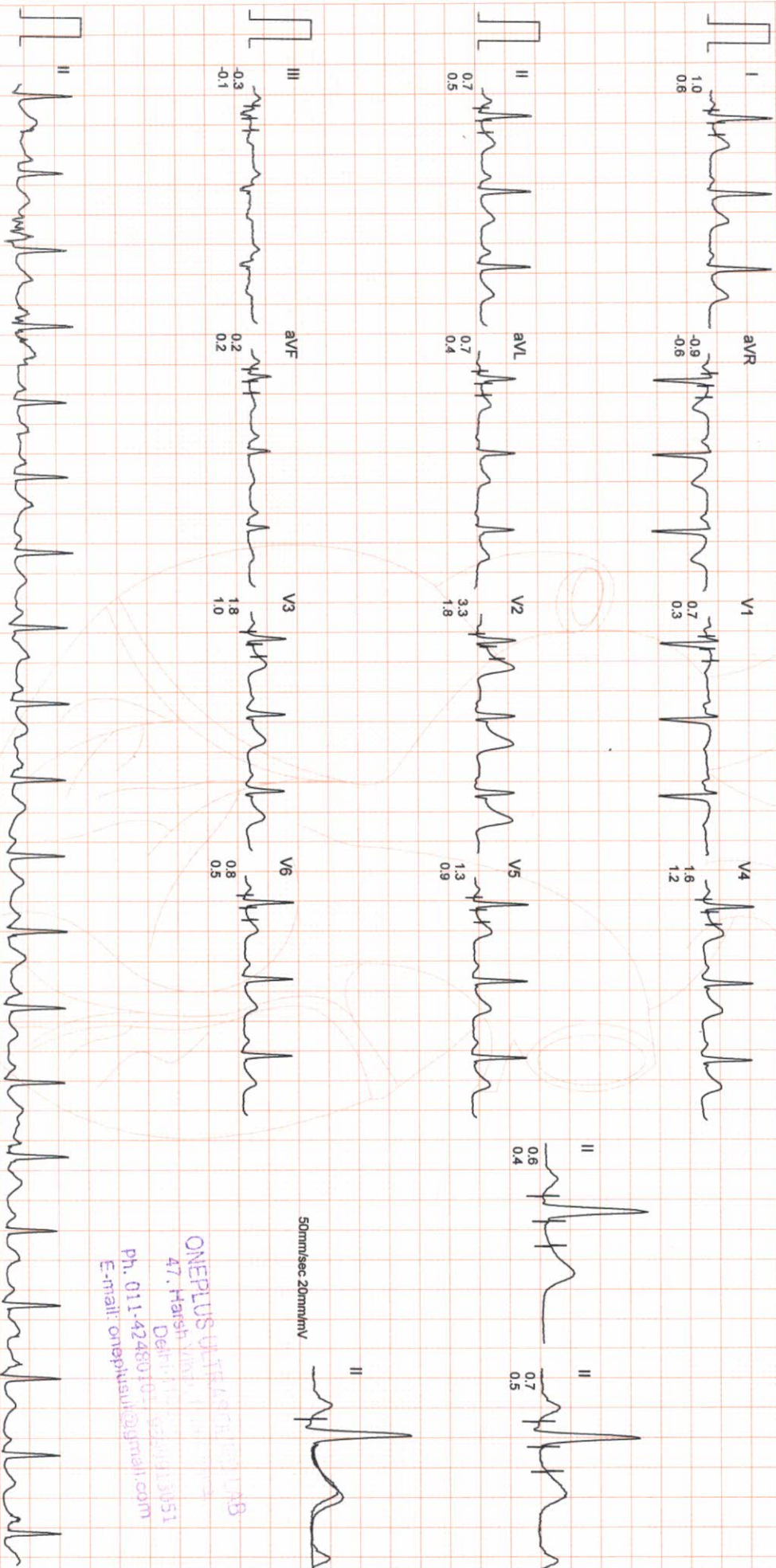
# ONEPLUS ULTRASOUND LAB

Mr. YASHPAL SINGH  
I.D. : 988  
AGE/SEX : 37/M  
RECORDED : 12-12-2021 11:32

RATE : 120 BPM  
B.P. : 136/86 mmHg

BRUCE  
EXERCISE 1  
PHASE TIME : 2:59  
STAGE TIME : 2:59

ST @ 10mm/mV  
80ms PostJ  
SPEED : 2.7 Km/HR  
GRADE : 10.0 %  
LINKED MEDIAN



ONEPLUS ULTRASOUND LAB  
47, Harsh Vihar, Sector 13, Gurgaon  
Delhi-122001, Gurgaon-122015  
Ph. 011-4248010, 011-4248011  
E-mail: onepplus@gmail.com

# ONEPLUS ULTRASOUND LAB

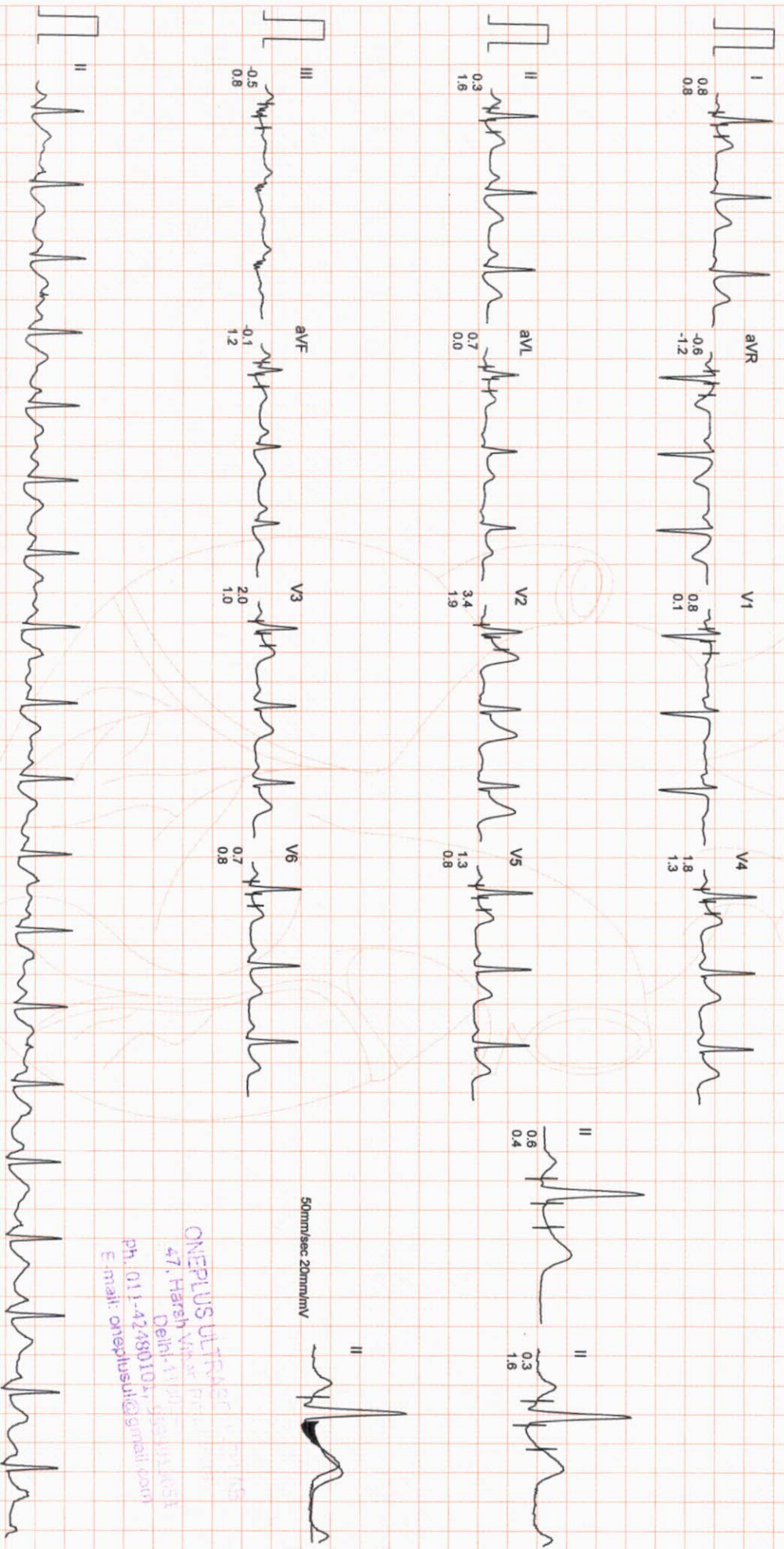
MR. YASHPAL SINGH  
I.D : 988  
AGE/SEX : 37/M  
RECORDED : 12-12-2021 11:32

RATE : 115 BPM  
B.P. : 146/88 mmHg

BRUCE  
EXERCISE 2  
PHASE TIME : 5:59  
STAGE TIME : 2:59

ST @ 10mm/mV  
80ms PostJ  
SPEED : 4.0 Km./Hr.  
GRADE : 12.0 %

LINKED MEDIAN



ONEPLUS ULTRASOUND LAB  
47, Harsh Vihar  
Delhi-110016  
Ph. 011-42480107  
E mail: onepplusul@gmail.com

Filtered

Computer Corrected Baseline

25mm/sec 10mm/mV

ARROW

CardiCom, (INDIA) Ph.:091-731-2620740, TeleFax:091-731-2431214

# ONEPLUS ULTRASOUND LAB

Mr. YASHPAL SINGH

I.D. : 988

AGE/SEX : 37/M

RECORDED : 12-12-2021 11:32

RATE : 136 BPM

B.P. : 158/90 mmHg

BRUCE

EXERCISE 3

PHASE TIME : 8:59

STAGE TIME : 2:59

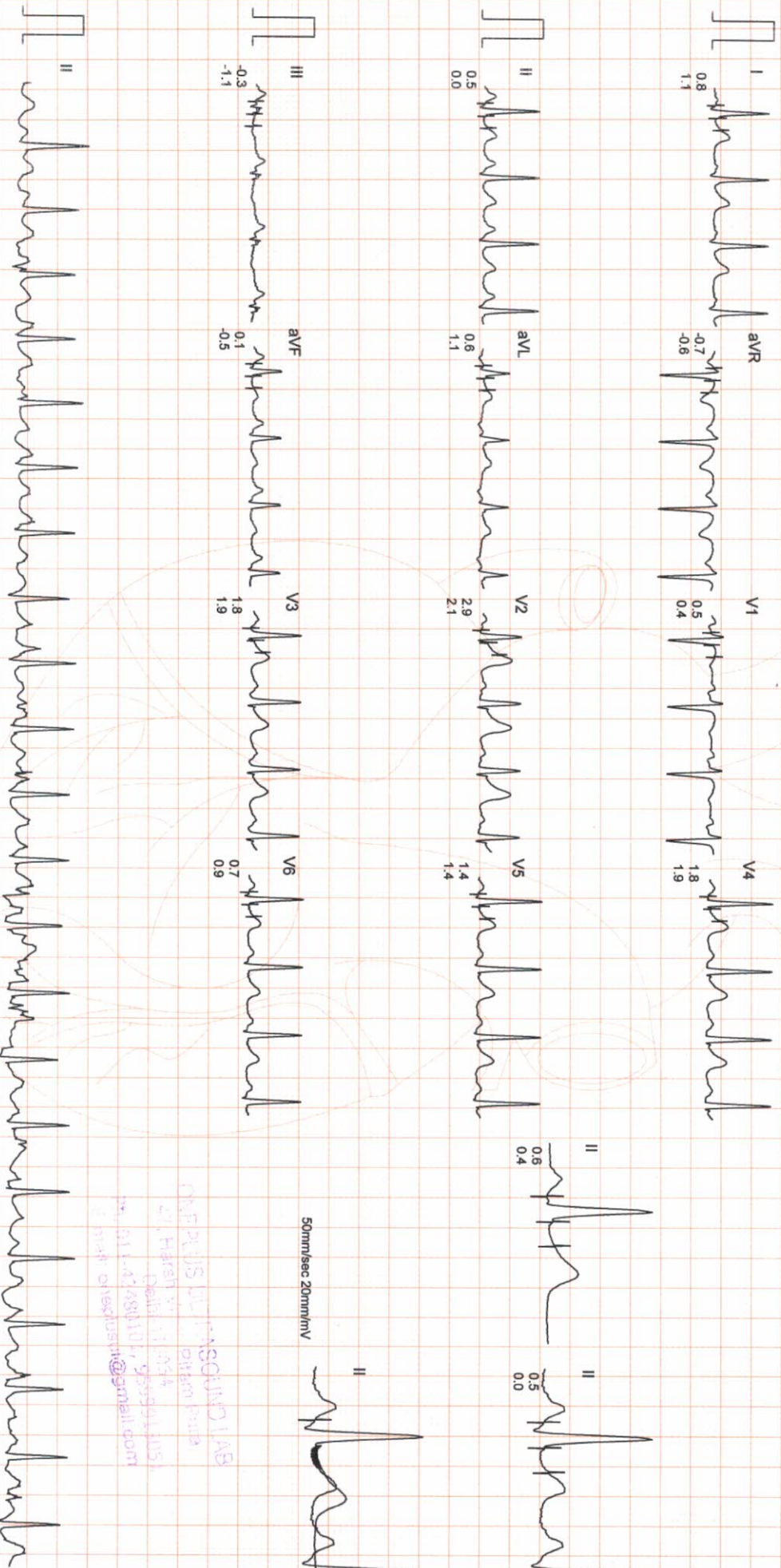
ST @ 10mm/mV

80ms PostI

SPEED : 5.4 Km./Hr.

GRADE : 14.0 %

LINKED MEDIAN



50mm/sec 20mm/mV

ONEPLUS ULTRASOUND LAB  
47, Hareesh Vihar, Pitampura  
Delhi-110034  
91-11-42881107, 9559911051  
Dr. Anshu Chakraborty@gmail.com

Filtered

Computer Corrected Baseline

25mm/sec 10mm/mV

AI/2/W

CardiCom, INDIA Ph.:091-731-2620740, TeleFax:091-731-2431214



# ONEPLUS ULTRASOUND LAB

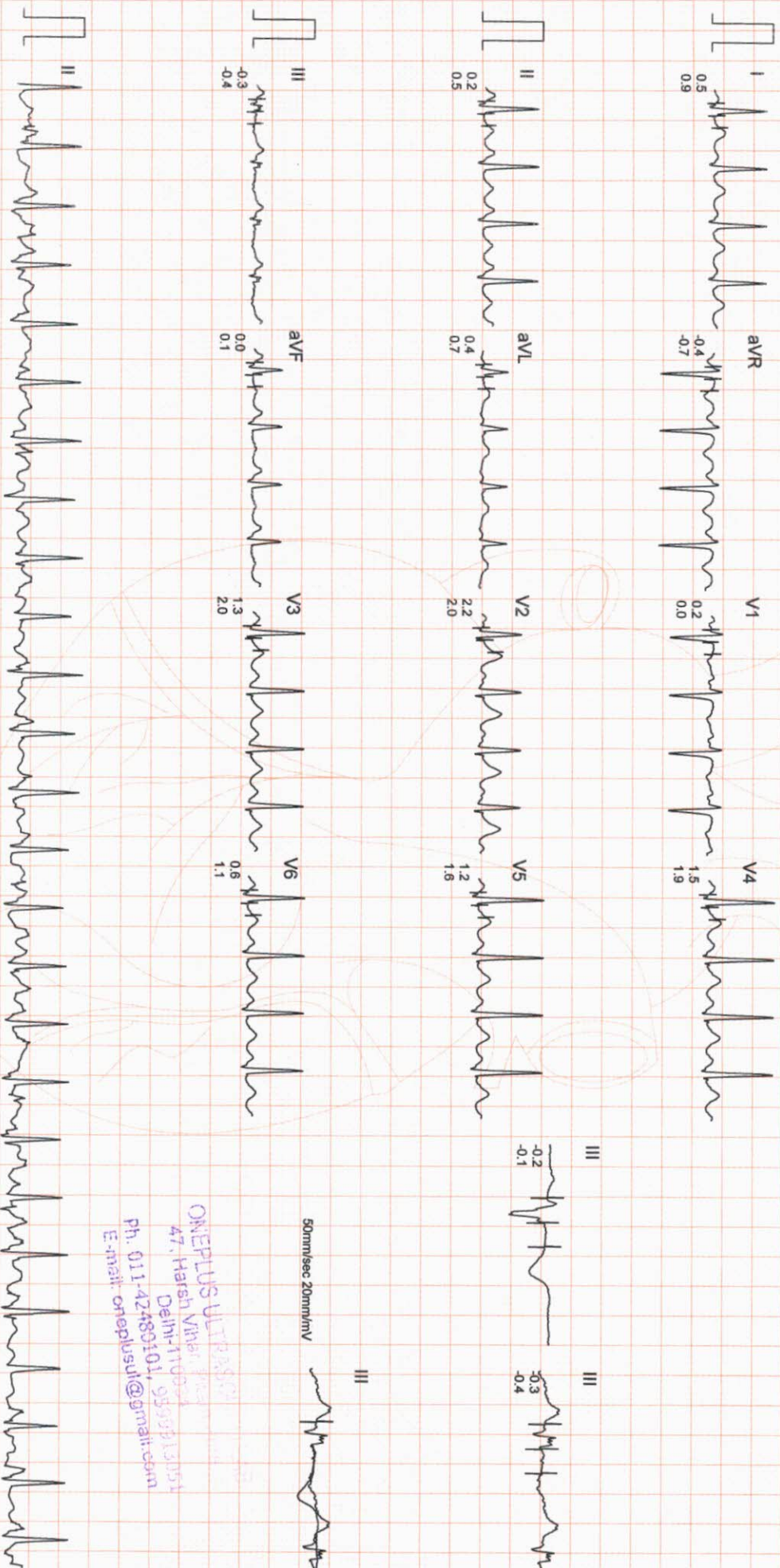
Mr. YASHPAL SINGH  
I.D. : 988  
AGE/SEX : 37/M  
RECORDED : 12-12-2021 11:32

RATE : 157 BPM  
B.P. : 170/92 mmHg

BRUCE  
EXERCISE 4  
PHASE TIME : 9:44  
STAGE TIME : 0:44

ST @ 10mm/mV  
80ms PostJ  
SPEED : 6.7 Km./Hr.  
GRADE : 16.0 %

LINKED MEDIAN



ONEPLUS ULTRASOUND LAB  
47, Harsh Vihar Phase 2  
Delhi-110057  
Ph. 011-42480101, 939913151  
E-mail: onepulsul@gmail.com

# ONEPLUS ULTRASOUND LAB

Mr. YASHPAL SINGH

I.D. : 988

AGE/SEX : 37/M

RECORDED : 12-12-2021 11:32

RATE : 160 BPM

B.P. : 170/92 mmHg

BRUCE

PEAK EXER

PHASE TIME : 9:47

STAGE TIME : 0:47

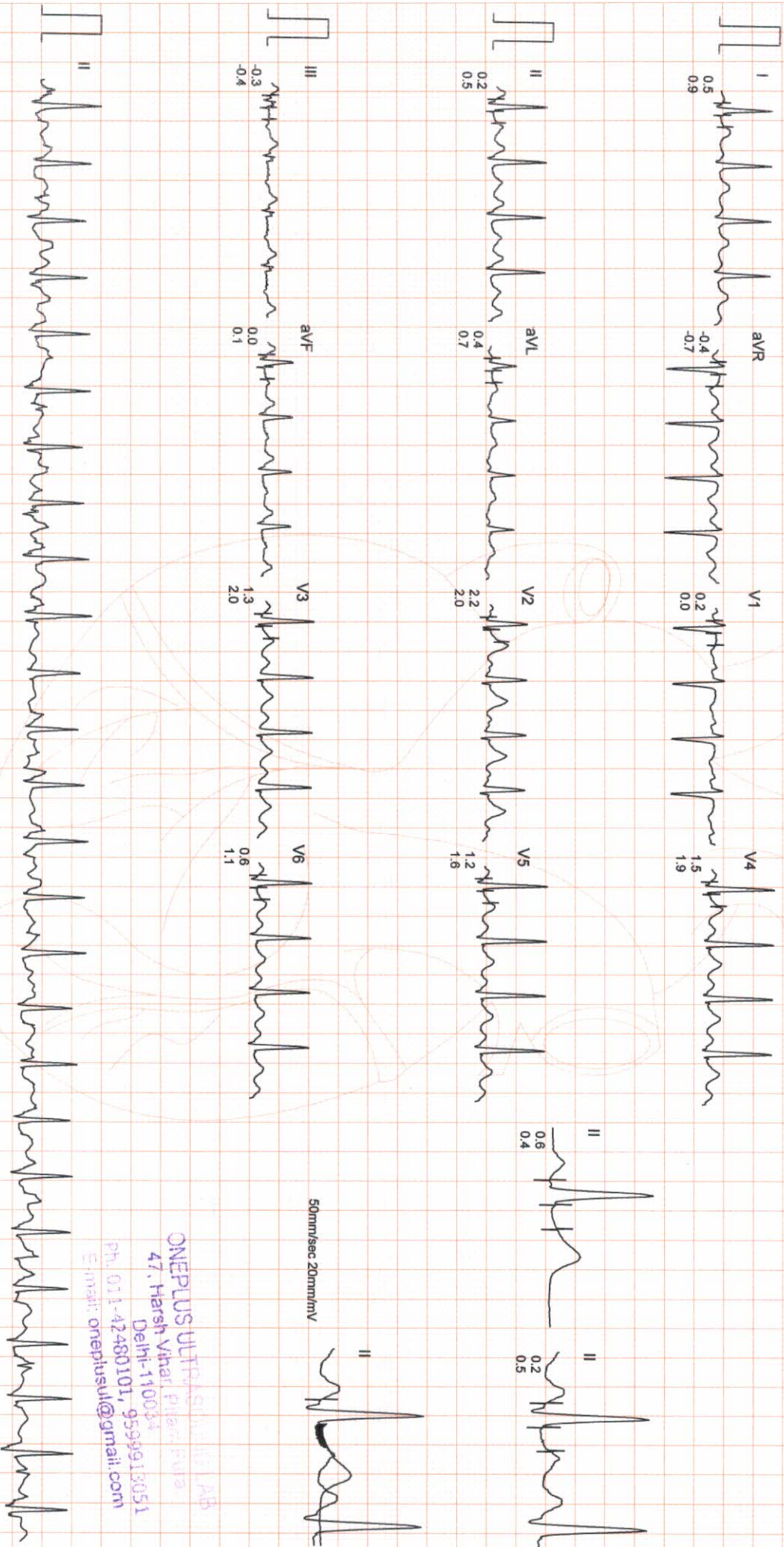
ST @ 10mm/mV

80ms PostJ

SPEED : 6.7 Km./Hr.

GRADE : 16.0 %

LINKED MEDIAN



50mm/sec 20mm/mV

ONEPLUS ULTRASOUND LAB  
47, Harsh Vihar, Pitampura  
Delhi-110034  
Ph: 011-42480101, 9599913051  
E-mail: onepusul@gmail.com

Filtered

Computer Corrected Baseline

25mm/sec 10mm/mV

ARROW

CardiCom, INDIA Ph.:091-731-2620740, TeleFax:091-731-2431214

Mr. YASHPAL SINGH

I.D. : 988

AGE/SEX : 37/M

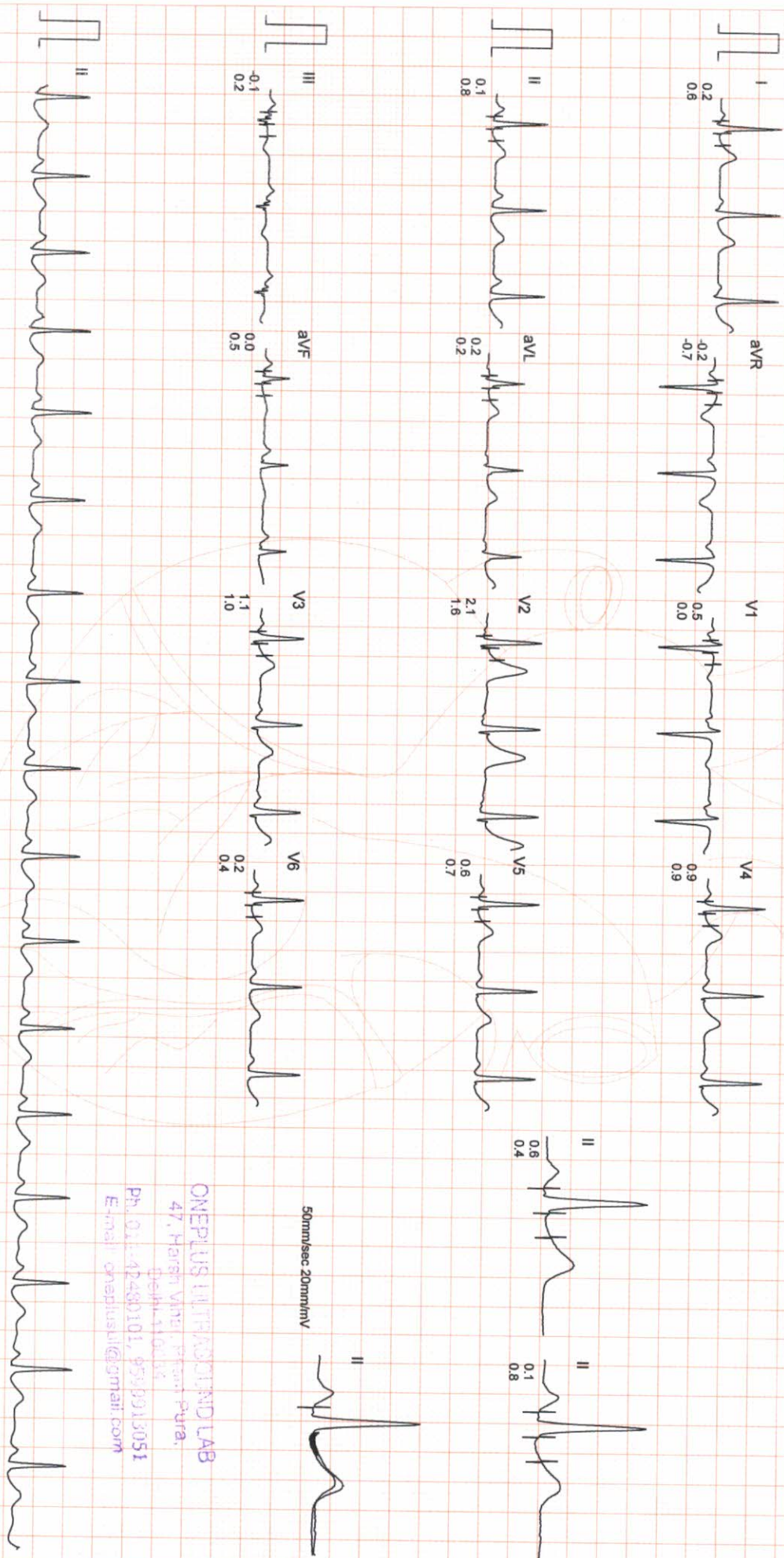
RECORDED : 12-12-2024 11:32

RATE : 102 BPM  
B.P. : 138/88 mmHg

# ONEPLUS ULTRASOUND LAB

BRUCE  
RECOVERY  
PHASE TIME : 2:59

ST @ 10mm/mV  
80ms PostJ  
SPEED : 0.0 Km./Hr.  
GRADE : 0.0 %  
LINKED MEDIAN

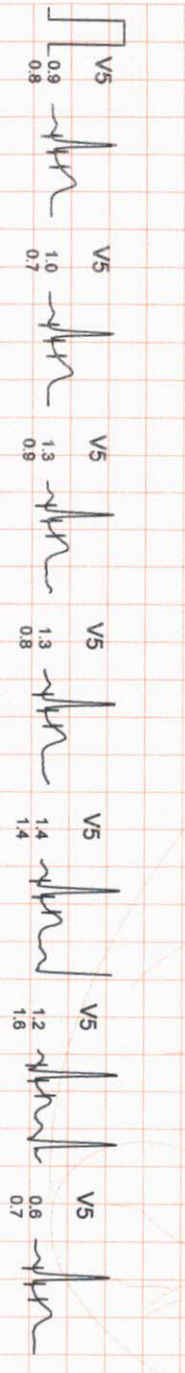

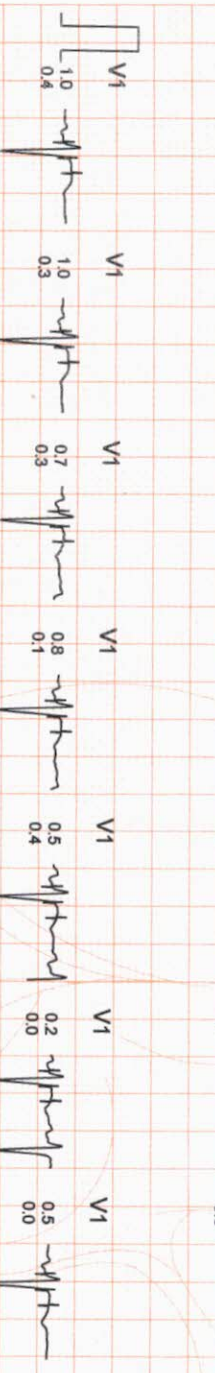

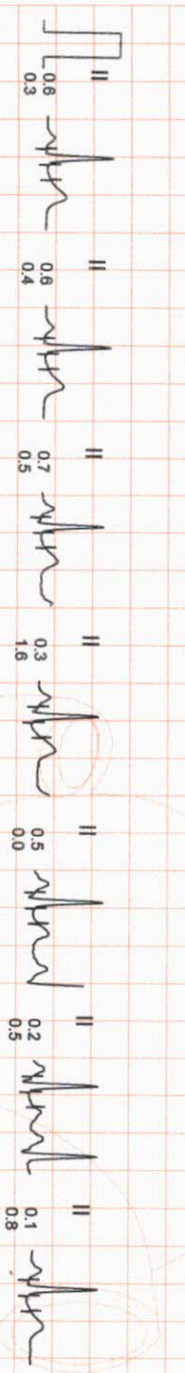


50mmsec 20mm/mV

ONEPLUS ULTRASOUND LAB  
 47, Harsh Vihar, Prant Pura,  
 Delhi-110014  
 Ph: 011-42480101, 9590913051  
 Email: onepusul@gmail.com



STANDING	SUPINE	STAGE 1	STAGE 2	STAGE 3	PEAK EXERCISE	RECOVERY
0.0Kmph 0.0% 81 bpm B.P. 136/86 80ms PostU	0.0Kmph 0.0% 81 bpm B.P. 136/86 80ms PostU	2:59 2:59 2:59 2.7Kmph 10.0% 120 bpm B.P. 136/86 80ms PostU	3:59 3:59 2:59 4.0Kmph 12.0% 115 bpm B.P. 146/88 80ms PostU	8:59 9:47 2:59 5.4Kmph 14.0% 136 bpm B.P. 158/90 80ms PostU	9:47 0:47 6:7Kmph 16.0% 160 bpm B.P. 170/92 80ms PostU	2:59 0.0Kmph 0.0% 102 bpm B.P. 138/86 80ms PostU



ONEPLUS ULTRASOUND LAB  
 47 Hazrat Nizamuddin Park,  
 Delhi 110021  
 Ph: 011-4780100, 9559913051  
 Email: onkx@rediffmail.com



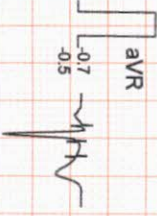



# ONEPLUS ULTRASOUND LAB

AGESEX : 37/M

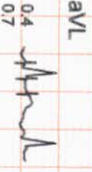


RECORDED : 12-12-2021 11:32

COMPARISON REPORT






SUPINE  
 0.0Kmph  
 0.0%  
 81 bpm  
 B.P. 136/86  
 80ms PostJ



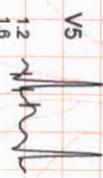



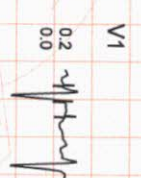
PEAK EXERCISE  
 9.47  
 0.47  
 6.7Kmph  
 16.0%  
 160 bpm  
 B.P. 170/92  
 80ms PostJ



SUPINE  
 0.0Kmph  
 0.0%  
 81 bpm  
 B.P. 136/86  
 80ms PostJ



PEAK EXERCISE  
 9.47  
 0.47  
 6.7Kmph  
 16.0%  
 160 bpm  
 B.P. 170/92  
 80ms PostJ



ONEPLUS ULTRASOUND LAB  
 47, Harshwanth, Indrapur,  
 Distt. Indore, M.P. 462013051  
 Ph. 0751-2451107, 0750913051  
 E-mail: onepplusultrasound@gmail.com



# OnePLUS Ultrasound Lab

**Dr. Nitin Agarwal**  
Pathologist & Director  
Ex. Sr. Res. MAMC  
& Lok Nayak Hospital  
Ex. Chief of Lab Dr. Lal Path Labs.

**Dr. Pooja (Garg) Agarwal**  
Radiologist & Director  
MAMC & Lok Nayak Hospital



NAME	Mr. YASHPAL SINGH	Barcode No	:10109890
AGE/GENDER	:37 YRS/Male	SPECIMEN DATE	:12/Dec/2021 09:49AM
PATIENT ID	:88473	SPECIMEN RECEIVED	:12/Dec/2021 09:58AM
REFERRED BY	:Dr. MEDIWHEEL	REPORT DATE	:12/Dec/2021 05:45PM
CENTRE NAME	:ONEPLUS ULTRASOUND LAB	LAB NO.	:012112120007

Test Name	Result	Unit	Ref. Range
-----------	--------	------	------------

### HAEMATOLOGY

#### Health checkup 2 Male

<b>Glycosylated Hemoglobin (HbA1c)</b>	6.9	%	<6.0%
<b>Estimated average blood glucose (eag)</b>	151		

**Reference range (mg/dl):**

90 - 120:Excellent control, 121 - 150:Good Control, 151 - 180:Average Control, 181 - 210:Action Suggested

>211:Panic value

**REMARKS:-**

In vitro quantitative determination of **HbA1C** in whole blood is utilized in long term monitoring of glycemia. The **HbA1C** level correlates with the mean glucose concentration prevailing in the course of the patient's recent history (approx - 6-8 weeks) and therefore provides much more reliable information for glycemia monitoring than do determinations of blood glucose or urinary glucose. It is recommended that the determination of **HbA1C** be performed at intervals of 4-6 weeks during Diabetes Mellitus therapy. On testing of HbA1C by HPLC method the result shows high variant window (93.8%) & no value of HbA1C. Therefore for accurate assay of glycaemic Control Fructosamine assay & for variant analysis Hb electrophoresis should be done.

Assay done by : Bio-Rad : D-10 (HPLC)

<b>BLOOD GROUP (ABO)</b>	AB
<b>Rh typing</b>	POSITIVE

**NOTE :**

- \* Apart from major A,B,H antigens which are used for ABO grouping and Rh typing, many minor blood group antigens exist. Agglutination may also vary according to titre of antigen and antibody.
- \* So before transfusion, reconfirmation of blood group as well as cross-matching is needed.
- \* Presence of maternal antibodies in newborns, may interfere with blood grouping.
- \* Auto agglutination (due to cold antibody, falciparum malaria, sepsis, internal malignancy etc.) may also cause erroneous result.

### CBC

Haemoglobin	14.4	g/dl	13.0-17.0
Total Leucocyte Count	9920	/cumm	4000-10000

**Differential leucocyte count**

Checked By.

DR. NITIN AGARWAL  
MBBS,MD(PATHOLOGIST)

Dr. NITIN AGARWAL  
M B B S (M D Path)  
DMC/R/S/136

47, Harsh Vihar, Pitampura, New Delhi-110034 | Ph.: 011-42480101, 9599913051  
E-mail: oneplusul@gmail.com | Web.: www.oneplusul.in

Clinical correlation is essential for final diagnosis. • If test results are unsatisfactory please contact personally or on phone. • This report is for perusal of doctors only. • All disputes Subject to Delhi Jurisdiction only. • Not for medicolegal purposes. • All congenital anomalies in a foetus may not be diagnosed in routine obstetric ultrasound.



# OnePLUS Ultrasound Lab

**Dr. Nitin Agarwal**  
Pathologist & Director  
Ex. Sr. Res. MAMC  
& Lok Nayak Hospital  
Ex. Chief of Lab Dr. Lal Path Labs.

**Dr. Pooja (Garg) Agarwal**  
Radiologist & Director  
MAMC & Lok Nayak Hospital



NAME (QUALITY FIRST... ALWAYS)	Mr. YASHPAL SINGH	Barcode No	:10109890
AGE/GENDER	:37 YRS/Male	SPECIMEN DATE	:12/Dec/2021 09:49AM
PATIENT ID	:88473	SPECIMEN RECEIVED	:12/Dec/2021 09:58AM
REFERRED BY	:Dr. MEDIWHEEL	REPORT DATE	:12/Dec/2021 05:45PM
CENTRE NAME	:ONEPLUS ULTRASOUND LAB	LAB NO.	:012112120007

Test Name	Result	Unit	Ref. Range
Neutrophils	74.4	%	40-80
Lymphocyte	19.20	%	20-40
Monocytes	3.80	%	2-10
Eosinophils	2.2	%	1-6
Basophils	0.4	%	0-2
RBC Count	4.91	million/cumm	4.5 - 5.5
PCV(Hematocrit)	46.3	%	40-50
MCV	94.4	fL	83-101
MCH	29.4	Pg	27-32
MCHC	31.2	G/dL	32-35
Platelet count	182000	/cumm	150000-450000
RDW-CV	14.1	%	11.4-14.0
ESR(WESTEGRENs METHOD)	12	mm in 1st hr	0-20

### BIOCHEMISTRY

<u>Blood sugar fasting</u>	156	mg/dL	70-110
<u>Blood sugar pp</u>	218	mg/dL	70.0-140.0
<u>Bun (blood urea nitrogen)</u>	14.60	mg/dl	8.9-21.6
<u>Uric acid, serum</u>	4.9	mg/dl	3.4-7.0
<u>Creatinine, serum</u>	1.09	mg/dl	0.60-1.1

### LFT(LIVER FUNCTION TEST)

Bilirubin Total	0.65	mg/dl	0.1-1.2
Bilirubin Conjugated	0.24	mg/dl	0-0.4
Bilirubin Unconjugated	0.41	mg/dl	up to 0.7
SGOT (AST)	64	U/L	0-35
SGPT (ALT)	56	U/L	<45.0
Alkaline phosphatase	100	U/L	40-129
Gamma glutamyl transpeptidase	27	U/L	<66
Total Protein	6.7	gm/dl	6.60 - 8.70

Checked By.

DR. NITIN AGARWAL  
MBBS,MD(PATHOLOGIST)

Dr NITIN AGARWAL  
M B B S, MD (Path)  
DMC/R/11436

Page 2 of 5

47, Harsh Vihar, Pitampura, New Delhi-110034 | Ph.: 011-42480101, 9599913051  
E-mail: oneplusul@gmail.com | Web.: www.oneplusul.in

Clinical correlation is essential for final diagnosis. • If test results are unsatisfactory please contact personally or on phone. • This report is for perusal of doctors only.  
• All disputes Subject to Delhi Jurisdiction only. • Not for medicolegal purposes. • All congenital anomalies in a foetus may not be diagnosed in routine obstetric ultrasound.



# OnePLUS Ultrasound Lab

**Dr. Nitin Agarwal**  
Pathologist & Director  
Ex. Sr. Res. MAMC  
& Lok Nayak Hospital  
Ex. Chief of Lab Dr. Lal Path Labs.

**Dr. Pooja (Garg) Agarwal**  
Radiologist & Director  
MAMC & Lok Nayak Hospital



NAME (QUALITY FIRST... ALWAYS)	<b>Mr. YASHPAL SINGH</b>	Barcode No	<b>:10109890</b>
AGE/GENDER	:37 YRS/Male	SPECIMEN DATE	:12/Dec/2021 09:49AM
PATIENT ID	:88473	SPECIMEN RECEIVED	:12/Dec/2021 09:58AM
REFERRED BY	:Dr. MEDIWHEEL	REPORT DATE	:12/Dec/2021 05:45PM
CENTRE NAME	:ONEPLUS ULTRASOUND LAB	LAB NO.	:012112120007

Test Name	Result	Unit	Ref. Range
Albumin	3.8	g/dL	3.8-5.1
Globulin	2.90	gm/dl	1.8-3.4
Albumin/Globulin Ratio	1.31		1.10 - 2.50

### LIPID PROFILE

Cholesterol	<b>212</b>	mg/dl	50-200
Triglycerides	142	mg/dL	25-150
HDL Cholesterol	49	mg/dL	30-70
LDL cholesterol	<b>135</b>	mg/dL	<130
VLDL cholesterol	28.4	mg/dL	5-40
Cholesterol/HDL Ratio	4.3		Low Risk 3.3-4.97 Average Risk 4.4-7.1 Moderate Risk 7.1-11.0 High Risk >11.0
LDL/HDL Ratio	2.8		0 - 3.55

According to ATP III and NCEP guidelines

Parameter	Normal	Desirable	Borderline	High
Total cholesterol	<200	200-239		240
Triglycerides	<150	150-199	200-499	500
LDL	Optimal <100 Near Optimal 100-129	130-159	160-180	190
HDL	<40 : LOW 60 : HIGH			

### ENDOCRINOLOGY

#### PSA TOTAL

Prostatic specific antigen, Total      0.66      ng/ml      <4.0

< 40 years	0.21 to 1.72 ng/ml
40 - 49	0.27 to 2.19 ng/ml
50 - 59	0.27 to 3.42 ng/ml

Checked By.

**DR. NITIN AGARWAL**  
MBBS, MD(PATHOLOGIST)

Dr. NITIN AGARWAL  
MBBS, MD (Path)  
DMC/R/01436

Page 3 of 5

**47, Harsh Vihar, Pitampura, New Delhi-110034 | Ph.: 011-42480101, 9599913051**  
**E-mail: oneplusul@gmail.com | Web.: www.oneplusul.in**





# OnePLUS Ultrasound Lab

**Dr. Nitin Agarwal**  
Pathologist & Director  
Ex. Sr. Res. MAMC  
& Lok Nayak Hospital  
Ex. Chief of Lab Dr. Lal Path Labs.

**Dr. Pooja (Garg) Agarwal**  
Radiologist & Director  
MAMC & Lok Nayak Hospital



NAME (FULLY FIRST... ALWA)	Mr. YASHPAL SINGH	Barcode No	:10109890
AGE/GENDER	:37 YRS/Male	SPECIMEN DATE	:12/Dec/2021 09:49AM
PATIENT ID	:88473	SPECIMEN RECEIVED	:12/Dec/2021 09:58AM
REFERRED BY	:Dr. MEDIWHEEL	REPORT DATE	:12/Dec/2021 05:45PM
CENTRE NAME	:ONEPLUS ULTRASOUND LAB	LAB NO.	:012112120007

Test Name	Result	Unit	Ref. Range
60 - 69	0.22 to 6.16 ng/ml		
> 69	0.21 to 6.77 ng/ml		

### Notes:

PSA is principally produced by the glandular epithelium of the prostate, and is secreted in the seminal fluid. PSA is also present in urine and blood. PSA acts on seminal fluid to fluidify and increase sperm mobility. PSA levels rise in prostatic pathologies such as benign prostatic hyperplasia (BPH) or prostate cancer.

### THYROID PROFILE(T3,T4,TSH)

Triiodothyronine total [t3]	0.95	ng/dl	0.52-1.9
Thyroxine total [t4]	7.20	µg/dl	4.4 - 10.8
TSH (Thyroid Stimulating Hormone)	6.40	µIU/ml	0.25-5.0

### AGE WISE VARIATION IN TSH

AGE	TSH(µIU/ml)	AGE	TSH(µIU/ml)
1-4 weeks	1.00 - 19.0	16-20 yrs	0.25 - 5.0
1-12 mths	1.70 - 9.1	21 - 80 yrs	0.25 - 5.0
1-5 yrs	0.80 - 8.2	I <sup>st</sup> trimester	0.25 - 5.0
6-10 yrs	0.25 - 5.0	II <sup>nd</sup> trimester	0.50 - 5.0
11-15 yrs	0.25 - 5.0	III <sup>rd</sup> trimester	0.4 - 6.0

### Reference ranges - Interpretation of Diagnostic tests - (Jacques Wallach)

1. Primary hypothyroidism is accompanied by depressed serum T3 and T4 values and elevated serum TSH level.
2. Primary hyperthyroidism is accompanied by elevated serum T3 and T4 levels along with depressed TSH values.
3. Slightly elevated T3 levels may be found in pregnancy and estrogen therapy, while depressed levels may be encountered in severe illness, renal failure and during therapy with drugs like propranolol and propyl thiouracil.
4. Although elevated TSH levels are nearly always indicative of primary hypothyroidism, and may be seen in secondary thyrotoxicosis

### CLINICAL PATHOLOGY

#### URINE ROUTINE

#### Physical examination

Checked By.

DR. NITIN AGARWAL  
MBBS,MD(PATHOLOGIST)

Dr. NITIN AGARWAL  
M.B.B.S. (Path)  
DMC/R/11-36

Page 4 of 5

47, Harsh Vihar, Pitampura, New Delhi-110034 | Ph.: 011-42480101, 9599913051  
E-mail: oneplusul@gmail.com | Web.: www.oneplusul.in



# OnePLUS Ultrasound Lab

**Dr. Nitin Agarwal**  
Pathologist & Director  
Ex. Sr. Res. MAMC  
& Lok Nayak Hospital  
Ex. Chief of Lab Dr. Lal Path Labs.

**Dr. Pooja (Garg) Agarwal**  
Radiologist & Director  
MAMC & Lok Nayak Hospital



NAME	Mr. YASHPAL SINGH	Barcode No	:10109890
AGE/GENDER	:37 YRS/Male	SPECIMEN DATE	:12/Dec/2021 09:49AM
PATIENT ID	:88473	SPECIMEN RECEIVED	:12/Dec/2021 09:58AM
REFERRED BY	:Dr. MEDIWHEEL	REPORT DATE	:12/Dec/2021 05:45PM
CENTRE NAME	:ONEPLUS ULTRASOUND LAB	LAB NO.	:012112120007

Test Name	Result	Unit	Ref. Range
Quantity	20		ML
Colour	PALE YELLOW		
Transparency	CLEAR		CLEAR
Sp.gravity	1.015		1.010-1.030
pH	6.00		
Reaction	ACIDIC		ACIDIC
<b>Chemical examination</b>			
Urine protein	NIL		NIL
Urine sugar	NIL		NIL
Bilirubin, urine	NEGATIVE		NEGATIVE
Urobilinogen	NORMAL		NORMAL
Ketones	NEGATIVE		NEGATIVE
<b>Microscopic examination</b>			
<b>Pus cells.</b>	1-2	/HPF	0-2
Epithelial cells	1-2	/HPF	NIL
R.B.C.	NIL	/HPF	NIL
Casts	NIL	/HPF	NIL
Crystals	NIL	/HPF	NIL
Bacteria	NIL	/HPF	NIL
Others.	NIL	NIL	NIL

\*\*\* End Of Report \*\*\*

Checked By.

DR. NITIN AGARWAL  
MBBS,MD(PATHOLOGIST)

Dr. NITIN AGARWAL  
M B B S, MD (Path)  
DMT 151436

Page 5 of 5

47, Harsh Vihar, Pitampura, New Delhi-110034 | Ph.: 011-42480101, 9599913051  
E-mail: oneplusul@gmail.com | Web.: www.oneplusul.in

Clinical correlation is essential for final diagnosis. • If test results are unsatisfactory please contact personally or on phone. • This report is for perusal of doctors only.  
• All disputes Subject to Delhi Jurisdiction only. • Not for medicolegal purposes. • All congenital anomalies in a foetus may not be diagnosed in routine obstetric ultrasound.