



# PARKLINE DIAGNOSTICS PVT. LTD.

L.G. 3, 4 & 5, Bhuvana Towers, S.D. Road, Secunderabad - 500 003.

Tel : +91 40-2784 5852, 6649 1787, 7995421787, 7093445852, Fax : +91 40 2784 7864

Email parklinediagnostics@gmail.com www.parklinediagnostics.com



NABL Accredited  
Certificate No.MC-2566

## MEDICAL EXAMINATION REPORT

Name	Mr. Buchireddy Srikanth Reddy		Date :	4/4/22	
Company	C/o. Mediwheel		Reg. No. :	1927373	
Contact No.	7020032519		Sex	<input type="checkbox"/> M <input checked="" type="checkbox"/> F	Age : <input type="checkbox"/> 35
Type	Pre-Emp		Emp. No.:	97456	
	Overseas		Height	152 cm	
	Annual	<input checked="" type="checkbox"/>	Weight	96 kg	
Remarks					
	<p><u>USG</u> : Simple left parapelvic cyst measuring 16x11mm.</p> <p>Advice follow up <math>\bar{c}</math> Urologist.</p> <p>- Slightly elevated TSH. Advice follow up.</p> <p>- Rest all clinical &amp; Lab parameters within <math>\odot</math> limits.</p> <p style="text-align: right;">DR. PRIYANKA SANNIDHI MBBS Regn. No: 11351</p>				
Fitness Status	Medically Fit / Unfit		Physician's Signature		

# COMPREHENSIVE MEDICAL EXAMINATION REPORT

NAME Mr. Buchi Reddy Srikanth Reddy

AGE 35 yrs / Male

MARITAL STATUS Married CHILDREN : M  F

IDENTIFICATION (IF ANY) A mole in the Rt eyeball

## PAST HISTORY

Any family H/o : High Blood Pressure, Heart Disease, Tuberculosis, Diabetes, Asthma, Cancer

Father

Any personal H/o Major illness like : Typhoid.....NIL.....Jaundice.....NIL.....Etc.

Any H/o STD.....NIL.....Skin infection.....NIL

H/o Blood Transfusion.....NIL.....Recent Vaccination.....COVASKIELD 2 Dose

H/o Epilepsy.....NIL.....Giddiness.....NIL

H/o Surgery.....NIL.....Fracture in the past.....NIL

### Any Personal H/O.

High Blood Pressure, Heart Disease Tuberculosis, Diabetes, Asthma, Cancer

Drug Abuse, Drug Allergy, Micturition, Bowels, Alcohol, Smoking, Sleep, MC, Wt. Loss/Wt. Gain

occasional

Present illness / Medication

## GENERAL EXAMINATION

Conjunctiva :

Skin :

Ears :

Nose :

Throat & Oral Cavity :

Bone, Joints : (N)

Nutritional Status :

Lymph Nodes :

Edema Feet :

Varicose Veins :

(N)

well Nourished

NPD

NIL

NIL

NPD

**Distant Vision : Near Vision :**

Right Eye: 6/6

With glasses / Without glasses

left Eye : 6/6

with glasses / without glasses

Colour Vision : BE normal

**Right Ear**

Hearing : (N)

Rinee's Test ;

Weber Test :

Discharge : NIL

Right Eye: Ng

With glasses / Without glasses

left Eye : Ng

with glasses / without glasses

**Ophthalmologist's Signature**

**Left Ear**

(N)

NIL

Dr. KATTA  
M.B.B.S., D.O., F.R.C.S.  
162981 (AMCI)

**SYSTEMIC EXAMINATION**

Pulse : 80bpm

B.P. : 120/80mmHg

Lungs : A. Shape of Chest B/c symmetrical  
B. Breath Sounds B/c clear ⊕  
C. Adventitious Sounds No

Heart : A. Sounds S1 S2 ⊕  
B. Murmurs No murmurs

Abdomen : A. Liver NPD  
B. Spleen NPD  
C. Piles NIL  
D. Any Lump NIL

**Nervous System**

A. Higher Function :  
B. Cranial Nerves :  
C. Sensory System :  
D. Motor System :  
E. Jerks :

(N)


General : A. Hernia  
B. Hydrocele  
C. Varicocele  
NAD

Breast : Rt \_\_\_\_\_ Lt. \_\_\_\_\_

## CANDIDATE'S DECLARATION

I hereby solemnly declare that I am not suffering from Asthma, Hypertension, Diabetes, Occult Psychological disorders or any other ailment which can be suppressed without my voluntary declaration.

Date : 04/04/2022



Signature

Place : Hyderabad

Note : General Physical Examination and Investigation included in the health check-up Have certain limitations and may not be able to detect all latent and asymptomatic diseases. Any new symptoms developing after the health check-up or persisting thereafter should be brought to the attention of the treating physician.



# PARKLINE DIAGNOSTICS PVT. LTD.

L.G. 3, 4 & 5, Bhuvana Towers, S.D. Road, Secunderabad - 500 003. Tel :+91 40-2784 5852, 6649 1787, 7995421787, 7093445852, Fax : +91 40 2784 7864 Email parklinediagnostics@gmail.com www.parklinediagnostics.com



NABL Accredited  
Certificate No.MC-2566

## ENT CONSULTATION

S.No. 1927373

Emp.No. 97456

Date 4/4/22

Name Mr. Buchireddy Srikanth Age 35 Yrs  
Reddy

Sex M/F

### EARS :

### Right

### Left

EAC

: patent no cerumen.

- do

TM

: Instab. pearly white.

- do

TFT

: Cone of light (+)  
Rinne's +ve

Rinne's +ve.

Weber's - Central

NOSE

: Septum (a). Bil. Tur's hypertrophied (a). PARS (a). ant.

THROAT

: Oropharynx (a). Bil. uv. c. c. (a). moving

NECK

: (a)

Axillary } bil

IMPRESSION:

Ears clinically normal.

*Dr. Hari Krishna Reddy*

Dr. D. Hari Krishna Reddy  
MS (ENT)

Head & Neck Surgeon

Reg. No: 88379

779968970

Name : B. Srikanth Reddy Sex : M Age : 36

Date : 7/9/2021

pt Came for routine checkup.

OPD No : .....

Rx

- ① Adv. Restoration
- ② Adv. oral prophylaxis -

**Smilesss**   
 ILTI SPECIALITY DENTAL CLINIC  
 Smile Confidentially... Not Confidentially...  
 B.D.S, IMPLANTOLOGIST (USA)  
 Rajamudaliar Street, Kalam

--	--	--	--	--	--

--	--	--	--	--	--



# PARKLINE DIAGNOSTICS PVT. LTD.

L.G 3, 4 & 5, Bhuvana Towers, Sarojini Devi Road, Secunderabad - 500 003.  
Tel. +91 40 2784 5852, 6649 1787, 77995421787, 7093445852, Fax : + 91 40 2784 7864  
Email : parklinediagnostics@gmail.com, www.parklinediagnostics.com



NABL Accredited  
Certificate No.: MC-2566

## TEST REPORT

Name	: Mr . BUCHIREDDY SRIKANTHREDDY [9745	TID	: UMR0759407
Age / Gender	: 35 Years / Male	Registered on	: 04-Apr-2022 09:43 AM
Ref.By	: Medi Wheel	Reported On	: 04-Apr-2022 01:17 PM
Req. No	: BIL1927373		

### ABDOMINO-PELVIC ULTRASONOGRAPHY

**LIVER** is normal shape, size ( 14.1 cms) and increased echopattern.  
No evidence of focal lesion or intrahepatic biliary ductal dilatation.  
Hepatic and portal vein radicals are normal.

**GALL BLADDER** shows normal shape and has clear contents.  
Gall bladder wall is of normal thickness.  
CBD is of normal calibre.

**PANCREAS** has normal shape, size and uniform echopattern.  
No evidence of ductal dilatation or calcification.

**SPLEEN** shows normal shape, size ( 10.4 cms) and echopattern.

**KIDNEYS** move well with respiration and have normal shape, size and echopattern. Cortico-medullary differentiations are well madeout.  
No evidence of calculus or hydronephrosis.  
Right kidney measures: 10.6 x 4.0 cms, Left kidney measures: 10.3 x 4.7 cms.  
Cyst measuring 16 x 11 mm is noted in the left parapelvic region.

**URINARY BLADDER** shows normal shape and wall thickness.  
It has clear contents. No evidence of diverticula.

**PROSTATE** : Normal in size and echotexture.  
Its measures : 3.2 x 4.5 x 2.4 cms,. Volume : 19.4 cc

No evidence of free fluid in the abdomen

#### IMPRESSION:

- \* **Grade I Fatty liver.**
- \* **Simple left parapelvic cyst.**

Suggested clinical correlation and follow up

  
Dr. Karuna Belide  
Consultant Radiologist

The Test marked with\* are not accredited by NABL

Lab Timings (Weekdays) : 7.00 am to 8.30 pm  
Sundays & Holidays : 7.00 am to 1.00 pm

Radiologists Timings (Weekdays) : 7.30 am to 1.30 pm  
& 5.30 pm to 7.45 pm  
Sundays & Holidays : 7.30 am to 9.30 am

Page:1 of 1



# PARKLINE DIAGNOSTICS PVT. LTD.

L.G 3, 4 & 5, Bhuvana Towers, Sarojini Devi Road, Secunderabad - 500 003.  
Tel. +91 40 2784 5852, 6649 1787, 77995421787, 7093445852, Fax : + 91 40 2784 7864  
Email : parklinediagnostics@gmail.com, www.parklinediagnostics.com



NABL Accredited  
Certificate No.: MC-2566

## TEST REPORT

Name : Mr . BUCHIREDDY SRIKANTHREDDY [9745  
Age / Gender : 35 Years / Male  
Ref.By : Medi Wheel  
Req. No : BIL1927373

TID : UMR0759407  
Registered on : 04-Apr-2022 09:43 AM  
Reported On : 04-Apr-2022 11:14 AM

### X-RAY CHEST PA VIEW

Lung fields are clear.

Cardia is normal.

Hila are normal.


C P angles are free.

Bony cage is normal.

Soft tissues are normal.

IMPRESSION : NORMAL CHEST X-RAY



  
Dr. D.J. MOHAN  
MD DMRD  
(Reg No. 8095)  
Consultant Radiologist

The Test marked with\*are not accredited by NABL

Lab Timings (Weekdays) : 7.00 am to 8.30 pm  
Sundays & Holidays : 7.00 am to 1.00 pm

Radiologists Timings (Weekdays) : 7.30 am to 1.30 pm  
& 5.30 pm to 7.45 pm  
Sundays & Holidays : 7.30 am to 9.30 am



MR.BUCHIREDDY SRIKANTH REDDY

Male 35Years

NSR  
WUC



HR : 67 bpm  
P : 120 ms  
PR : 175 ms  
QRS : 88 ms  
QT/QTc : 377/399 ms  
P/QRS/T : 30/43/10 °  
RV5/SV1 : 1.753/0.614 mV

**Dr. NAVEEN KUMAR .C**  
M.D., D.M.  
**Consultant Cardiologist**  
Reg. No. 52291

Diagnosis Information:  
Sinus Rhythm  
Poor R Wave Progression(V3)

Report Confirmed by:

PATIENT SUMMARY REPORT

DIAGNOSTICS PVT.LTD

1927373

MRS.BUCHIREDDY SRIKANTH REDDY

35 / MALE

HEIGHT (cm) : 182  
WEIGHT (kg) : 96  
PROTOCOL : BRUCE

REF. BY : MEDIWHEEL  
DONE BY : DR.NAVEEN KUMAR  
TECHNICIAN : G.M.SURESH

04-04-2022, 12:27:  
RAC

TORY :

ON :

OF TEST :

Routine Check Up.

TOR :

None.

Very Active.

VESTIGATION :

E C G

FOR TERMINATION :

THR ACHIEVED

SE TOLERANCE :

Good (> 10 METS).

SE INDUCED ARRHYTHMIAS :

No.

RESPONSE :

Normal.

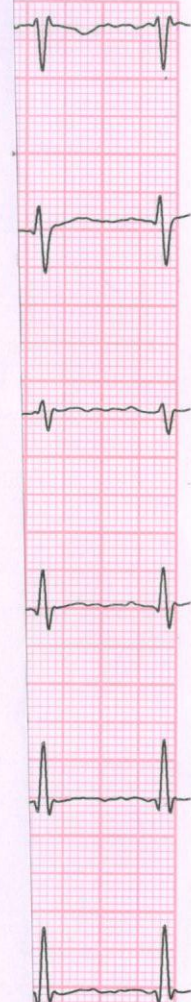DO RESPONSE :

Normal.

MPRESSION :

*Negative for inducible ischemia*

OMMENTS :



Confirmed By :

**Dr. NAVEEN KUMAR .C**  
Signature

**Consultant Cardiologist**  
Reg. No. 52291

Page No.: 1

BPL DYNATRAC

Tested On 04-04-2022, 12:27:40

BC