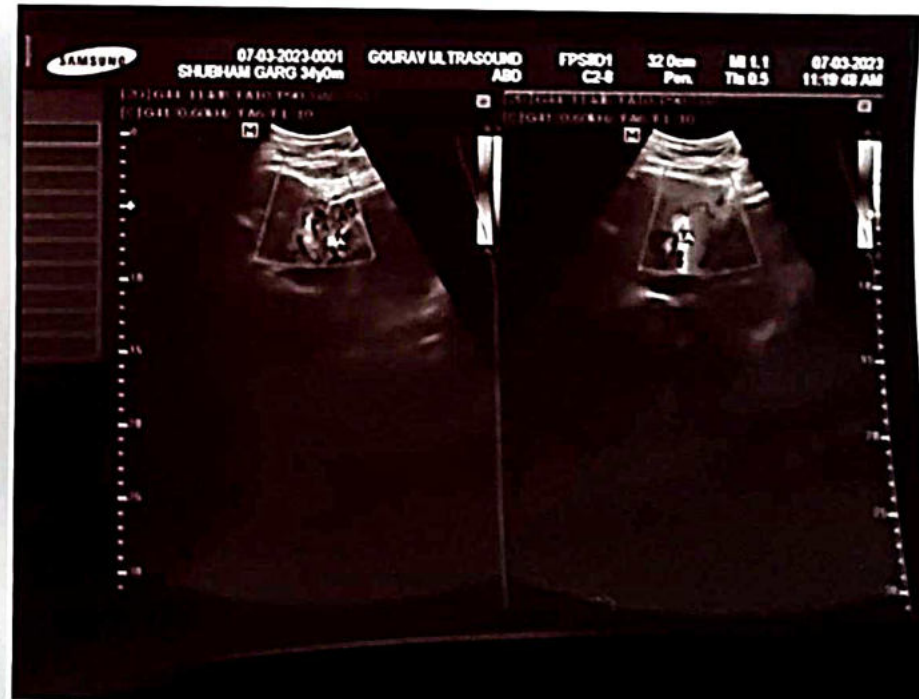
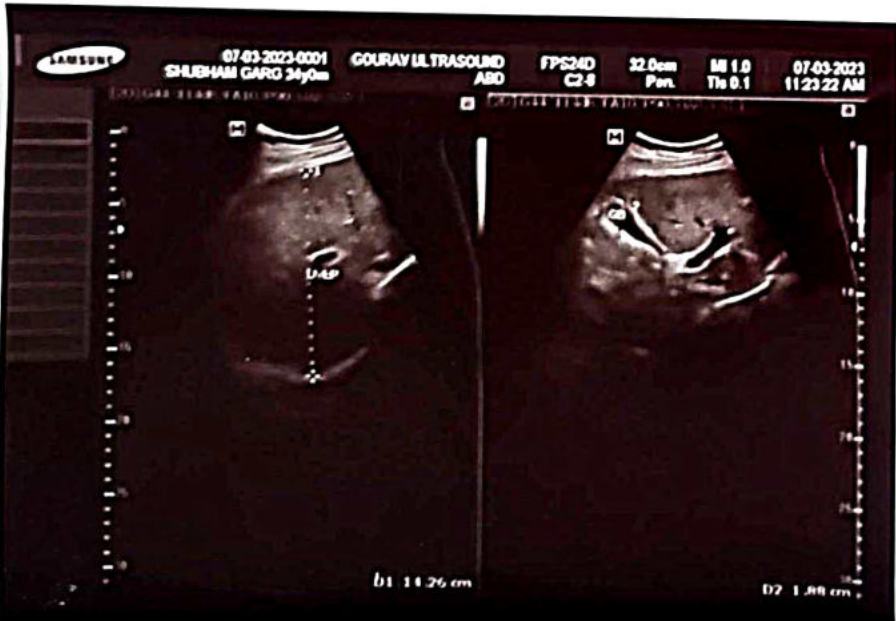
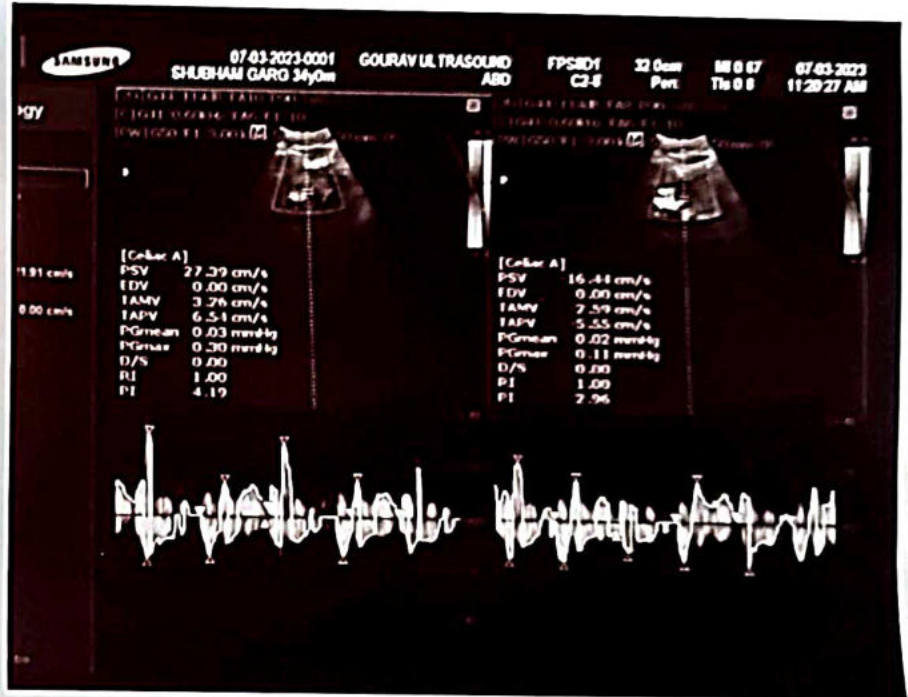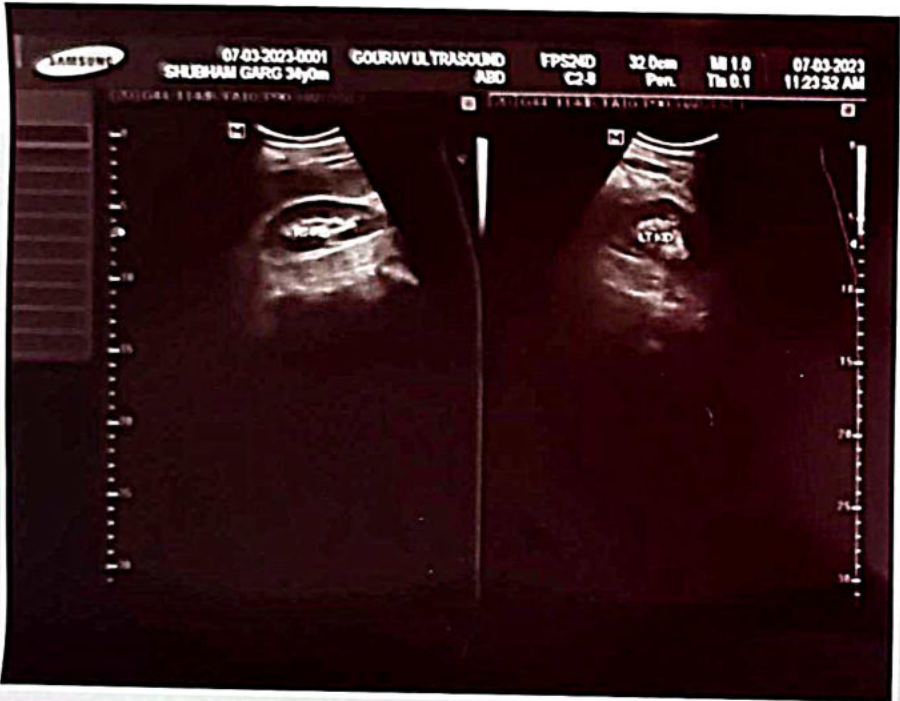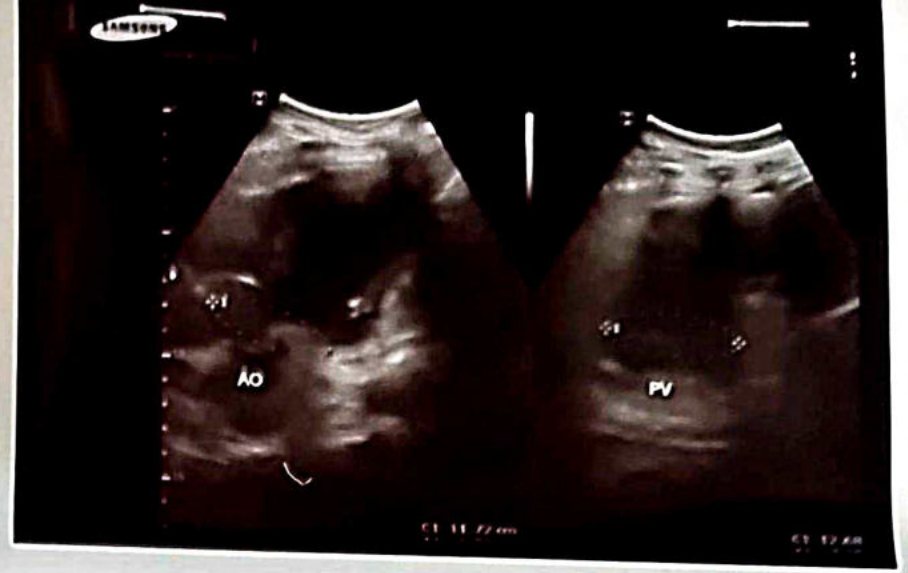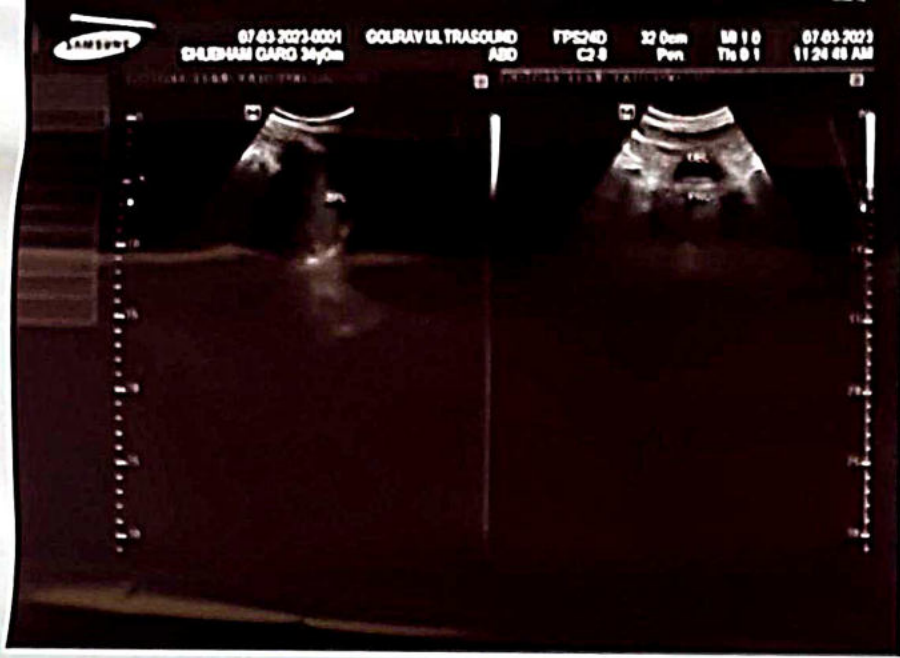GAURAV NURSING HOME

TIKHAMPUR (NEAR CHHAYA CINEMA)BALLIA

PATHOLOGY REOPRT

Regn. No.: 10396
Patient Name: Shri SHUBHAM KUMAR GARG
Address:
Referred By: Dr. D. RAI MD

Date : 07-03-2023
Age: 34 Years Sex: Male

BIO CHEMISTRY

Serum Albumin	04.00 gm%	(3-5gm%)
Seum Glubolin	03.20 gm%	(1.5-3.5gm%)

URINE ANALYSIS

Urine Routine Analysis

<u>Macroscopic Finding</u>		<u>Microscopic Finding</u>	
Quantity	Sufficient	Pus Cells	3-4 /HPF
Colour	Pale Yellow	RBCs	Not Seen /HPF
Appearance	Transparent	Epith. Cells	2-3 /HPF
Sediment	NIL	Bacteria	Not Seen /HPF
Reaction	6.0	Casts	Not Seen /HPF
Sp. Gravity	1.05	Crystals	Not Seen /HPF
		Spermatazoa	Not Seen /HPF
		Parasites	Not Seen /HPF

Chemical Finding

Glucose	NIL
Protien	Trace

REMARK Fresh Urine Sample is Examined

End of Report

HBA1C

5.2

GAURAV
Pathologist/Technician
Maha Pathological Centre
W.B.S.P.C.P.
DNB (Path.) PGDMCH
Regd. No.-59481 (KMC)
Gaurav Multispeciality Hospital
Tikhampur, Ballia
(4-6%)

GAURAV NURSING HOME

TIKHAMPUR (NEAR CHHAYA CINEMA)BALLIA

PATHOLOGY REOPRT

Regn. No.: 10396
Patient Name: Shri SHUBHAM KUMAR GARG
Address:
Referred By: Dr . D. RAI MD

Date : 07-03-2023
Age: 34 Years Sex: Male

Cardiac/Lipid Profile

Total Serum Colestrol	152.00 mg%	(150-250mg%)
Serum HDL Cholestrol	30.00 mg/dl	(Male: 30-70mg/dl)
Serum LDL Cholestrol	99.00 mg%	(60-115mg%)
VLDL	23.00 mg%	(15-30mg%)
Serum Try Glyceride	118.00 mg/dl	(25-160mg/dl)

CBC

Haemoglobin	13.2 g/dl	(Male: 13.5-18.0g/dl)
Total Leucocyte Count	5400 /cumm	(4000-11000/cumm)

Differential Leucocyte Count

Nutrophils	55 %	(50-70%)
Eosinophils	02 %	(1-4%)
Basophils	00 %	(0-1%)
Lymphocytes	43 %	(20-30%)
Monocytes	00 %	(1-3%)
Blast Cells	00 %	(0-1%)
Toxic/Bend Cells	00 %	(0-1%)
Platelets Count	01.85 Lacs/cumm	(1.5-4Lacs/cumm)
Total RBCs Count	05.01 mill/cumm	(Male: 3.8-5.3mill/cumm)
M.C.V.	95.7 fl	(80-100fl)
M.C.H.	29.6 Pg	(27-32Pg)
M.C.H.C.	34.5 g /dl	(32-36g /dl)

Dr. CHALNA
M.B.B.S., D.C.P.
DNB (Path.) PGDMCH
Pathologist & Clinician
Gaurav Nursing Home
Tikhampur, Ballia

GAURAV NURSING HOME

TIKHAMPUR (NEAR CHHAYA CINEMA)BALLIA

PATHOLOGY REOPRT

Regn. No.: 10396

Patient Name: Shri SHUBHAM KUMAR GARG

Address:

Referred By: Dr. D. RAI MD

Date : 07-03-2023

Age: 34 Years Sex: Male

Liver Profile

Serum Total Bilirubin	00.68 mg%	(0.2-1mg%)
Serum Direct Bilirubin	00.26 mg%	(0-0.2mg%)
Serum Indirect Bilirubin	00.32 mg%	(0-0.8mg%)
SGPT	39.00 unit	(5-35unit)
SGOT	24.00 unit	(5-45unit)
Serum Alkaline Phosphatase	96.00 IU/L	

Normal Range:- Male: 50 - 126 (20-50 years), 57 - 111 (>60 years)

Normal Range:- Female: 37 - 103 (20 - 50 years), 50 - 143 (>60 years)

Higher Value Seen in growing children

HAEMATOLOGICAL REPORT

Blood Group	"O"	
RH Type	Positive	
E.S.R. (Windrops)	10 mm/hr.	(Male: 0-9mm/hr.) (Female: 0-20mm/hr.)

BIO CHEMISTRY

Fasting Plasma Glucose	82.00 mg%	(70-110mg%)
Post Prandial Glucose	105.00 mg%	(70-140mg%)
(Afte 2 Hrs. of taking meal)		
Serum Urea	21.00 mg/dl	(13-45mg/dl)
Serum Creatinie	00.71 mg/dl	(Male: 0.7-1.4mg/dl)
Total Serum Protien	07.20 gm%	(6-8gm%)

Dr. CHALNA
Pathologist & Technician
Gaurav Multispecialty Pathological Centre
Regd. No. - 59481
Gaurav Multispecialty
Tikhampur, Ballia

Electrocardiogram Report

• Patient Name SHUBHAM CHARY

Age 34/M Date 07/31/2023

• Clinical summary NOCOMPLAINT

• ECG Findings

• Rate 78

Rhythm Regular Mechanism SINUS Axis NORMAL

• P wave UPRIGHT

PR Interval 0.16 sec complex 0.08 sec

• ST Segment 0.25 sec

T Wave UPRIGHT Q Wave ABSENT QT interval 0.36 sec

• Diagnosis NORMAL

• Impression NORMAL

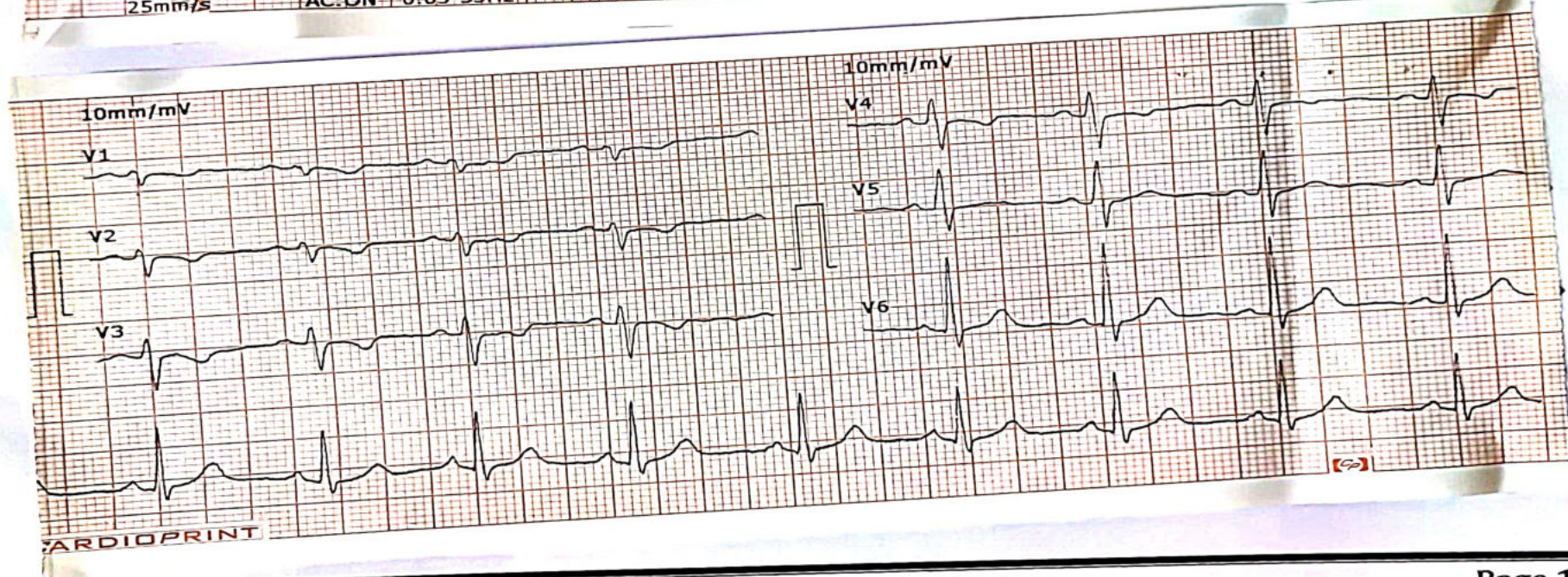
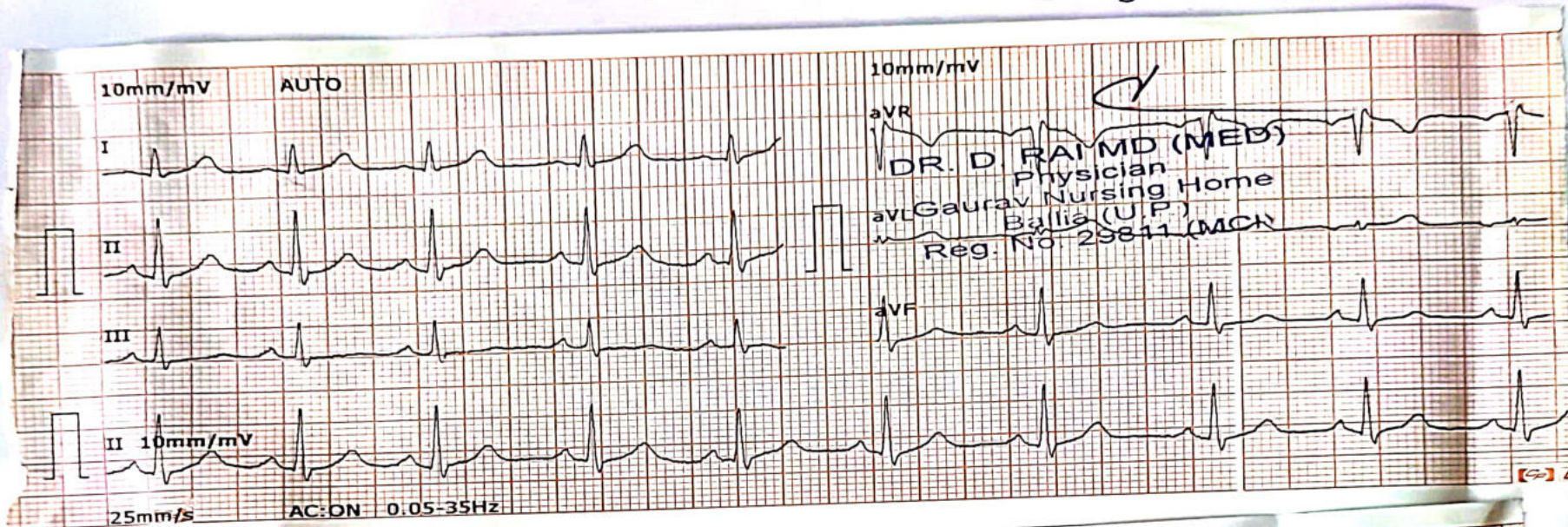
• Speed 25 mm

• Voltage 10 mm

DR. D. RAI MD (MED)
Physician
Gaurav Nursing Home
Ballia (U.P.)

Reg. No. 29811 (MCI)

■ Dr. signature



**GAURAV MULTI SPECIALITY HOSPITAL
TIKHAMPUR= BALLIA**

PATIENT SHUBHAM GARG
REFERD BY DRD.RAI...(M.D).....

DATE 07/03/2023
AGE 34/M

CHEST X-RAY PA

INVESTIGATION: X Ray Chest PA View

- Both the lungs field are equally translucent
- Cardiac out line are normal
- The Costo-phernic angle are clear

Heart size and Cardiac out line are Normal

- No hilar Meditational mass is seen
- No obvious Skeletal abnormality Seen

EMPRESSION : normal chest x ray .

Dr. Seema Pandey (Radiologist)
M.B.B.S., M.D.
38790
SIGNATURE



Ph: 05498-241635

Gaurav Multispeciality Hospital

Near Chhaya Cinema, Tikhampur, Ballia (U.P.)

Dr. D. Rai

M.B.B.S (Hons.)
M.D. (General Medicine).IMS BHU
Cardiologist & General Physician
Member
Association of Physician of India

Consultation Time

7am to 10am
11am to 7pm

SHUBHAM GARY 34/m

A NO CONSUME MEDICINE

ALL REQUIRE AS NOTED

07/03/2023

wt 62

BP-110/80

SpO2-99

PR-84

T-97.6F

wt-62kg

DR. D. RAI MD (MED)
Physician
Gaurav Nursing Home
Ballia (U.P.)
Reg. No. 23811 (MCI)

विशेष सुविधायें:

- ◆ 24 घण्टे इमरजेन्सी एवम् एम्बुलेन्स सेवा, कम्प्यूटर द्वारा फेफड़े की जाँच, वेन्टिलेटर तथा कार्डियक मानिटर से सुसज्जित आई.सी.सी.यू., यातानुकूलित प्राइवेट वार्ड, जनरल वार्ड, हृदय रोग, न्यूरोलॉजी, पेट, उदर, श्वास, छत्रती रोग, मधुमेह तथा रक्तचाप, सभी प्रकार की सर्जरी, प्लास्टिक सर्जरी, नार्मल डिलेवरी, सिजेरियम, इको टी.एम.टी., डिजिटल एक्सरे, अल्ट्रासाउण्ड, पैथोलॉजी तथा मेडिकल स्टेर, आयुष्मान कार्ड धारक एवं मृतपूर्व सैनिक (ECHS) के मरीजों का निःशुल्क इलाज की सुविधा तथा हृदय के मरीजों का सम्पूर्ण इलाज तथा आपरेशन की सुविधा उपलब्ध है।

नोट-यह पर्ची केवल दस दिनों हेतु मान्य है।

GAURAV MULTI SPECIALITY HOSPITAL
TIKHAMPUR= BALLIA
ULTRA SOUND REPORT

PATIENT. SHUBHAM GARG
REFERD BY DR SELF

DATE 07/03/2023
AGE 34/M

LIVER

Liver normal in shape and size & size is 14.2 Cm. Intrahepatic biliary radicals, portal veins and hepatic veins are not dilated. Echodensity is normal. No mass seen in liver.

GALL BLADDER.

Gall bladder normal in shape and size in 2.1mm. no stone or mass seen in gallbladder wall thickness normal.

C.B.D. : Normal in caliber.

PANCREAS.

Pancreas is normal in shape, size and echo pattern.

SPLEEN.

Spleen is normal in shape and size & size is 10.6 cm.

KIDNEYS

Rt kidney is normal in shape and size. Lt kidney is also normal in shape and size. Cortico-medullary differentiation is normal and no evidence of hydronephrosis or nephrolethiasis seen..

URINARY BLADDER

Normal in shape, size inner mucosal thickening. Echopattern is normal. No calculi / Mass / Lesion is seen.

PROSTATE

It is normal in size, measures Capsules are normal & Intact. It's volume is about 21 cc./Gms.

IMPRESSION

1. LIVER NORMAL.
2. GALL BLADDER NORMAL.
3. CBD NORMAL.
4. BOTH KIDNEYS NORMAL.
5. SPLEEN NORMAL.
6. URINARY BLADDER NORMAL
7. PROSTATE NORMAL.
8. GASEOUS BOWEL'S LOOPS.

Dr. Seema Pandey (Radiologist)
M.B.B.S., M.D.
Reg. No. -38790
SONOLOGIST

R

SHUBHAM 34 year(s) Male

Chest PA

GAURAV

NOT FOR MEDICO LEGAL PURPOSE

GAURAV MULTI SPECIALITY HOSPITAL TIKHAMPUR= BALLIA

PATIENT. SHUBHAM GARG
REFERED BY DR SELF

DATE 07/03/2023
AGE 34/M

ECHOCARDIOGRAPHY & COLOR DOPPLER REPORT

Quality of Imaging : Fair.

MEASUREMENT/DIMENSIONS	ABSOLUTE VALUE	NORMAL (Adult)
Aortic Root Diameter	24.2 mm.	20 – 37 mm. < 22 mm/ m2
Aortic Valve Opening	19.7 mm.	15 – 26 mm.
Left Atrial Dimension	37.6 mm.	19 - 40 mm. < 22 mm/ m2
RV Dimension	21 mm.	07 – 26 mm.
RV Thickness	8.8 mm.	03 – 09 mm.
LV ED Dimension	39.2 mm.	37 - 56 mm. < 32 mm/ m2
LV ES Dimension	26.7 mm.	22 - 40 mm.
IVS Thickness	9.1 mm.	09 – 11 mm.
LVPW Thickness	10.3 mm.	05 – 11 mm.
Mitral Valve Area	5.75 cm2	> 6 cm2 .
Tricuspid Valve Area	6.49 cm2	> 7 cm2 .
IVSeD / IV SeS	06 – 10 mm	06 – 12 mm.

MORPHOLOGICAL					
Mitral Valve	Normal	Right Ventricle	Normal	Inter Atrial Septum	Normal
Tricuspid Valve	Normal	Left Ventricle	Normal	I.Ventricular Septum	Normal
Aortic Valve	Normal	Right Atrium	Normal	Aorta	Normal
Pulmonary Valve	Normal	Left Atrium	Normal	Pulmonary Artery	Normal

2 D IMAGING :

LV/ RV/ LA/ RA. Are all normal sized.

Mitral & Aortic Valves are almost normal.

Tricuspid & Pulmonary valve are normal.

I.V. Systolic function : Good.

I.V. Diastolic function : Good.

M.R./A.R./ & T.R./P.R. : Not Audible.

LV Ejection Fraction = 58%.

RV Function : Normal.

Dr. Seema Pandey (Radiologist)
M.B.B.S., M.D.
Reg. No.-38790

Continued Pg. 2.

GAURAV MULTI SPECIALITY HOSPITAL TIKHAMPUR= BALLIA

PATIENT. SHUBHAM GARG
REFERD BY DR SELF

DATE 07/03/2023
AGE 34/M

ECHOCARDIOGRAPHY & COLOR DOPPLER REPORT

Page : 2.

Regional Wall Motion Abnormality (RWMA) : Normal at Rest.

Sinus Rhythm with H.R.:- 104 BpM.

DOPPLER STUDY :

MR 0/4 ; TR 0/4 ; / AR 0/4 ; PR 0/4. (Normal Value 0-1 / 4).

PA Pressure : Normal.


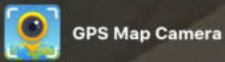
COLOR FLOW MAPPING :

No Regurgitation Audible at TR, MR, / AR, PR.

FINAL IMPRESSION :

1. SINUS RHYTHM WITH NORMAL VENTRICLES (LV & RV).
2. NORMAL LV EJECTION FRACTION ; LVEF = 58 %.
3. MITRAL & AORTIC VALVES ARE NORMAL.
4. GOOD LV, S & D FUNTION & GOOD RV, S & D FUNTION.
5. NO RWMA ; NO CARDIOMAYOPATHY / CARDIOMEGALY.
6. SINUS RYTHM IS IS APPARENT.

Dr. Seema Pandey Radiologist
M.B.B.S., M.D.
CARDIOLOGIST



Ballia, Uttar Pradesh, India
Q5C3+Q65, Ballia, Uttar Pradesh 277001, India
Lat 25.772224°
Long 84.153137°
07/03/23 10:57 AM GMT +05:30