

 भारत सरकार
GOVERNMENT OF INDIA


 देवकरान मीणा
Devkaran Meena
जन्म वर्ष / Year of Birth - 1966
पुरुष / Male




5408 5654 8547


आधार – आम आदमी का अधिकार


[Handwritten signature]


 भारतीय विशिष्ट पहचान प्राधिकरण
UNIQUE IDENTIFICATION AUTHORITY OF INDIA

पता: S/O. रामजी लाल मीणा, ई-250, अम्बेडकर नगर, अलवर, राजस्थान, 301001
Address: S/O: Ramji Lal Meena, E-250, Ambedkar Nagar, Alwar, Rajasthan, 301001

 1947
1800 180 1947

 help@uidai.gov.in

 www.uidai.gov.in

 P.O. Box No 1947
Bengaluru-580 001

[Handwritten signature]
Dr. M. N. THAREJA
MBBS
Thareja Nursing Home
Alwar-301001, (Raj.)



THAREJA NURSING HOME

1, Ram Kuteer Company Bagh Road, ALWAR - 301001 (Raj.)
Mob. 9982111801, Ph. 0144-2700184, 2331842, Telefax: 0144-2342339
E-mail: drmnthareja@yahoo.com



Name Dev Kanan Meena Age 56 Yr OPD/UHID..... Date 10-12-22

Address Mobile No. 94143819936

VITALS	B.P.	Pulse	Temp.	Wt.	Ht.	Allergies
--------	------	-------	-------	-----	-----	-----------

Complaints

Pt. came for regular dental checkup. (within normal limit)

Findings

Contd'

Investigation

—

Treatment

Maintain oral hygiene

DR. M.N. THAREJA
7233 (RMC)
Male Infertility Specialist

DR. SAVITA THAREJA
7600 (RMC)
Female Infertility Specialist

DR. JAYANT THAREJA
A-0824 (RSDC)
M.D.S.
Oral & Maxillo - Facial Surgery
Ex Resident Trauma Centre,
AIIMS, Delhi

DR. SHIVANI THAREJA
10807 / 31220 (RMC)
Ophthalmologist
Cornea Specialist

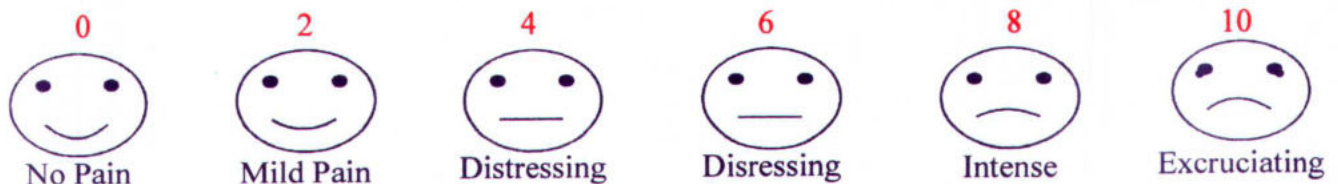
DR. PRERNA THAREJA
A-3574
MDS (Endodontics)
Root Canal Specialist
Ex Resident
AIIMS, Jodhpur

DR. H.R. GUPTA
1744 (RMC)
Senior Consultant
M.S. Gen Surgeon

DR. VARUN SAPRA
Reg. No. 70990 (DMC)
MBBS DNB ORTHO, D.ORTHO
Joint Replacement &
Arthroscopy Surgeon

Dr. Prerna Thareja
MDS (Endodontics)
Diploma in Oral Implantology
Diploma in Hospital Administration
Ex Senior Resident AIIMS, Jodhpur
Life Member GCI A-3574

Pain Scale





THAREJA NURSING HOME

1, Ram Kuteer Company Bagh Road, ALWAR - 301001 (Raj.)
Mob. 9982111801, Ph. 0144-2700184, 2331842, Telefax: 0144-2342339
E-mail: drmnthareja@yahoo.com



Name Dev karam meens Age..... Yr OPD/UHID..... Date 10/12/22

Address Mobile No.....

VITALS	B.P.	Pulse	Temp.	Wt.	Ht.	Allergies
--------	------	-------	-------	-----	-----	-----------

Complaints

Routine eye check-up.

DR. M.N. THAREJA
7233 (RMC)
Male Infertility Specialist

DR. SAVITA THAREJA
7600 (RMC)
Female Infertility Specialist

Findings

VA $\begin{matrix} 6/9 \\ 6/9 \end{matrix}$ eyeglasses

DR. JAYANT THAREJA
A-0824 (RSDC)
M.D.S.
Oral & Maxillo - Facial Surgery
Ex Resident Trauma Centre,
AIIMS, Delhi

Investigation

N6
N6

DR. SHIVANI THAREJA
10807 / 31220 (RMC)
Ophthalmologist
Cornea Specialist

Colour vision- colour vision within
Normal limit BLE.

DR. PRERNA THAREJA
A-3574
MDS (Endodontics)
Root Canal Specialist
Ex Resident
AIIMS, Jodhpur

Treatment

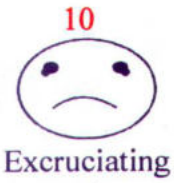

Adv
① Continue glasses

DR. H.R. GUPTA
1744 (RMC)
Senior Consultant
M.S. Gen Surgeon

Shivani
Dr. Shivani Thareja
M.S. (OPHTHAL)
Fellow (CORNEA)
L.V. Prasad Eye Institute
CORNEA CONSULTANT

DR. VARUN SAPRA
Reg. No. 70990 (DMC)
MBBS DNB ORTHO, D.ORTHO
Joint Replacement &
Arthroscopy Surgeon

Pain Scale





THAREJA NURSING HOME



DIGITAL X-RAY, OPG, COMPUTERISED ECG & EEG, DIAGNOSTIC
LABORATORY EQUIPED WITH COMPUTERISED AUTO ANALYZER & CBC

1, Ram Kuteer, Company Bagh Road, ALWAR - 301001 (Raj.) Ph: 0144-2700184, 2331842

Name : **DEV KARAN MEENA**

Age : **56**

Sex : **MALE**

Ref. By : **M N THAREJA**

Lab No. :

Date : **December 10, 2022**

Immunology

<u>Test</u>	<u>Value</u>	<u>Units</u>	<u>Biological Ref. Values</u>
Prostate Specific Antigen (PSA)	0.10	ng/mL	< 4 ng/mL

Method : **Fluorescence Immunoassay Technology**


Sample Type : **Serum / Plasma / Whole Blood**

Supported By : **GYRO DIAGNOSTICS, JAIPUR**

Clinical Information :

Prostate Specific Antigen (PSA) is a Neutral Serine Protease with Chymotrypsin-like activity and Composed of a Single Polypeptide chain of 237 Amino Acids. It is an Intracellular Glycoprotein Containing 7-8% Carbohydrate as a Single N-linked Oligosaccharide side Chain, and has a Molecular Weight of Approximately 33 KDa. PSA is Synthesized by the Glandular Epithelium of the Prostate and Present in benign Hyperplastic and Malignant Prostatic Tissue, in Metastatic Prostatic Carcinoma, in Prostatic Fluid, and Seminal Plasma. Low Levels of PSA are Found in the Blood of Normal Male as a Result of Leakage of the Antigen from the Prostate Gland into Circulation. The Elevated Levels of PSA in the Blood are Associated with Prostatic Pathology, including Prostatitis, Benign Prostatic Hyperplasia (BPH), and Prostate Cancer.


Signature of Technician


Signature of Doctor
Dr. M N THAREJA
MBBS
Thareja Nursing Home
Alwar-301001, (Raj.)

This Report is not Valid for Medical Legal Purpose



THAREJA NURSING HOME



DIGITAL X-RAY, OPG, COMPUTERISED ECG & EEG, DIAGNOSTIC LABORATORY EQUIPED WITH COMPUTERISED AUTO ANALYZER & CBC

1, Ram Kuteer, Company Bagh Road, ALWAR - 301001 (Raj.) Ph: 0144-2700184, 2331842

Name : **DEV KARAN**

age **56**

Sex : **MALE**

Ref. By : **M.N. THAREJA**

Lab No. :

Date : **December 10, 2022**

HORMONES & MARKERS

Test	Value	Units	Biological Ref. Values
T3 (Total Triiodothyronine)	1.10	ng/dL	0.60-1.81 ng/dL Adults
T4 (Total Thyroxine)	4.21	µg/dL	3.2-12.60 µg/dL : Adults
TSH (Thyroid Stimulating Hormone)	2.39	µIU/mL	Adults : 0.35-5.50 µIU/mL

Interpretation of TSH :-

Children

0 Days : 1.0~39.0 uIU/mL

5 days : 1.7~9.1 uIU/mL

1 year : 0.4~8.6 uIU/mL

2 years : 0.4~7.6 uIU/mL

3 years : 0.3~6.7 uIU/mL

4-19 years : 0.4~6.2 uIU/mL

Adults

20-54 years : 0.35-5.50 uIU/mL

55-87 years : 0.5-8.9 uIU/mL

Pregnancy

1st Trimester : 0.30 - 4.50 µIU/mL

2nd Trimester : 0.50 - 4.60 µIU/mL

3rd Trimester : 0.80 - 5.20 µIU/mL

Interpretation of TSH :-

Children

3.20 - 34.6 µIU/mL 1- 2 Days

0.70 - 15.4 µIU/mL 3 - 4 Days

0.70 - 9.10 µIU/mL 15 Days - 5 Months

0.70 - 6.40 µIU/mL 5 Months - 20 Years

Pregnancy

0.30 - 4.50 µIU/mL 1st Trimester

0.50 - 4.60 µIU/mL 2nd Trimester

0.80 - 5.20 µIU/mL 3rd Trimester

Method : **Fluorescence Immunoassay Technology**

Sample Type : **Fresh Blood Serum**


Remarks :

Primary malfunction of the Thyroid gland may result in excessive (hyper) or Low (hypo) release of T3 or T4. In addition, as TSH directly affect thyroid function, malfunction of the pituitary or the hypothalamus influences the thyroid gland activity.

Disease in any portion of the thyroid-pituitary-hypothalamus system may influence the level of T3 and T4 in the blood, in Primary Hypothyroidism,

TSH levels are significantly elevated, while in secondary and tertiary hypothyroidism, TSH levels may be low. In addition, in Euthyroid sick syndrome, multiple alterations in serum thyroid function test findings have been recognized.


Signature of Technician


Dr. M.N. THAREJA
MBBS
Thareja Nursing Home
Signature of Doctor
Alwar-301001. (Raj.)



THAREJA NURSING HOME



DIGITAL X-RAY, OPG, COMPUTERISED ECG & EEG, DIAGNOSTIC LABORATORY EQUIPED WITH COMPUTERISED AUTO ANALYZER & CBC

1, Ram Kuteer, Company Bagh Road, ALWAR - 301001 (Raj.) Ph: 0144-2700184, 2331842

PROPOSAL NO. 155289

Patient Name ME DEV KARAN MEENA

Ref. By Dr. M. N. THAREJA

Date

10/12/2022

Age

56 Yrs.

Sex

M

Details of packages		Patients report	Units	Normal value
HB		15.9	gm%	M-13.5-18, F-11.5-16.5
TRBC		5.53	million /cu mm	M-4.0-5.5, F-3.9-5.6
TWBC		10,500	cu mm	4000-11000
DLC	Polymorphs	60	%	42-75
	Lymphocytes	32	%	20-50
	Eosinophil	08	%	1-6
ESR		03	mm 1 st Hr.	M-0-9, F-0-20
Platelets		1,61,000	Lack / cu mm	1.5-4
PCV		44.7	%	37-54
MCV		80.8	Cubicmicrons	86-98
MCH		28.8	Picograms	26-34
MCHC		35.6	%	32-36
Blood Grouping & Rh Factor		" O "Rh+(POSITIVE)		
BUN		12.0	mg %	M-7-20
S. Creatinine		0.81	Mg/100ml	0.9-1.4 mg /100 ml
HBsAg		-		
HIV I & II		-	Elisa Method	
HbA1C		6.0	%	4-6%
VDRL		-		

Details of packages		Patients report	Units	Normal value
LFT	GGTP	26.0	U/L	5-60
	SGOT	20.0	Units / ml	Upto 40
S. Bilirubin	SGPT	23.0	Units / ml	Upto 40
	Total Bilirubin	0.61	mg%	Upto 1.2
	Direct Bilirubin	0.20	mg%	0-0.25
	Indirec Bilirubin	0.41	mg%	
	T. Protein	7.62	Gm%	6.2-8.3
	S. Albumin	4.38	Gm%	3.2-5.3
	Globulin	3.24	Gm%	
	Alkaline phosphate	110.0	IU/L	60 - 170
	S. Calcium	-	Gm%	8.5-10.5
	Uric Acid	3.7	Mg%	2.5-7 mg%
Blood Sugar Fasting		96.0	Mg%	60-110 mg %
Blood Sugar PP		105.0	Mg%	Upto 160
Lipid Profile	S. Cholesterol	193.0	mg%	120-220
	S. Triglycerides	110.0	mg/ml	Upto 170
	HDL Cholesterol	52.0	IU/L	
	LDL cholesterol	119.0	IU/L	450 at 37° C
	VLDL	22.0	mg %	Upto 35

Routine Urine Analysis

Physical/ Chemical		Microscopic:	
Appearance	Clear	RBCs	Nil
Specific Gravity	1010	WBCs	1-2 HPF
Ph	ACIDIC	Epith. Cells	1-2/HPF
Albumin	Nil	Casts	Nil
Glucose F	NIL	Crystals	Nil
Ketones	-----	Bacteria	Nil
Blood	Nil	Glucose P.P.	NIL

Signature of Technician

Dr. M. N. THAREJA
Signature of Doctor
Thareja Nursing Home
Alwar-301001, (Raj.)

This Report is not Valid for Medical Legal Purpose



THAREJA NURSING HOME



DIGITAL X-RAY, OPG, COMPUTERISED ECG & EEG, DIAGNOSTIC
LABORATORY EQUIPED WITH COMPUTERISED AUTO ANALYZER & CBC

1, Ram Kuteer, Company Bagh Road, ALWAR - 301001 (Raj.) Ph: 0144-2700184, 2331842

PROPOSAL NO.

Date 10/12/2022

Patient Name DEV KARAN MEENA

Age 56 Yrs.

Ref. By Dr. M. N. THAREJA

Sex M

PART - X-RAYED : X-RAY CHEST PA VIEW
REPORT : X-RAY CHEST P.A. VIEW
:- Chest is bilaterally symmetrical.
:- C.P. Angles are clear.

CONCLUSSION: NORMAL STUDY

Vijay
Signature of Technician

Dr. M. N. THAREJA
M.N. Thareja
MEBS
Thareja Nursing Home
Signature of Doctor
Alwar-301001, (Raj.)

This Report is not Valid for Medical Legal Purpose

Pat-Name:

Devkaram meera

HR 60/min

Axis:

SINUS RHYTHM

P 34°

LEFTWARD AXIS

QRS -21°

OTHERWISE NORMAL ECG

T 12°

Intervals:

RR 1007 ms

P 98 ms

PR 142 ms

QRS 100 ms

QT 392 ms

QTC 392 ms

P (II) 0.08 mV

S (V1) -0.79 mV

R (V5) 1.36 mV

Sokol. 2.65 mV

5.70

UNCONFIRMED REPORT

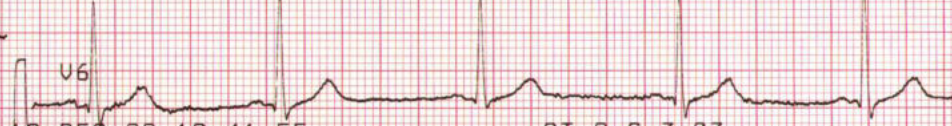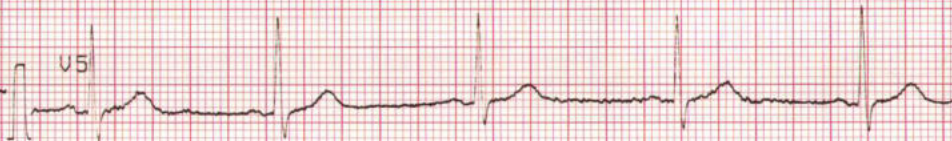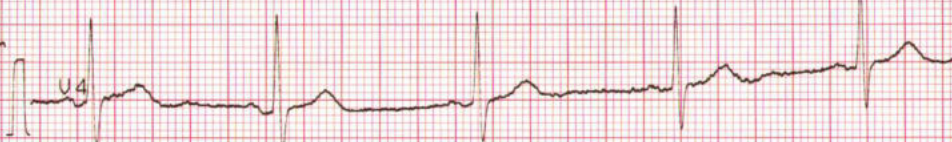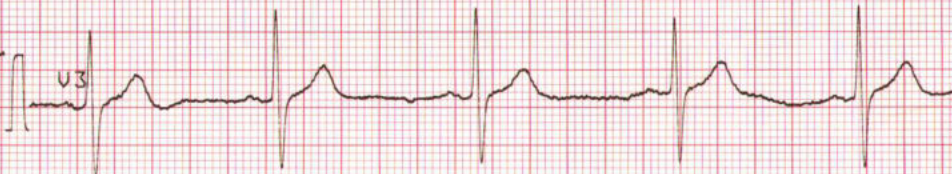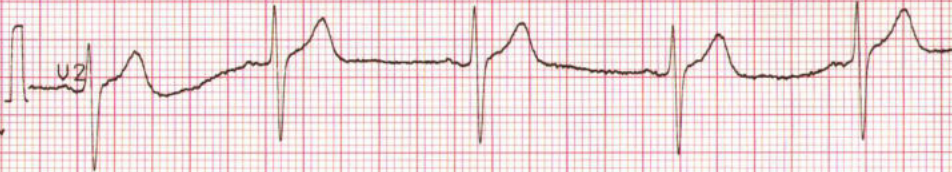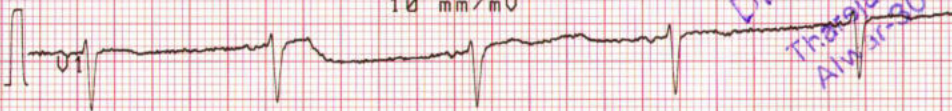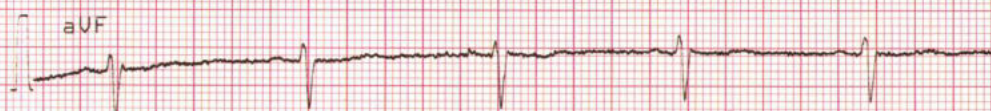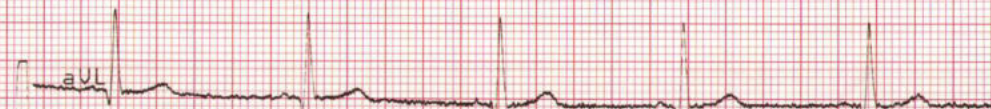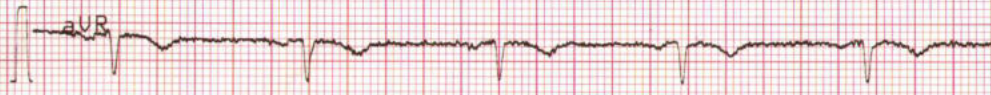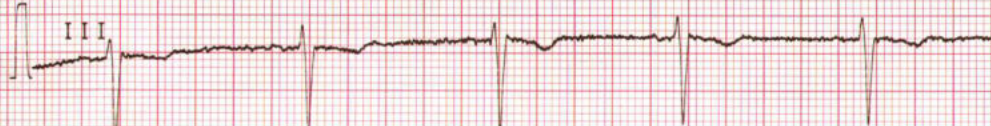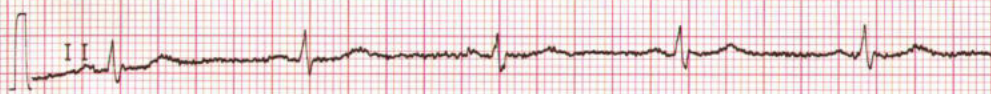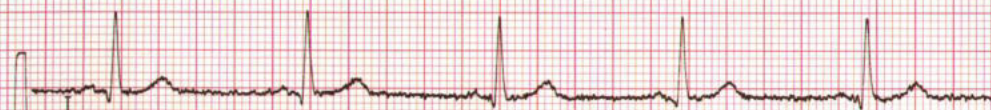Age: 56 Yr M / F

..... cm / kg

..... 10/12/22 mmHg

10 mm/mV

10 mm/mV



Handwritten signature

Dr. M. N. THAREJA
Thareja Nursing Home
Alwar-301001 (Raj)

25 mm/s

0.05-35 Hz F50

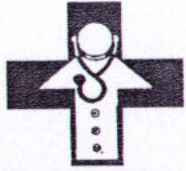Sa 10-DEC-22 10:41:55

AT-2 C 3.03

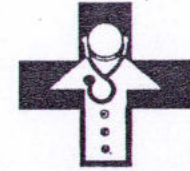SCHILLER

Part No.2.157017M CE 0123

S.BA



THAREJA CLINIC



1, Ram Kuteer Company Bagh Road, ALWAR (Raj.) ☎ 2700184, 2331842 (H)

POLY CLINIC EQUIPPED WITH COMPUTERISED AUTOANALYSER, CBC
SONOGRAPHY, X-RAY, OPG, COMPUTERISED ECG, EEG &
DIAGNOSTIC LABORATORY, COMPUTERISED LUNG FUNCTION TEST

DEADDICATION CENTRE

Dr. M.N. Thareja

M.B.B.S., F.C.G.P.

F.R.S.T.M. & H (London)

- ❖ Vice Chairperson of Sex Education & Parenthood International.
- ❖ Vice President of National Sexology Society of India
- ❖ Member of American Association of Sex Educator USA
- ❖ Executive Member of Indian Andro-Pause Society
- ❖ Life Member of Association for Prevention & Control of Rabies in India (APCRI)
- ❖ Life Member of Indian Red Cross Society
- ❖ Life Member of IMA College of General Practitioners
- ❖ Post Graduate Certificate Course of HIV/AIDS & STD Management Counsellor.
- ❖ Post Graduate Certificate Course Environmental & Occupational Health.

ELECTROCARDIOGRAM

Patient Name Dev Karam meena

Date 10-12-22 Age 56 Sex m

Referred by Dr. M N Thareja



GUPTA ENT AND HEART CENTRE

Dayanand Marg, Nangli Circle, Alwar (Raj.) Ph. 0144-3591336 | M. 7378184427

Echocardiography Report

Name	: Mr. Dev Karan Meena	Refd by: Dr. M. N. Thareja
Age / Sex	: 56yrs./male	Date : 10 December 2022

Clinical Diagnosis : For Cardiac Evaluation

2D Echocardiography Findings

Mitral Valve	:	Normal
Aortic Valve	:	Thickened
Tricuspid Valve	:	Normal
Pulmonary Valve	:	Normal
Left Atrium	:	3.8cm: Normal
Left Ventricle	:	Mild concentric LVH with normal LV systolic function. No RWMA

LVIDd	5.3cm.	IVSd	1.1cm.	EF	60%	Visual
LVIDs	3.2cm.	PWd	1.1cm.	EF	%	F.S.

Right Atrium	:	Normal
Right Ventricle	:	Normal
Aorta	:	2.7cm: Normal
Pulmonary Artery	:	Normal
Pulmonary Veins	:	Normal
Superior Venacava	:	Normal
Inferior Venacava	:	Normal
Pericardium	:	Normal
Intracardiac Masses	:	No Intracardiac masses seen
IAS/IVS	:	Intact

Doppler Findings:

Valve	Peak Velocity (cm/s)	Peak Gradient (mmHg)	Mean Gradient (mmHg)	Regurgitation Grade	others/comments
Mitral Valve	E-/A-58/75			No MR	
Aortic Valve	89				
Tricuspid Valve				No TR, No PAH.	
Pulmonary Valve	66				

Diagnosis : Transthoracic echo done in supine position at resting heart rate of 60bpm, shows
Mild concentric LVH with normal LV systolic function.
LVEF~60% (Visual).
No RWMA.
Other cardiac chambers are normal in Size.
No MR, No TR, No PAH.
Grade I diastolic dysfunction.
No pericardial effusion /Vegetation /Clot Intracardiac masses seen.
Normal left sided arch of aorta, No Coarctation.

Dr. Prachi Gupta
MBBS, PGDCG
Dr. PRACHI GUPTA
(Non-invasive cardiologist)
Gupta ENT and Heart Centre
Nangli Circle, Alwar

Please correlate clinically

This report is not valid for medico legal purpose.



MEHAR'S

SAHARA DIAGNOSTICS

Reg. No. NHM/434

Dr. R.D. Arora

M.D., D.M.R.E (Radio-dagnosis)

University Topper

R.M.C. Reg. No. 28052 & 009456

Mob.: 9829136035

The Healing Ashram, 12 Kailash Colony, Bhagat Singh Circle, Alwar

10 DEC 2022

NAME : DEVKARAN

Clinician: Dr M N THAREJA

FOR : ABDOMEN

c/o pain abdomen [indication/ reason for scan]

Patient information -Technically poor quality scans because of obesity and thick abd wall +hypersthenia

On real time B-mode sonography

Liver is enlarged in size and echo pattern enhanced, no SOL is seen. Hepatic and portal veins are normal. CBD is normal in caliber, no obstruction is seen.

Pancreas is normal in size and echopattern, no SOL is seen.

Spleen is normal in size and echopattern, no SOL is seen.

Kidneys, bilaterally are normal in size and shape, no calculus or dilated calyces are seen.

Right Iliac region appendix could not be traced at present

No evidence of ascites, free Pleural effusion or lymphadenopathy is seen.

Urinary Bladder is normal in size, wall is normal in thickness, no calculus or growth is seen.

Prostate normal

IMPRESSION:

SMALL umbilical hernia

Fatty liver gr 1

Further evaluation is suggested.

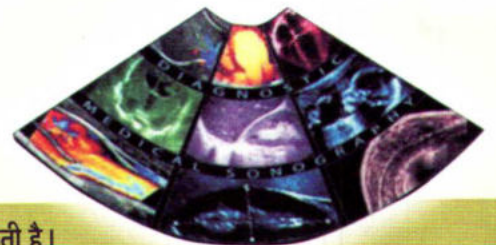Patient information -Kindly note no luminal pathology can be detected in non distended urinary tract .

Dr Ram das arora

Dr Ram das arora

Ultrasound scan is an investigation and therefore has technical limitations as well as inaccuracies inherent in the laboratory and statistical analysis of biological process. It should always be viewed in this perspective. Further this is a routine general scan grossly containing information sought by ref consultant and report generated thus, is for his perusal only. Considering pace of advances in the field of sonography, more specified information can also be obtained by prior intimation.

- Consultant of Radiology works
- Working hours 10 a.m. to 4 p.m. On Call Basis



“ भ्रूण लिंग परीक्षण करवाना जघन्य अपराध है तथा इसकी शिकायत 104 टोल फ्री सेवा पर की जा सकती है।

“ • “बेटी बचाओं - बेटी पढ़ाओं”

RIGHT

DEV KARAN MEENA 56 Y BY DR M.N. THAREJA 34216.5 M CHEST, PA 12/10/2022
THAREJA NURSING HOME. COMPANY BAGH ROAD, ALWAR