

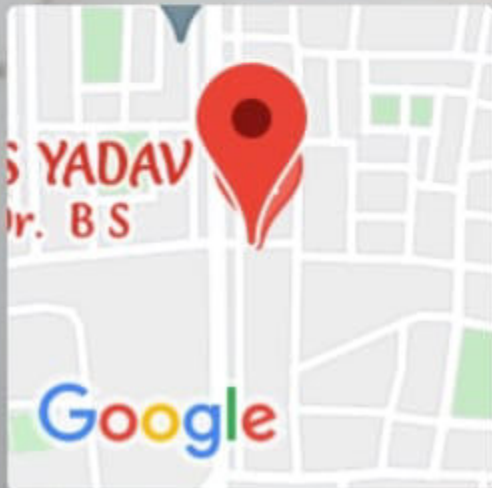

Diwaka Diagnostic Centre

पेथोलोजी | टी.एँम.टी. | .सी.जी. | एको कार्डियो ग्राफी | सोनोग्राफी



GPS Map Camera



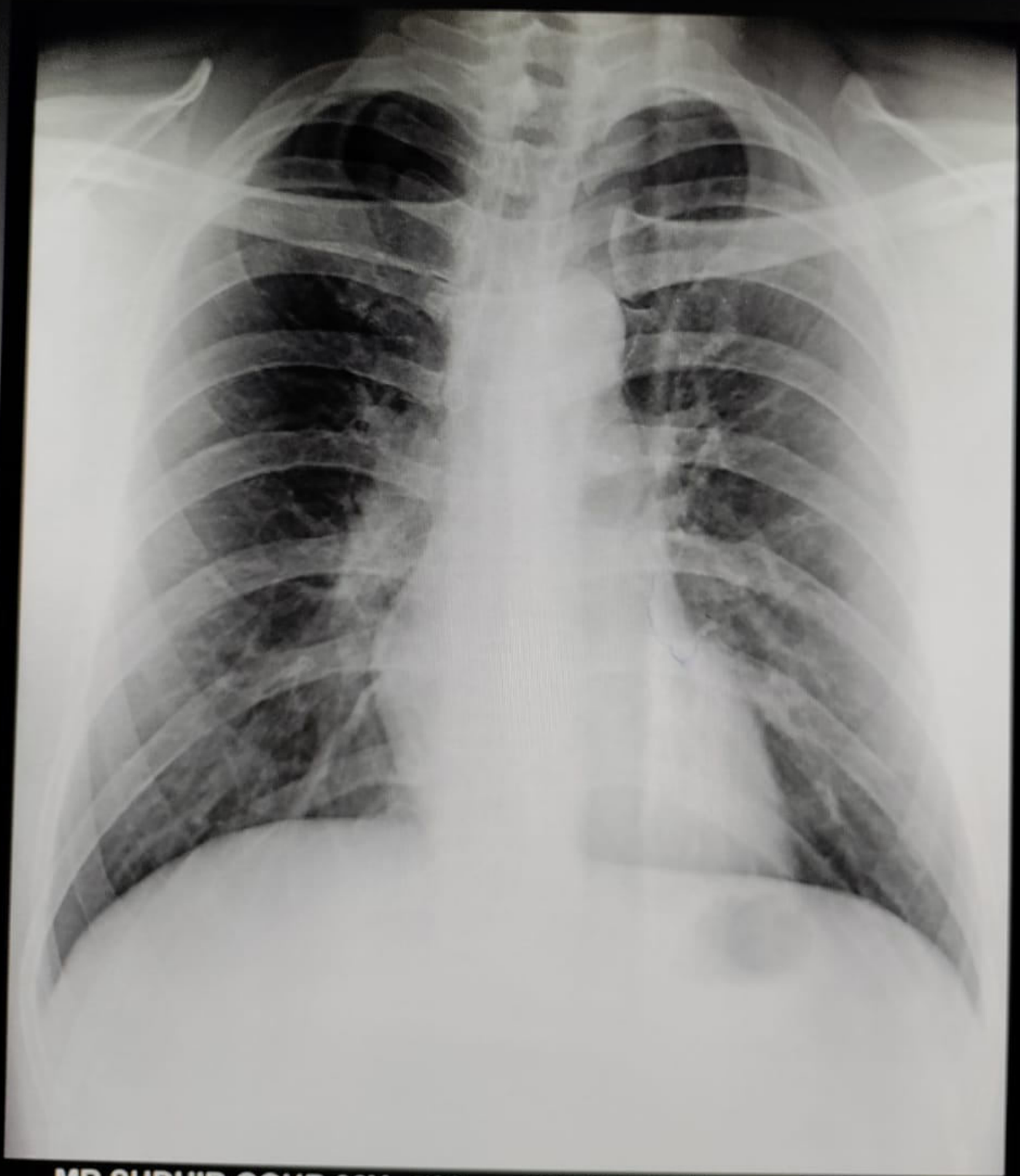Bhopal, Madhya Pradesh, India

636, Champion School Rd, E-7, Arera Colony, Bhopal, Madhya Pradesh 462016, India

Lat 23.205933°

Long 77.431584°

18/11/21 10:11 AM



MR SUDHIR GOUR 32Y 780 CHEST,FRN P->A 18-Nov-21
DIWAKAR DIAGNOSTIC CENTRE , ARERA COLONY ,BHOPAL

Shot on OnePlus

By 🤖

डिवाकर डायग्नोस्टिक सेंटर



E-7/636, पंजाब नेशनल बैंक के पास, मंग रोड, अरसा कॉलोनी भापाल (म.प्र.)
फोन: 0755-2465288, 0755-3520545 मो: 9826340190

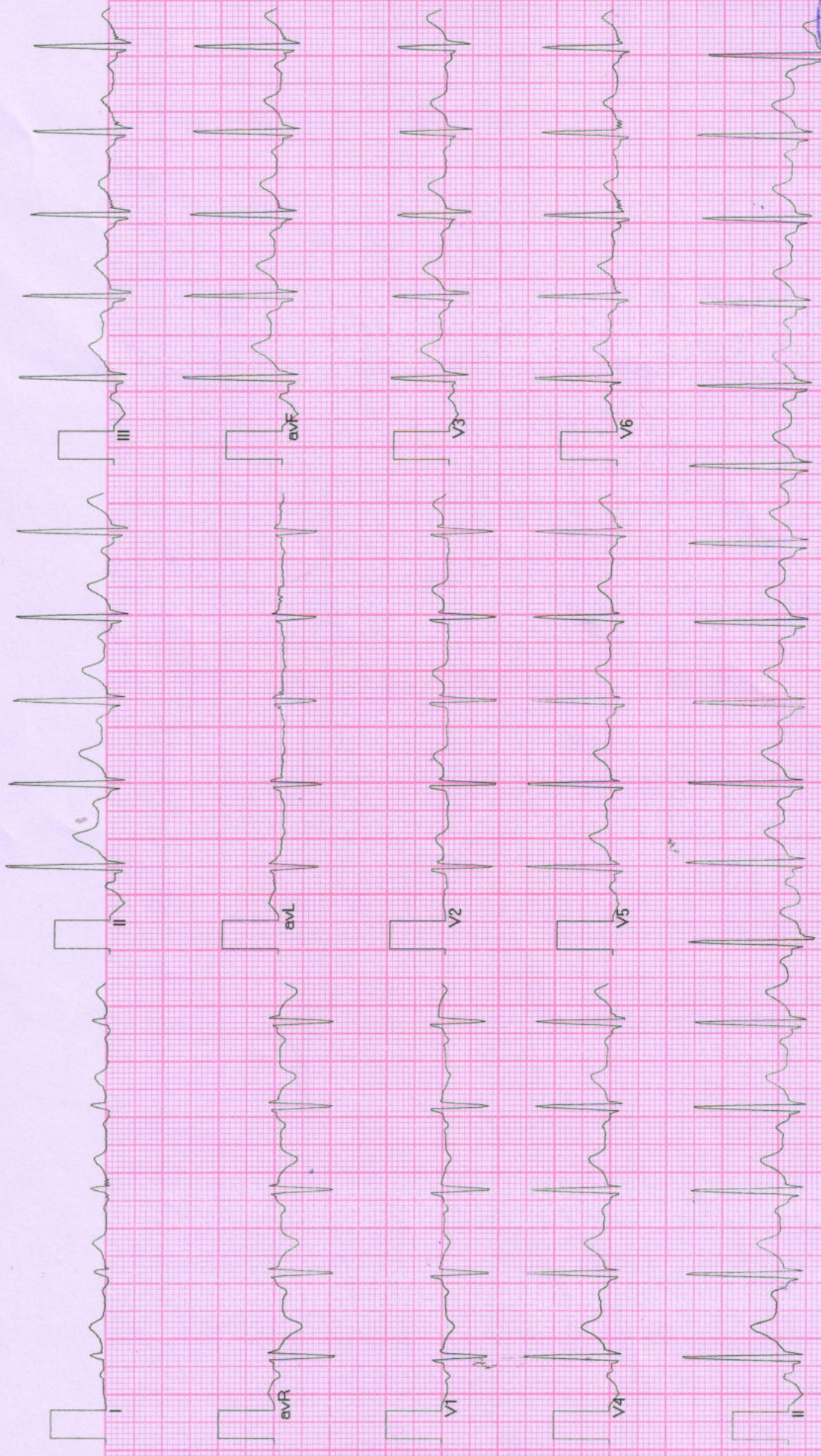


Dr. B. M. Agarwal
MBBS, DCP
Consultant Pathologist



Allengers Global Healthcare Pvt Ltd.,
111 / MR. SUDHIR GOUR / 32 Yrs / F / 76Cms. / 176Kgs.
Heart Rate : 103 bpm / Tested On : 18-Nov-21 09:47:58 / HF 0.05 Hz - LF 100 Hz / Notch 50 Hz / Sn 1.00 Cm/mV / Sw 25 mm/s
/ Refd By.: BOB

ECG



BPL-DYNATRAC

Allengers ECG (Piscos)(PI/S213180317)



दिवाकर डायग्नोस्टिक सेंटर

E-7/636, पंजाब नेशनल बैंक के पास, मैन रोड, अरेरा कॉलोनी भोपाल (म.प्र.)

फोन: 0755-2465288, 0755-3520545 मो: 9826340190


Pt.Name :-	Mr. Sudhir Gour
Age :-	32y/M
Refd. By :-	BOB
Lab.pNo.:-	99
Date :-	18/11/2021

EXAMINATION OF BLOOD

TEST	RESULT	NORMAL VALUE
Haemoglobin	14.6mgs%	Female 12-16gms%, Male 14-18gms%
Red Cell count	5.0	4.5-5.6 million /cumm
Platelite Count	2.58	1.5-5.6 Lac/cumm
Leucocytes per.cu.mm	7900/cumm	5000-11000/cumm
Neutrophils	60%	50-70%
Lymphocytes	30%	20-40%
Eosinophils	06%	0-7%
Monocytes	04%	2-8%
PCV	41.2	37-47
MCV	81.6	76-96
MCH	31.5	27-32
MCHC	33.0	31-35
ESR	06	Male 0-9, Female 0-20mm/FHR
Blood Group	O Positive	By Slide Method
S.Bilirubin(Total)	0.78	0.2-1.0mg/dl
Direct	0.30	0.0-0.25mg/dl
Indirect	0.48	
SGOT	31.8	5-35U/L
SGPT	34.0	8-40U/L
Alk Phosphatase	10.6	3-13 KA units
S. Protein(Total)	7.0	6.0-8.0mg%
Albumin	4.0	3.7-5.3mg%
Globulin	3.0	1.5 to 3.5 mg%
AG Ratio	1.23	1.-2.0
Blood Urea Nitrogen (BUN)	16.2	7-20 mg/dl
S.Creatine	0.91	0.5-1.4mg/dl
S. Uric Acid	5.2	3.5-7.5mg%
Calcium	9.1	8.5-10.5 gm/dl
GGTP	33.8	5-35 UL/dl
HbsAg	Negative	By card method
HIV I&II	Negative	By elisa method
Fasting Blood Sugar	82.8	70 to 110mg/dl
Post Prandial Blood Surar	128.5	Up to 150mg/dl
Total Serum Cholesterol	171.6	100-250 mg%
Serum Triglyceride	135.6	Up to 160 mg%
Serum Cholesterol HDL	49.5	Up to 65 mg%
Serum Cholesterol LDL	94.9	Up to 125 mg%
VLDL	27.1	Up to 30 mg%
Glycosylated Hemoglobin HBA1c	5.5	Below - 6.0 % -Non Diabetic control 6-7 % -Excellent control Above- 8 % -Poor control

S. M. Agarwal
Pathologist
MBBS, DCP
Sant Pathologist

All test have technical limitation. Collaborative clinic pathological interpretation is mandatory. In case of disparity test may be repeated immediately. Typographical mistakes should be get correct instantly. This report is not valid for medico legal purpose





द्विवाकर डायग्नोस्टिक सेंटर

E-7/636, पंजाब नेशनल बैंक के पास, मैन रोड, अरेरा कॉलोनी भोपाल (म.प्र.)


फोन: 0755-2465288, 0755-3520545 मो: 9826340190

Pt.Name :-	Mr. Sudhir Gour
Age :-	32y/M
Refd. By :-	BOB
Lab.pNo.:-	99
Date :-	18/11/2021

URINE ANALYSIS

<u>A. PHYSICALEXAMINATION</u>		<u>C. MICROSCOPIEXAMINATION</u>	
1. Colour	Yellow	Pus Cells	2-3/HPF
2. Appearance	Clear	R.B.C.	Nil
3. Specific Gravity	Q.N.S.	Epithelial Cell	occ/HPF
<u>B. CHEMICAL EXAMINATION</u>		Cast	Nil
1.Reaction	Acidic	Crystals(Cal.Oxa)	Nil
2.Albumin	Absent	Bacteria	Nil
3.Sugar	Nil	Amorphous	Nil
4.Bile Salts	Absent	T. Vaginitis	Nil

URINE COTININE	Negative	By Card method
----------------	----------	----------------



Dr. B. M. Agarwal
MBBS, DCP
Consultant Pathologist

All test have technical limitation. Collaborative clinic pathological interpretation is mandatory. In case of disparity test may be repeated immediately. Typographic mistakes should be get correct instantly. This report is not valid for medico legal purpose.



दिवकर डायग्नोस्टिक सेंटर

E-7/636, पंजाब नेशनल बैंक के पास, मैन रोड, अरेरा कॉलोनी भोपाल (म.प्र.)

फोन: 0755-2465288, 0755-3520545 मो: 9826340190

Pt.Name :-	Mr. Sudhir Gour
Age :-	32y/M
Refd. By :-	BOB
Lab.pNo.:-	99
Date :-	18/11/2021
Skigram	X Ray Chest PA View
Radiologist	Dr. B.M.Agarwal MD (Radiology)

REPORT

Tricia Central

Thoracic cage normal

Both Lungs Field Clear.

Both hilers normal

Cardiac border normal

Both cp angles clear

Both domes and diaphragm normal

IMPRESSION

-NO CARDIO PULMONARY PATHOLOGY
-COORELATE WITH CLINICAL FINDINGS.



Dr. B. M. Agarwal
MD, Radiology
Consultant Radiologist
Radiologist



दिवकर डायग्नोस्टिक सेंटर

E-7/636, पंजाब नेशनल बैंक के पास, मैन रोड, अरेरा कॉलोनी भोपाल (म.प्र.)

फोन: 0755-2465288, 0755-3520545 मो: 9826340190

Pt Name :	Mr. Sudhir Gour
Age :	32/M
Ref.By :	BOB
Lab. No. :	99
Date :	18/11/2021

EXAMINATION OF BLOOD

Thyroid profile

TEST	RESULT	NORMAL VALUE
T3 - TOTAL	96.5	82-213 ng/dL
T4 - TOTAL	6.89	6.09-12.23 ug/dL
THYROID STIMULATING HORMONE (TSH)	1.35	0.45-4.25 ul/mL

Interpretation:

TSH Levels will be elevated in primary hypothyroidism, TSH levels will be low in Hyperthyroidism there is decreased production of thyroid hormones by the thyroid hence the person may experience symptoms such as weight gain, constipation, cold intolerance and fatigue. Iodine deficiency and Hashimoto thyroiditis is the most common cause of hypothyroidism It makes Thyroid stimulating hormone. If TSH levels are abnormally high it could mean you have an underactive thyroid or hypothyroidism.



Dr. B. M. Agarwal
MBBS, DCP
Consultant Pathologist



द्विवाकर डायग्नोस्टिक सेंटर

E-7/636, पंजाब नेशनल बैंक के पास, मैन रोड, अरेरा कॉलोनी भोपाल (म.प्र.)

फोन: 0755-2465288, 0755-3520545 मो: 9826340190

Pt Name :	Mr. Sudhir Gour
Age :	32y/M
Ref.By :	BOB
Lab. No. :	99
Date :	18/11/2021

EXAMINATION OF BLOOD

<u>TEST</u>	<u>RESULT</u>	<u>NORMAL VALUE</u>
PSA	4.10 ng/ml.	0.21-6.77 ng/ml.



Dr. B. M. Agarwal
MBBS, DCP
Consultant Pathologist

All test have technical limitation. Collaborative clinic pathological interpretation is mandatory. In case of disparity test may be repeated immediately. Typographic mistakes should be get correct instantly. This report is not valid for medico legal purpose

PTO

Right kidney is normal in size, shape and position. Corticomedullary differentiation (CMD) is well maintained. Normal cortical thickness is noted. No E/O hydronephrosis or calculus is noted.

No evidence of free fluid is noted.

No evidence of lymphadenopathy is noted.

IVC and aorta appear to be normal.

Spleen is normal in size and echo texture.

contour. No peripancreatic pathology seen. (Not seen due to gases)

Pancreas appear normal in size, shape and echo texture with smooth

Common duct reveals normal course and caliber.

lumen. GB wall is normal / thickened. No E/O pericholecystic collection.

Gall Bladder is physiologically well distended. No. E/O echogenic foci in GB

No E/O subdiaphragmatic Collection.

dilatation is seen. Hepatic veins and portal veins appear normal.

increased parenchymal echogenicity is noted. No E/O focal lesion/ IHR

Liver appears normal in size and shape with normal outline. Normal/

WHOLE ABDOMEN ULTRASOUND REPORT

Indication: Health check-up.

R/B No. Date

Name : Mrs. Sudhir Gour 33/male. Age. YRS./F

श्री. साविता क्लिनिक
34, भूतल, मोहिनी अटलि आर्कड, शाहपुरा मस्जिद के पास
भरत नगर रोड, ई-7/194, अररा कॉलोनी, भोपाल - 462038
Mob. : 8989649694, 9516333619
Clinic Registration : CL/5392/Jun/2017
PNDT Registration : MPFCPNDT/BPL/2017/206



Left Kidney is normal in size, shape and position. CMD is well maintained. Normal cortical thickness is noted. No E/O hydronephrosis or calculus is noted.

Urinary Bladder is well distended (physiological). its contents are echo free. No E/O bladder wall thickening is noted. Post-void residue is insignificant.

Prostate is normal in size. Shape and echo texture with smooth outline. No E/O focal lesion is noted.

Uterus is ante/retroverted and normal in size, shape and echotexture with smooth outline. No E/O focal lesion is noted. Endometrial echo appears normal. Cervical and vaginal shadows appear normal.

Right Ovary appears enlarged / Normal in size, shape and echo texture.

Left Ovary appears enlarged / Normal in size, shape and echo texture.

Impression : Normal study.

Advised clinical Correlation.

Dr. P. Savita, MD
MBBS, MD (O&G) Reg. No. 9971

स्त्री रोग विशेषज्ञ

Dr. Jayant Yadav, MD
MBBS, MD (Radiologist) Reg. No. 4166

रेडियोलॉजिस्ट

