

ID: 416

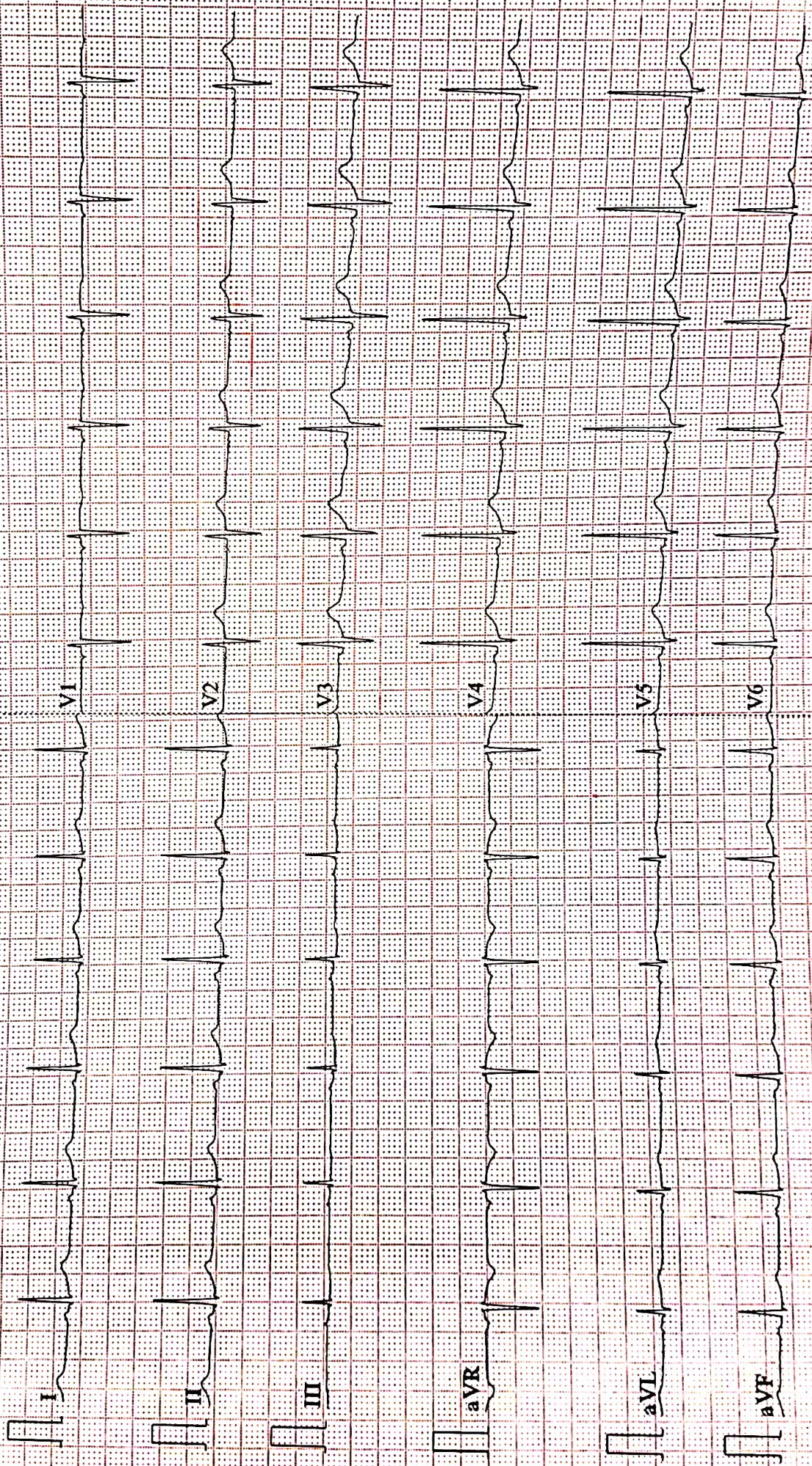
RAVI RANJAN KR.
Male
Years

29-07-2021 09:40:17 AM

HR	75	bpm
P	79	ms
PR	121	ms
QRS	76	ms
QT/QTc	365/408	ms
P/QRS/T	57/51/20	°
RV5/SV1	1.582/0.899	mV

Diagnosis-Information:
Sinus Rhythm
Normal ECG

Report Confirmed by:





SUBHAM IMAGING & A.L.C. DIAGNOSTICS CENTRE

H.O. : Ajay Market, Dena Bank Building, East Ashok Nagar, Kankarbagh, Patna - 20

B.O. : Khanpura Road (Below Gyan Sharowar School), Paliganj, Patna.

e-mail : shubham.pat.usg@gmail.com # website : www.alchealthcheckup.in

OPINION MUST BE CORRELATES WITH CLINICAL & OTHER INVESTIGATION FOR DIAGNOSIS NOT FOR MEDICO LEGAL PURPOSE

Pt. Name :- **RAVI RANJAN**

Date:- 29-Jul-21

Ref. By :- **DR. / B O B**

Age / Sex - 33 Yrs. M.

REAL TIME U.S.G. OF WHOLE ABDOMEN

Thanks for your kind referral

(Report.)

- LIVER** :- Measures 14.72 cm. Mild Enlarged in shape, size and echo texture. I.H.B.R. are not dilated. Hepatic veins are normal. No SOL seen.
- G.BL.** :- Lumen is echo free. Wall thickness appears normal.
- C.B.D.** :- Measures 3.3 mm in diameter with echo free lumen. No calculi or mass seen.
- P.V.** :- Measures 7.2 mm in diameter. Appears normal. No thrombus seen.
- PANCREAS** :- Normal in shape, size and echo texture. No calcification mass seen.
- SPLEEN** :- Measures 10.25 cm. Normal in shape, size and echo texture. No SOL seen.
- KIDNEY** :- Both kidney shows normal shape, size & echotexture. C.M.D.intact. P.C.S.is not dilated. No calculi, cyst or hydronephrosis seen on either side.
- Right Kidney** :- Measures 10.0 X 4.4 cm.
- Left Kidney** :- Measures 10.80 X 4.5 cm.
- URETER** :- Not dilated. No apparent calculi seen.
- U.BLADDER** :- Shows normal in outline with echo free lumen. No calculi or mass seen.
- Pre void** - 310 ml. **Post void** - is in significant
- PROSTATE** :- Normal in Size Shape Capsule is intact
- R.I.F.** :- Son graphically no appendicular mass or collection seen.
- OTHERS** :- Distended Bowel Loops seen in abdominal cavity with Excess bowel Gasses No Ascites no Lymph Adenopathy No pleural effusion seen on either side.

IMPRESSION

- Mild Hepatomegaly
- Adv :- Further Work Up LFT / Other Investigation
Otherwise son graphically normal scan. of rest organs

↓
29/7/21

Consultant Radiologist

ESTB BY:-

Dr. P. K. Tiwari

MD, BRIT (Radio Imaging)

Consultant Imaginationologist & Sonologist

A.L.C. Diagnostics & Research Centre, Patna

Dr. S. Kumar

MD. (Pat)

Consultant Pathologist

Dr. A. K. Singh

MBBS, PGDMCH

Consultant Radiologist & Sonologist



रवि रंजन कुमार
GOVERNMENT OF INDIA



रवि रंजन कुमार
Ravi Ranjan Kumar
जन्म वर्ष / Year of Birth : 1989
पुरुष / Male

5900 4516 6393

आधार - आम आदमी का अधिकार