

भारत सरकार
Government of India

आधार

देव नंदन शाह
Dev Nandan Shah
जन्म तिथि/DOB: 01/12/1963
पुरुष/ MALE

Download Date: 12/07/2021

Issue Date: 09/07/2021

6783 5152 2916
VID : 9106 5385 1397 9694

मेरा आधार, मेरी पहचान

१५७७७

Dr. NITIN AGARWAL
MBBS, MD
Regn. No. DMC-R-1436

1947

help@uidai.gov.in | www.uidai.gov.in

6783 5152 2916
VID : 9106 5385 1397 9694


Address:
S/O Anand Shah, house no 1202, gall no 26
A, sawantar nagar, narala, Narala, North
West Delhi,
Delhi - 110040

पता:
S/O अनांदी शाह, हाउस नं 26 ए,
सॉवन्तार नगर, नराला, नराला, उत्तर पश्चिम,
दिल्ली - 110040

भारतीय पहचान प्राधिकरण
Unique Identification Authority of India

AAADHAR

ONEPLUS ULTRASOUND LAB
47, Harsh Vihar, Pitam Pura,
Delhi-110034
Ph. 011-42480101, 9599913051
E-mail: oneplusul@gmail.com



99777



Dr. NITIN AGARWAL
MBBS, MD
Regn. No. DMC-R-1436

ONEPLUS ULTRASOUND LAB
47, Harsh Vihar, Pitam Pura,
Delhi-110034
Ph. 011-42480101, 9599913051
E-mail: oneplusul@gmail.com

ONEPLUS ULTRASOUND LAB

47, HARSH VIHAR, PITAMPURA, DELHI- 110034

Mr. SHAH DEV NANDAN
 Age : 58M
 Ref. by : MEDIMHEEL
 Indication1 :
 Indication2 :
 Indication3 :
 COMMENTS :

ID : 2064
 HMM : 165/71
 Recorded : 7-1-2023 9:10
 Medication1 :
 Medication2 :
 Medication3 :

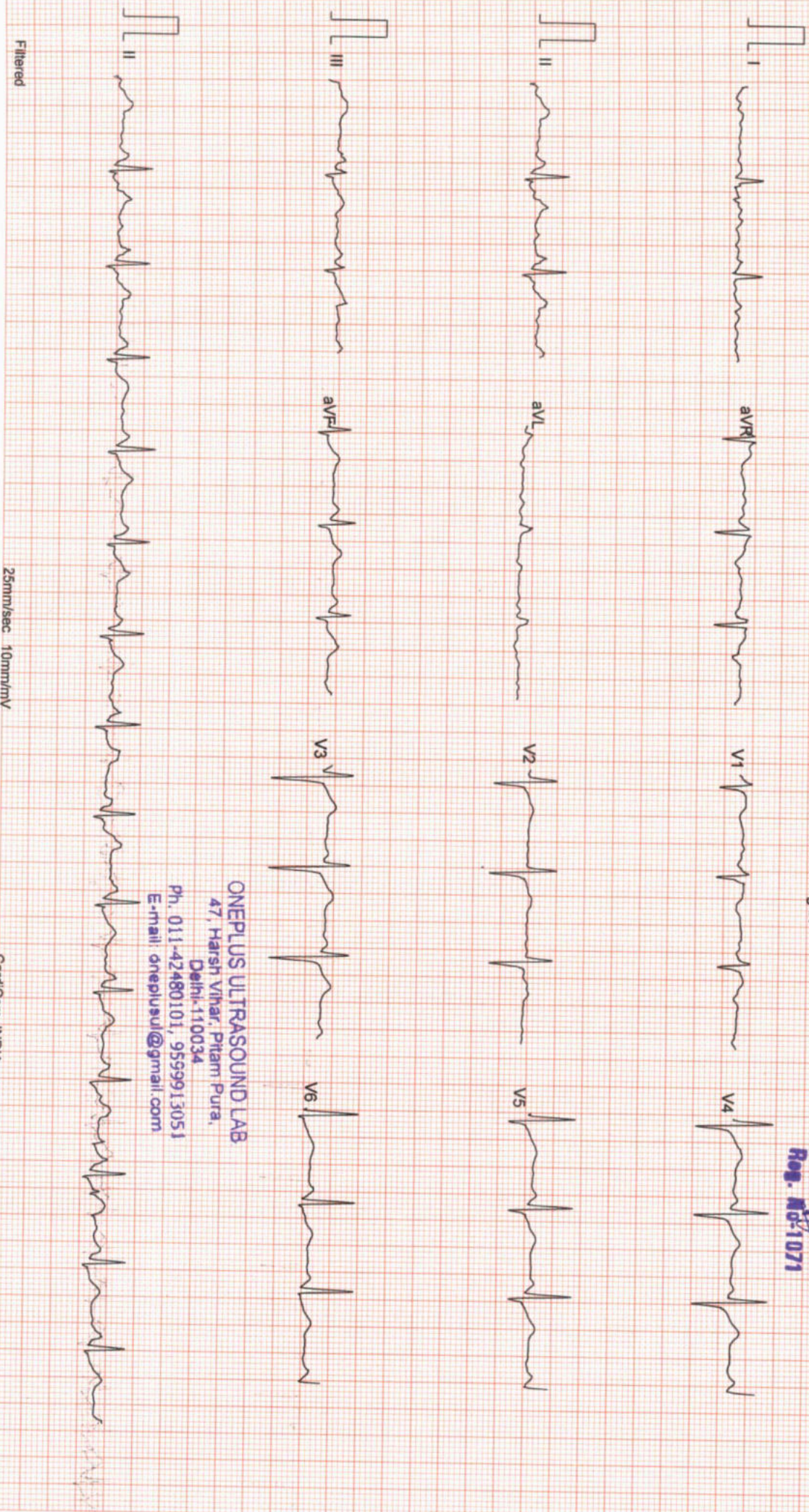
BPM : 94
 BP : 138/88
 P Axis : 63 deg
 QRS Axis : 29 deg
 T Axis : 76 deg

P duration : 96 msec
 PR duration : 100 msec
 QRS duration : 110 msec
 QT Interval : 323 msec
 QTc Interval : 382 msec

Handwritten signature

Unconfirmed Report Reviewed By:
 Cardiologist

Dr. P.K. RUPIA
 MBBS, MD
 Reg. No-1071



Filtered
 25mm/sec 10mm/mV

ONEPLUS ULTRASOUND LAB
 47, Harsh Vihar, Pitam Pura,
 Delhi-110034
 Ph. 011-42480101, 9599913051
 E-mail: oneplusul@gmail.com

ONEPLUS ULTRASOUND LAB

47, HARSH VIHAR PITAMPURA DELHI 110034

Mr. DEV NANDAN SHAH

Age/Sex : 59/M
Ref. by : MEDIWHEEL

Indication1 :
Indication2 :
Indication3 :

ID : 989
HWT : 165/71
Recorded : 7-1-2023 9:13

TREADMILL TEST SUMMARY REPORT
Protocol: BRUCE
History:
Medication1 :
Medication2 :
Medication3 :

PHASE	PHASE TIME	STAGE TIME	SPEED (Km./Hr.)	GRADE (%)	H.R. (BPM)	B.P. (mmHg)	RPP X100	II	ST LEVEL (mm) V2	V5	METS
STANDING SUPINE					91	138/88	125	1.0	0.6	0.5	
STAGE 1	2:59	2:59	2.70	10.00	91	138/88	125	1.0	0.6	0.5	
STAGE 2	5:59	2:59	4.00	12.00	117	138/88	161	-0.1	0.4	-0.2	4.80
STAGE 3	6:29	0:29	5.40	14.00	97	150/90	145	-0.5	0.5	-0.4	7.10
PEAK EXER	6:38	0:38			142	160/94	227	-0.9	0.2	-0.9	7.57
RECOVERY	2:59	2:59	0.00	0.00	145	160/94	232	-0.9	0.1	-1.1	
					112	138/88	154	0.1	0.1	-0.3	7.72

RESULTS

Exercise Duration : 6:38 Minutes
Max Heart Rate : 145 bpm
Max Blood Pressure : 160/94 mmHg
Max Work Load : 7.72 METS
Reason of Termination :

Negative for isch. chd

99777

Dr. P.A. GUPTA
Cardiologist
MBBS, MD

ONEPLUS ULTRASOUND LAB
47, Harsh Vihar, Pitam Pura
Delhi-110034
Ph. 011-42480101, 9599913051
E-mail: oneplusul@gmail.com

ONEPLUS ULTRASOUND LAB

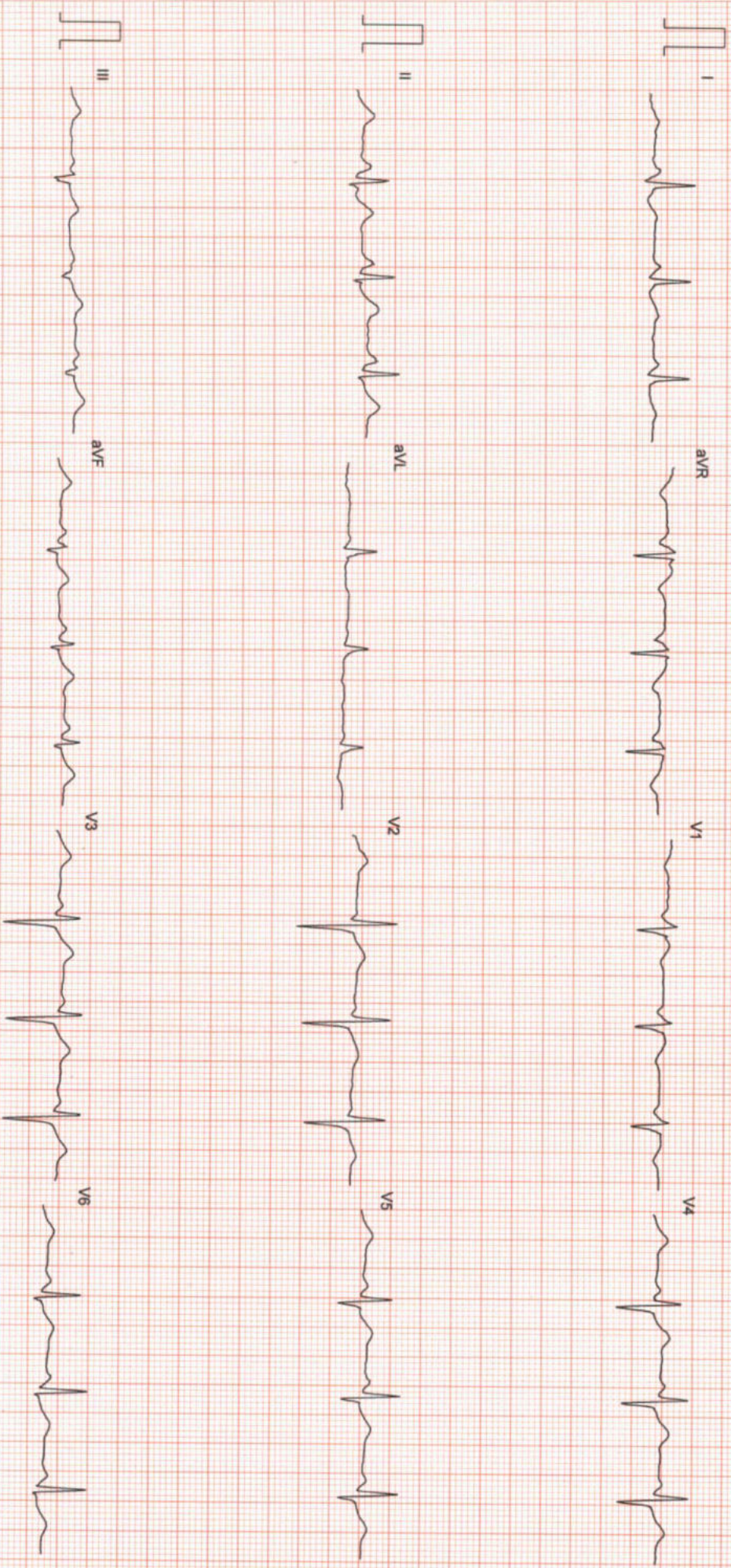
SUPINE
PRETEST

ST @ 10mm/mV
80ms PostJ

Mr. DEV NANDAN SHAH
I.D. : 989
AGE/SEX : 59/M

RATE : 91 BPM
B.P. : 138/88 mmHg

RAW E.C.G.



Filtered

25mm/sec 10mm/mV

CardiCom. INDIA Ph.:091-731-2620740, Telefax:091-731-2431214

ONEPLUS ULTRASOUND LAB
47, Haran Vihar, Pitam Pura,
Delhi-110034
Ph. 011-42480101, 9559913051
E-mail: onepiusul@gmail.com

M. DEV NANDAN SHAH

I.D. : 989

AGE/SEX : 59/M

RECORDED : 7-1-2023 9.13

RATE : 91 BPM

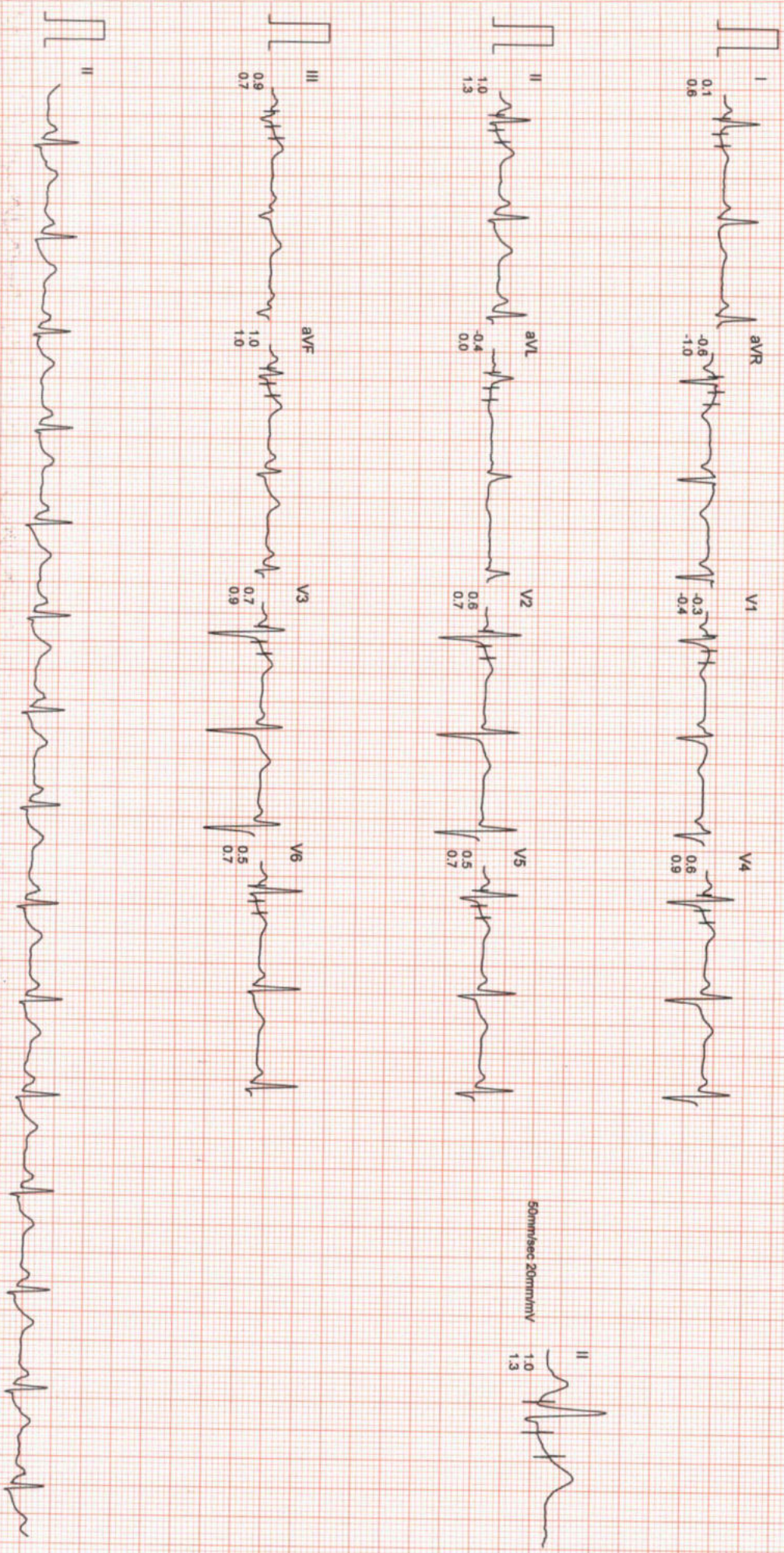
B.P. : 138/88 mmHg

ONEPLUS ULTRASOUND LAB

STANDING
PRETEST

ST @ 10mm/mV
80ms PostJ

LINKED MEDIAN



50mm/sec 20mm/mV
1.0 1.3

Filtered Computer Corrected Baseline 25mm/sec 10mm/mV

ONEPLUS ULTRASOUND LAB

47, Harsh Vihar, Pitam Pura,
Delhi-110034

Ph. 011-42480101, 9539913051
E-mail: oneplusul@gmail.com

CardiCom, INDIA Ph.:091-731-2620740, TeleFax:091-731-2431214

ONEPLUS ULTRASOUND LAB

Mr. DEV NANDAN SHAH

I.D. : 989

AGE/SEX : 59/M

RECORDED : 7-1-2023 9:13

RATE : 117 BPM
B.P. : 138/88 mmHg

BRUCE

EXERCISE 1

PHASE TIME : 2:59

STAGE TIME : 2:59

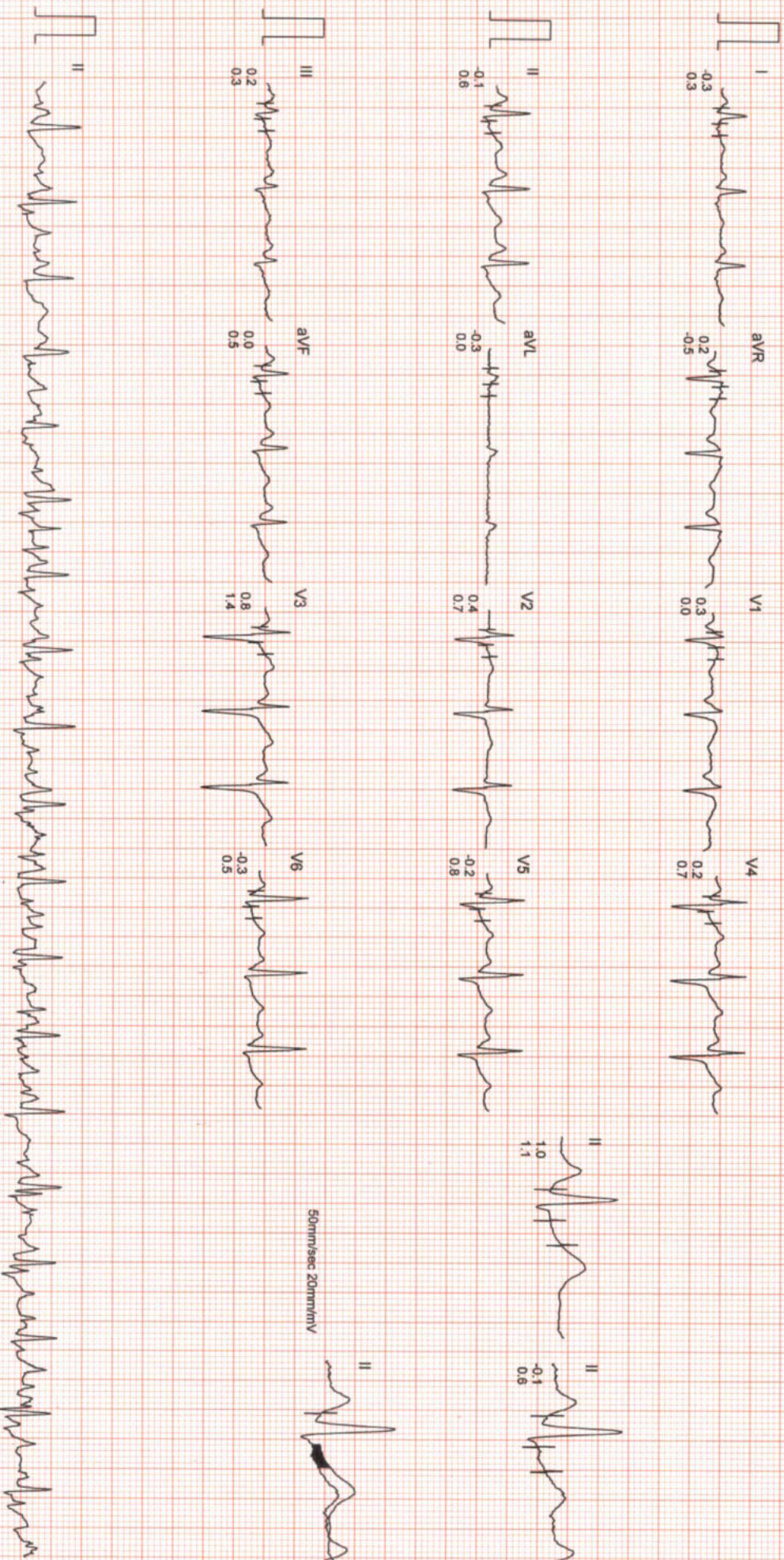
ST @ 10mm/mV

80ms PostJ

SPEED : 2.7 Km./Hr.

GRADE : 10.0 %

LINKED MEDIAN



Filtered

Computer Corrected Baseline

25mm/sec 10mm/mV

ONEPLUS ULTRASOUND LAB

47, Harsh Vihar, Pitam Pura,

Delhi-110034

Ph. 011-42480101, 9539913051

E-mail: onepplusul@gnmail.com

CardiCom, INDIA Ph.: 091-731-2620740, TeleFax: 091-731-2431214

ONEPLUS ULTRASOUND LAB

Mr. DEV NANDAN SHAH
I.D. : 989

AGE/SEX : 59/M

RECORDED : 7-1-2023 9:13

RATE : 97 BPM
B.P. : 150/90 mmHg

BRUCE

EXERCISE 2

PHASE TIME : 5:59

STAGE TIME : 2:59

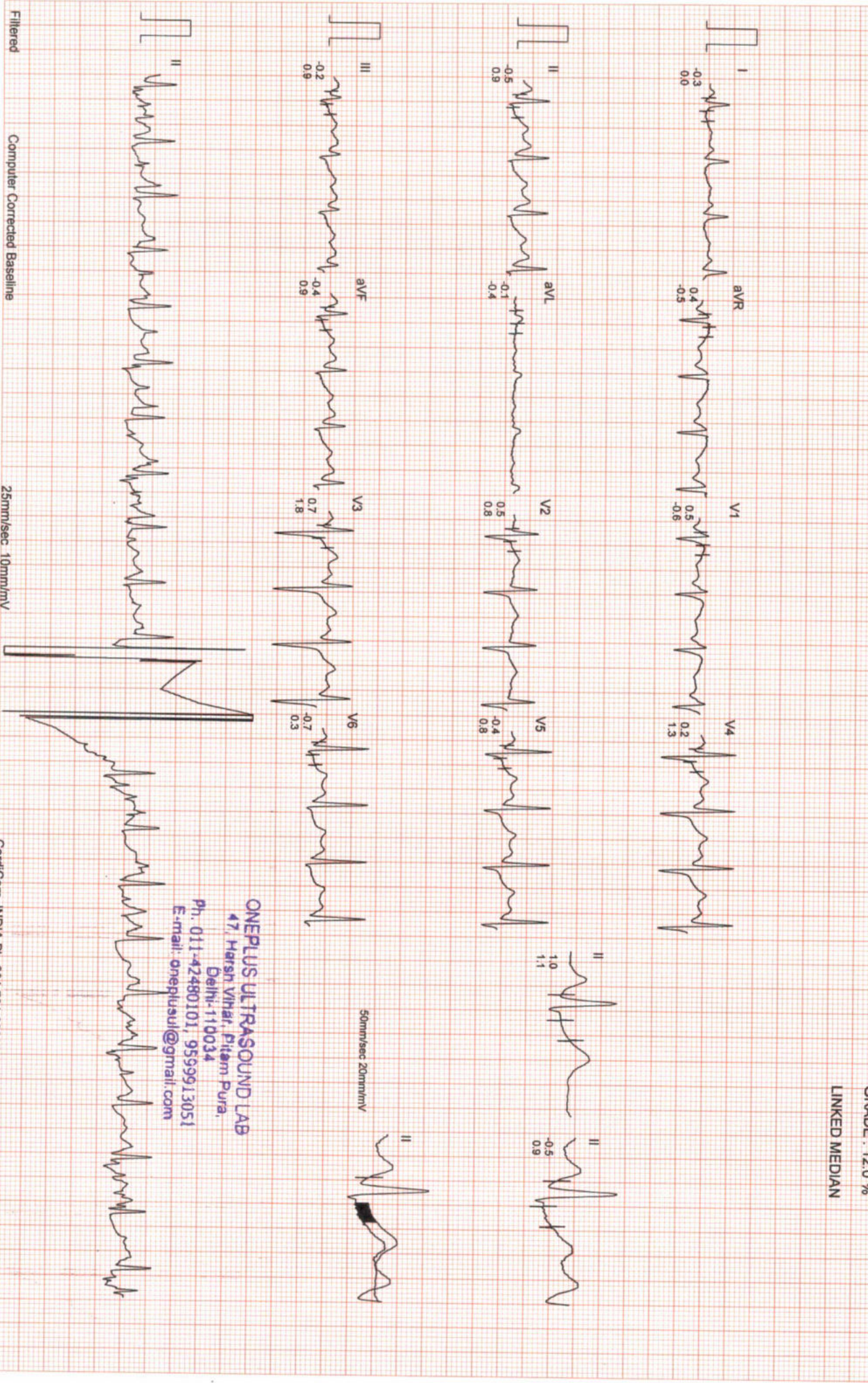
ST @ 10mm/mV

80ms PostJ

SPEED : 4.0 Km./Hr.

GRADE : 12.0 %

LINKED MEDIAN



ONEPLUS ULTRASOUND LAB
47, Harsh Vihar, Pitam Pura,
Delhi-110034

Ph. 011-42480101, 9599913051

E-mail: oneplusul@gmail.com

ONEPLUS ULTRASOUND LAB

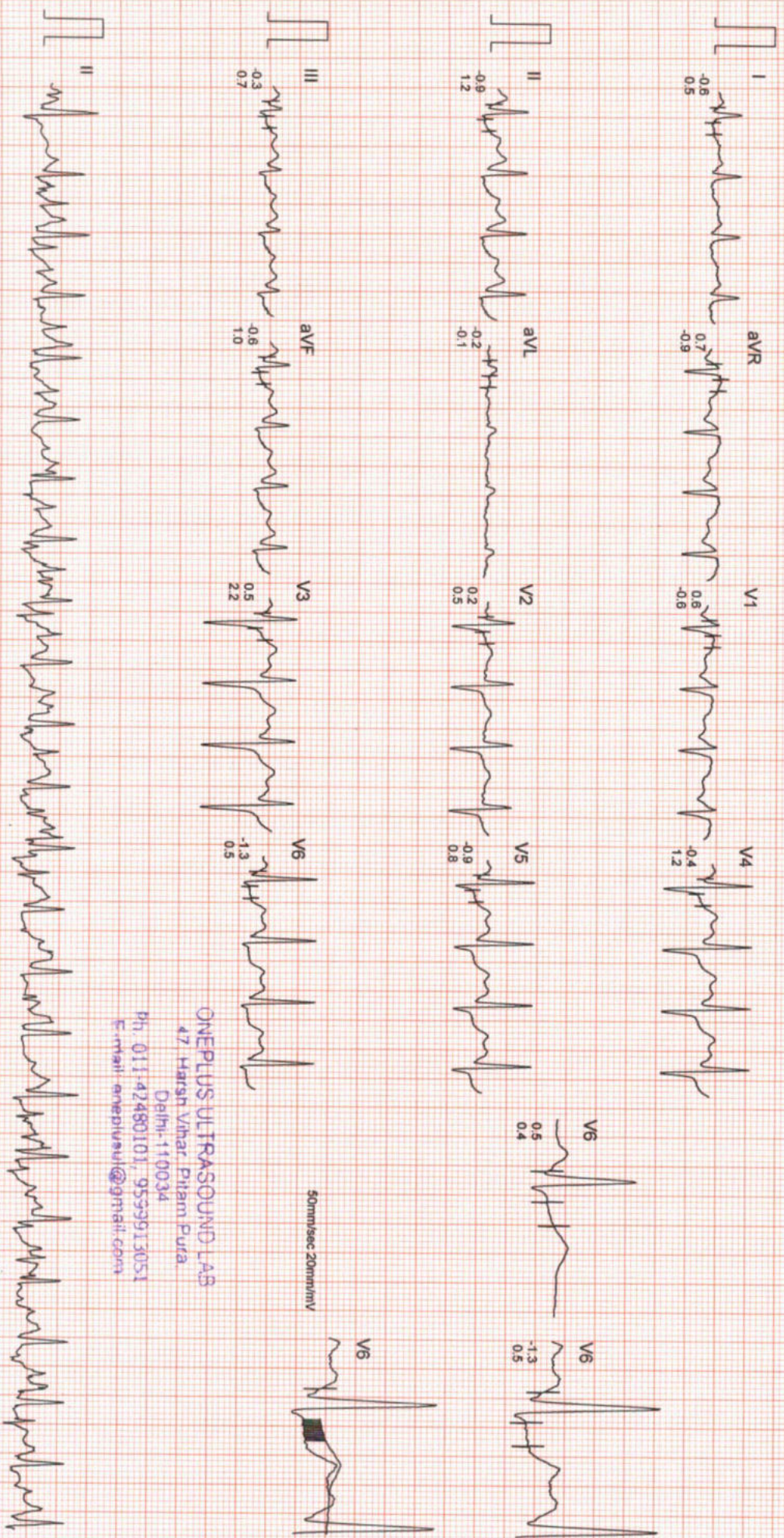
Mr. DEV NANDAN SHAH
I.D. : 989
AGE/SEX : 59/M
RECORDED : 7-1-2023 9:13

RATE : 142 BPM
B.P. : 160/94 mmHg

BRUCE
EXERCISE 3
PHASE TIME : 6:29
STAGE TIME : 0:29

ST @ 10mm/mV
80ms PostJ
SPEED : 5.4 Km/Hr.
GRADE : 14.0 %

LINKED MEDIAN



ONEPLUS ULTRASOUND LAB
47 Harsh Vihar, Pitam Pura
Delhi-110034
Ph: 011-42480101, 9539913051
E-mail: oneplusul@gniff.com

Filtered Computer Corrected Baseline

25mm/sec 10mm/mV

CardiCom, INDIA Ph: 091-731-2620740, TeleFax: 091-731-2431214

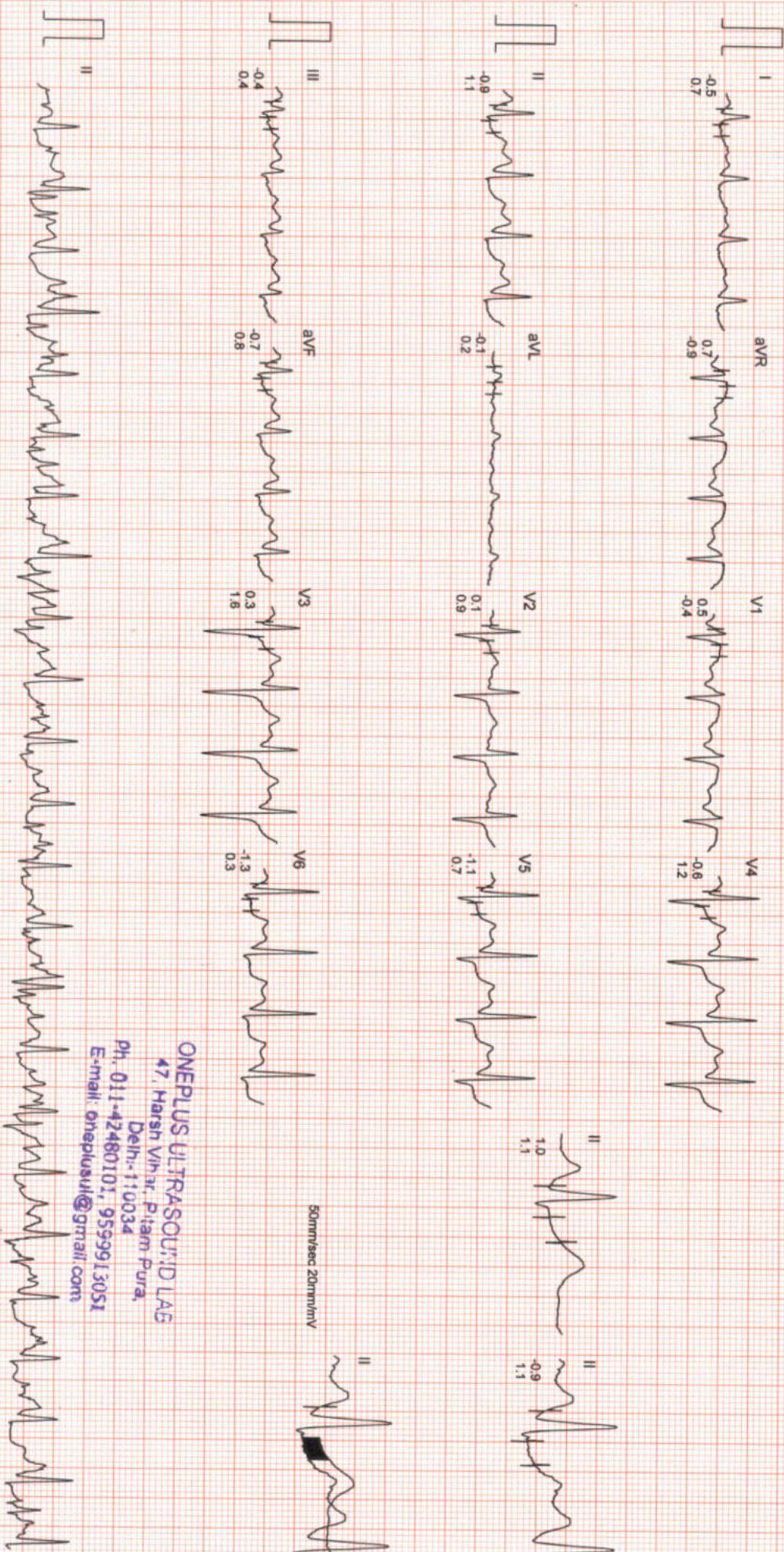
ONEPLUS ULTRASOUND LAB

MR. DEV NANDAN SHAH
I.D. : 989
AGE/SEX : 59/M
RECORDED : 7-1-2023 9:13

RATE : 145 BPM
R.P. : 160/94 mmHg

BRUCE
PEAK EXER
PHASE TIME : 6:38
STAGE TIME : 0:38

ST @ 10mm/mV
80ms PostJ
SPEED : 5.4 Km./HR.
GRADE : 14.0 %
LINKED MEDIAN



Filtered Computer Corrected Baseline 25mm/sec 10mm/mV Cardicom, INDIA Ph.:091-731-2620740, TeleFax:091-731-2431214

ONEPLUS ULTRASOUND LAB
47, Harsh Vihar, Pitam Pura,
Delhi-110034
Ph. 011-42480101, 9599913051
E-mail: onepplusul@gmail.com

ONEPLUS ULTRASOUND LAB

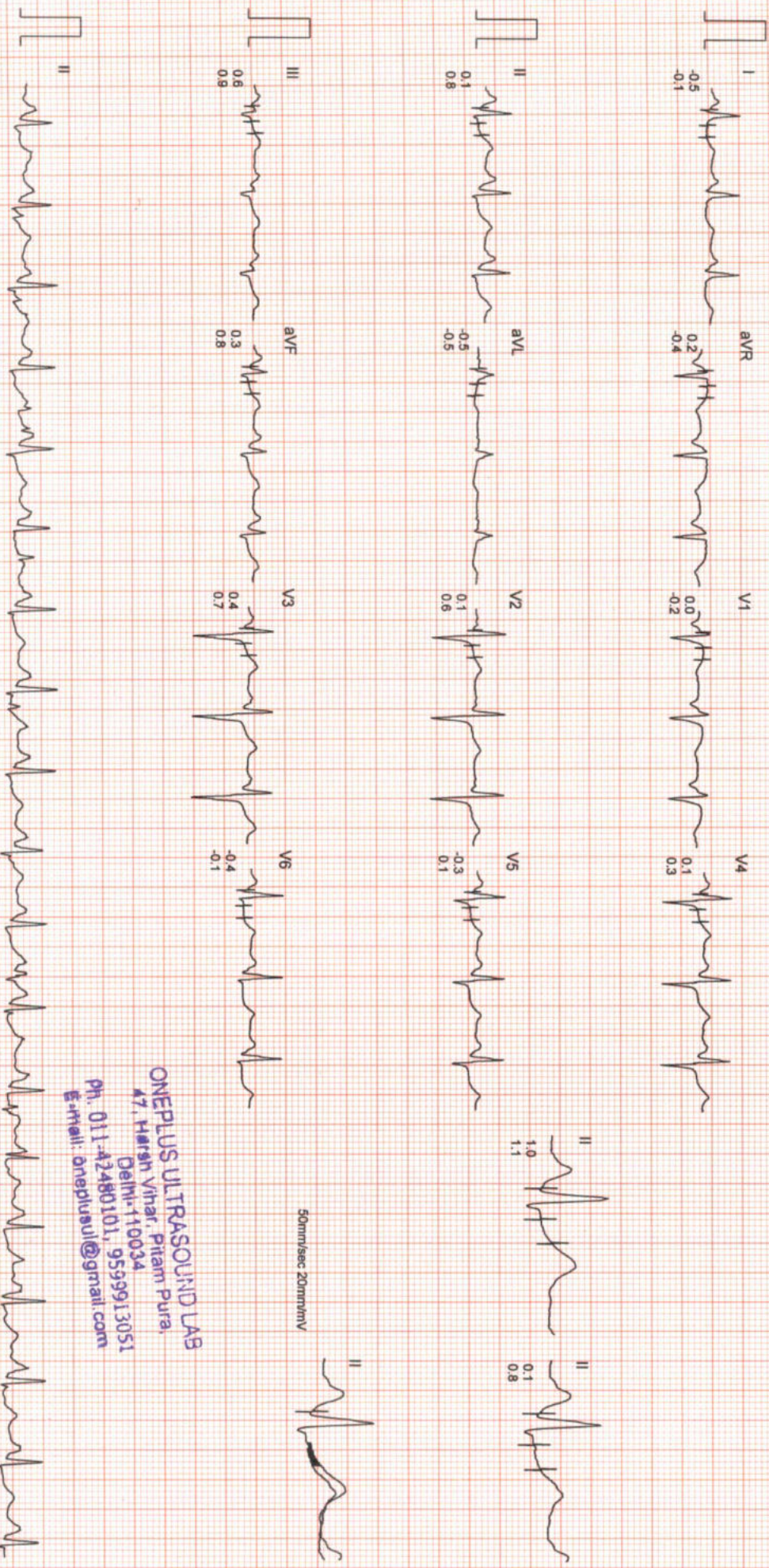
M. DEV NANDAN SHAH
I.D. : 989
AGE/SEX : 59/M
RECORDED : 7-1-2023 9:13

RATE : 112 BPM
B.P. : 138/88 mmHg

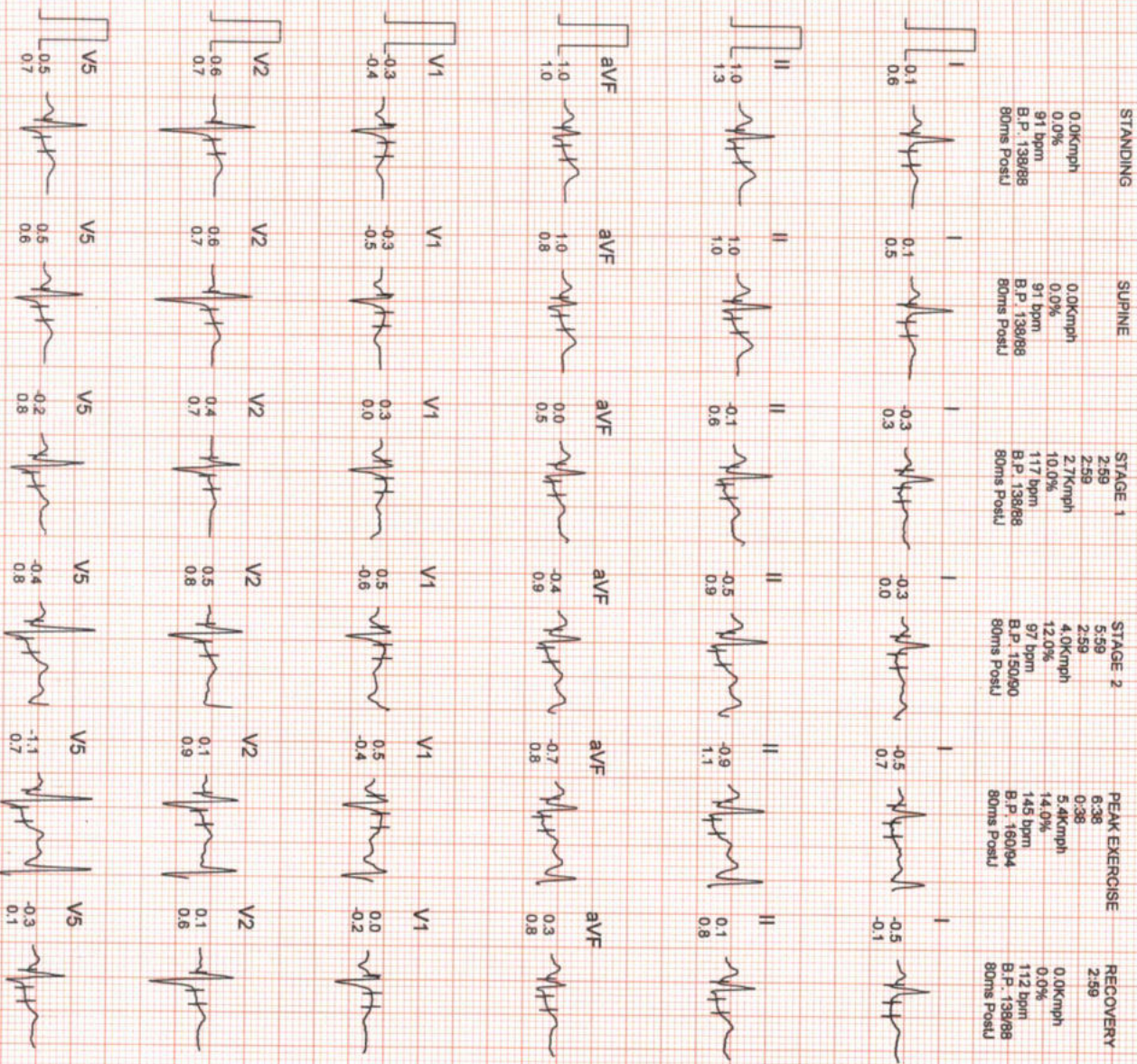
BRUCE
RECOVERY
PHASE TIME : 2:59

ST @ 10mm/mV
80ms PostJ
SPEED : 0.0 Km./Hr.
GRADE : 0.0 %

LINKED MEDIAN

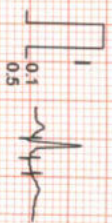


ONEPLUS ULTRASOUND LAB
47, Harsih Vihar, Pitam Pura,
Delhi-110034
Ph. 011-42480101, 9599913051
E-mail: oneplusul@gmail.com



ONEPLUS ULTRASOUND LAB
 17, Harsih Vihar, Pitam Pura,
 Delhi-110034
 Ph. 011-42480101, 9539913051
 E-mail: oneplussul@gmail.com

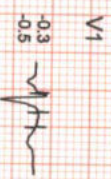
SUPINE
 0.0Kmph
 0.0%
 91 bpm
 B.P. 138/88
 80ms PostJ



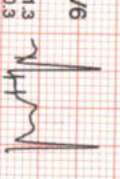
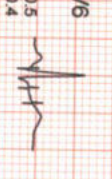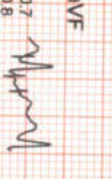
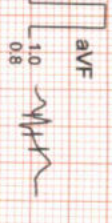
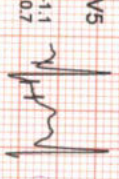
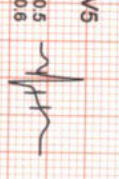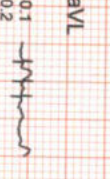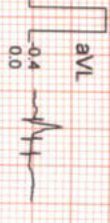
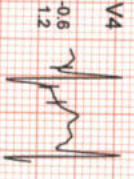
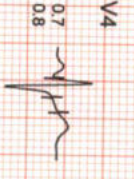
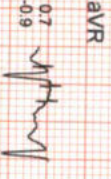
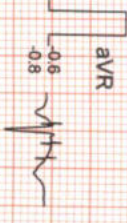
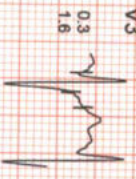
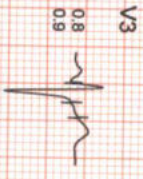
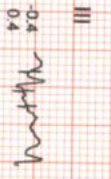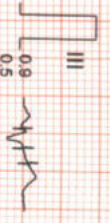

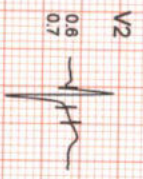
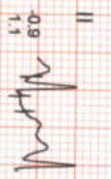

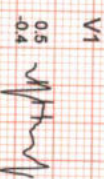
PEAK EXERCISE
 6:38
 0:38
 5.4Kmph
 14.0%
 145 bpm
 B.P. 160/94
 80ms PostJ



SUPINE
 0.0Kmph
 0.0%
 91 bpm
 B.P. 138/88
 80ms PostJ



PEAK EXERCISE
 6:38
 0:38
 5.4Kmph
 14.0%
 145 bpm
 B.P. 160/94
 80ms PostJ



ONEPLUS ULTRASOUND LAB
 17, Star Street, Warangal, Telangana
 India - 506002
 Ph: 011-41484111, 9533918051
 Email: onepplus@oneplusultrasound.com

Name	: Mr. SHAH DEV NANDAN	Age/Sex	: 59 YRS/Male
Ref. By	: Dr. MEDIWHEEL	Lab No	: 012301070003
Date	: 07-Jan-2023	Patient ID	: LSHHI107369

ULTRASOUND EXAMINATION---WHOLE ABDOMEN

Liver is normal in size (13.4 cm) and normal in outline with **altered echopattern. Diffuse increase in echogenicity of liver parenchyma is noted, suggestive of fatty infiltration (grade II). Intrahepatic biliary radicles are not dilated.** No abscess or mass lesion seen. Hepatic veins, portal vein, IVC and aorta are normal. CBD is normal (7.4 mm) in caliber.

Gall bladder is well distended. Wall thickness is normal. **A small single 6.7 mm sized focal nodule, likely benign polyp, is seen adherent along the wall of gall bladder. This could not be moved by gravity. No evidence of cholecystitis or cholelithiasis seen.**

Both kidneys are normal in size, shape, position, outline and echopattern. Corticomedullary differentiation is maintained. No pelvicalyceal dilation or mass lesion is seen.

Spleen is normal in size and echotexture. No mass lesion seen.

Pancreas is normal in size, outline and echotexture.

Urinary bladder is normal in shape and position. No evidence of intravesical stone or mass seen.

Prostate is normal in size, shape and echopattern.

Prostate measures 3.1 x 3.1 x 3.9 cm. **Weight of prostate is 19.3 grams.**

No abnormal bowel wall thickening seen in right iliac fossa.
No free fluid seen anywhere in abdomen.

IMPRESSION:

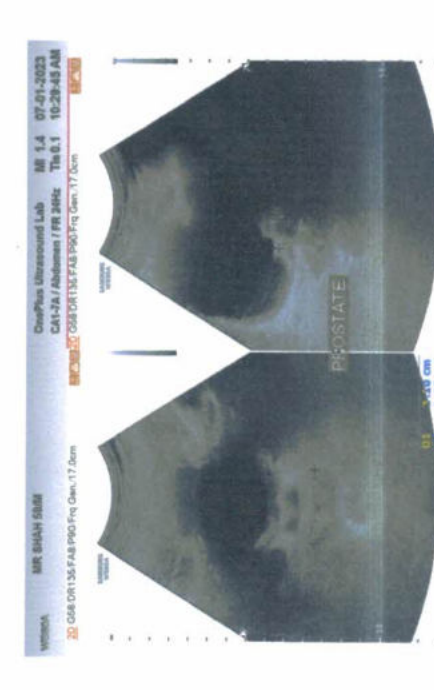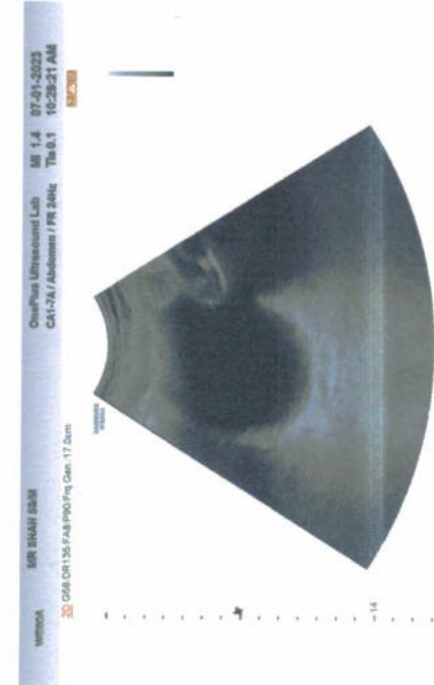
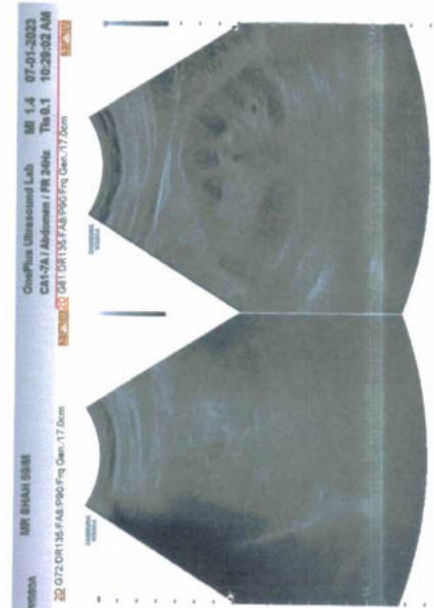


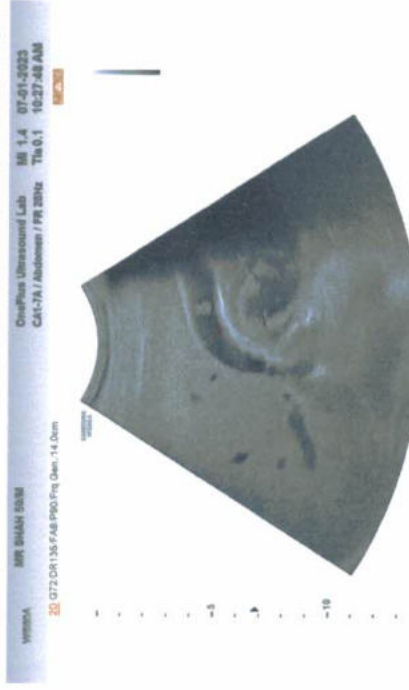
- **Fatty infiltration of liver (grade II) with no hepatomegaly.**

DR. POOJA GARG
RADIOLOGIST
REG NO. DMC/R/03398
Dr. POOJA GARG
M.B.B.S., D.M.R.D.
Reg No. DMC/R/03398
Radiologist

Type By : pooja

47, Harsh Vihar, Pitampura, New Delhi-110034 | Ph.: 011-42480101, 9599913051
E-mail: oneplusul@gmail.com | Web.: www.oneplusul.in

Ultrasound Image Report



Ultrasound Image Report

1505-1515 4.1 20 ASD (Anterior) - Right
MUSCULOSKELETAL
MUSCULOSKELETAL




1505-1515 4.1 20 ASD (Anterior) - Right
MUSCULOSKELETAL
MUSCULOSKELETAL



1505-1515 4.1 20 ASD (Anterior) - Right
MUSCULOSKELETAL
MUSCULOSKELETAL



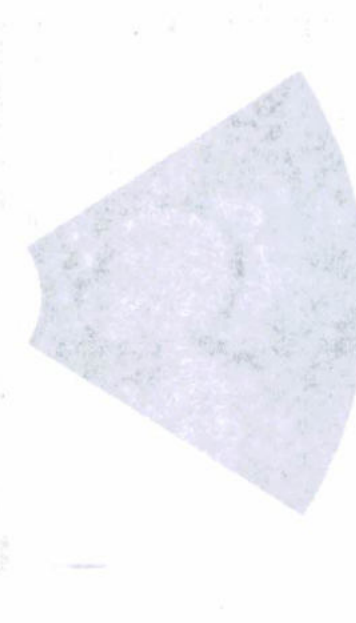
1505-1515 4.1 20 ASD (Anterior) - Right
MUSCULOSKELETAL
MUSCULOSKELETAL



1505-1515 4.1 20 ASD (Anterior) - Right
MUSCULOSKELETAL
MUSCULOSKELETAL



1505-1515 4.1 20 ASD (Anterior) - Right
MUSCULOSKELETAL
MUSCULOSKELETAL



1505-1515 4.1 20 ASD (Anterior) - Right
MUSCULOSKELETAL
MUSCULOSKELETAL



1505-1515 4.1 20 ASD (Anterior) - Right
MUSCULOSKELETAL
MUSCULOSKELETAL



1505-1515 4.1 20 ASD (Anterior) - Right
MUSCULOSKELETAL
MUSCULOSKELETAL



1505-1515 4.1 20 ASD (Anterior) - Right
MUSCULOSKELETAL
MUSCULOSKELETAL



OnePLUS Ultrasound Lab

— QUALITY FIRST... ALWAYS! —

Dr. Nitin Agarwal
Pathologist & Director
Ex. Sr. Res. MAMC
& Lok Nayak Hospital
Ex. Chief of Lab Dr. Lal Path Labs.

Dr. Pooja (Garg) Agarwal
Radiologist & Director
MAMC & Lok Nayak Hospital



NAME	:Mr. DEV NANDAN SHAH	Barcode No	:10135222
AGE/GENDER	:64 YRS/Male	SPECIMEN DATE	:07/Jan/2023 07:56AM
PATIENT ID	:107369	SPECIMEN RECEIVED	:07/Jan/2023 08:04AM
REFERRED BY	:Dr. MEDIWHEEL	REPORT DATE	:07/Jan/2023 03:54PM
CENTRE NAME	:ONEPLUS ULTRASOUND LAB	LAB NO.	:012301070003

Test Name	Result	Unit	Ref. Range
-----------	--------	------	------------

HAEMATOLOGY

Health checkup 2 Male

Glycosylated Hemoglobin (HbA1c)	6.6	%	Non Diabetic adults <5.7 Prediabetic (at risk) 5.7-6.4 Diabetes >6.4
--	-----	---	--

Estimated average blood glucose (eag)	143
--	-----

Reference range (mg/dl):

90 - 120:Excellent control, 121 - 150:Good Control, 151 - 180:Average Control, 181 - 210:Action Suggested

>211:Panic value

BLOOD GROUP (ABO)	B
Rh typing	POSITIVE

NOTE :

- * Apart from major A,B,H antigens which are used for ABO grouping and Rh typing, many minor blood group antigens exist. Agglutination may also vary according to titre of antigen and antibody.
- * So before transfusion, reconfirmation of blood group as well as cross-matching is needed.
- * Presence of maternal antibodies in newborns, may interfere with blood grouping.
- * Auto agglutination (due to cold antibody, falciparum malaria, sepsis, internal malignancy etc.) may also cause erroneous result.

CBC

Haemoglobin	16.0	g/dl	13.0-17.0
Total Leucocyte Count	6300	/cumm	4000-10000
Differential leucocyte count			
Neutrophils	66.8	%	40-80
Lymphocyte	26.70	%	20-40
Monocytes	3.50	%	2-10
Eosinophils	2.4	%	1-6
Basophils	0.6	%	0-2
RBC Count	5.20	million/cumm	4.5 - 5.5

Checked By.

Dr. NITIN AGARWAL
MBBS, MD (P),
DMC/R/01436
DR. NITIN AGARWAL
MBBS, MD (PATHOLOGIST)

47, Harsh Vihar, Pitampura, New Delhi-110034 | Ph.: 011-42480101, 9599913051
E-mail: oneplusul@gmail.com | Web.: www.oneplusul.in

Page 1 of 6



OnePLUS Ultrasound Lab

— QUALITY FIRST... ALWAYS! —

Dr. Nitin Agarwal

Pathologist & Director

Ex. Sr. Res. MAMC

& Lok Nayak Hospital

Ex. Chief of Lab Dr. Lal Path Labs.

Dr. Pooja (Garg) Agarwal

Radiologist & Director

MAMC & Lok Nayak Hospital



NAME	:Mr. DEV NANDAN SHAH	Barcode No	:10135222
AGE/GENDER	:64 YRS/Male	SPECIMEN DATE	:07/Jan/2023 07:56AM
PATIENT ID	:107369	SPECIMEN RECEIVED	:07/Jan/2023 08:04AM
REFERRED BY	:Dr. MEDIWHEEL	REPORT DATE	:07/Jan/2023 03:54PM
CENTRE NAME	:ONEPLUS ULTRASOUND LAB	LAB NO.	:012301070003

Test Name	Result	Unit	Ref. Range
PCV(Hematocrit)	51.3	%	40-50
MCV	99.1	fL	83-101
MCH	30.9	Pg	27-32
MCHC	31.2	G/dL	32-35
Platelet count	158000	/cumm	150000-450000
RDW-CV	12.9	%	11.4-14.0
ESR(WESTEGRENs METHOD)	10	mm in 1st hr	0-20

BIOCHEMISTRY

<u>Blood sugar fasting</u>	130	mg/dL	70-110
<u>Blood sugar pp</u>	120	mg/dL	70.0-140.0
<u>Bun (blood urea nitrogen)</u>	12.20	mg/dl	8.4-25.7
<u>Uric acid, serum</u>	4.6	mg/dl	3.5-7.2
<u>Creatinine, serum</u>	0.7	mg/dl	0.60-1.2


LFT(LIVER FUNCTION TEST)

Bilirubin Total	0.58	mg/dl	0.1-1.2
Bilirubin Conjugated	0.28	mg/dl	0-0.4
Bilirubin Unconjugated	0.3	mg/dl	up to 0.7
SGOT (AST)	27	U/L	0-46
SGPT (ALT)	33	U/L	0-49
Alkaline phosphatase	98	U/L	40-129
Gamma glutamyl transpeptidase	28	U/L	10-45
Total Protein	7.4	gm/dl	6.60 - 8.70
Albumin serum	4.2	g/dL	3.0-5.2
Globulin	3.20	gm/dl	1.8-3.4
Albumin/Globulin Ratio	1.31		1.10 - 2.50

LIPID PROFILE

Cholesterol	257	mg/dl	50-200
Triglycerides	194	mg/dL	25-150

Checked By.


Dr NITIN AGARWAL
 M B B S , MD (P) MBBS, MD(PATHOLOGIST)
 DMC/R/01436

47, Harsh Vihar, Pitampura, New Delhi-110034 | Ph.: 011-42480101, 9599913051

E-mail: oneplusul@gmail.com | Web.: www.oneplusul.in

Page 2 of 6



OnePLUS Ultrasound Lab

— QUALITY FIRST... ALWAYS! —

Dr. Nitin Agarwal

Pathologist & Director
Ex. Sr. Res. MAMC
& Lok Nayak Hospital
Ex. Chief of Lab Dr. Lal Path Labs.

Dr. Pooja (Garg) Agarwal

Radiologist & Director
MAMC & Lok Nayak Hospital



NAME	:Mr. DEV NANDAN SHAH	Barcode No	:10135222
AGE/GENDER	:64 YRS/Male	SPECIMEN DATE	:07/Jan/2023 07:56AM
PATIENT ID	:107369	SPECIMEN RECEIVED	:07/Jan/2023 08:04AM
REFERRED BY	:Dr. MEDIWHEEL	REPORT DATE	:07/Jan/2023 03:54PM
CENTRE NAME	:ONEPLUS ULTRASOUND LAB	LAB NO.	:012301070003

Test Name	Result	Unit	Ref. Range
HDL Cholesterol	55	mg/dL	40 - 60
LDL cholesterol	163	mg/dL	<130
VLDL cholesterol	38.8	mg/dL	5-40
Cholesterol/HDL Ratio	4.7		Low Risk 3.3-4.97 Average Risk 4.4-7.1 Moderate Risk 7.1-11.0 High Risk >11.0
LDL/HDL Ratio	3.0		0 - 3.55

According to ATP III and NCEP guidelines

Parameter	Normal	Desirable	Borderline	High
Total cholesterol	<200		200-239	240
Triglycerides	<150	150-199	200-499	500
LDL	Optimal <100 Near Optimal 100-129	130-159	160-180	190
HDL	<40 : LOW 60 : HIGH			

ENDOCRINOLOGY

PSA TOTAL

Prostatic specific antigen, Total 1.00 ng/ml <4.0

< 40 years	0.21 to 1.72 ng/ml
40 - 49	0.27 to 2.19 ng/ml
50 - 59	0.27 to 3.42 ng/ml
60 - 69	0.22 to 6.16 ng/ml
> 69	0.21 to 6.77 ng/ml

Notes:

Checked By.

Dr. NITIN AGARWAL
M B B S , MD (Path)
DMC/R/01436

DR. NITIN AGARWAL
MBBS, MD(PATHOLOGIST)

47, Harsh Vihar, Pitampura, New Delhi-110034 | Ph.: 011-42480101, 9599913051

E-mail: oneplusul@gmail.com | Web.: www.oneplusul.in

Page 3 of 6



OnePLUS Ultrasound Lab

— QUALITY FIRST... ALWAYS! —

Dr. Nitin Agarwal
Pathologist & Director
Ex. Sr. Res. MAMC
& Lok Nayak Hospital
Ex. Chief of Lab Dr. Lal Path Labs.

Dr. Pooja (Garg) Agarwal
Radiologist & Director
MAMC & Lok Nayak Hospital



NAME	:Mr. DEV NANDAN SHAH	Barcode No	:10135222
AGE/GENDER	:64 YRS/Male	SPECIMEN DATE	:07/Jan/2023 07:56AM
PATIENT ID	:107369	SPECIMEN RECEIVED	:07/Jan/2023 08:04AM
REFERRED BY	:Dr. MEDIWHEEL	REPORT DATE	:07/Jan/2023 03:54PM
CENTRE NAME	:ONEPLUS ULTRASOUND LAB	LAB NO.	:012301070003

Test Name	Result	Unit	Ref. Range
PSA is principally produced by the glandular epithelium of the prostate, and is secreted in the seminal fluid. PSA is also present in urine and blood. PSA acts on seminal fluid to fluidify and increase sperm mobility. PSA levels rise in prostatic pathologies such as benign prostatic hyperplasia (BPH) or prostate cancer.			

THYROID PROFILE(T3,T4,TSH)

Triiodothyronine total [t3]	0.84	ng/dl	0.52-1.9
Thyroxine total [t4]	7.60	µg/dl	4.4 - 10.8
TSH (Thyroid Stimulating Hormone)	2.10	µIU/ml	0.25-5.0

AGE WISE VARIATION IN TSH

AGE	TSH(µIU/ml)	AGE	TSH(µIU/ml)
1-4 weeks	1.00 - 19.0	16-20 yrs	0.25 - 5.0
1-12 mths	1.70 - 9.1	21 - 80 yrs	0.25 - 5.0
1-5 yrs	0.80 - 8.2	I st trimester	0.25 - 5.0
6-10 yrs	0.25 - 5.0	II nd trimester	0.50 - 5.0
11-15 yrs	0.25 - 5.0	III rd trimester	0.4 - 6.0

Reference ranges - Interpretation of Diagnostic tests - (Jacques Wallach)

1. Primary hypothyroidism is accompanied by depressed serum T3 and T4 values and elevated serum TSH level.
2. Primary hyperthyroidism is accompanied by elevated serum T3 and T4 levels along with depressed TSH values.
3. Slightly elevated T3 levels may be found in pregnancy and estrogen therapy, while depressed levels may be encountered in severe illness, renal failure and during therapy with drugs like propranolol and propyl thiouracil.
4. Although elevated TSH levels are nearly always indicative of primary hypothyroidism, and may be seen in secondary thyrotoxicosis

CLINICAL PATHOLOGY

URINE ROUTINE

Physical examination

Quantity	20	ML
Colour	PALE YELLOW	
Transparency	SLIGHTLY TURBID	CLEAR
Sp.gravity	1.010	1.010-1.030
pH	6.50	

Checked By.

Dr NITIN AGARWAL
M B B S , MD (Pathology)
DMC/R/01436 MBBS,MD(PATHOLOGIST)

47, Harsh Vihar, Pitampura, New Delhi-110034 | Ph.: 011-42480101, 9599913051

E-mail: oneplusul@gmail.com | Web.: www.oneplusul.in

Page 4 of 6

Clinical correlation is essential for final diagnosis. • If test results are unsatisfactory please contact personally or on phone. • This report is for perusal of doctors only. • All disputes Subject to Delhi Jurisdiction only. • Not for medicolegal purposes. • All congenital anomalies in a foetus may not be diagnosed in routine obstetric ultrasound.



OnePLUS Ultrasound Lab

— QUALITY FIRST... ALWAYS! —

Dr. Nitin Agarwal

Pathologist & Director
Ex. Sr. Res. MAMC
& Lok Nayak Hospital
Ex. Chief of Lab Dr. Lal Path Labs.

Dr. Pooja (Garg) Agarwal

Radiologist & Director
MAMC & Lok Nayak Hospital



NAME	:Mr. DEV NANDAN SHAH	Barcode No	:10135222
AGE/GENDER	:64 YRS/Male	SPECIMEN DATE	:07/Jan/2023 07:56AM
PATIENT ID	:107369	SPECIMEN RECEIVED	:07/Jan/2023 08:04AM
REFERRED BY	:Dr. MEDIWHEEL	REPORT DATE	:07/Jan/2023 03:54PM
CENTRE NAME	:ONEPLUS ULTRASOUND LAB	LAB NO.	:012301070003

Test Name	Result	Unit	Ref. Range
Reaction	ACIDIC		ACIDIC
<u>Chemical examination</u>			
Urine protein	NIL		NIL
Urine sugar	NIL		NIL
Bilirubin, urine	NEGATIVE		NEGATIVE
Urobilinogen	NORMAL		NORMAL
Ketones	NEGATIVE		NEGATIVE
<u>Microscopic examination</u>			
Pus cells.	2-3	/HPF	0-2
Epithelial cells	1-2	/HPF	NIL
R.B.C.	NIL	/HPF	NIL
Casts	NIL	/HPF	NIL
Crystals	CALCIUM OXALATE SEEN	/HPF	NIL
Bacteria	NIL	/HPF	NIL
Others.	NIL	NIL	NIL
STOOL ROUTINE			
<u>Physical examination</u>			
Colour	BROWNISH		
Consistency	SEMI LOOSE		Semi Formed
Blood	ABSENT		Absent
Mucus	ABSENT		Absent
<u>Chemical examination, stool</u>			
pH	6.50		
<u>Microscopic examination</u>			
Pus cells	0-1	/HPF	
R.B.C.	NIL	/HPF	NIL
Ova	NIL		NIL
Cysts	NIL		NIL

Checked By.

Dr. NITIN AGARWAL
M B B S, MD (Path)
DMC/R/01436
DR. NITIN AGARWAL
MBBS, MD (PATHOLOGIST)

47, Harsh Vihar, Pitampura, New Delhi-110034 | Ph.: 011-42480101, 9599913051

E-mail: oneplusul@gmail.com | Web.: www.oneplusul.in

Page 5 of 6



OnePLUS Ultrasound Lab

— QUALITY FIRST... ALWAYS! —

Dr. Nitin Agarwal

Pathologist & Director
Ex. Sr. Res. MAMC
& Lok Nayak Hospital
Ex. Chief of Lab Dr. Lal Path Labs.

Dr. Pooja (Garg) Agarwal

Radiologist & Director
MAMC & Lok Nayak Hospital




NAME	:Mr. DEV NANDAN SHAH	Barcode No	:10135222
AGE/GENDER	:64 YRS/Male	SPECIMEN DATE	:07/Jan/2023 07:56AM
PATIENT ID	:107369	SPECIMEN RECEIVED	:07/Jan/2023 08:04AM
REFERRED BY	:Dr. MEDIWHEEL	REPORT DATE	:07/Jan/2023 03:54PM
CENTRE NAME	:ONEPLUS ULTRASOUND LAB	LAB NO.	:012301070003

Test Name	Result	Unit	Ref. Range
Bacteria	PRESENT	/HPF	NIL
Others	NIL		

*** End Of Report ***

Checked By.

Dr NITIN AGARWAL 
M B B S , MD (Path) DR. NITIN AGARWAL
DMC/R/01436 MBBS,MD(PATHOLOGIST)

47, Harsh Vihar, Pitampura, New Delhi-110034 | Ph.: 011-42480101, 9599913051

E-mail: oneplusul@gmail.com | Web.: www.oneplusul.in

Page 6 of 6

Clinical correlation is essential for final diagnosis. • If test results are unsatisfactory please contact personally or on phone. • This report is for perusal of doctors only.
• All disputes Subject to Delhi Jurisdiction only. • Not for medicolegal purposes. • All congenital anomalies in a foetus may not be diagnosed in routine obstetric ultrasound.



OnePLUS
Ultrasound Lab

— QUALITY FIRST... ALWAYS! —

Dr. Nitin Agarwal

Pathologist & Director
Ex. Sr. Res. MAMC
& Lok Nayak Hospital
Ex. Chief of Lab Dr. Lal Path Labs.

Dr. Pooja (Garg) Agarwal

Radiologist & Director
MAMC & Lok Nayak Hospital

Name	: Mr. DEV NANDAN SHAH	Age/Sex	: 64 YRS/Male
Ref. By	: Dr. MEDIWHEEL	Lab No	: 012301070003
Date	: 07-Jan-2023	Patient ID	: LSHHI107369

X-ray-Chest PA view

Bony cage and soft tissues are normal.
Cardiothoracic ratio is normal.
Mediastinum is normal.
Both hila are normal.
Both costophrenic angles are clear.
Both domes of diaphragm are normal.
Lung fields are clear. No parenchymal lesion seen.

IMPRESSION: Normal Study.

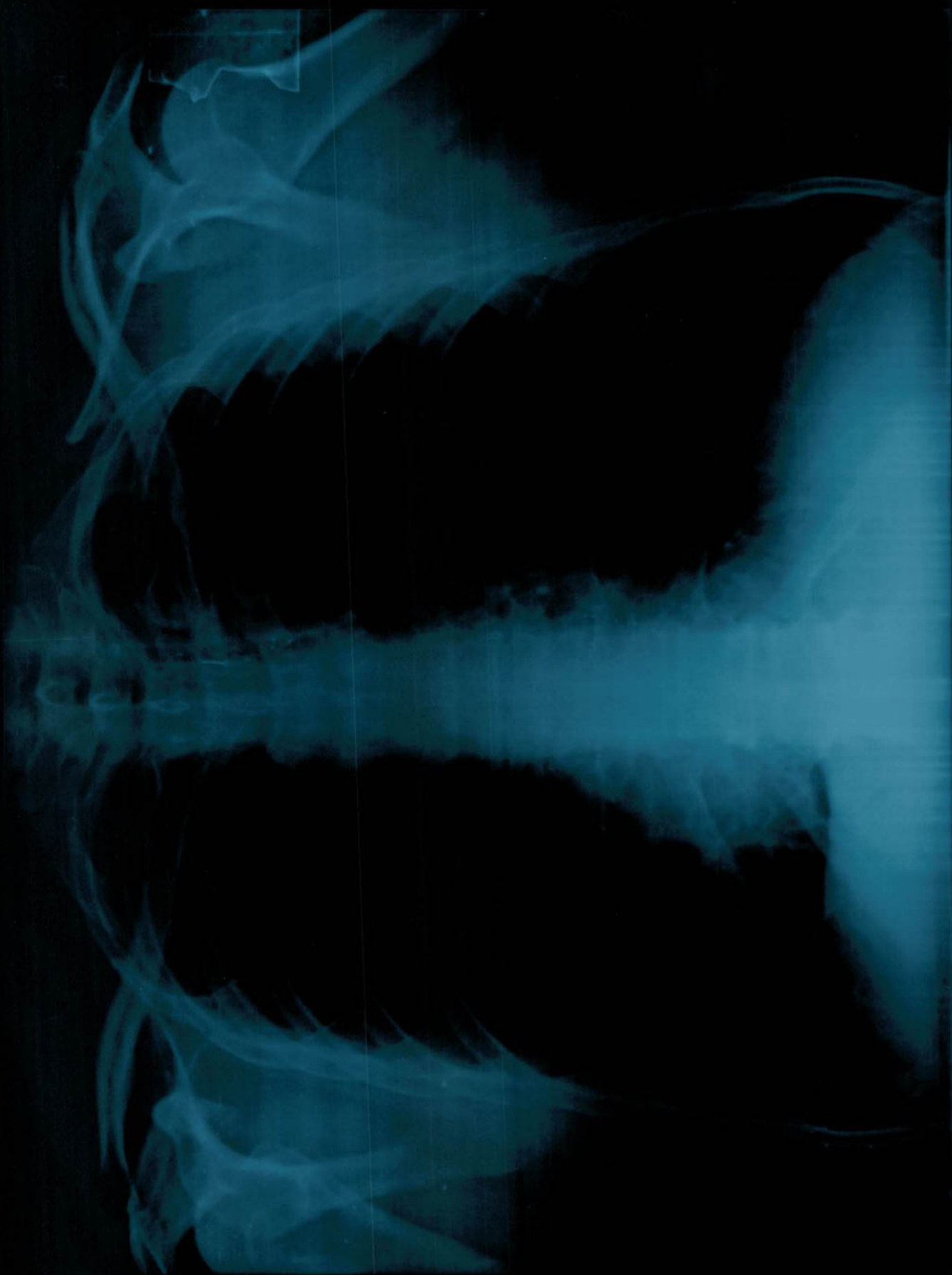

Dr. SAMRIDHI GARG
MBBS, DNB
DR. SAMRIDHI GARG
CONSULTANT RADIOLOGIST
Reg. No. DMC No. 09087
REG NO- DMC/R/09087
Radiologist
Reg. No. DMC No. 09087
MBBS, DNB
Dr. SAMRIDHI GARG

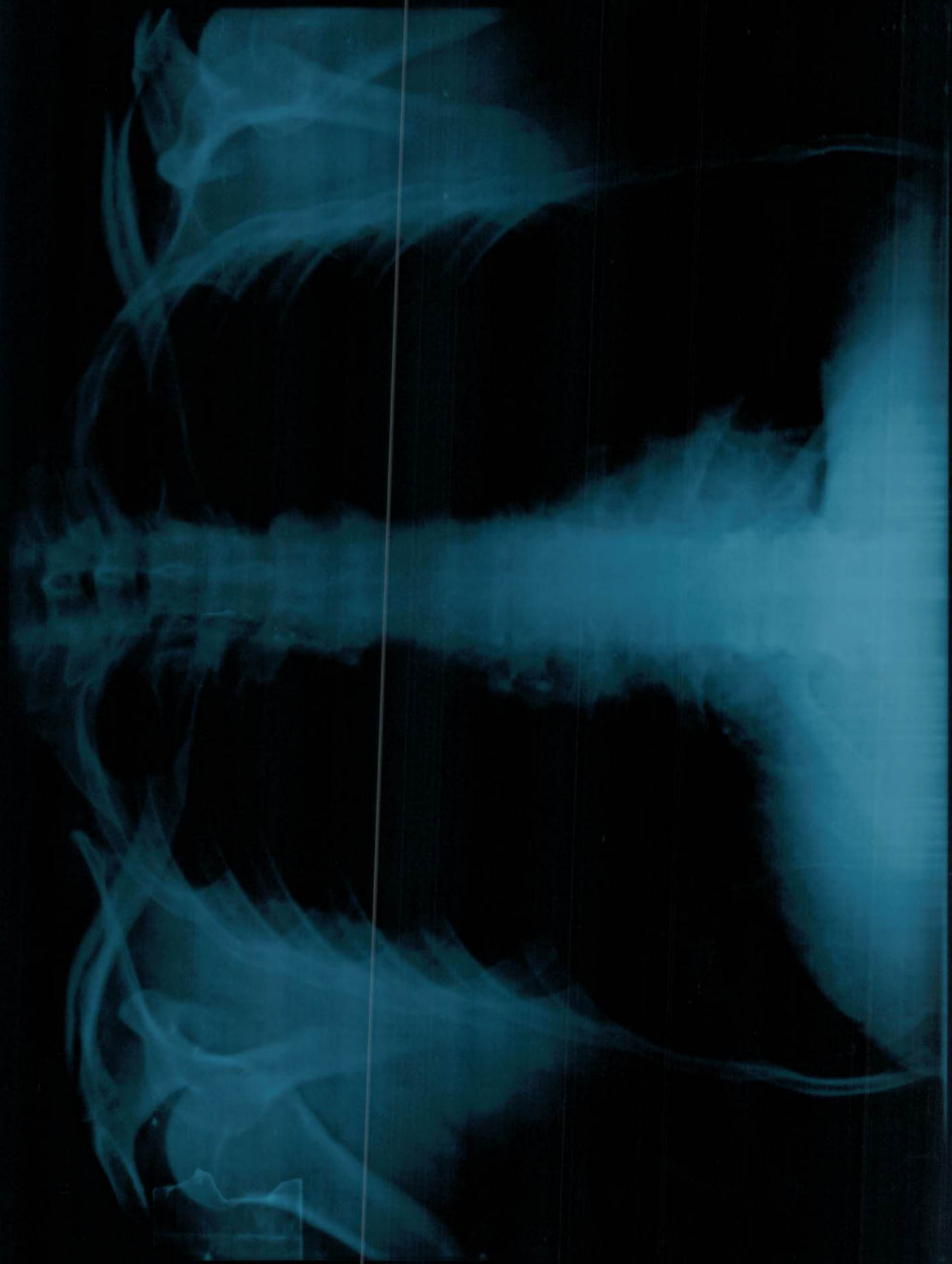
47, Harsh Vihar, Pitampura, New Delhi-110034 | Ph.: 011-42480101, 9599913051

E-mail: oneplusul@gmail.com | Web.: www.oneplusul.in

Clinical correlation is essential for final diagnosis. • If test results are unsatisfactory please contact personally or on phone. • This report is for perusal of doctors only.
• All disputes Subject to Delhi Jurisdiction only. • Not for medicolegal purposes. • All congenital anomalies in a foetus may not be diagnosed in routine obstetric ultrasound.

ONE PLUS ULTRASOUND I AB 43 HARSH AHER PITAMPURA
MR. DEV NANDAN SHAH 21/5053 M CHESTI BA NIEM 12/5053





MR DEV NANDAN SHAH 7/1/2023 M CHEST PA VIEW 1/7/2023
ONEPLUS UI TRASOUND I AB 47 HARSH VIHAR PITAMPURA