

**Facilities:**

All clinical Biomedical & Hematology Investigations including Bone Marrow Examination  
VPT, Podiascan & Complete Foot Care (First Time in Purvanchal)  
All Hormonal Investigation by Chemiluminescent Method  
Visceral Fat by (AB-140) Ambulatory BP Monitoring  
CGMS & Insulin Pump Available  
PFT, 2D-ECHO (Color Doppler), Holter, TMT, Cardiac-3 available  
VIA, VILI, Colposcopy available  
Special Endocrinological Investigation Protocols.

ISO 9001:2008 Certified  
Mobile: 9389994334, 9554572190, 9453837595



# Panacea Pathology

## Clinical Reference Lab

Persistence, Preparedness and Precision  
EQAS (CMC Vellore Attached) & IQAS System  
पूर्वांचल की सर्वोत्तम गुणवत्ता वाली पैथोलॉजी

PATIENT NAME : PALLAVI SINGHAL

AGE/GENDER : 33 YRS/FEMALE

REFD BY DR. : ARCO FEMI HEALTHCARE LTD.

RECEIVED DATE : 28-01-2023(10:00AM)

SAMPLE : BLOOD & URINE

REPORT DATE : 28-01-2023(06:00PM)

## PATHOLOGY REPORT

### COMPLETE BLOOD COUNT (CBC)

| TEST                          | LAB TEST VALUES | NORMAL RANGE             |
|-------------------------------|-----------------|--------------------------|
| <b>HEMOGRAM</b>               |                 |                          |
| HEMOGLOBIN (FLOW CYTOMETRY)   | 8.2             | 13 – 16 gm/dl            |
| TOTAL LEUCOCYTE COUNT (TLC)   | 7000            | 4000 – 11000             |
| RBC COUNT                     | 3.63            | 3.5 – 5.5                |
| PCV (HCT)                     | 27.0            | 37 – 47                  |
| MCV                           | 74.4            | 80 – 95                  |
| MCH                           | 22.5            | 28 – 34                  |
| MCHC                          | 30.2            | 30 – 36                  |
| PLATELET COUNT                | 2,60,000        | 1,50,000 – 4,00,000      |
| E.S.R. (WINTROBE FIRST HOURS) | 38.0            | 20 mm/1 <sup>st</sup> hr |
| <b>DIFFERENTIAL LEUCOCYTE</b> |                 |                          |
| NEUTROPHILS                   | 70              | 40 – 75%                 |
| LYMPHOCYTES                   | 25              | 20 – 45%                 |
| EOSINOPHILS                   | 02              | 1 – 6%                   |
| MONOCYTES                     | 03              | 2 – 8%                   |
| BASOPHILS                     | 00              | < 2%                     |

### RENAL & KIDNEY PROFILE, SERUM

| TEST                        | LAB TEST VALUES | NORMAL RANGE            |
|-----------------------------|-----------------|-------------------------|
| <b>RENAL FUNCTION TESTS</b> |                 |                         |
| BLOOD UREA NITROGEN (BUN)   | 10.2            | 10 – 50 mg/dl           |
| SERUM CREATININE            | 00.81           | 0.60 – 1.60 mg/dl       |
| URIC ACID                   | 3.25            | 3.60 – 7.70 mg/dl       |
| ALKALINE PHOSPHATASE (ALP)  | 68.0            | 142 – 353 mg/dl         |
| TOTAL PROTIENS              | 7.25            | 0 – 39 mg/dl            |
| ALBUMIN                     | 4.10            | 3.8 – 5.4 mg/dl         |
| SERUM GLOBULIN              | 3.15            | 2.1 – 3.5 mg/dl         |
| CALCIUM                     | 9.0             | 8.80 – 10.20            |
| PHOSPHORUS                  | 3.04            | 2.50 – 5.00             |
| SERUM SODIUM NA+            | 1.005           | 135.00 – 155.00 mEq/Ltr |
| SERUM POTASIAM K+           | 4.12            | 3.60 – 5.50 mEq/Ltr     |
| ICALCIUM                    | 1.22            | 1.10 – 1.35 mmol/L      |
| SERUM CHLORIDE CL+          | 101.3           | 98.00 – 110.00 mEq/Ltr  |

PAGE 1

Lab Technician

**PANACEA HOSPITAL**  
(A UNIT OF AAROH HEALTH CARE PVT. LTD)  
REG. NO. AL-1500  
B.36/44, B-4, KABIR NAGAR  
DURGAKUND, VARANASI

Timing : 8.00 a.m. to 9.00 p.m. (Sunday 8.00 a.m. to 3.00 p.m.)

This Report is not valid for medico legal purpose

**Note:** These tests have technical limitations. Clinico-pathological interpretation is necessary. In case of any disparity test may be repeated immediately.

Address : 36/44 FK Kabir Nagar, Durgakund, Varanasi – 221005

Email: [dramishra@gmail.com](mailto:dramishra@gmail.com), [drpallaviojha@gmail.com](mailto:drpallaviojha@gmail.com) Website: [panaceahospital.org](http://panaceahospital.org)



# PANACEA HOSPITAL

B 36/44 F.K KABIR NAGAR, DURGAKUND  
TOLLFREE NO-18001233070.  
Whatsapp No - 8795832852  
www.piire.org



## OP Slip

Print Date : 28-Jan-2023 05:22PM



|   |   |                                      |
|---|---|--------------------------------------|
| <b>UHID No</b> :- UD-22230003440                            | <b>OP No</b> :- OP-22230012792                  | <b>OP Date</b> :- 28 Jan 2023 5:21PM |
| <b>Patient Name</b> :- Mrs PALLAVI SINGAL<br>BANK OF BARODA | <b>Age/Sex</b> :- 33 Y/Female                   | <b>Mobile No</b> :- 9304202090       |
| <b>Husband</b> :- ANKUR SINGAL                              | <b>Department</b> :- OBST. & GYNAECOLOGY        |                                      |
| <b>Pay Type</b> :- Cash                                     | <b>Consultant</b> :- Dr Tusharika Rai (MBBS,MS) |                                      |
| <b>Token No</b> :- NOR. - 7                                 | <b>Paid/Bal</b> :- 0.00 / 500.00                |                                      |
| <b>Patient Type</b> :- Normal                               |   |                                      |
| <b>Address</b> :- VNS, varanasi                             |   |                                      |

BP :- 120/80  
height :-  
Weight (kg) :- 79.5  
BMI :- 98  
SpO2 :-  
PR :- 78

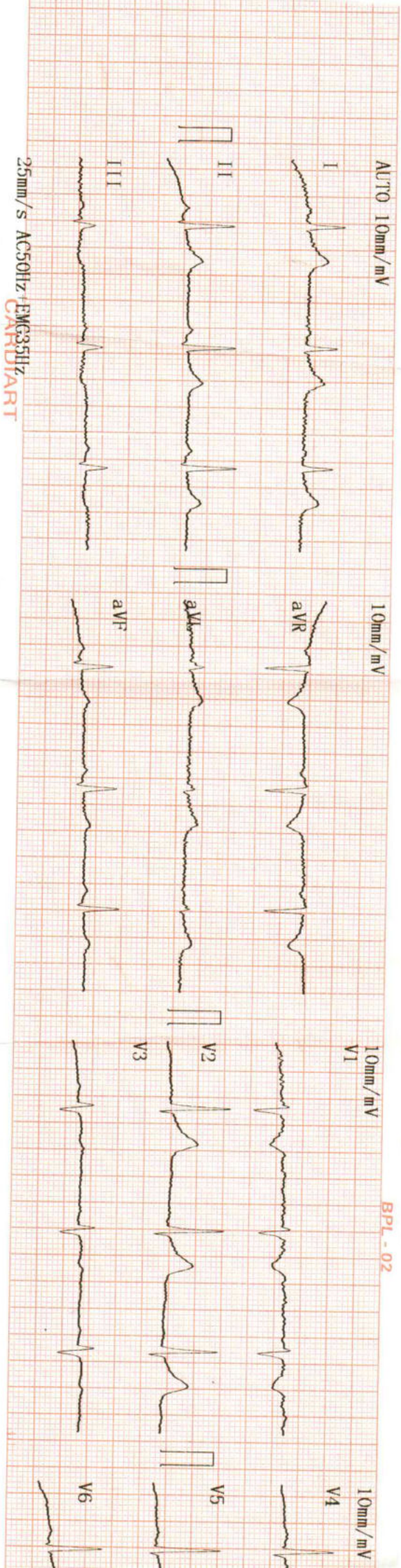
**Rx** Pilo (IARTH) Clo. Irregular periods X 3-4 years  
↓ Δ - 6 yrs | 0 | TVD | ARTH.  
LMP - 16/1/2023  
MH - ~~Regular~~ 3-4 day [ F-Aug. P ⊕ OCC. 28-30d L ⊕ ]  
Spotting on 1st day.

Hb - 8.2 gm %

USG - cholelithiasis  
Borderline  
Splenomegaly.

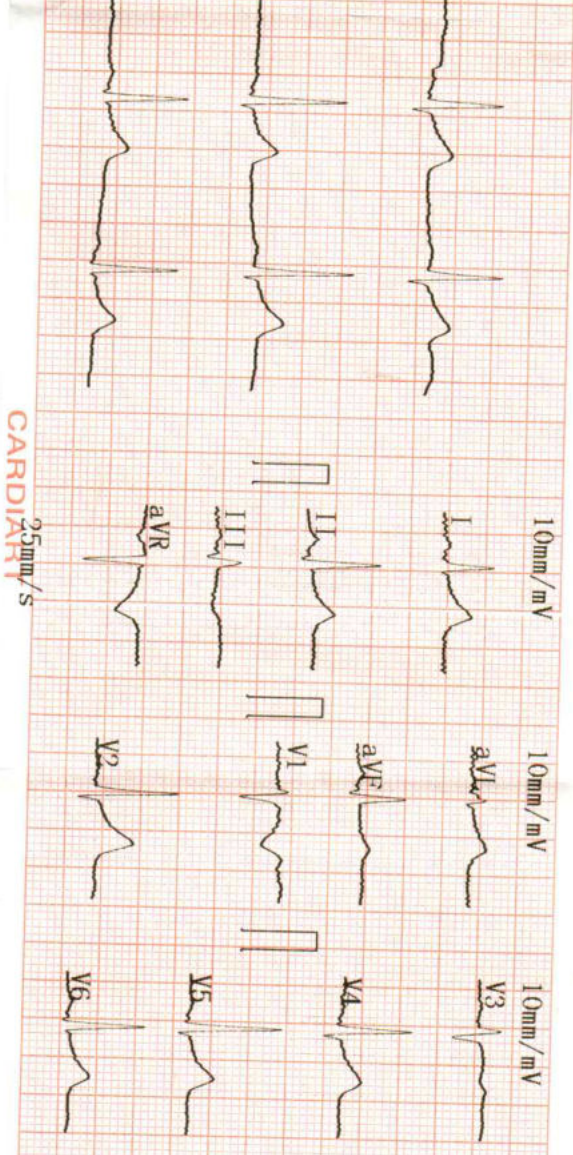
Adv. - USG whole abdomen  
- liquid base  
cytology / PAP smear  
PAP taken on touch.  
F heal pessary p/v X 6 mths  
- Syp Menohelp 2 tet < X/month.  
- TB lactogut UA BD < X 2 weeks.

Printed By : Mr NITIN YADAV  
Created By : Mr NITIN YADAV



BPL - 02

CARDIAC 25mm/s



2023-01-28 12:31  
 ID :  
 Name : **Pallavi**  
 Sex : **F**  
 Height :  
 SYS :  
 DIA :  
 HR : 65 [bpm]  
 PR Interval : 151 ms  
 P Duration : 120 ms  
 QRS Duration : 87 ms  
 T Duration : 220 ms  
 QT/QTc : 391/405 ms  
 P/QRS/T Axis : 33.2/45.4/25.2 deg  
 R(V5)/S(V1) : 1.23/0.50 mV  
 R(V5)+S(V1) : 1.74 mV

<< Conclusions >>

Normal Sinus Rhythm  
 Cardiac electric axis normal;  
 \*\*Report need physician confirm\*\*

Physician

*Pallavi*  
**DR. PALLAVI MISHRA**  
 MBBS, MD (GENERAL MEDICINE)  
 MCI Reg. No. 52033



# PANACEA HOSPITAL

*A shelter for many hearts* *A Home for many lives*

(An ISO 9001:2008 Certified Organisation)

Lab Attached with CMC Vellore Under EQAS Scheme

|         |                       |                      |      |             |            |
|---------|-----------------------|----------------------|------|-------------|------------|
| Name    | MRS.PALLAVI SINGAL    | Sex /Age             | 33/F | Date        | 28/01/2023 |
| Ref. by | Dr.Pallavi Mishra(MD) | BSA - m <sup>2</sup> |      | Echo window | fair       |

## Echo - Cardiography

|                         |   |   |
|-------------------------|---|---|
| MITRAL VALVE Doppler    | AML - normal morphology<br>MV Flow - E - 0.9 A-0.5<br>E/A=1.73  | PML - normal morphology<br>MVA - 3.0 cm <sup>2</sup><br>Mitral Regurgitation - <b>No</b>  |
| TRICUSPID VALVE Doppler | Normal<br>TV Flow -No   | Tricuspid Regurgitation - <b>No</b>   |
| PULMONARY VALVE Doppler | Normal<br>PV Flow -No   | Pulmonary Regurgitation - No  |
| AORTIC VALVE Doppler    | Trileaflet-No<br>AV Flow - no   | Aortic Regurgitation - no   |
| MEASUREMENT             | Aorta - 31.4 (20-38) mm<br>IVS ed - 12.0 (6 -12) mm<br>LVID ed - 49.7 (35 - 55) mm<br>LVPW ed - 7.4 (6 -12) mm<br>OA - 7 (> 5) mm | LA - 30.8 (24-32) mm<br>IVS es -13.7 (6 - 12) mm<br>LVID es - 36.0 (24 - 40) mm<br>LVPW es - 12.0 (6 -12) mm<br>EPSS - 6 (< 9) mm |

**CONCLUSION**

All cardiac chamber dimensions are WNL  
 No valvular abnormalities  
 Good LV systolic function present Modified Simpson's method (4C, 2C) (LVEF-53%)  
 No diastolic dysfunction present (E/A = 1.73) by tissue Doppler (E/e'=7.2)  
 No RWMA  
 No pericardial effusion  
 Intact IAS / IV  
 No PAH  
 No intra cardiac mass /thrombus /vegetation

## IMPRESSION

**Normal Echocardiogram**

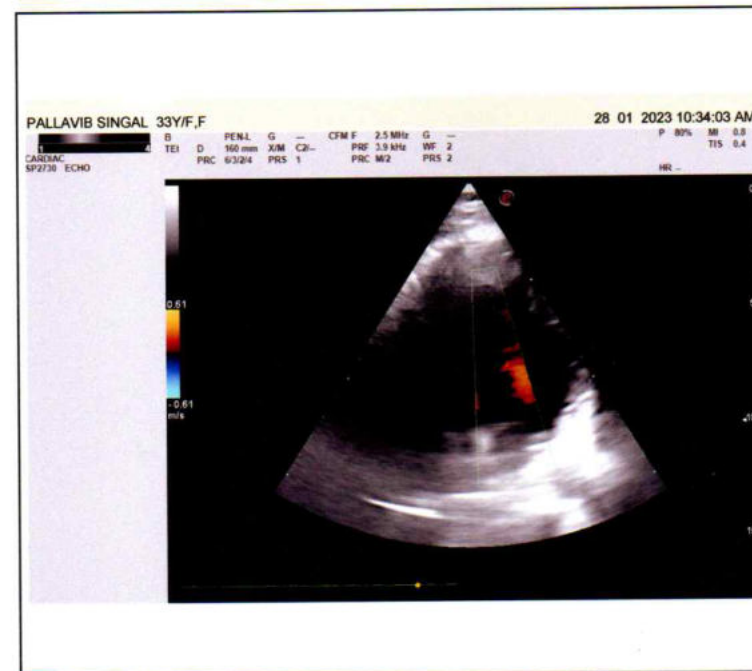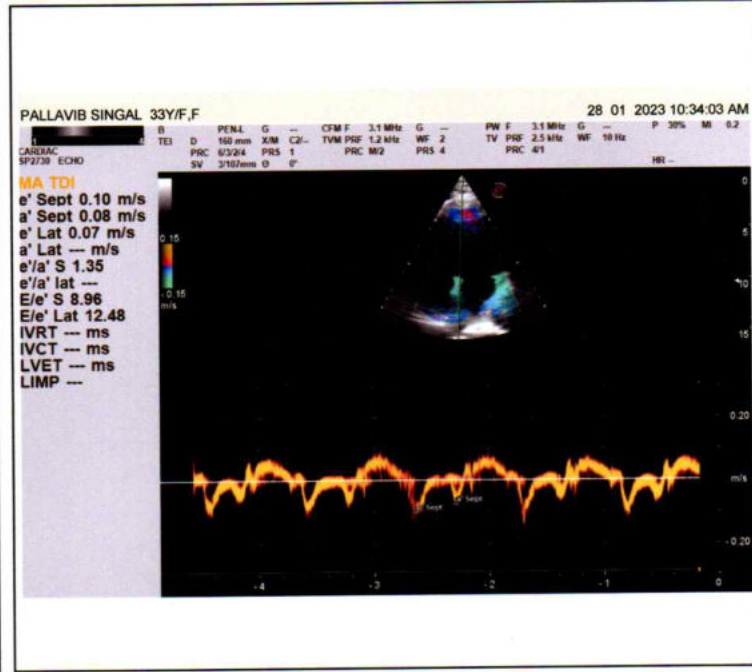
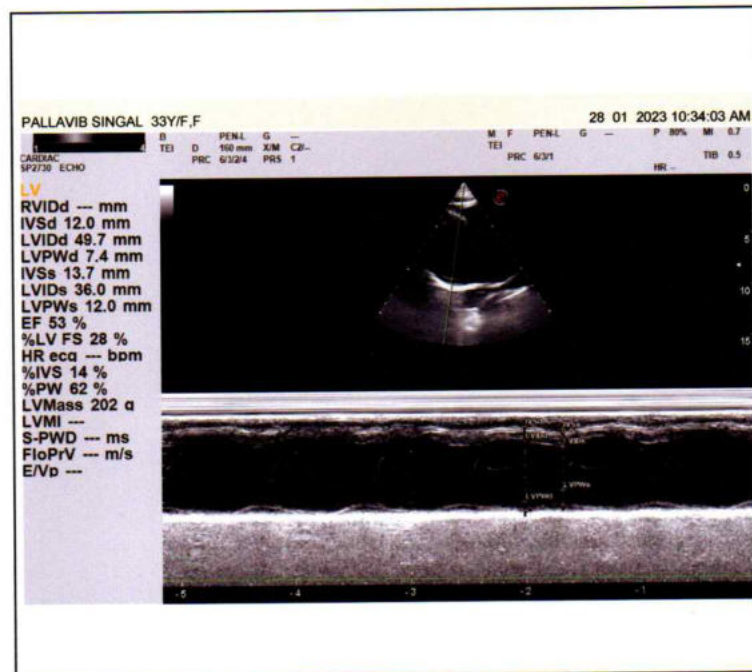
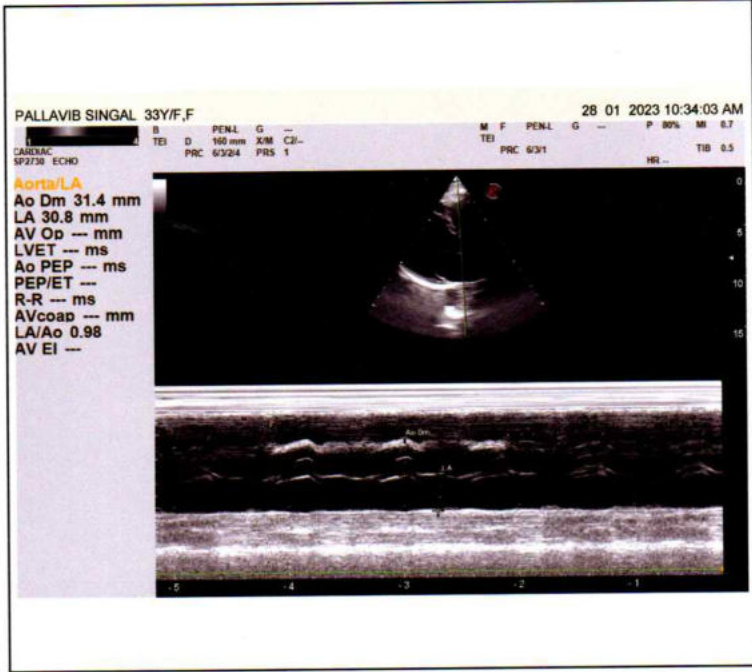
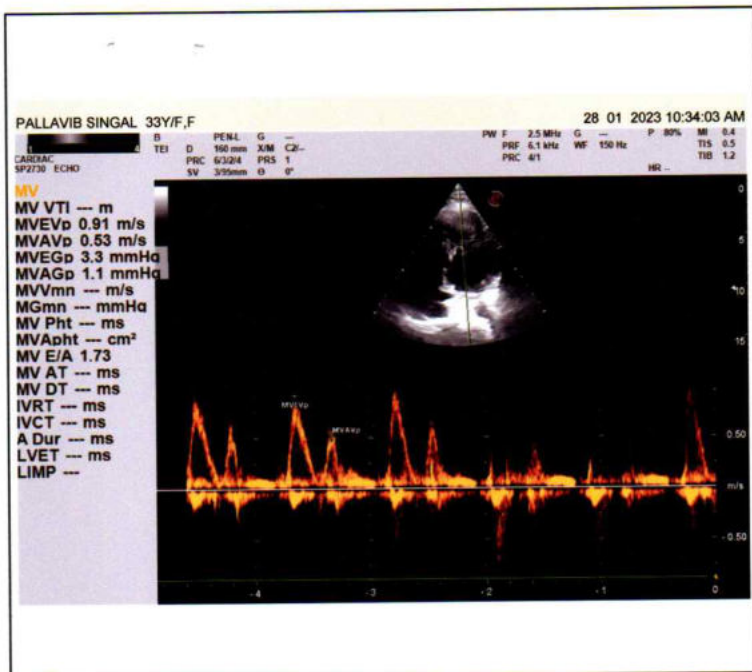
*Niraj Mishra*  
 Niraj Mishra  
 Physician Assistant  
 (PIIRE)

*Pallavi* **DR. PALLAVI MISHRA**  
 MBBS, MD (GENERAL MEDICINE)  
 MCI Reg.No. 52033  
 Dr. Pallavi Mishra  
 MBBS, MD (MED) Lucknow  
 Echocardiography Specialist, MIAE  
 Non-invasive cardiologist  
 Women Cardiologist  
 Diabetocardiologist

Address : Kabir Nagar (Near Sanjay Shiksha Niketan), Durgakund, Varanasi

Mobile : 9554572190 / 9453837595 / Recpn. 9389994334

E-mail : dramishra@gmail.com, drpallaviojha@gmail.com, Website: www.piire.org





# PANACEA HOSPITAL

*A shelter for many hearts A Home for many lives*

(An ISO 9001:2008 Certified Organisation)

Lab Attached with CMC Vellore Under EQAS Scheme

**NAME:** MRS. PALLAVI SINGAL

**AGE/SEX:** 33 YRS / FEMALE

**REF BY:** DR. ASHUTOSH MISHRA (MD)

**DATE:** 28/01/2023

## ULTRA SOUND FOR ABDOMAN REPORT

- Liver:** Normal in shape and size and shows smooth and regular margin.  
No diffuse/focal lesion seen.
- Gall bladder** Contracted shows multiple echogenic foci with posterior acoustic shadowing s/o calculi (largest of them measures 6.4 mm).
- CBD** Visualized part normal in course & caliber.
- Pancreas:** Normal in size, shape & echogenicity.  
Margins are smooth & regular.  
No diffuse/ focal lesion seen. Pancreatic tail obscured.
- Spleen:** **BORDERLINE SPLENOMEGALY** (11.8 cm), shape & echogenicity.  
Margins are smooth & regular. No diffuse / focal lesion seen.  
Splenic vessels at hilum is normal.
- Kidney:** Bilateral kidney normal in size, shape, echogenicity & position.  
Cortical-medullary differentiation is maintained.  
Pelvicalyceal system normal.  
No calculus/mass lesion seen.  
No hydronephrosis/ hydroureter seen.  
No suprarenal mass lesion.

**Address :** Kabir Nagar (Near Sanjay Shiksha Niketan), Durgakund, Varanasi

**Mobile :** 9554572190 / 9453837595 / Recpn. 9389994334

**E-mail :** dramishra@gmail.com, drpallaviojha@gmail.com, **Website:** www.piire.org



# PANACEA HOSPITAL

*A shelter for many hearts A Home for many lives*

(An ISO 9001:2008 Certified Organisation)

Lab Attached with CMC Vellore Under EQAS Scheme

**inary bladder:** Normally distended, wall thickness is normal.  
No echogenic foci lumen or diverticula seen.  
Both VUJ appears normal.  
No E.R. calculus / mass lesion seen.

**Uterus:** **Retroverted** Uterus normal in size shape, & echogenicity.  
Margins are smooth & regular.  
Endometrial thickness within normal limits .

**Ovary:** Right ovary normal in size and shows normal morphology.  
Left ovary normal in size and shows normal morphology.

**Others:** No free fluid in peritoneal cavity.  
No free fluid in bilateral pleural cavity.

#### IMPRESSION:

- **Cholelithiasis**
- **Borderline Splenomegaly**

Please correlate clinically and further investigations.

*Pallavi*  
**DR. PALLAVI MISHRA**  
MBBS MD (GENERAL MEDICINE)  
MCPROG No. 52033

MBBS MD(MED) Lucknow  
Echocardiography specialist, MIAE  
Non invasive cardiologist  
Women cardiologist

*[Signature]*  
Radiologist

**Dr. Tusharika Rai**  
MBBS MS

Note: (1) This report is not valid for medico-legal purposes.  
(2) In case of any discrepancy due typing error, please get it Rectified immediately.

Address : Kabir Nagar (Near Sanjay Shiksha Niketan), Durgakund, Varanasi

Mobile : 9554572190 / 9453837595 / Recpn. 9389994334

E-mail : dramishra@gmail.com, drpallaviojha@gmail.com, Website: www.piire.org







# PANACEA HOSPITAL

*A shelter for many hearts A Home for many lives*

(An ISO 9001:2008 Certified Organisation)

Lab Attached with CMC Vellore Under EQAS Scheme

**NAME:** MRS.PALLAVI SINGAL

**AGE/SEX:** 33 YRS / FEMALE

**REF BY:** DR. ASHUTOSH MISHRA (MD)

**DATE:** 28/01/2023

## X-RAY CHEST PA

### BOTH LUNG FIELDS AND PLEURAE:

Both lungs show normal bronchovascular pattern.

Right & left hila are normal

No focal mass or calcification is seen

There is no evidence of any fluid in the both the pleural cavities.

Both domes of diaphragms are normal in position.

### MEDIASTINUM:

Trachea is central in position.

Cardiac silhouette is of normal size and configuration.

No evidence of pericardial effusion.

No significant lymphadenopathy is seen.

Visualized skeleton is normal.

-----  
NO SIGNIFICANT RADIOGRAPHIC ABNORMALITY.

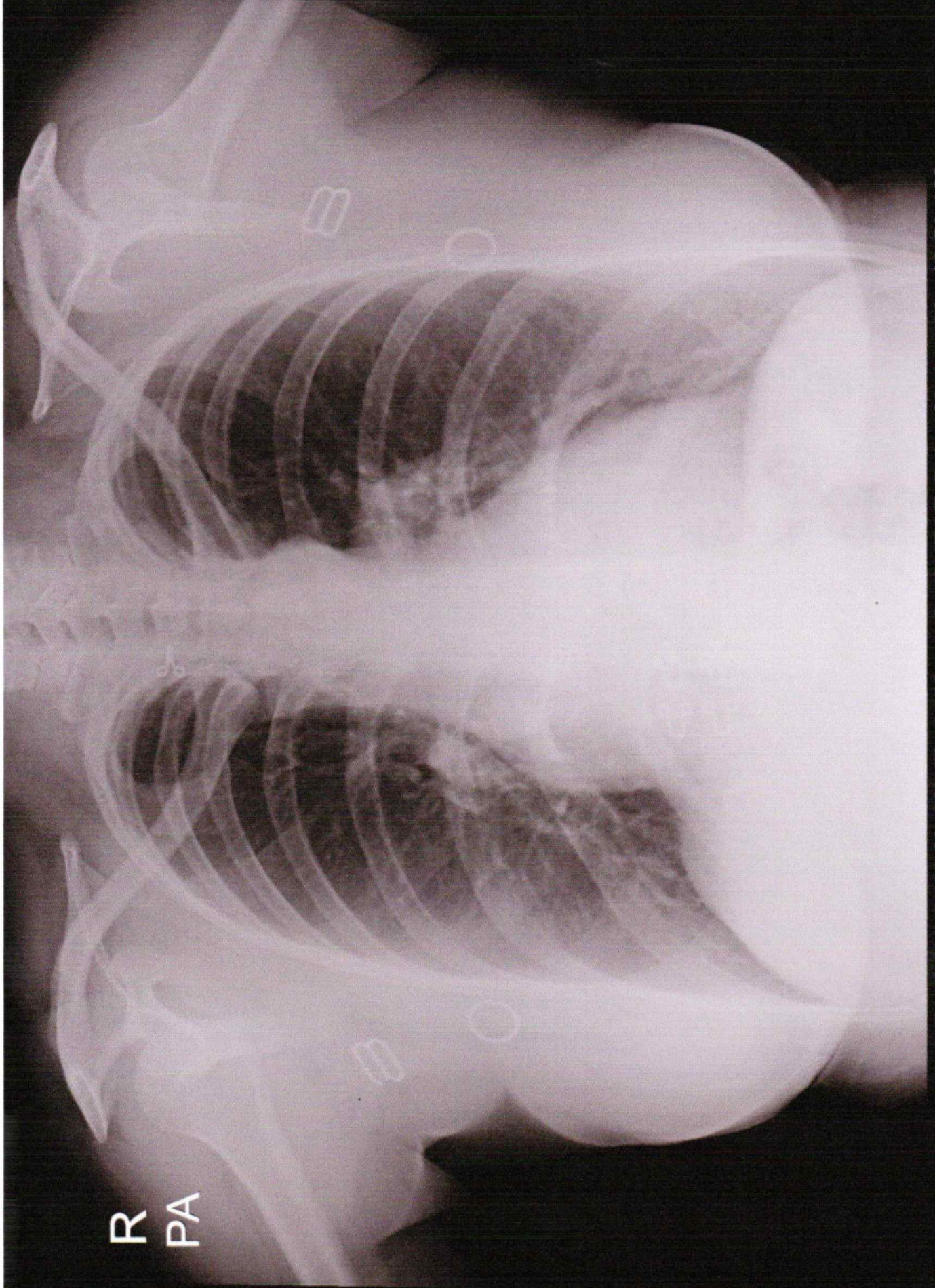
  
Radiologist

**Address :** Kabir Nagar (Near Sanjay Shiksha Niketan), Durgakund, Varanasi

**Mobile :** 9554572190 / 9453837595 / Recpn. 9389994334

**E-mail :** dramishra@gmail.com, drpallaviojha@gmail.com, **Website:** www.piire.org

R  
PA



PALLAVI SINGAL 33Y/F 3440 O CHEST P.A. 28-Jan-23 10:59 AM

PANACEA HOSPITAL KABIR NAGAR DURGAKUND VARANASI