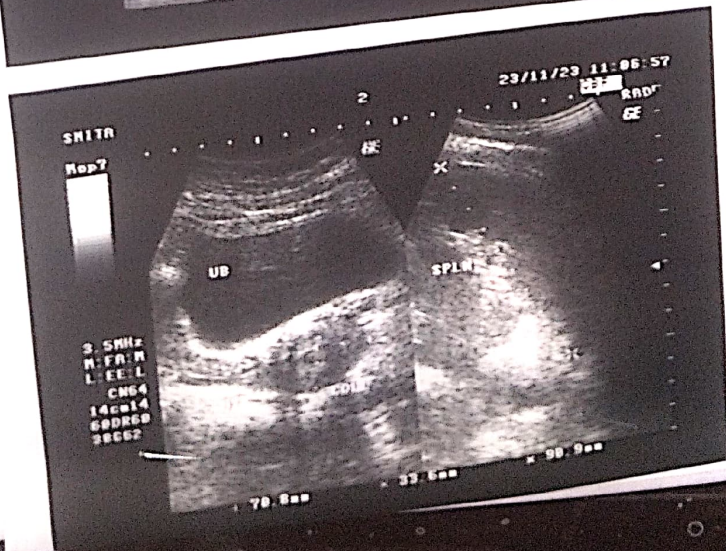
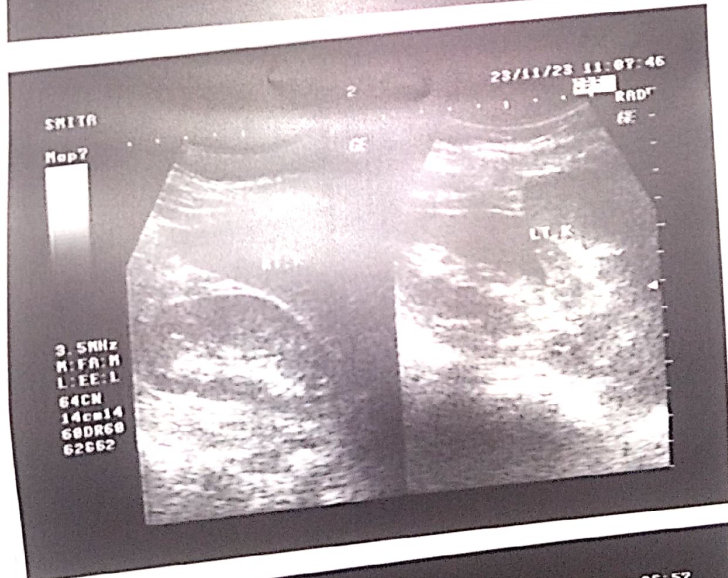
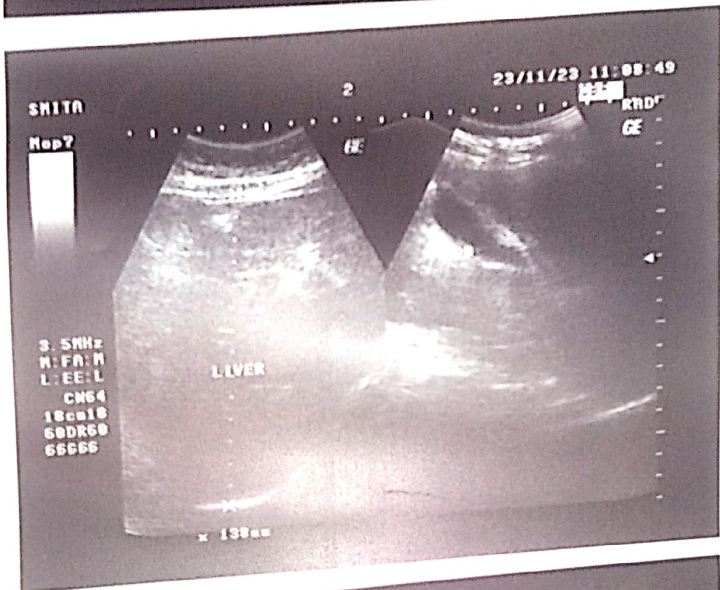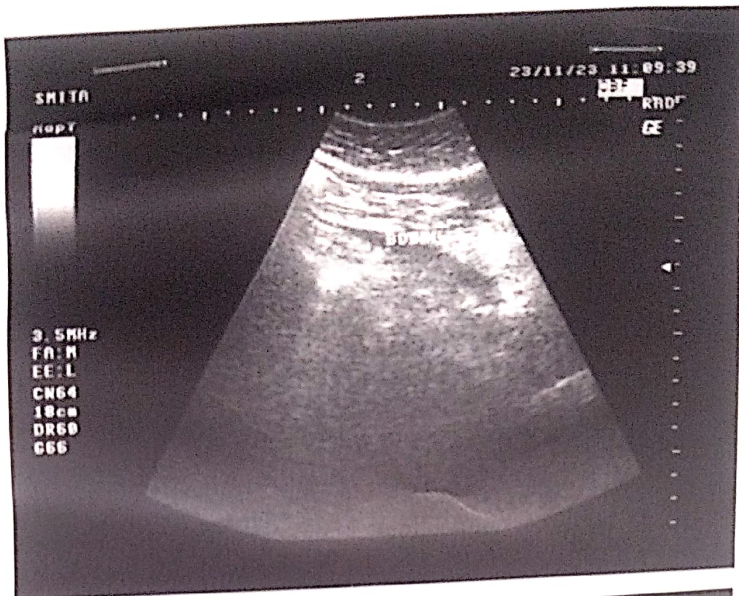SHREE VINAYAK ULTRASOUND CENTRE

COLOR DOPPLER



Reg. No.: 107/2013

Juran Chapra, Near Govt. School
Road No.-4, Muzaffarpur

Dr. A. R. Sinha
M.D. Ph.D.
(Sonologist)

NAME :- SMITA KUMARI
REFD.BY:-DR. SELF


DATE :- 23/11/2023
SEX:- F

Thanks for the kind referral.
USG of Whole Abdomen

- Liver:-** Liver is normal in shape, size [138.0mm] with homogenous coarse echo texture. No focal lesion seen or Intrahepatic ducts dilation seen. Movements of both domes of diaphragm appears normal
- GB:-** Normal distention. Walls are not thickened. No evidence of calculus, sludge, or mass lesion seen.
- C.B.D:-** C.B.D. is normal in calibre.
- Pancreas:-** Pancreas normal in size shape and echotexture.
- Spleen:-** Normal in shape, size & contour. (bipolar length is 98.9mm).
- Kidneys:-** Rt. kidney (88.0 mm) Lt. kidney (90.0 mm)
Both kidneys are normal in shape, size, contour, cortical echo texture, and sinus echoes. No evidence of calculus, calcification, hydronephrotic changes or mass lesion seen.
- UB:-** Urinary bladder is smoothly outlined. There is no calculus within.
- UTERUS:-** Anteverted, anteflexed, normal in shape and size (70.8 x33.6mm) with endometrium are not thickened and normal echotexture.
- ADENEXA:-** Both ovaries seen appears normal & No adenexal lesion seen.
- P.O.D.:-** Mild collection seen.
- Free fluid:-** No free fluid is noted in the peritoneal cavity.
- OTHERS :-** Thickened bowel wall with few fecal gas & less movement of intestine seen.

IMPRESSION :- POD collection.

Thickened bowel wall with few fecal gas & less movement of Intestine seen. s/o. colitis.

(sonologist) 

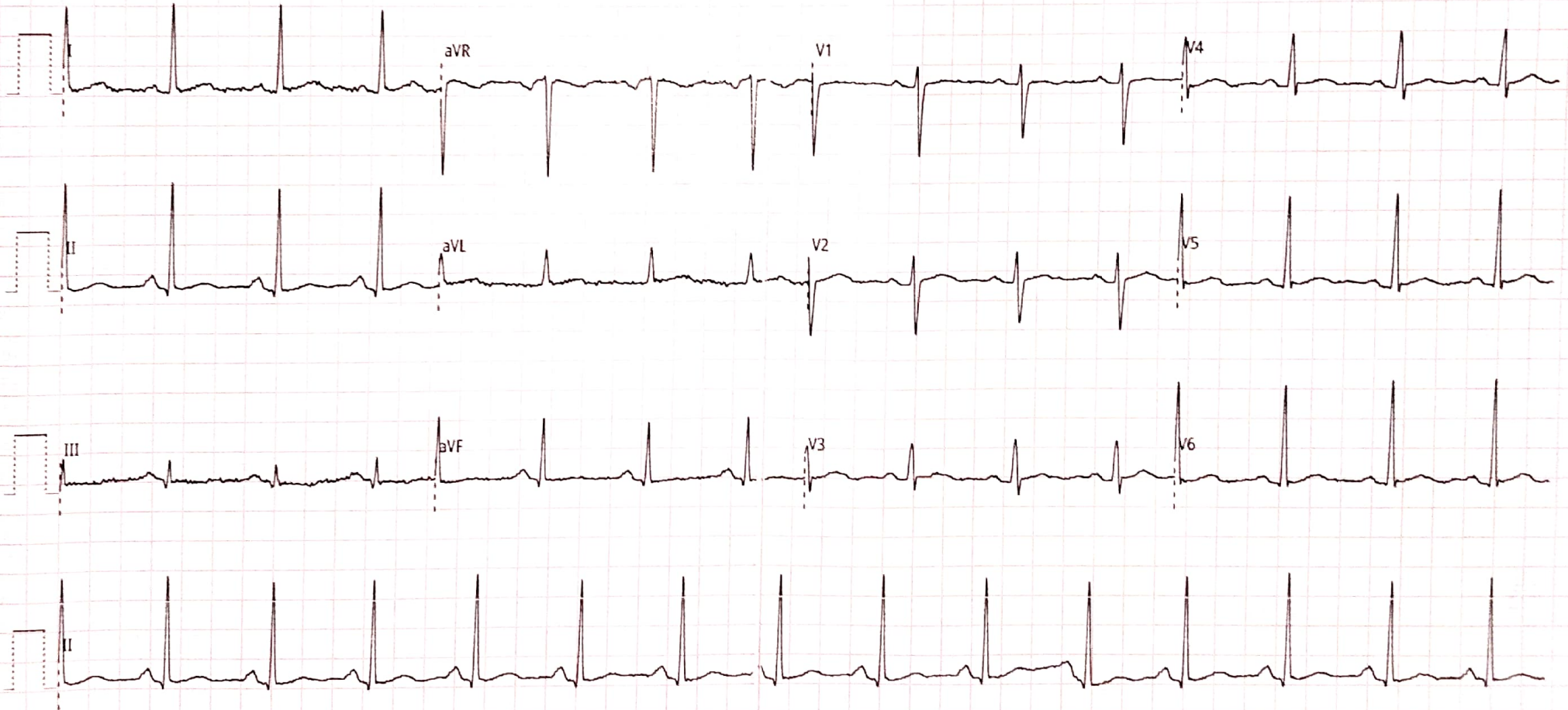
THIS IS PROFESSIONAL OPINION. NOT THE DIAGNOSIS. THIS SHOULD BE CLINICALLY CORRELATED.
NOT FOR MEDICO LEGAL PURPOSES. ALL THE FINDING ARE VALID FOR THE DAY OF SCANNING RADIOLOGICAL
AND IMAGING DIAGNOSIS ALONE ARE NOT ALWAYS CONFIRMATORY AND SHOULD BE CORRELATED WITH CLINICAL
FINDING INCASE OF ANY DOUBT. (SEX DETERMINATION IS NOT DONE HERE)

SUNRISE PATHOLOGY ECG report

ID : 20231122173236 HR : 89 bpm
Name : SMITA KUMARI PR : 150 ms
Gender : F QRS : 74 ms
Age : 38 Years QT/QTc : 340/391 ms
Dept : P/QRS/T : 61/34/12 °
Bed No. : RV5/SV1 : 1.494/1.055 mv
 RV5+SV1: 2.549 mv

<<Interpretations >>
Sinus rhythm
Normal ECG

Confirm and sign:



MEDICAL FITNESS CERTIFICATE

(To be signed by a registered medical practitioner holding a Medical degree)

This is to certify that Mr./Ms*. SMITA KUMARI son/daughter of
Shri _____ of aged 38 years. Based on the examination, I certify
that he/she is in good mental and physical health and is free from any physical
defects such a deafness, colour blindness, and any chronic or contagious diseases.

Signature of the Candidate: _____ .

Place:

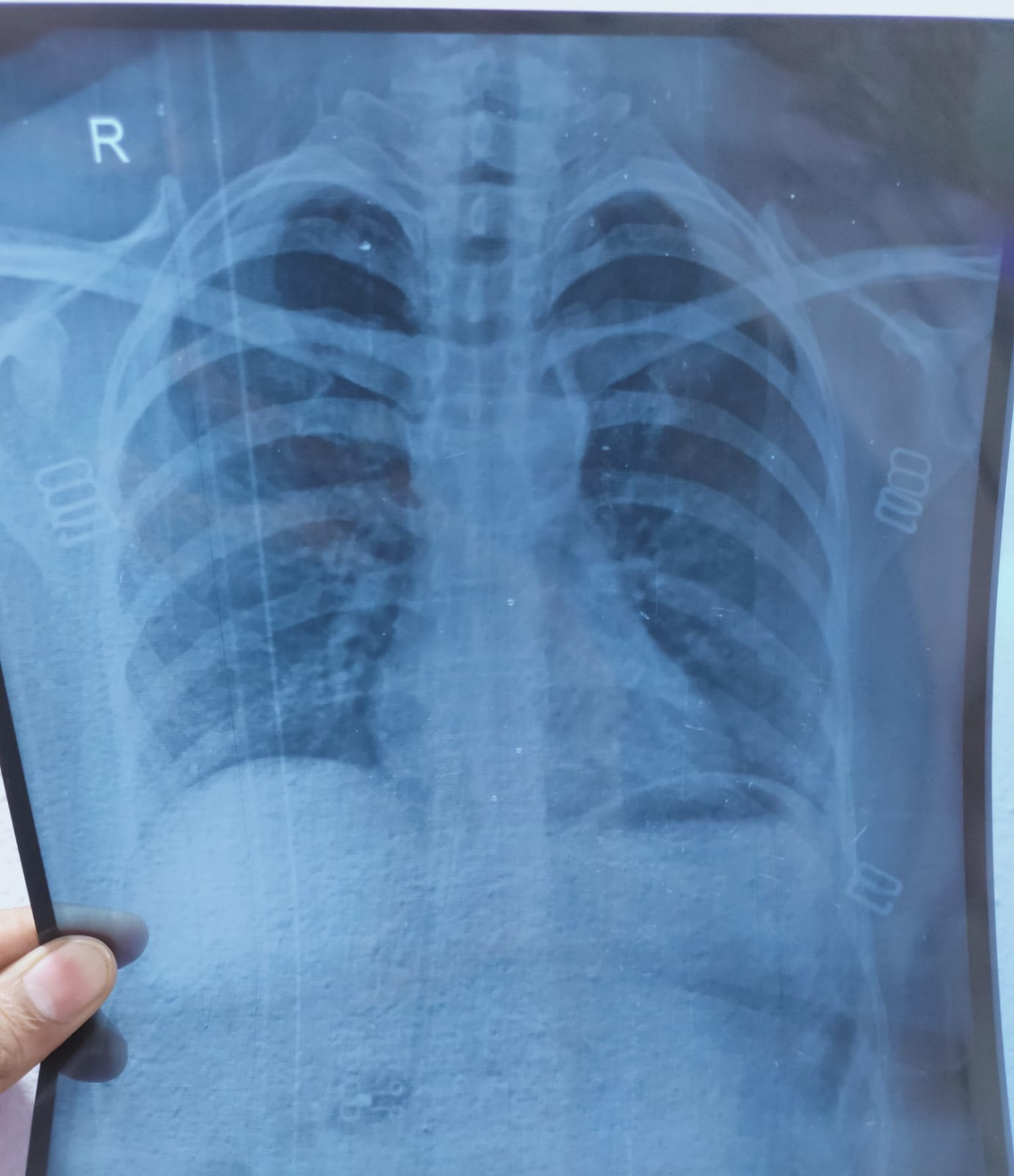
Date:

Dr. MD. Ali Muzffar
M.D. Path.
Reg. No.-34765

Dr.MD.Ali.Muzaffar

MD.Path.
Name & Signature of the Medical Officer





R

000

000

007