



(20/1)

Reg. No.- 815

PARASHAR HOSPITAL

(A Unit of Vijayesh Kumar & Sons Pvt Ltd.)

MURLI MANOHAR COMPLEX, KHADI BHANDAR CHOWK, MUZAFFARPUR-842002 (BIHAR)

Mob.: 6200471018, 7992247583 E-mail: parashar.hospital@gmail.com

Name: - Pooja Rani / Age: - 31/F Date: 24/08/21.....

Add: - Aghoriya Bazaar

C/C: - Carious teeth in the upper right back region

O/E: - Carious wt 4

T/P: - R.C.T wt 4

IOPA wt 4

Rx: -

- Augmentin 625 - bd = 0
 - Zerodol SP - bd = 0
 - Yeas D - od - 0
 - Flagyl 400 - tds = 0
 - BNC - od - 0
 - Chlorhex ASD M/W - Rinse twice daily
- } 5 days.

PATIENT NAME : RANI POOJA
 AGE/SEX : 0Y/Adult-F
 REF. BY DR. : DR. PARASAR HOSPITAL
 RPT. DATE : 23/08/2021
 TEST. DATE : 23/08/2021
 REFF. NO : 23/08/21CP/50
 UNIT

HAEMATOLOGY

CBC (COMPLETE BLOOD COUNT)

RBC (Red Blood Cells) 3.74 3.8-6.5 M/uL
 Hb (Haemoglobin) 10.6 11-14.8 gm/dl
 HCT (Haematocrit) 30.8 37-54 %
 MCV 82.3 76-96 fL
 MCH 28.3 27-32 pg
 MCHC 34.4 31-36 gm%
 TC of WBC 4,200 4500-10500 /cumm
 DC of WBC

Neutrophil (seg)

58 50 - 70 %
 Lymphocyte 37 20 - 40 %
 Eosinophil 04 1 - 6 %
 Monocyte 01 2 - 8 %
 Basophil 00 0 - 1 %
 Platelets 1.77 1.5-3.5 Lakh/cumm
 Red Cell Distribution Width (RDW) 13.1 11.5-14.5 fL
 ESR (DONE BY AUTO ANALYZER) 36 0-20 mm/hr

Blood Group

ABORH

"B" POSITIVE

BIOCHEMISTRY

Plasma Glucose (Fasting) 79 70-110 mg/dl
 Plasma Glucose (Post Prandial) 118 100-140 mg/dl
 Serum Total Cholesterol 132 50-230 mg/dl
 Serum HDL Cholesterol Direct 39 30-65 mg/dl

Dr.Sima Kumari

Ph.D (Micro)
 M.Sc (Micro)
 Ex. Project Trainee
 AIIMS New Delhi (Lab Medicine Dept.)

Dr.R.K. Narayan

M.D.(Path.)
 Regd.No.14962

PATIENT NAME :RANI POOJA
AGE/SEX :0Y/Adult-F
REF. BY DR. :DR. PARASAR HOSPITAL

REF. NO :23/08/21CP/50
TEST. DATE :23/08/2021
RPT. DATE :23/08/2021

INVESTIGATIONS	VALUE	REF. RANGE	UNIT
Serum Triglycerides	78	25-200	mg/dl
Serum LDL Cholesterol	77.40	85-130	mg/dl
Serum VLDL Cholesterol	15.60	7-32	mg/dl
TC/HDL Cholesterol Ratio	3.38	3.0-5.0	Ratio
LDL/HDL Ratio	1.98:1	1.5-3.5	Ratio
LIVER PROFILE			
Serum Bilirubin			
Total	0.6	0.1-1.2	mg%
Direct	0.3	0-0.3	mg%
Indirect	0.30	0-0.6	mg%
Serum SGPT (ALAT)	22	9-38	IU/L
Serum SGOT (ASAT)	18	10-40	IU/L
Alkaline Phosphatase	172	64-306	U/L
Total Protien			
Protein	7.4	6.0-8.0	g/dl
Albumin	4.1	3.7-5.3	g/dl
Globulin	3.30	2.3-3.6	g/dl
A:G Ratio	1.24:1	1.0-2.3	Ratio
Gamma Glutamyl transferase (GGT)	26	9-58	U/L
RENAL FUNCTION TEST (RFT)			
Serum Creatinine	0.7	0.6-1.4	mg/dl
Blood Urea Nitrogen (Bun)	10.74	7-21	mg/dl
Serum Uric Acid	4.5	2.5-6.8	mg/dl
Serum Calcium (Total)	9.2	8.7-11.0	mg/dl
Blood Urea	23	13-45	mg/dl


Dr. Sima Kumari

Ph.D (Micro)
M.Sc. (Micro)
Ex. Project Trainee
AIIMS New Delhi (Lab. Medicine Dept.)


Dr. R.K. Narayan

M.D. (Path.)
Regd. No. 14962

PATIENT NAME : RANI POOJA
AGE/SEX : 0Y/Adult-F
REF. BY DR. : DR. PARASAR HOSPITAL

REF. NO : 23/08/21CP/50
TEST. DATE : 23/08/2021
RPT. DATE : 23/08/2021

INVESTIGATIONS	VALUE	REF. RANGE	UNIT
SERUM ELECTROLYTE			
Sodium (Na)+	141.0	135-150	m mol/L
Potassium (K)+	4.0	3.5-5.1	m mol/L
Chloride (Cl)-	104.5	97-111	m mol/L


Dr. Sima Kumari

Ph.D (Micro)
M.Sc. (Micro)
Ex. Project Trainee
AIIMS New Delhi (Lab. Medicine Dept.)


Dr. R.K. Narayan

M.D. (Path.)
Regd. No. 14962

PATIENT NAME : RANI POOJA

REF. NO : 23/08/21CP/50

AGE/SEX : 0Y/Adult-F

TEST. DATE : 23/08/2021

REF. BY DR. : DR. PARASAR HOSPITAL

RPT. DATE : 23/08/2021

INVESTIGATIONS

VALUE

REF. RANGE

UNIT

BIOCHEMISTRY

HbA1c

5.6

4.2-6.0

Good Diabetic Control 5.5 - 6.8 Fair Control 6.8 - 7.6 Poor Control Above 7.6


Dr. Sima Kumari

Ph.D (Micro)

M.Sc. (Micro)

Ex. Project Trainee

AIIMS New Delhi (Lab. Medicine Dept.)


Dr. R.K. Narayan

M.D. (Path.)

Regd No. 14962

PATIENT NAME : RANI POOJA
AGE/SEX : 0Y/Adult-F
REF. BY DR. : DR. PARASAR HOSPITAL

REF. NO : 23/08/21CP/50
TEST. DATE : 23/08/2021
RPT. DATE : 23/08/2021

INVESTIGATIONS	VALUE	REF. RANGE	UNIT
----------------	-------	------------	------

URINE ROUTINE

Physical Examination

Colour : Pale Straw
Appearance : Clear

Chemical Examination

PH : Acidic
Specific Gravity : 1.025
Sugar : Negative
Albumin : Negative

Microscopic Examination

Crystal : Nil
RBC : Nil
WBC : 60-70/HPF
Epithelial Cells : A Few
Granular Cast : Absent
Bacteria : Absent
Cast : Absent
Other : NIL



Dr. Sima Kumari

Ph.D (Micro)

M.Sc. (Micro)

Ex. Project Trainee

AIIMS New Delhi (Lab. Medicine Dept.)



Dr. R.K. Narayan

M.D. (Path.)

Regd. No. 14962



PARASHAR HOSPITAL

(A Unit of Vijayesh Kumar & Sons Pvt Ltd.)

MURLI MANOHAR COMPLEX, KHADI BHANDAR CHOWK, MUZAFFARPUR-842002 (BIHAR)

Mob.: 6200471018, 7992247583 E-mail : parashar.hospital@gmail.com

Date : 29/08/2021

Soft Rami Roops
B1/E

BSP - 110/70

Go = RHC, knee joint pain

O/E - H/R - N
chest - clear
Lir - V

By Calcium K₂ - 30
12hr

2 Calcium Sachet
1 Sachet bid -
H/R 1/1/1/1/1/1
200 of 200
2 sachet
D



PARASHAR HOSPITAL

(A Unit of Vijayesh Kumar & Sons Pvt Ltd.)

MURLI MANOHAR COMPLEX, KHADI BHANDAR CHOWK, MUZAFFARPUR-842002 (BIHAR)

Mob.: 6200471018, 7992247583 E-mail : parashar.hospital@gmail.com

Date :

PATIENT NAME : RANI POOJA
 AGE/SEX : 0Y/Adult-F.
 REF. BY DR. : DR. PARASAR HOSPITAL

REF. NO : 23/08/21CP/50
 TEST. DATE : 23/08/2021
 RPT. DATE : 23/08/2021

INVESTIGATIONS	VALUE	REF. RANGE	UNIT
----------------	-------	------------	------

HAEMATOTOLOGY

CBC (COMPLETE BLOOD COUNT)			
RBC (Red Blood Cells)	3.74	3.9-6.5	M/uL
Hb (Haemoglobin)	10.6	11-14.8	gm/dl
HCT (Haematocrit)	30.8	37-54	%
MCV	82.3	76-96	fL
MCH	28.3	27-32	pL
MCHC	34.4	31-36	gm%
TC of WBC	4,200	4500-10500	/cumm
DC of WBC			
Neutrophil (seg)	58	50 - 70	%
Lymphocyte	37	20 - 40	%
Eosinophil	04	1 - 6	%
Monocyte	01	2 - 8	%
Basophil	00	0 - 1	%
Platelets	1.77	1.5-3.5	lakh/cumm
Red Cell Distribution Width (RDW)	13.1	11.5-14.5	fL
ESR (DONE BY AUTO ANALYZER)	36	0-20	mm/hr

IMMUNOLOGY


Blood Group

ABORH

"B" POSITIVE

BIOCHEMISTRY

Plasma Glucose (Fasting)	79	70-110	mg/dl
Plasma Glucose (Post Prandial)	118	100-140	mg/dl
LIPID PROFILE			
Serum Total Cholesterol	132	50-230	mg/dl
Serum HDL Cholesterol Direct	39	30-65	mg/dl



 Dr. Sima Kumari

Ph.D (Micro)

M.Sc. (Micro)

Ex. Project Trainee

AIIMS New Delhi (Lab. Medicine Dept.)


 Dr. R.K. Narayan

M.D. (Path.)

Regd. No. 14962



PARASHAR HOSPITAL

(A Unit of Vijayesh Kumar & Sons Pvt Ltd.)

MURLI MANOHAR COMPLEX, KHADI BHANDAR CHOWK, MUZAFFARPUR-842002 (BIHAR)

Mob.: 6200471018, 7992247583


E-mail : parashar.hospital@gmail.com

Date :

PATIENT NAME : RANI POOJA
AGE/SEX : 0Y/Adult-F
REF. BY DR. : DR. PARASAR HOSPITAL

REF. NO : 23/08/21CP/50
TEST. DATE : 23/08/2021
RPT. DATE : 23/08/2021

INVESTIGATIONS	VALUE	REF. RANGE	UNIT
Serum Triglycerides	78	25-200	mg/dl
Serum LDL Cholesterol	77.40	95-130	mg/dl
Serum VLDL Cholesterol	15.60	7-32	mg/dl
TC/HDL Cholesterol Ratio	3.38	3.0-5.0	Ratio
LDL/HDL Ratio	1.98:1	1.5-3.5	Ratio
LIVER PROFILE			
Serum Bilirubin			
Total	0.6	0.1-1.2	mg%
Direct	0.3	0-0.3	mg%
Indirect	0.30	0-0.6	mg%
Serum SGPT (ALAT)	22	9-38	IU/L
Serum SGOT (ASAT)	18	10-40	IU/L
Alkaline Phosphatase	172	64-306	U/L
Total Protien			
Protein	7.4	6.0-8.0	g/dl
Albumin	4.1	3.7-5.3	g/dl
Globulin	3.30	2.3-3.6	g/dl
A:G Ratio	1.24:1	1.0-2.3	Ratio
Gamma Glutamyl transferase (GGT)	26	9-58	U/L
RENAL FUNCTION TEST (RFT)			
Serum Creatinine	0.7	0.6-1.4	mg/dl
Blood Urea Nitrogen (Bun)	10.74	7-21	mg/dl
Serum Uric Acid	4.5	2.5-6.8	mg/dl
Serum Calcium (Total)	9.2	8.7-11.0	mg/dl
Blood Urea	23	13-45	mg/dl



Dr. Sima Kumari

Ph.D (Micro)

M.Sc. (Micro)

Ex. Project Trainee

AIIMS New Delhi (Lab. Medicine Dept.)


Dr. R.K. Narayan

M.D. (Path)

Regd. No. 14962



PARASHAR HOSPITAL

(A Unit of Vijayesh Kumar & Sons Pvt Ltd.)

MURLI MANOHAR COMPLEX, KHADI BHANDAR CHOWK, MUZAFFARPUR-842002 (BIHAR)


Mob.: 6200471018,7992247583 E-mail : parashar.hospital@gmail.com

Date :

PATIENT NAME : RANI POOJA
 AGE/SEX : 0Y/Adult-F
 REF. BY DR. : DR. PARASAR HOSPITAL

REF. NO : 23/08/21CP/50
 TEST. DATE : 23/08/2021
 RPT. DATE : 23/08/2021

INVESTIGATIONS	VALUE	REF. RANGE	UNIT
SERUM ELECTROLYTE			
Sodium (Na)+	141.0	135-150	m mol/L
Potassium (K)+	4.0	3.5-5.1	m mol/L
Chloride (Cl)-	104.5	97-111	m mol/L



Dr. Sima Kumari

Ph.D (Micro)

M.Sc. (Micro)

Ex. Project Trainee

AIIMS New Delhi (Lab. Medicine Dept.)


Dr. R.K. Narayan

M.D. (Path.)

Regd. No. 14962



PARASHAR HOSPITAL

(A Unit of Vijayesh Kumar & Sons Pvt Ltd.)

MURLI MANOHAR COMPLEX, KHADI BHANDAR CHOWK, MUZAFFARPUR-842002 (BIHAR)

Mob.: 6200471018, 7992247583 E-mail : parashar.hospital@gmail.com

Date :

PATIENT NAME : RANI POOJA

REF. NO : 23/08/21CP/50

AGE/SEX : 0Y/Adult-F

TEST . DATE : 23/08/2021

REF. BY DR. : DR. PARASAR HOSPITAL

RPT. DATE : 23/08/2021

INVESTIGATIONS	VALUE	REF. RANGE	UNIT
----------------	-------	------------	------

URINE ROUTINE

Physical Examination

Colour Pale Straw

Appearance Clear

Chemical Examination

PH Acidic

Specific Gravity 1.025

Sugar Negative

Albumin Negative

Microscopic Examination

Crystal Nil

RBC Nil

WBC 60-70/HPF


Epithelial Cells A Few

Granular Cast Absent

Bacteria Absent

Cast Absent

Other NIL


Dr. Sima Kumari

Ph.D (Micro)

M.Sc (Micro)

Ex. Project Trainee

AIIMS New Delhi (Lab. Medicine Dept.)


Dr. R.K. Narayan

M.D. (Path.)

Regd. No. 14962



PARASHAR HOSPITAL

(A Unit of Vijayesh Kumar & Sons Pvt Ltd.)

MURLI MANOHAR COMPLEX, KHADI BHANDAR CHOWK, MUZAFFARPUR-842002 (BIHAR)


Mob.: 6200471018, 7992247583 E-mail : parashar.hospital@gmail.com

Date :

PATIENT NAME	: RANI POOJA	REF. NO	: 23/08/21CP/50
AGE/SEX	: 0Y/Adult-F	TEST. DATE	: 23/08/2021
REF. BY DR.	: DR. PARASAR HOSPITAL	RPT. DATE	: 23/08/2021
INVESTIGATIONS	VALUE	REF. RANGE	UNIT

BIOCHEMISTRY

HbA1c 5.6 4.2-6.0
 Good Diabetic Control 5.5 - 6.8 Fair Control 6.8 - 7.6 Poor Control Above 7.6


Dr. Sima Kumari

Ph.D (Micro)

M.Sc. (Micro)

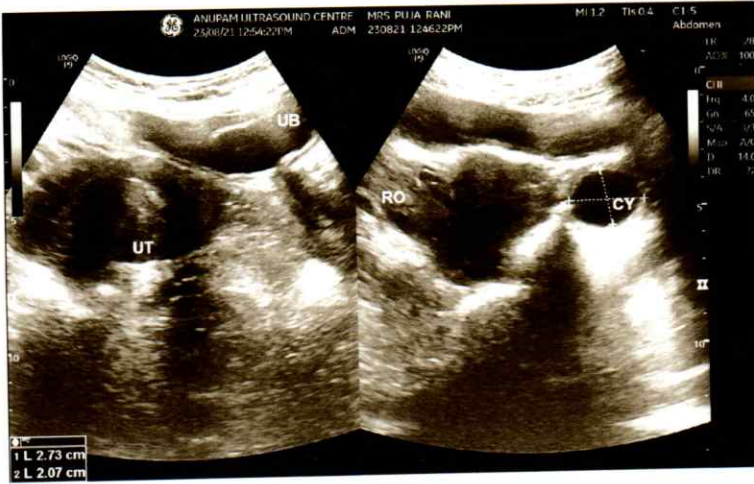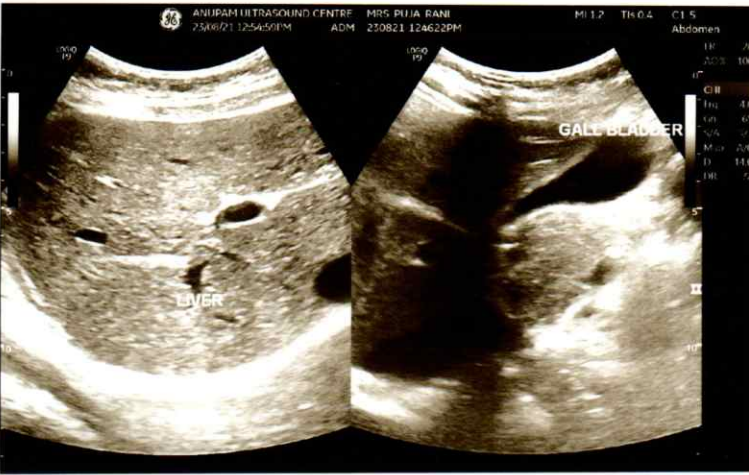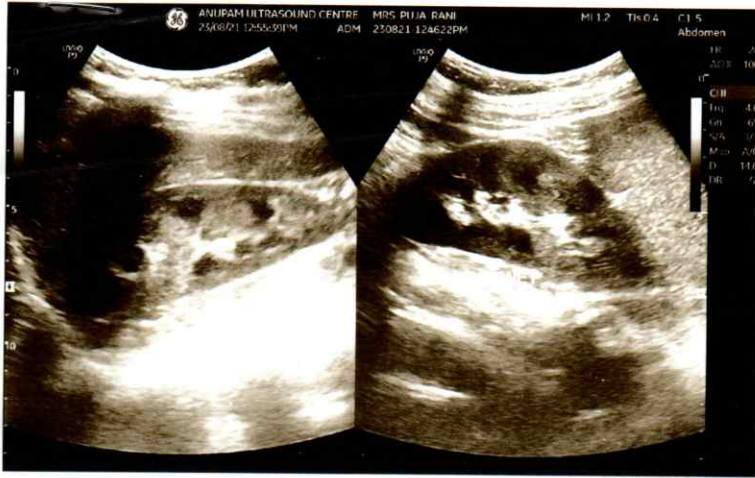Ex. Project Trainee

AIIMS New Delhi (Lab. Medicine Dept.)


Dr. R.K. Narayan

M.D. (Path.)

Regd. No. 14962



PAM

SOUND & COLOR DOPPLER CENTRE

1, JURAN CHAPRA, MUZAFFARPUR - 842 001
 - 2224133, 9525971756, E-mail : anupct1@gmail.com

Dr. A. K. Shah
 PGDM (Sonologist)

U/S Reg. No- 07/2001

Reg. No- BMR- 16156

Age/ Sex : Y/F
 ID No - : 406
 Date/ Time : 23.08.2021

ABDOMEN REPORT

parenchymal echotexture. There is no focal lesion or
 stones, portal vein is normal.

thickness and echofree lumen.

and echotexture.

pathy seen.

shape & position. The C.M. differentiation is well
 defined and cast shadow.

lesion.

seen. There is no calculus within.

is normal and normal in echotexture.

No collection or mass seen in RIF.

OPINION: Left Ovarian Cyst (Size- 27 x 20mm)

On request
 Not valid for medico-legal purpose

(Handwritten Signature)
 Sonologist



Thanks for referral

ANUPAM

ULTRASOUND & COLOR DOPPLER CENTRE

ROAD NO. 1, JURAN CHAPRA, MUZAFFARPUR - 842 001

Phones : 0621 - 2224133, 9525971756, E-mail : anupct1@gmail.com

Dr. Ajay Jaiswal
MBBS, MRSH

Dr. A. K. Shrivastava
PGDM (Sonology)

U/S Reg. No- 07/2001

Reg. No- BMR- 16156

Name : Mrs. Rani Puja
Part scanned : Whole Abdomen
Refd. by Dr. : Parashar Hospital
Muz.

Age/ Sex : Y/F
ID No - : 406
Date/ Time : 23.08.2021

USG OF WHOLE ABDOMEN REPORT

Liver is normal in size with uniform parenchymal echotexture. There is no focal lesion or dilatation of intrahepatic biliary radicles, portal vein is normal.

Gall bladder shows normal wall thickness and echofree lumen. C.B.D. is normal in caliber.

Pancreas is normal in size, shape and echotexture. Spleen is normal in size .

There is no abdominal lymphadenopathy seen.

Both kidneys are normal in size, shape & position. The C.M. differentiation is well maintained .There is no hydronephrosis and cast shadow.

No evidence of ascites/ pleural effusion.

Urinary bladder is smooth in outlined. There is no calculus within.

Uterus is retroverted, normal in size and normal in echotexture.

Right ovary is normal in size.

Left ovary shows cyst (27 x 20mm)

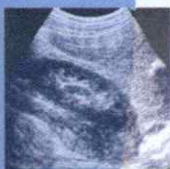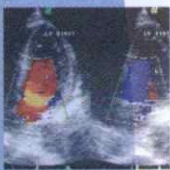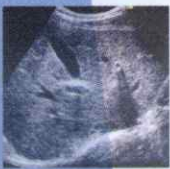No collection or mass seen in RIF.

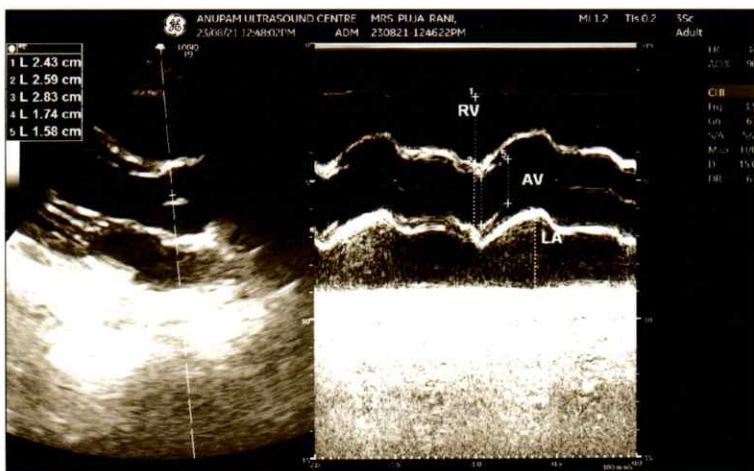
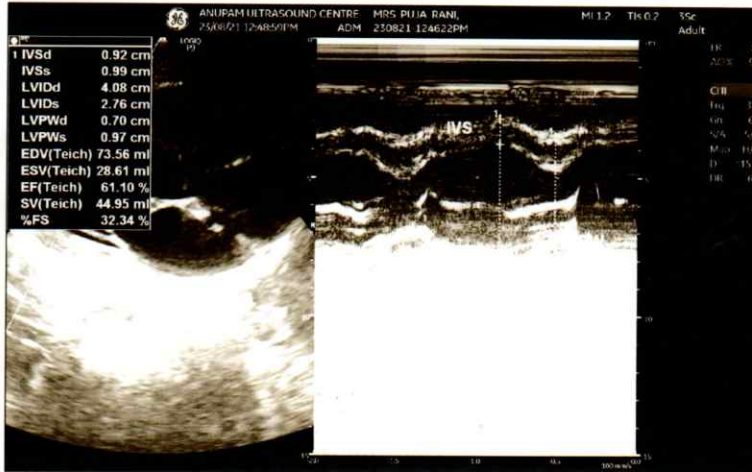
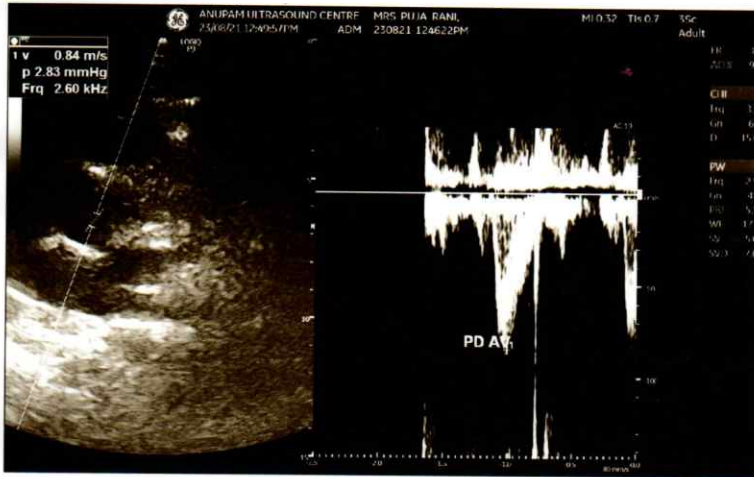
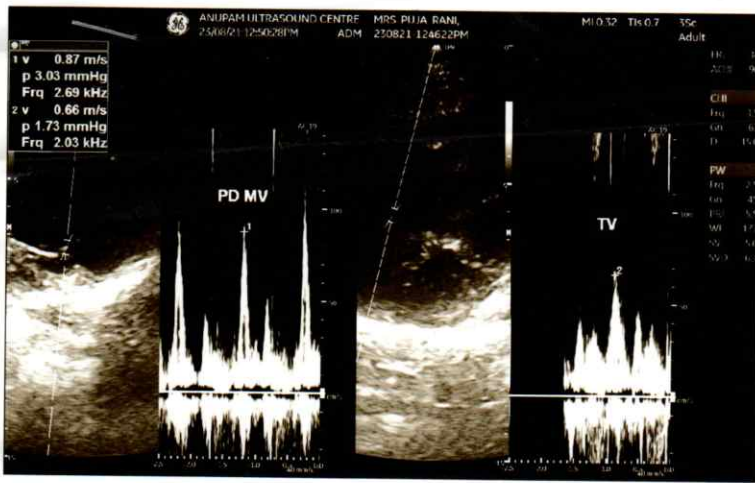
OPINION: Left Ovarian Cyst (Size- 27 x 20mm)


Sonologist

On request

Not valid for medico-legal purpose.





ANUPAM

SOUND & COLOR DOPPLER CENTRE

No. 1, JURAN CHAPRA, MUZAFFARPUR - 842 001
- 2224133, 9525971756, E-mail : anupct1@gmail.com

Dr. A. K. Sha

PGDM (Sonology)

Reg. No- 07/2001

Reg. No- BMR- 16156

Age/ Sex : Y/F
 ID No - : 405
 Date - : 23.08.2021

Age/ Sex : Y/F

ID No - : 405

Date - : 23.08.2021

DIAGRAM REPORT

in parasternal long and short axis, apical and

There is no aortic regurgitation. The aorta diameter is 2.59cm. Aortic valve opening dimension 1.74cm. Doppler velocity of aortic valve is 0.84m/sec. There is no mitral regurgitation, the velocity of mitral leaflets excursion is 0.87m/sec).

There is no tricuspid regurgitation. The doppler velocity of tricuspid valve is 0.66m/sec.

IVS thickness dimension is 2.83 cm. There is no atrial septal defect.

Dimension of L.V.C is 2.76cm at the end of diastole.

EF is 61.10%. Right atrium is normal.

There are no pericardial effusions seen at rest.

None seen.

Diastole S early diastole-E and Late diastole A wave are normal.

IVSs - 2.83cm, LVIDd - 4.08cm, LVPWd - 0.70cm, IVSs - 2.83cm, LVIDs - 2.76cm, LVPWs - 0.97cm, EDV - 73.56ml, ESV - 28.61ml, EF - 61.10%.

(Signature)
Sonologist

ANUPAM

ULTRASOUND & COLOR DOPPLER CENTRE

ROAD NO. 1, JURAN CHAPRA, MUZAFFARPUR - 842 001

Phones : 0621 - 2224133, 9525971756, E-mail : anupct1@gmail.com

Dr. Ajay Jaiswal
MBBS, MRSH

Dr. A. K. Shah
PGDM (Sonologis



Thanks for referral

U/S Reg. No- 07/2001

Reg. No- BMR- 16156

Name	: Mrs. Rani Puja	Age/ Sex	: Y/F
Part scanned	: Echocardiography	ID No -	: 405
Refd. by Dr.	: Parashar Hospital Muz.	Date -	: 23.08.2021

ECHOCARDIOGRAM REPORT

2D echo / color doppler studies done in parasternal long and short axis, apical and subcostal view.

The aortic valves appears normal. There is no aortic regurgitation. The aorta appears normal and its dimension is 2.59cm. Aortic valve opening dimension 1.74cm in begning and 1.58 cm at end. The doppler velocity of aortic valve is 0.84m/sec. The mitral valves appears normal . There is no mitral regurgitation, the velocity of mitral valve is 0.87m/sec and valve leaflets excursion (D - DE -1.65cm, and V -EF - 0.15m/sec).

Tricuspid valves are normal. There is no tricuspid regurgitation. The doppler velocity of TV is 0.66m/sec.

Pulmonary valve is normal.

The left atrium appears normal and its dimension is 2.83 cm. There is no atrial fibrillation seen.

Left ventricle is normal and the dimation of L.V.C is 2.76cm at the end of diastole . Left ventricular E/F at rest is about 61%.

Right ventricle is normal and its dimation is 2.43 cm. Right atrium is normal . No VSD or ASD seen .

No segemental wall motion abnormality are seen at rest .

There is no intracardiac thrombi or clot seen .

There is no pericardial effusion seen.

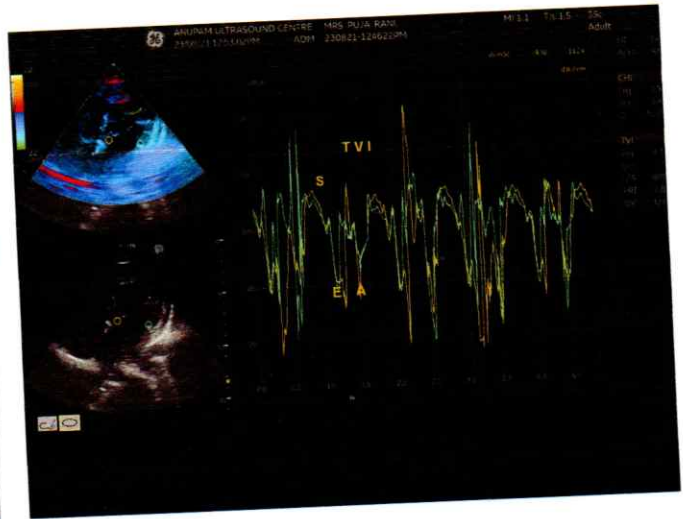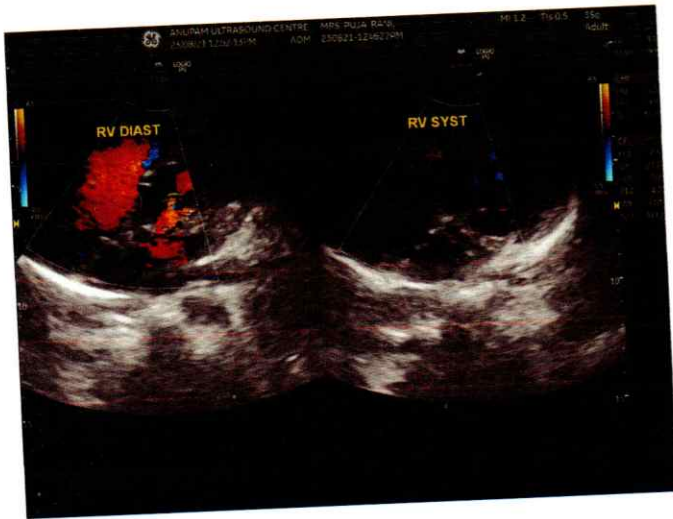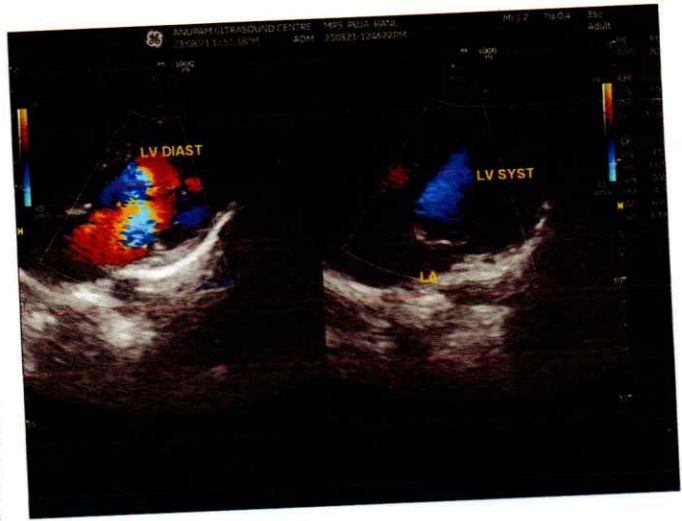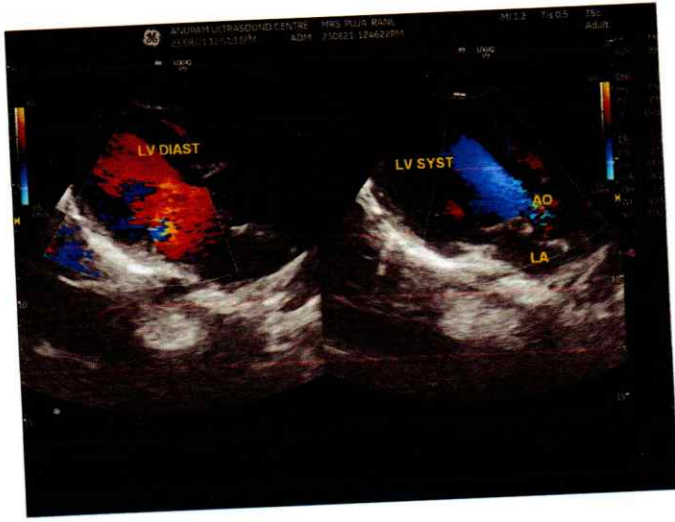
On TVI the mean velocity of early systole S early diastole E and Late diastole A wave at basal ant and basal lat wall appears normal

M mode measurement : IVSD -0.92cm, LVIDd - 4.08cm, LVPWd - 0.70cm, IVSs - 0.99cm, LVIDs - 2.76cm, LVPWs -0.97cm, EDV- 73.56ml, SV - 44.95ml, ESV-28.61ml, EF - 61.10%.

OPINION - Normal Study


Sonologist

ANUPAM ULTRASOUND CENTRE
ROAD NO. 1, JURAN CHAPRA, MUZAFFARPUR -842001



2021-08-19 12H:20M

ID: 20210819122019

Name: Rani, Pooja

Age: 30

Sex: Female

Hospital:

Department:

(Analysis Result)

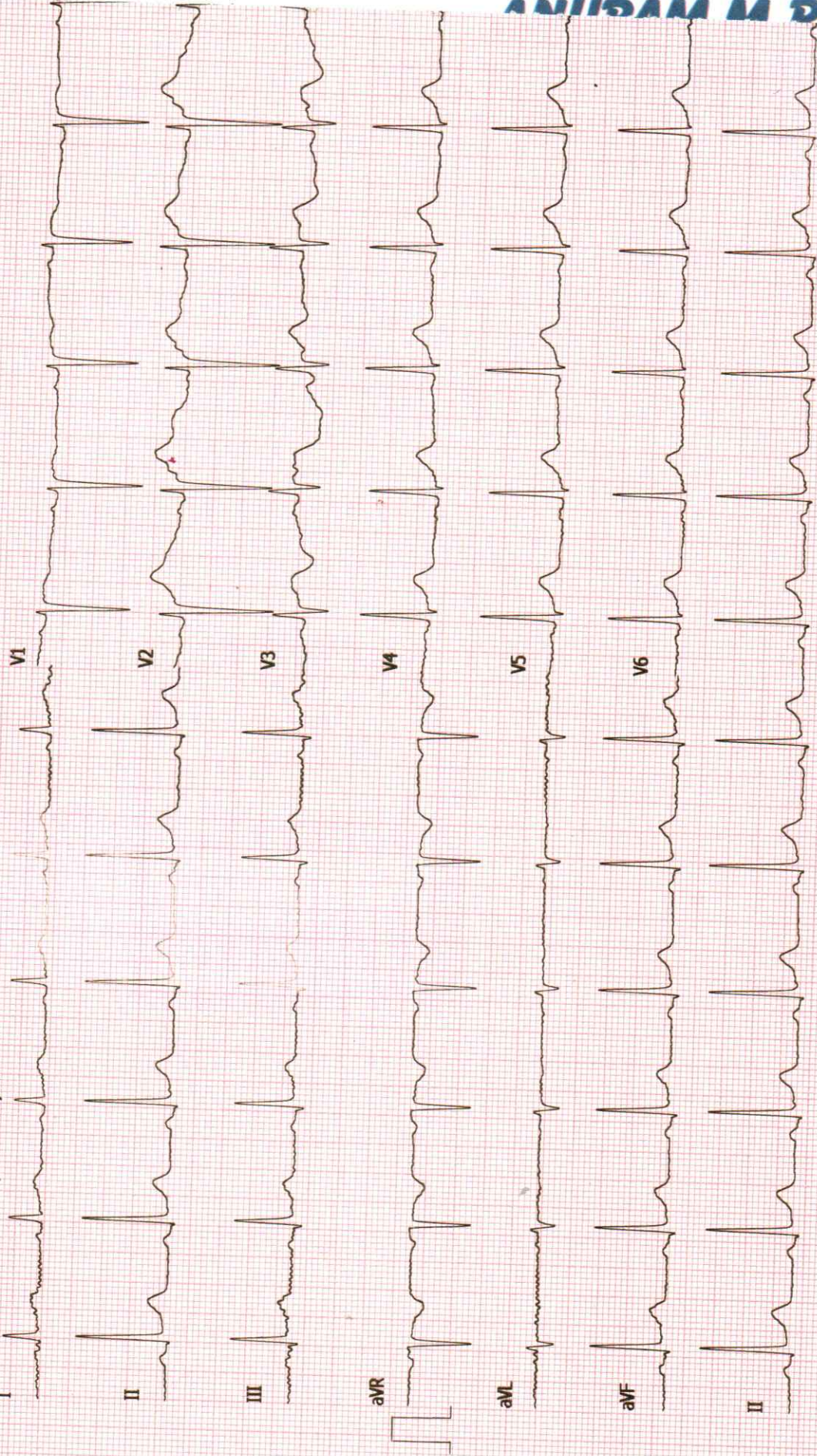
normal ECG

Sinus rhythm

HR	:	72 bpm
PR	:	148 ms
QRS	:	94 ms
QT/QTc	:	382/418 ms
P/QRS/T	:	84/68/65 °
RV5/SV1	:	1.257/-1.458 mV
RV5+SV1	:	2.715 mV

Need to be confirmed by doctor. Doctor Name: _____

0.5Hz - 25Hz AC 60Hz 25 mm/s 10 mm/mv



Dr. Ajay jaiswal
MBBS, MRSH

Dr. Abhitesh Kumar
MBBS, DMRD

Dr. A. P. Singh
MD, DMRD

**ANUPAM M.R.I
& C.T. SCAN CENTRE**
Equipped With 16 Slice High Speed Ct Sc

Name	: Rani Puja	Age/ Sex	: Y/F
Part scanned	: X-Ray Chest PA View	Date/Time	: 23.08.2021
Refd. by Dr.	: Parashar Hospital Muz.	ID No-	: 1505

X - RAY REPORT

Lung fields appear clear on both side.

Both CP angles is clear.

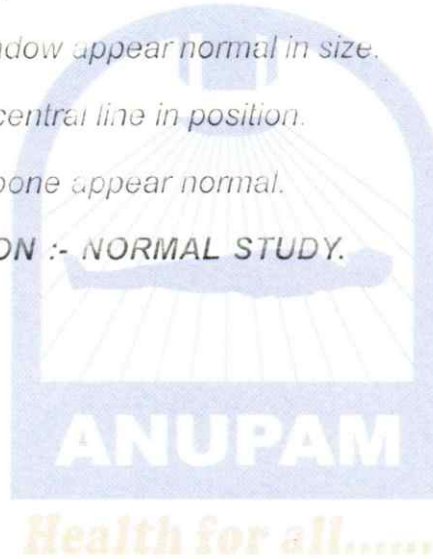
Both hila appear normal.

Cardiac shadow appear normal in size.

Trachea is central line in position.

Visualized bone appear normal.

IMPRESSION :- NORMAL STUDY.



Please correlate clinically.

On request
Not valid for medico-legal purpose.


Dr. Abhitesh Kumar
MBBS, DMRD.
Radiologist.



ROAD NO. 1, JURAN CHAPRA, MUZAFFARPUR - 842 001 (BIHAR)

Phones : 0621 - 2224133, 95259 71756

E-mail : abhiteshctscan@gmail.com

THIS IS A PROFESSIONAL OPINION NOT A DIAGNOSIS. IT NEEDS CLINICAL CORRELATION. REPORT IS NOT VALID FOR MEDICO - LEGAL PURPOSE.