

ID: 1  
NEERAJ SINHA  
Male Years

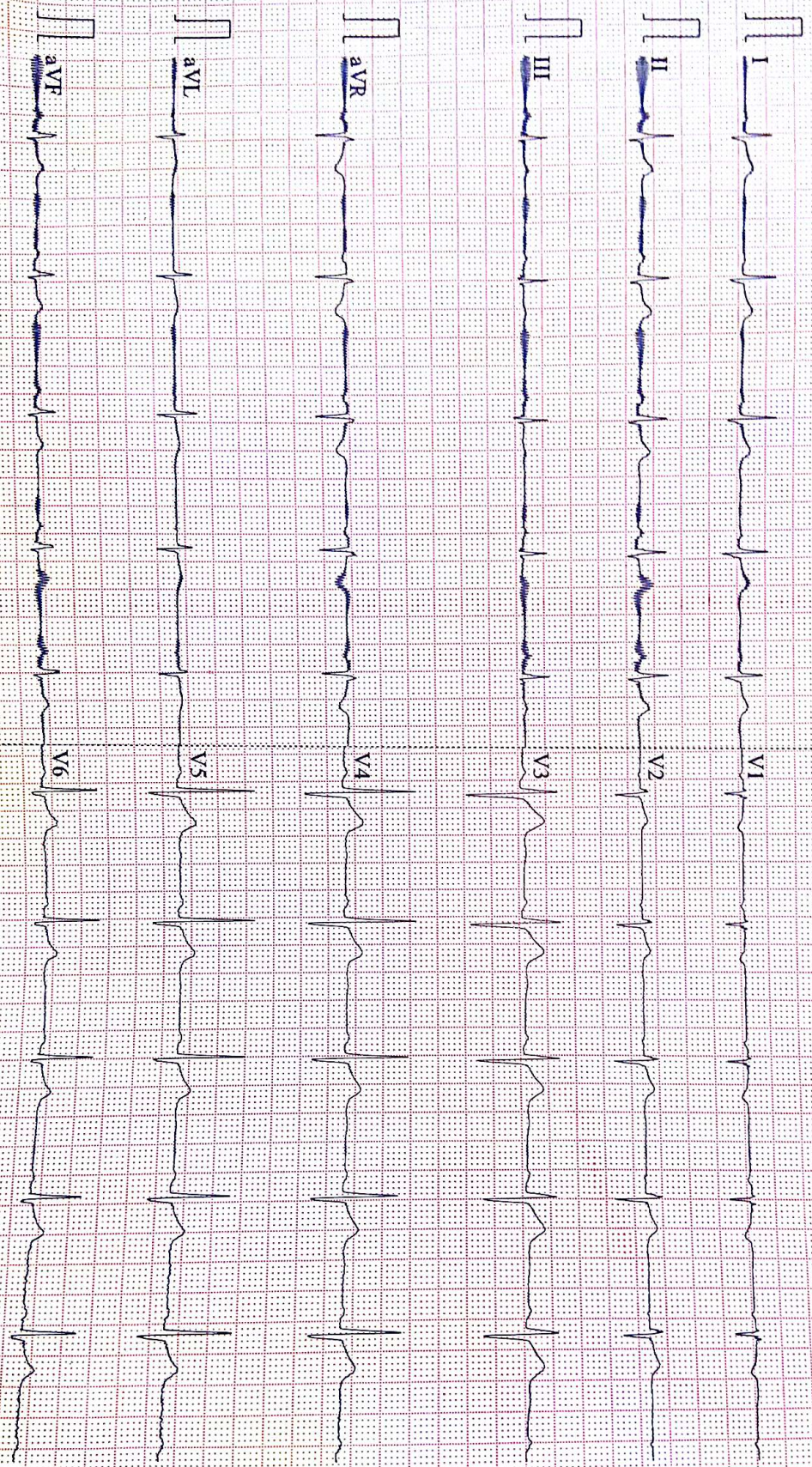
29-07-2021 09:51:02 AM

HR : 62 bpm  
P : 93 ms  
PR : 156 ms  
QRS : 79 ms

Diagnosis Information:  
Sinus Arrhythmia

QT/QTc : 365/373 ms  
P/QRS/T : 67/60/42 °  
RV5/SV1 : 1.234/0.360 mV

Report Confirmed by:



0.07-100Hz AC50 25mm/s 10mm/mV 2=5.0s V2.2 SEMIF-VI&I DIAGNOSTIC





# SUBHAM IMAGING & A.L.C. DIAGNOSTICS CENTRE

H.O. : Ajay Market, Dena Bank Building, East Ashok Nagar, Kankarbagh, Patna - 20

B.O. : Khanpura Road (Below Gyan Sharowar School), Paliganj, Patna.

e-mail : shubham.pat.usg@gmail.com # website : www.alchealthcheckup.in

OPINION MUST BE CORRELATES WITH CLINICAL & OTHER INVESTIGATION FOR DIAGNOSIS NOT FOR MEDICO LEGAL PURPOSE

Pt. Name :- **NIRAJ SINHA**  
Ref. By :- **DR . / B O B**

Date:- **29-Jul-21**  
Age / Sex :- **31 Yrs. M.**

## REAL TIME U.S.G. OF WHOLE ABDOMEN Thanks for your kind referral

(Report.)

- LIVER** :- Measures 14.16 cm. Mild Enlarged in shape, size and echo texture. I.H.B.R. are not dilated. Hepatic veins are normal. No SOL seen.
- G.BL.** :- Lumen is echo free. Wall thickness appears normal.
- C.B.D.** :- Measures 3.3 mm in diameter with echo free lumen. No calculi or mass seen.
- P.V.** :- Measures 7.2 mm in diameter. Appears normal. No thrombus seen.
- PANCREAS** :- Normal in shape, size and echo texture. No calcification mass seen.
- SPLEEN** :- Measures 10.25 cm. Normal in shape, size and echo texture. No SOL seen.
- KIDNEY** :- Both kidney shows normal shape, size & echotexture. C.M.D.intact. P.C.S.is not dilated. No calculi, cyst or hydronephrosis seen on either side.  
**Right Kidney** :- Measures 10.0 X 4.1 cm.  
**Left Kidney** :- Measures 10.10 X 4.2 cm.
- URETER** :- Not dilated. No apparent calculi seen.
- U.BLADDER** :- Shows normal in outline with echo free lumen. No calculi or mass seen.  
**Pre void** – 310 ml. **Post void** – is in significant
- PROSTATE** :- Normal in Size Shape Capsule is intact
- R.I.F.** :- Sonographically no appendicular mass or collection seen.
- OTHERS** :- Distended Bowel Loops seen in abdominal cavity with Excess bowel Gasses No Ascites no Lymph Adenopathy No pleural effusion seen on either side.

## IMPRESSION

- **Mild Hepatomegaly**
- **Adv :- Further Work Up LFT / Other Investigation**  
*Otherwise sonographically normal scan. of rest organs*

*29/7/21*

ESTB BY:-

**Dr. P. K. Tiwari**  
MD, BRIT (Radio Imaging)  
Consultant Imagiologist & Sonologist  
A.L.C. Diagnostics & Research Centre, Patna

**Dr. S. Kumar**  
MD. (Pat)  
Consultant Pathologist

**Dr. A. K. Singh**  
MBBS, PGDMCH  
Consultant Radiologist & Sonologist

Consultant Radiologist


PRINTING MISTAKE SHOULD BE REPORTED BACK IMMEDIATELY/ यहाँ जन्म से पहले भ्रुण का लिंग जाँच नहीं होता है ।




बैंक ऑफ बड़ौदा  
Bank of Baroda

नाम: **NEERAJ SINHA**  
Name:

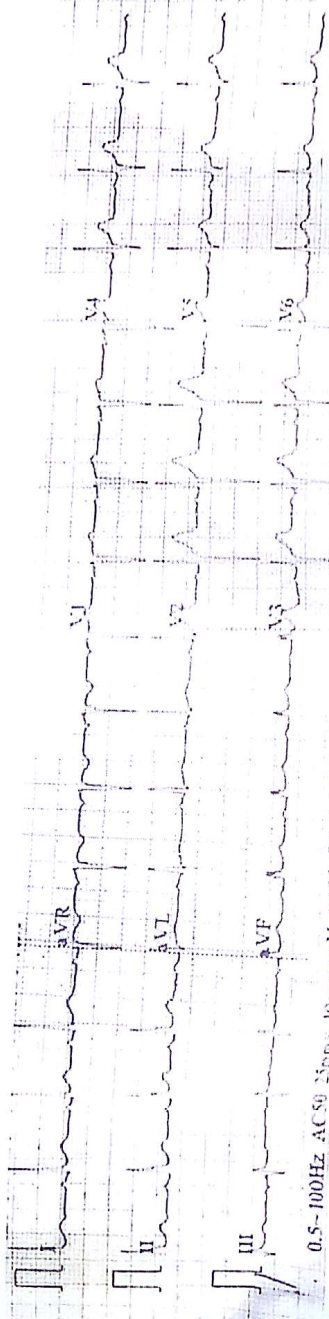
कर्मचारी कूट क्र.  
E.C. No.: **125089**

  
जारी करने प्राधिकारी  
Issuing Authority



  
धारक के हस्ताक्षर  
Signature of Holder





0.5-100Hz ACS 25mm/s 10mm/mV ♡109 SE-3 V1.0 SEMIP V1.7

ID: 179

male  
 Years ( / / )  
 cm kg

HR : 96 bpm  
 P : 95 ms  
 PR : 146 ms  
 QRS : 75 ms  
 QTc : 391.381 ms  
 PQRST : 322.333 ms  
 RV5:SV1 : 0.9591088 mV

Diagnosis Information:  
 Sinus Rhythm  
 Normal ECG  
 Kustagra

Dr. *Rohit Kumar*

M.D (Medicine)-BHU  
 Reg. No-BCMR-41854

Report Confirmed by: