



भारतीय विशिष्ट पहचान प्राधिकरण

Unique Identification Authority of India



पता:

द्वारा: शशांक बरनवाल, रंग महल रोड, रेलवे क्रॉसिंग
गोपालपट्टी रजपुरा, भदोही, संत रविदास नगर,
उत्तर प्रदेश - 221401



Address:

C/O: Shashank Baranwal, Rang Mahal Road
, Railway Crossing Gopalpatti Rajpura,
Bhadohi, Sant Ravidas Nagar,
Uttar Pradesh - 221401

4776 0588 6883

VID : 9104 9750 5495 7053



1947



help@uidai.gov.in



www.uidai.gov.in



GPS Map Camera



Varanasi, Uttar Pradesh, India

44-B3, Durgakund, Bhelupur, Varanasi, Uttar
Pradesh 221001, India

Lat 25.289252°

Long 82.993347°

25/02/23 09:51 AM GMT +05:30



सत्यमेव जयते

भारत सरकार

Government of India



आधार

Download Date: 10/02/2021



प्रियंका बरनवाल

Priyanka Barnwal

जन्म तिथि/DOB: 30/10/1992

महिला/ FEMALE

Issue Date: 02/02/2021

4776 0588 6883

VID : 9104 9750 5495 7053

मेरा आधार, मेरी पहचान



GPS Map Camera



Varanasi, Uttar Pradesh, India

44-B3, Durgakund, Bhelupur, Varanasi, Uttar Pradesh 221001, India

Lat 25.289252°

Long 82.993347°

25/02/23 09:51 AM GMT +05:30

Google

Facilities:

All clinical Biomedical & Hematology Investigations including Bone Marrow Examination
VPT, Podiascan & Complete Foot Care (First Time in Purvanchal)
All Hormonal Investigation by Chemiluminescent Method
Visceral Fat by (AB-140) Ambulatory BP Monitoring
CGMS & Insulin Pump Available
PFT, 2D-ECHO (Color Doppler), Holter, TMT, Cardiac-3 available
VIA, VILI, Colposcopy available
Special Endocrinological Investigation Protocols.

ISO 9001:2008 Certified
Mobile: 9389994334, 9554572190, 9453837595



Panacea Pathology

Clinical Reference Lab

Persistence, Preparedness and Precision
EQAS (CMC Vellore Attached) & IQAS System
पूर्वांचल की सर्वोत्तम गुणवत्ता वाली पैथोलॉजी

PATIENT NAME : PRIYANKA BARANWAL

AGE/GENDER : 31YRS/FEMALE

REFD BY DR. : ARCO FEMI HEALTHCARE LTD.

RECEIVED DATE : 25-02-2023(09:30AM)

SAMPLE : BLOOD & URINE

REPORT DATE :25-02-2023(07:00PM)

PATHOLOGY REPORT

COMPLETE BLOOD COUNT (CBC)

TEST	LAB TEST VALUES	NORMAL RANGE
HEMOGRAM		
HEMOGLOBIN (FLOW CYTOMETRY)	11.3	13 – 16 gm/dl
TOTAL LEUCOCYTE COUNT (TLC)	4,700	4000 – 11000
RBC COUNT	3.92	3.5 – 5.5
PCV (HCT)	36.4	37 – 47
MCV	92.7	80 – 95
MCH	28.7	28 – 34
MCHC	31.0	30 – 36
PLATELET COUNT	1,53,000	1,50,000 – 4,00,000
E.S.R. (WINTROBE FIRST HOURS)	18.0	20 mm/1 st hr
DIFFERENTIAL LEUCOCYTE		
NEUTROPHILS	50	40 – 75%
LYMPHOCYTES	44	20 – 45%
EOSINOPHILS	03	1 – 6%
MONOCYTES	03	2 – 8%
BASOPHILS	00	< 2 %

RENAL & KIDNEY PROFILE, SERUM

TEST	LAB TEST VALUES	NORMAL RANGE
RENAL FUNCTION TESTS		
BLOOD UREA NITROGEN (BUN)	8.21	10 – 50 mg/dl
SERUM CREATININE	0.60	0.60 – 1.60 mg/dl
URIC ACID	4.12	3.60 – 7.70 mg/dl
ALKALINE PHOSPHATASE (ALP)	71.0	142 – 353 mg/dl
TOTAL PROTIENS	7.36	0 – 39 mg/dl
ALBUMIN	4.12	3.8 – 5.4 mg/dl
SERUM GLOBULIN	3.24	2.1 – 3.5 mg/dl
CALCIUM	9.0	8.80 – 10.20
PHOSPHORUS	3.04	2.50 – 5.00
SERUM SODIUM NA+	1.005	135.00 – 155.00 mEq/Ltr
SERUM POTASIUM K+	4.12	3.60 – 5.50 mEq/Ltr
ICALCIUM	1.22	1.10 – 1.35 mmol/L
SERUM CHLORIDE CL+	101.3	98.00 – 110.00 mEq/Ltr

PAGE 1

Lab Technician

PANACEA HOSPITAL
UNIT OF AAROH HEALTHCARE PVT. LTD.
REG. NO. AL-1500
B.36/44, BK-4 KABIR NAGAR
DURGAKUND, VARANASI
M.D., Pathology

Timing : 8.00 a.m. to 9.00 p.m. (Sunday 8.00 a.m. to 3.00 p.m.)

This Report is not valid for medico legal purpose

Note: These tests have technical limitations. Clinico-pathological interpretation is necessary. In case of any disparity test may be repeated immediately.

Address : 36/44 FK Kabir Nagar, Durgakund, Varanasi – 221005

Email: dramishra@gmail.com, drpallaviojha@gmail.com Website: panaceahospital.org

Facilities:

All clinical Biomedical & Hematology Investigations including Bone Marrow Examination
VPT, Podiascan & Complete Foot Care (First Time in Purvanchal)
All Hormonal Investigation by Chemiluminescent Method
Visceral Fat by (AB-140) Ambulatory BP Monitoring
CGMS & Insulin Pump Available
PFT, 2D-ECHO (Color Doppler), Holter, TMT, Cardiac-3 available
VIA, VILI, Colposcopy available
Special Endocrinological Investigation Protocols.

ISO 9001:2008 Certified
Mobile: 9389994334, 9554572190, 9453837595



Panacea Pathology

Clinical Reference Lab

Persistence, Preparedness and Precision
EQAS (CMC Vellore Attached) & IQAS System
पूर्वाचल की सर्वोत्तम गुणवत्ता वाली पैथोलॉजी

PATIENT NAME : PRIYANKA BARANWAL	AGE/GENDER : 31YRS/FEMALE
REFD BY DR. : ARCO FEMI HEALTHCARE LTD.	RECEIVED DATE : 25-02-2023(09:30AM)
SAMPLE : BLOOD & URINE	REPORT DATE : 25-02-2023(07:00PM)

PATHOLOGY REPORT

LIPID PROFILE, SERUM

TEST	LAB TEST VALUES	NORMAL RANGE
BLOOD CHEMISTRY		
TOTAL CHOLESTEROL (SERUM)	132.0	Desirable:- < 200 mg/dl Borderline:- 200 – 239 mg/dl High:- > 240 mg/dl
TRIGLYCERIDES (SERUM)	144.0	35 – 170 mg/dl
HDL CHOLESTEROL (SERUM)	36.0	35.30 – 79.50 mg/dl
LDL CHOLESTEROL (SERUM)	67.2	< 130 mg/dl
VLDL	28.8	< 40 mg/dl
CHOLESTROL/HDL RATIO	3.66	< 3.0 Low Risk Ratio 3.0 – 5.0 Avg Risk > 5.0 High Risk
LDL/HDL RATIO	1.8	< 3 Ratio

BLOOD GROUP

TEST	LAB TEST VALUES
BLOOD GROUP ABO & RH FACTOR	
BLOOD GROUP	"B"
RH FACTOR	POSITIVE

GLYCOSYLATED HEMOGLOBIN (HBA1C)

TEST	LAB TEST VALUES	NORMAL RANGE
HBA1C	5.3	Normal : <5.97 % Good Control : 5.97 – 6.81% Fair Control : 6.81 – 7.65% Poor Control : >7.65%

THYROID PROFILE (T3, T4, TSH)

TEST	LAB TEST VALUES	NORMAL RANGE
THYROID FUNCTION TEST		
T3	1.21	0.60 – 1.81 ng/ml
T4	7.86	4.50 – 10.90 ug/dl
TSH	2.65	0.39 – 6.10 uIU/mL

PAGE 2

Lab Technician

PANACEA HOSPITAL
(A UNIT OF AAROH HEALTH CARE PVT. LTD.)
REG. NO. 1500
B.36/44, B-4, KABIR NAGAR
DURGAMUDA, Pathology

Timing : 8.00 a.m. to 9.00 p.m. (Sunday 8.00 a.m. to 3.00 p.m.)

This Report is not valid for medico legal purpose

Note: These tests have technical limitations. Clinico-pathological interpretation is necessary. In case of any disparity test may be repeated immediately.

Address : 36/44 FK Kabir Nagar, Durgakund, Varanasi – 221005

Email: dramishra@gmail.com, drpallaviojha@gmail.com Website: panaceahospital.org

All clinical Biomedical & Hematology Investigations including Bone Marrow Examination VPT, Podiascan & Complete Foot Care (First Time in Purvanchal) All Hormonal Investigation by Chemiluminescent Method Visceral Fat by (AB-140) Ambulatory BP Monitoring CGMS & Insulin Pump Available PFT, 2D-ECHO (Color Doppler), Holter, TMT, Cardiac-3 available VIA, VILI, Colposcopy available Special Endocrinological Investigation Protocols.

ISO 9001:2008 Certified
Mobile: 9389994334, 9554572190, 9453837595



Panacea Pathology

Clinical Reference Lab

Persistence, Preparedness and Precision
EQAS (CMC Vellore Attached) & IQAS System
पूर्वांचल की सर्वोत्तम गुणवत्ता वाली पैथोलॉजी

PATIENT NAME : PRIYANKA BARANWAL

AGE/GENDER : 31YRS/FEMALE

REFD BY DR. : ARCO FEMI HEALTHCARE LTD.

RECEIVED DATE : 25-02-2023(09:30AM)

SAMPLE : BLOOD & URINE

REPORT DATE : 25-02-2023(07:00PM)

PATHOLOGY REPORT

LIVER PROFILE TEST, SERUM

TEST	LAB TEST VALUES	NORMAL RANGE
BIO CHEMISTRY		
TOTAL BILIRUBIN	0.66	0.0 – 1.1 mg/dl
DIRECT BILIRUBIN	0.24	0.0 – 0.2 mg/dl
INDIRECT BILIRUBIN	0.42	< 0.90 mg/dl
SGOT (AST)	18.6	0 – 52 mg/dl
SGPT (ALT)	22.0	0 – 39 mg/dl
GGT (GYT)	20.0	< 55 U/L

URINE ROUTINE EXAMINATION

TEST	LAB TEST VALUES	NORMAL RANGE
PHYSICAL EXAMINATION		
QUANTITY	29	ML
COLOUR	STRAW	PALE YELLOW
APPEARANCE	CLEAR	CLEAR
SPECIFIC GRAVITY	1.010	1.01 – 1.03
PH	5.5	4.7 – 7.5
CHEMICAL EXAMINATION		
GLUCOSE	Not Detected	Not Detected
PROTEIN	NIL	Not Detected
MICROSCOPIC EXAMINATION		
PUS CELLS	1-2	0-5
RBC	Not Detected	Not Detected
EPITHELIAL CELLS	2-3	0-5
CASTS	Not Detected	Not Detected
CRYSTALS	Not Detected	Not Detected
BACTERIA	Not Detected	Not Detected

RANDOM/FASTING BLOOD SUGAR

TEST	LAB TEST VALUES	NORMAL RANGE
RBS/FBS		
RANDOM BLOOD SUGAR	97.0	125-140 mg/dl
FASTING BLOOD SUGAR	76.2	70-110 mg/dl

----- End of Report -----

Lab Technician

PANACEA HOSPITAL
(A UNIT OF ARCO FEMI HEALTHCARE PVT. LTD.)
REG. NO. AL-1500
B.36/4, M.D., Pathology
DURGAKUND, VARANASI

Timing : 8.00 a.m. to 9.00 p.m. (Sunday 8.00 a.m. to 3.00 p.m.)

This Report is not valid for medico legal purpose

Note: These tests have technical limitations. Clinico-pathological interpretation is necessary. In case of any disparity test may be repeated immediately.

Address : 36/44 FK Kabir Nagar, Durgakund, Varanasi – 221005
Address : 36/44 FK Kabir Nagar, Durgakund, Varanasi – 221005
Email: dramishra@gmail.com, drpallavi@panacea.org
Email: dramishra@gmail.com, drpallavi@panacea.org

Address : 36/44 FK Kabir Nagar, Durgakund, Varanasi – 221005
Address : 36/44 FK Kabir Nagar, Durgakund, Varanasi – 221005
Email: dramishra@gmail.com, drpallavi@panacea.org
Email: dramishra@gmail.com, drpallavi@panacea.org



PANACEA HOSPITAL

B 36/44 F.K KABIR NAGAR, DURGAKUND
TOLLFREE NO-18001233070.
Whatsapp No - 8795832852
www.piire.org



OP Slip

Print Date : 25-Feb-2023 09:55AM



UHID No :- UD-22230003768	OP No :- OP-22230013949	OP Date :- 25 Feb 2023 9:55AM
Patient Name :- Mrs PRIYANKA BARNWAL	Age/Sex :- 31 Y/Female	Mobile No :- 9540047150
Husband :-	Department :- OBST. & GYNAECOLOGY	
Pay Type :- Cash	Consultant :- Dr VANDANA SINGH (MBBS,MS)	
Token No :- NOR. - 2	Paid/Bal :- 0.00 /30.00	
Patient Type :- Normal		
Address :- BHADOHI, BHADOHI		

BP :- 110/70 **Rx**
 height :- 161
 Weight (kg) :- 55.6
 BMI :-

clo → nil.
 for routine check up.

SpO₂ - 98
 PR - 56

LMP - 24/2/2023.
Regular

NO Gynae complaints.
 Took abortifacient ~~in~~ last month.

P₁+L₁ → ♀ 11m LSCS.

USG - WNL.

adu
 Pap smear - when
 bleeding stop.

adu
 ⇒ Tab tranera * TDS * 3d.
 Tab Ibus XT 1 x OD x 30d
 Tab calcium 1 x OD x 30d

Printed By : Mr NITIN YADAV
 Created By : Mr NITIN YADAV

Page 1 of 1

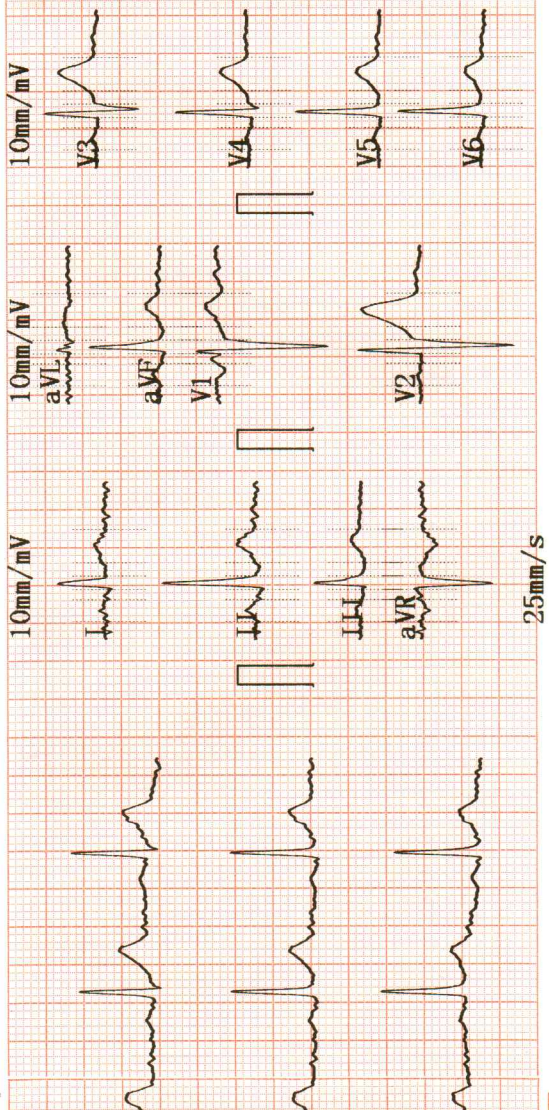
BPL-02

2023-02-25 12:46

<< Conclusions >>

Normal Sinus Rhythm;
Cardiac electric axis normal;
Age :
Weight: kg **Report need physician confirm**

Dr. Pallavi Mishra
MBBS, MD (GENERAL MEDICINE)
MCT Reg. No. 52073



25mm/s

Physician _____

CARDI

RT

BPL - 02

AUTO 10mm/mV

10mm/mV

10mm/mV

10mm/mV

I

aVR

V1

V4

II

aVL

V2

V5

III

aVF

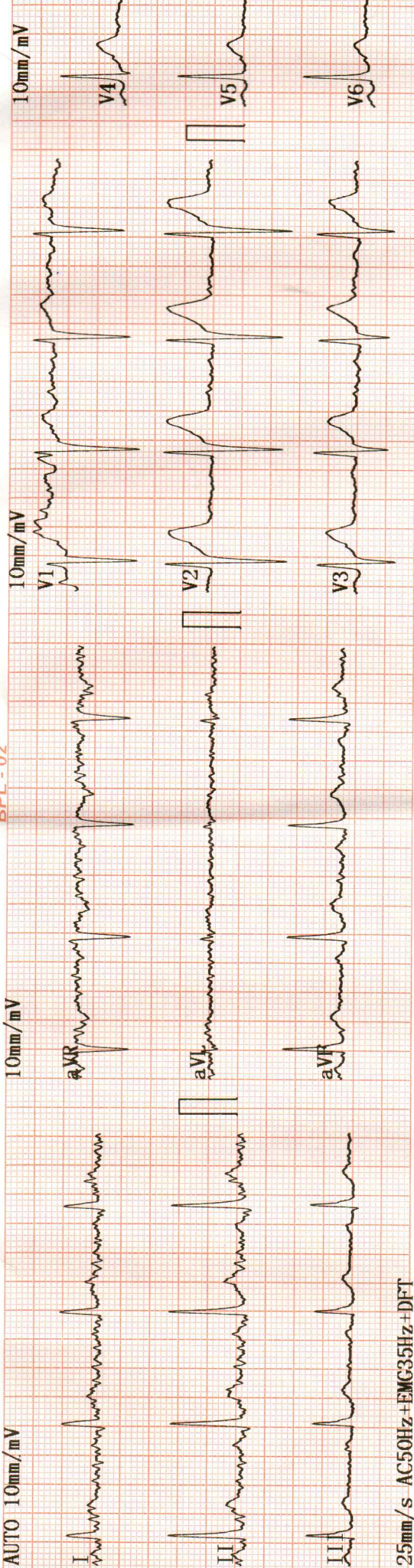
V3

V6

25mm/s AC50Hz+EMC35Hz+DFT

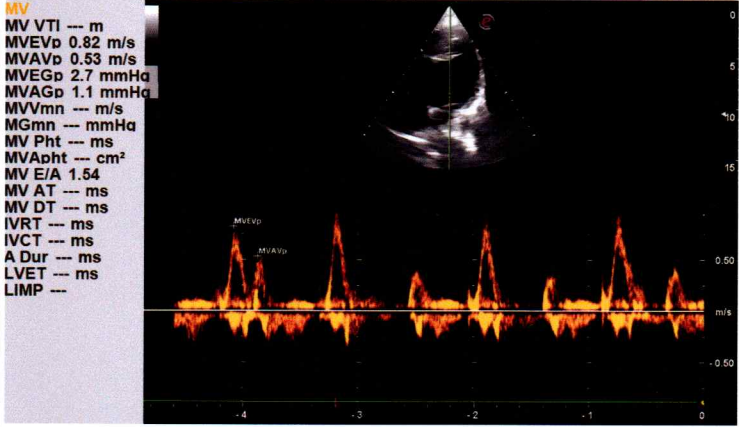
ART

CARD



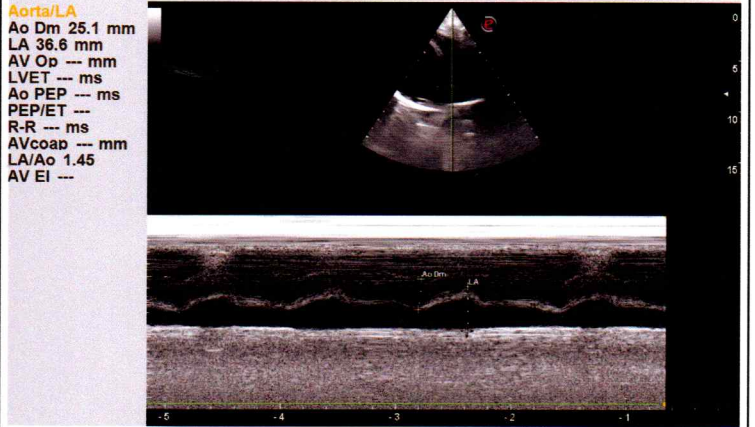
PRIYANKA BARNWAL 31Y/F 25 02 2023 10:27:06 AM

CARDIAC SP2730 ECHO B PENL G -- M F PENL G -- P 80% MI 0.4
 TEI D 160 mm X/M C2- PRF 6.1 MHz WF 150 Hz TIB 1.2
 PRC 6/3/2/4 PRS 1 PRC 4/1 HR --



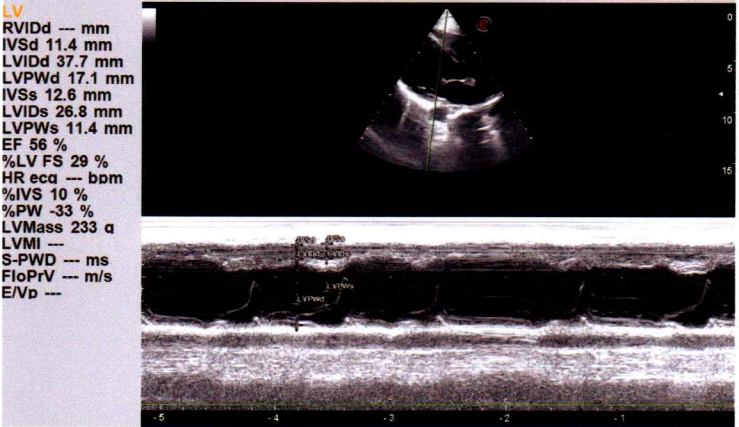
PRIYANKA BARNWAL 31Y/F 25 02 2023 10:27:06 AM

CARDIAC SP2730 ECHO B PENL G -- M F PENL G -- P 80% MI 0.7
 TEI D 160 mm X/M C2- PRF 6.3/2/4 PRS 1 TIB 0.5
 PRC 6/3/1 HR --



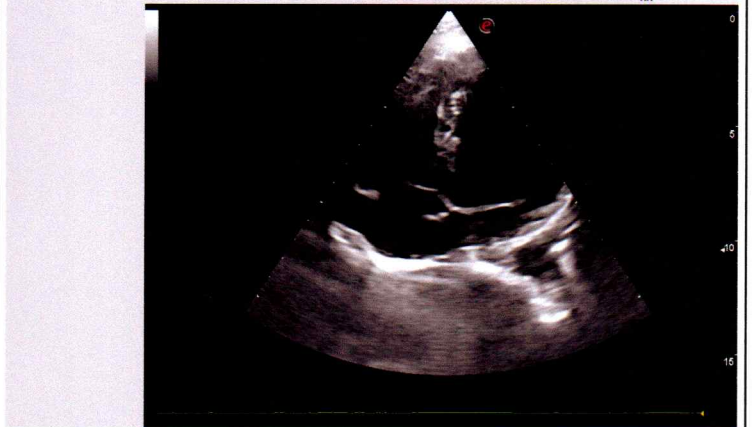PRIYANKA BARNWAL 31Y/F 25 02 2023 10:27:06 AM

CARDIAC SP2730 ECHO B PENL G -- M F PENL G -- P 80% MI 0.7
 TEI D 160 mm X/M C2- PRF 6.3/2/4 PRS 1 TIB 0.5
 PRC 6/3/1 HR --



PRIYANKA BARNWAL 31Y/F 25 02 2023 10:27:06 AM

CARDIAC SP2730 ECHO B PENL G -- M F PENL G -- P 80% MI 0.9
 TEI D 160 mm X/M C2- PRF 6.3/2/4 PRS 1 TIB 0.5
 PRC 6/3/1 HR --





Call Now - 1800-123-3070

PANACEA HOSPITAL

A shelter for many hearts A Home for many lives

(An ISO 9001:2008 Certified Organisation)

Lab Attached with CMC Vellore Under EQAS Scheme

Name	MRS.PRIYANKA BARNWAL	Sex /Age	31/F	Date	25/02/2023
Ref. by	Dr.Pallavi Mishra(MD)	BSA - m ²		Echo window	fair

Echo - Cardiology

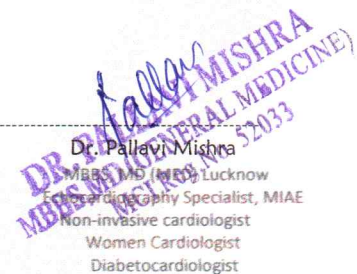
MITRAL VALVE Doppler	AML - normal morphology MV Flow - E - 0.8 A-0.5 E/A=1.54	PML - normal morphology MVA - 3.0 cm ² Mitral Regurgitation - No
TRICUSPID VALVE Doppler	Normal TV Flow -No	Tricuspid Regurgitation - No
PULMONARY VALVE Doppler	Normal PV Flow -No	Pulmonary Regurgitation - No
AORTIC VALVE Doppler	Trileaflet-No AV Flow - no	Aortic Regurgitation - no
MEASUREMENT	Aorta - 25.1 (20-38) mm IVS ed - 11.4 (6 -12) mm LVID ed - 37.7 (35 - 55) mm LVPW ed - 17.1 (6 -12) mm OA - 7 (> 5) mm	LA - 36.6 (24-32) mm IVS es -12.6 (6 - 12) mm LVID es - 26.8 (24 - 40) mm LVPW es - 11.4 (6 -12) mm EPSS - 8 (< 9) mm

CONCLUSION

All cardiac chamber dimensions are WNL
No valvular abnormalities
Good LV systolic function present Modified Simpson's method (4C, 2C) (LVEF-56%)
No diastolic dysfunction present (E/A = 1.54) by tissue Doppler (E/e'=6.2)
No RWMA
No pericardial effusion
Intact IAS / IV
No PAH
No intra cardiac mass /thrombus /vegetation

IMPRESSION **Normal Echocardiogram**

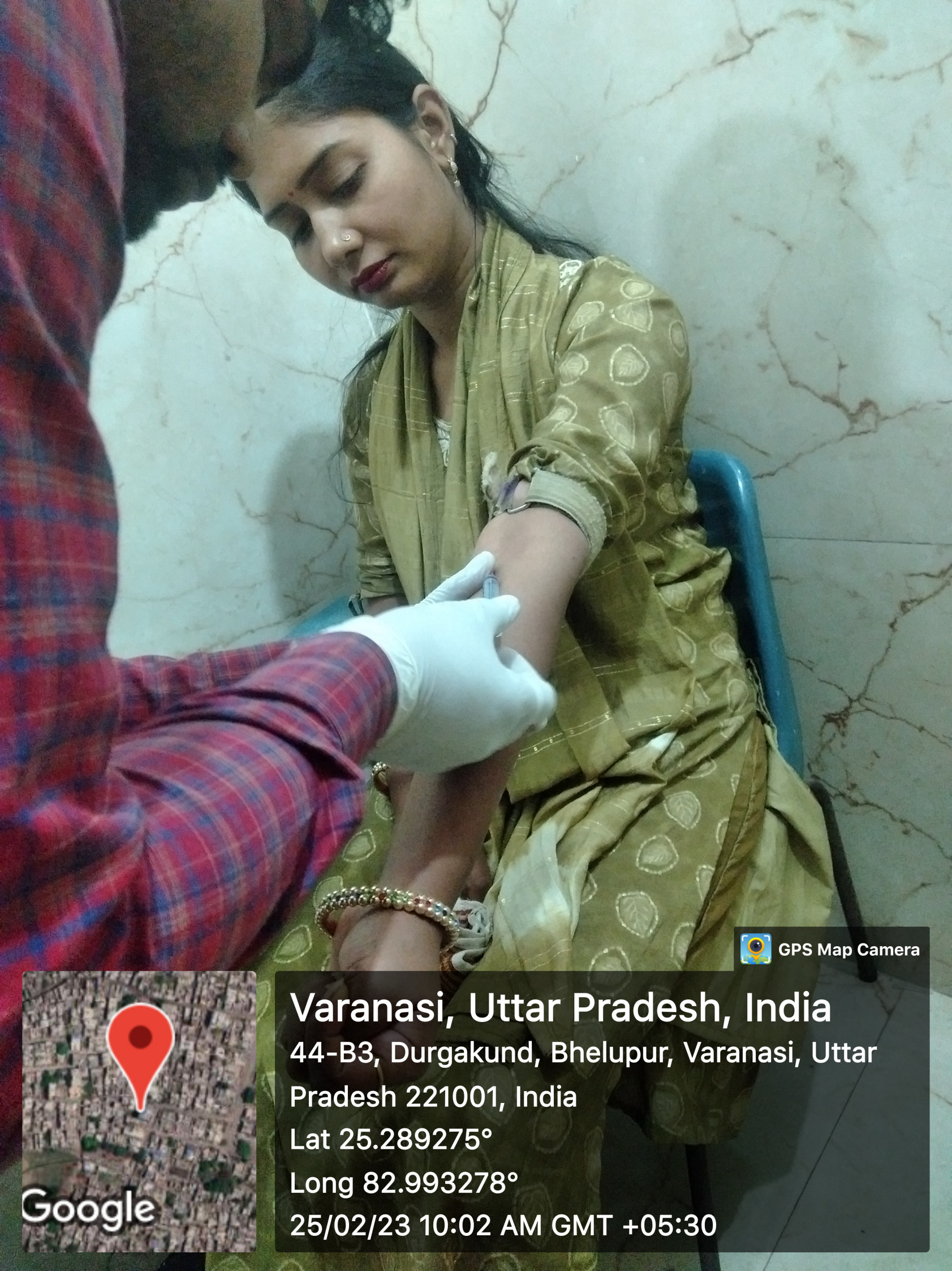
Nisha Mishra
Physician Assistant
(PIIRE)



Dr. Pallavi Mishra
MBBS MD (MED) Lucknow
Cardiology Specialist, MIAE
Non-invasive cardiologist
Women Cardiologist
Diabetocardiologist

Address : Kabir Nagar (Near Sanjay Shiksha Niketan), Durgakund, Varanasi

Mobile : 9554572190 / 9453837595 / Recpn. 9389994334

E-mail : dramishra@gmail.com, drpallaviojha@gmail.com, Website: www.piire.org



 GPS Map Camera



Varanasi, Uttar Pradesh, India

44-B3, Durgakund, Bhelupur, Varanasi, Uttar Pradesh 221001, India

Lat 25.289275°

Long 82.993278°

25/02/23 10:02 AM GMT +05:30

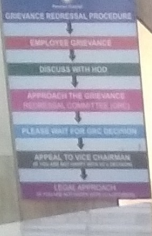Panacea Hospital

A Smile For Many Hearts
Home For Many Lives

Diabetes Care Organisation

आप कैमरे की निगरानी में हैं
YOU ARE UNDER CCTV SURVEILLANCE

महत्वपूर्ण सूचना
शुचता मरीजों और उनके रिश्तेदारों के लिए
किसी भी अस्पताल/नर्सिंग होम/
क्लीनिक/हिल्व सेक्टर में तोड़-फोड़
करना या डाक्टर एवं स्टाफ के साथ
अश्रद्ध व्यवहार अथवा मारपीट
करना गैर जमानती अपराध है।
कानून
U.P. Medical Protection Act - 2013
1. शोषण, उत्पीड़न, हानि और खानगी अपराध है।
2. 3 साल की सजा से 50000/- तक जुर्माना।
3. गम्भीर मामलों में सजा से 10 सालों की कैद की सजा भी संभव।
4. 10-15 साल तक पुलिस द्वारा जांचित भी जारी
रखी जा सकती है।



ओ. पी. डी.
O.P.D. ROOM

MAY I HELP YOU

GPS Map Camera



Varanasi, Uttar Pradesh, India
44-B3, Durgakund, Bhelupur, Varanasi, Uttar Pradesh 221001, India
Lat 25.289247°
Long 82.993377°
25/02/23 09:52 AM GMT +05:30



Call Now - 1800-123-3070

PANACEA HOSPITAL

A shelter for many hearts A Home for many lives

(An ISO 9001:2008 Certified Organisation)

Lab Attached with CMC Vellore Under EQAS Scheme

NAME: MRS.PRIYANKA BARNWAL

AGE/SEX: 31 YRS / FEMALE

REF BY: DR. ASHUTOSH MISHRA (MD)

DATE:25/02/2023

ULTRA SOUND FOR ABDOMEN REPORT

Liver: Normal in shape and size(11.3cm) and shows smooth and regular margin.

Gall bladder Normal distended with normal wall thickness and echo-free lumen.

CBD Visualized part normal in course & caliber.

Pancreas: Normal in size, shape & echogenicity.Margins are smooth & regular.No diffuse/ focal lesion seen. Pancreatic tail obscured.

Spleen: Normal in size shape & echogenicity.Margins are smooth & regular. No diffuse / focal lesion seen. Splenic vessels at hilum is normal.

Kidney: Right kidney: 9.8 X 4.4cm Left kidney: 10.2 X 4.6 cm Normal cortical echogenicity with well maintained Cortical-medullary differentiation.,Pelvicalyceal system normal.No calculus/mass lesion seen.No hydronephrosis/hydroureter seen.

Urinary bladder: Normally distended, wall thickness is normal. No echogenic foci lumen or diverticula seen. Both VUJ appears normal. No E.R. calculus / mass lesion seen

Uterus: Uterus normal in size shape & echogenicity. Margins are smooth & regular. Endometrial thickness within normal limits(5.0 cm).

Ovary: Right ovary normal in size and shows normal morphology. Left ovary normal in size and shows normal morphology.

Others: No free fluid in peritoneal cavity. No free fluid in bilateral pleural cavity.

Impression:

❖ **NO SIGNIFICANT SONOLOGICAL ABNORMALITY DETECTED.**

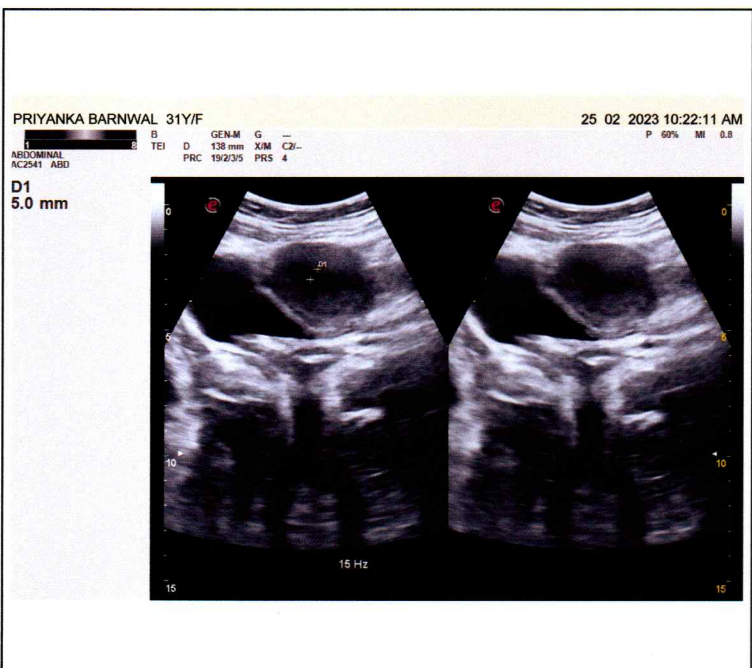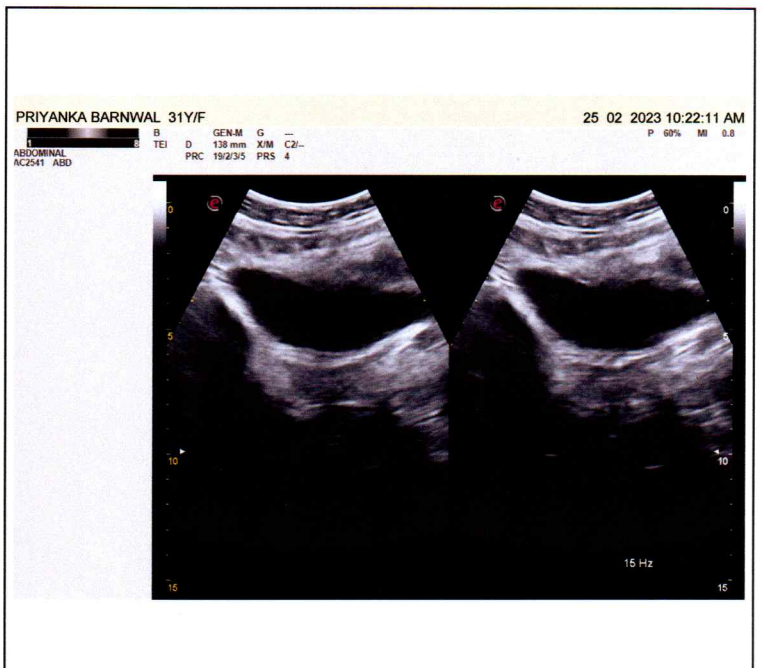
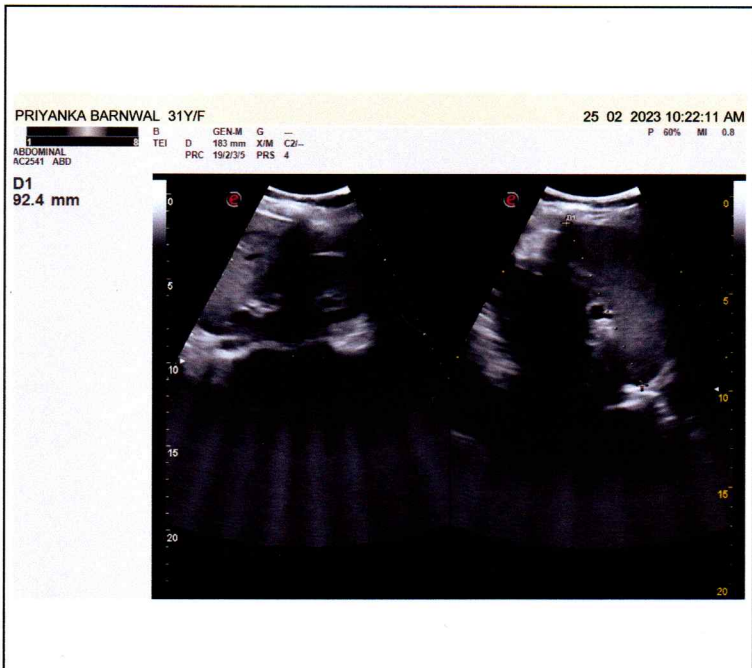
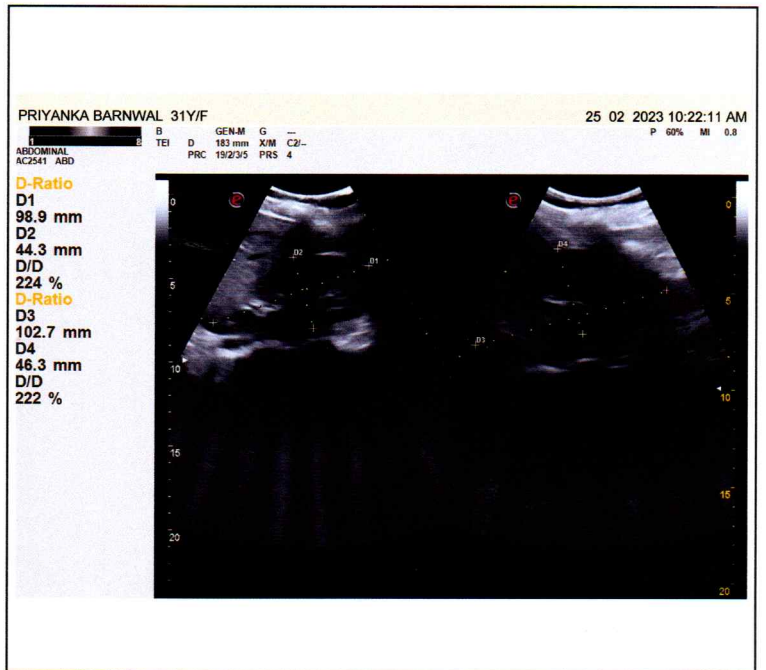
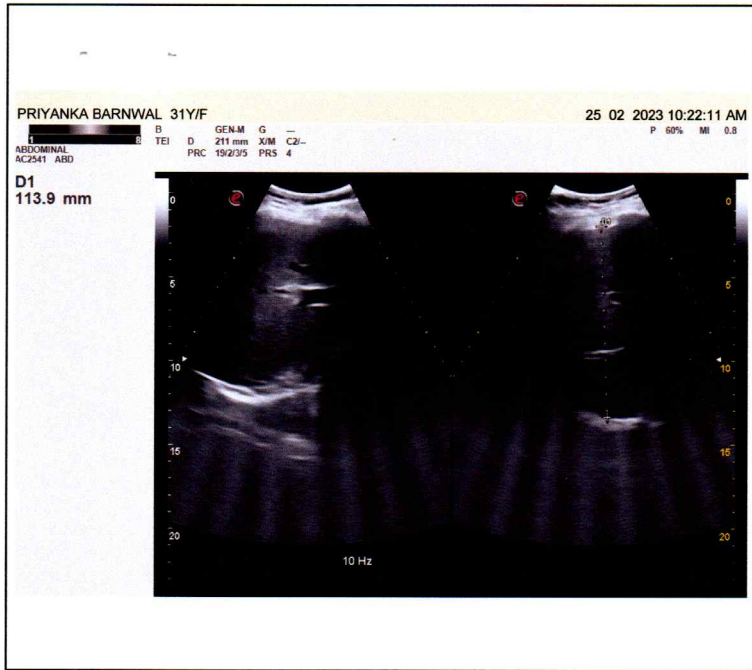
REPORTED BY
DR. B. K. TIWARI
MD RADIODIAGNOSIS (GOLD MEDALIST)
KGMU,LUCKNOW
Reg.No. 57557

Please correlate clinically and further investigations.

Address : Kabir Nagar (Near Sanjay Shiksha Niketan), Durgakund, Varanasi

Mobile : 9554572190 / 9453837595 / Recpn. 9389994334

E-mail : dramishra@gmail.com, drpallaviojha@gmail.com, **Website:** www.piire.org





Call Now - 1800-123-3070

PANACEA HOSPITAL

A shelter for many hearts A Home for many lives

(An ISO 9001:2008 Certified Organisation)

Lab Attached with CMC Vellore Under EQAS Scheme

NAME:MRS.PRIYANKA BARNWAL

AGE/SEX: 31 YRS / FEMALE

REFBY:DR.ASHUTOSH MISHRA(MD)

DATE:25/02/2023

X-RAY CHEST PA

BOTH LUNG FIELDS AND PLEURAE:

Both lungs show normal bronchovascular pattern.

Right & left hila are normal

No focal mass or calcification is seen

There is no evidence of any fluid in the both the pleural cavities.

Both domes of diaphragms are normal in position.

MEDIASTINUM:

Trachea is central in position.


Cardiac silhouette is of normal size and configuration.

No evidence of pericardial effusion.

No significant lymphadenopathy is seen.

Visualized skeleton is normal.

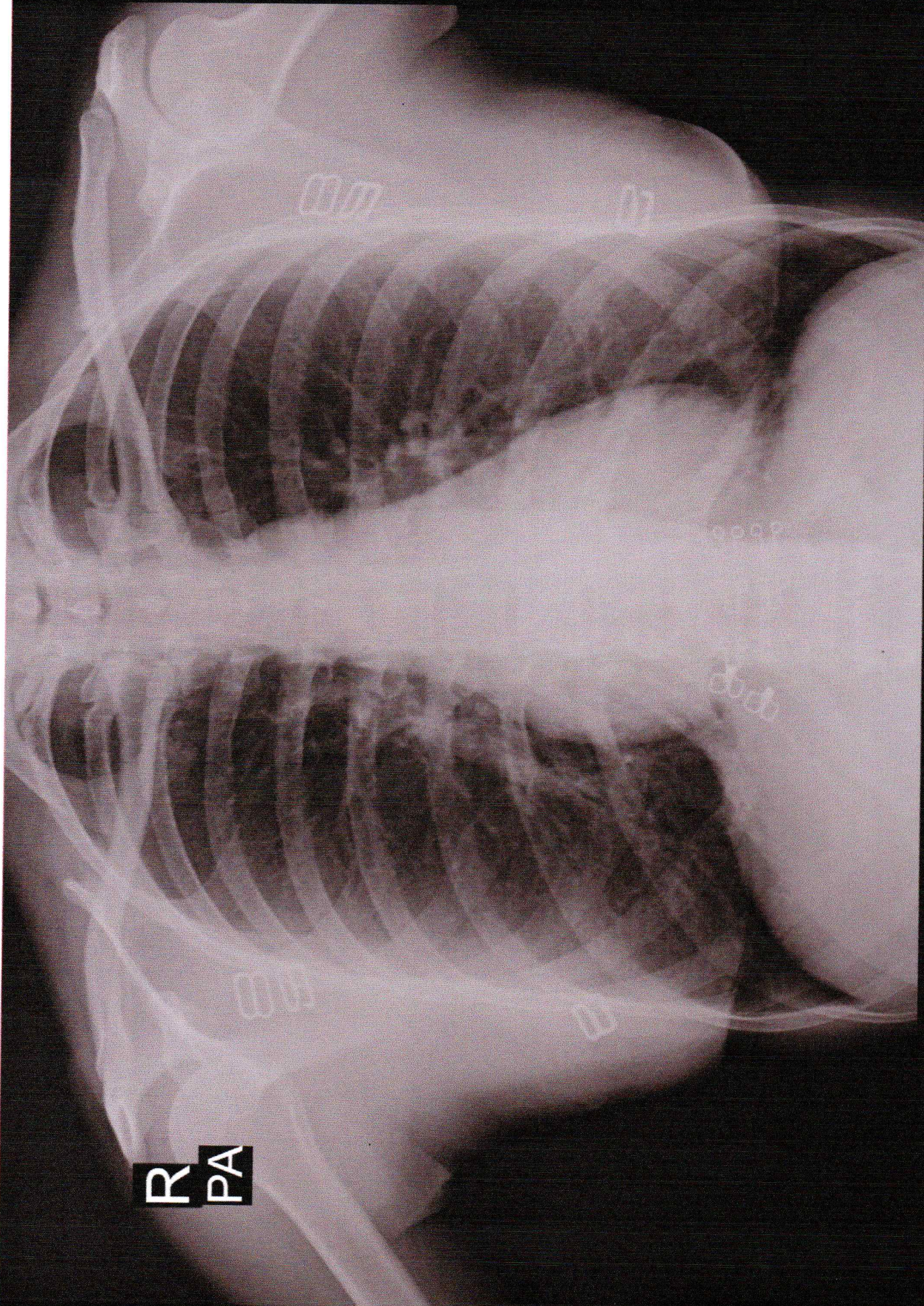
NO SIGNIFICANT RADIOGRAPHIC ABNORMALITY.


REPORTED BY
DR. Rahul Kumar Tiwari
MBBS, MD (Radio Diagnosis)
Reg.No. 57557

Address : Kabir Nagar (Near Sanjay Shiksha Niketan), Durgakund, Varanasi

Mobile : 9554572190 / 9453837595 / Recpn. 9389994334

E-mail : dramishra@gmail.com, drpallaviojha@gmail.com, Website: www.piire.org



R
PA

PRIYANKA BARANWAL 31Y/F 3768 O CHEST P.A. 25-Feb-23 10:26 AM

PANACEA HOSPITAL, KABIR NAGAR, DURGAKUND, VARANASI