



SCAN REPORT

NAME	:MR.ANBUK KUMAR.G	PATIENT ID	:MH20220041695
AGE/SEX	:33 Years / MALE	IP / OP NO	:OP21035141
CONSULTANT	:DR.ARUN PRAKASH	DATE	:21/11/2022

ULTRA SOUND SCAN OF ABDOMEN

LIVER: Enlarged in size and measures- 17.3 cm and increased in echotexture. No focal lesions are seen. No dilatation of intra-hepatic biliary radicals present. Hepatic veins and IVC appear normal. Portal vein is normal in caliber. Common bile duct is normal in caliber.

GALL BLADDER: Partially distended.

PANCREAS: Normal in size and echotexture. No focal lesions are seen. No evidence of calculi or calcifications. No evidence of pancreatic duct dilation.

PARA AORTIC AREAS: Aorta and IVC appear normal. No evidence of para aortic lymphadenopathy.

SPLEEN: Normal in size and measures-9.5 cm. Normal in echotexture. No evidence of focal lesions.

RIGHT KIDNEY: Measures 9.9 x 4.9 cm and is normal in size and echotexture. Cortico medullary differentiation is well maintained. There is no hydronephrosis or mass.

LEFT KIDNEY: Measures 10.3 x 4.6 cm and is normal in size and echotexture. Cortico medullary differentiation is well maintained. There is no calculus or hydronephrosis or mass.

URINARY BLADDER: Minimally distended.

PROSTATE: Normal in size and measures- 3.1 x 3.4 x 2.0 cm echotexture. Volume- 11.7 cc.

Seminal vesicles appear normal.

No ascites present. No retroperitoneal lymphadenopathy present.

IMPRESSION:

- Hepatomegaly with fatty infiltration.
- No other significant abnormality detected in the visualized abdominal organs.


DR. BAKTIN MDRD.,

CONSULTANT RADIOLOGIST,



MURUGAN HOSPITALS

HEALING HANDS



ECHO CARDIOGRAM REPORT

NAME : MR. ANBUK KUMAR.G

UHID NO: MH20220041695

AGE&SEX : 33Y/MALE

IP/OP : OUTPATIENT

CONSULTANT: DR. ARUN PRAKASH

DATE : 21-11-2022

2D PLAX (mm)

RV - 25 mm
AO - 34 mm
LA - 27 mm

COLOR DOPPLER

Normal

M-Mode (mm)

IVS - 07 mm
PW - 09 mm
LVD - 43 mm
LVS - 27 mm
EF - 68 %
FS - 37 %

DOPPLER (m/sec)

MITRAL E - 0.6 m/s
MITRAL A - 0.4 m/s
PULMONARY - 1.0 m/s
AORTIC - 0.8 m/s
TRICUSPID - 0.5 m/s

IMPRESSION:

No RWMA
Normal LV Systolic function
Grade I left ventricular diastolic dysfunction
Normal RV function
No pulmonary hypertension
No pericardial effusion
No clot/ Vegetation.



DR. SIDDHARTHAN MD., DM.,
CONSULTANT CARDIOLOGIST

Healing Hearts and Lives

264/125, Kilpauk Garden Road, Kilpauk, Chennai - 600 010.
Phone : +91 44 4644 8989 / 75500 53335 | Email : muruganhosp@gmail.com
Website : www.muruganhospitals.in

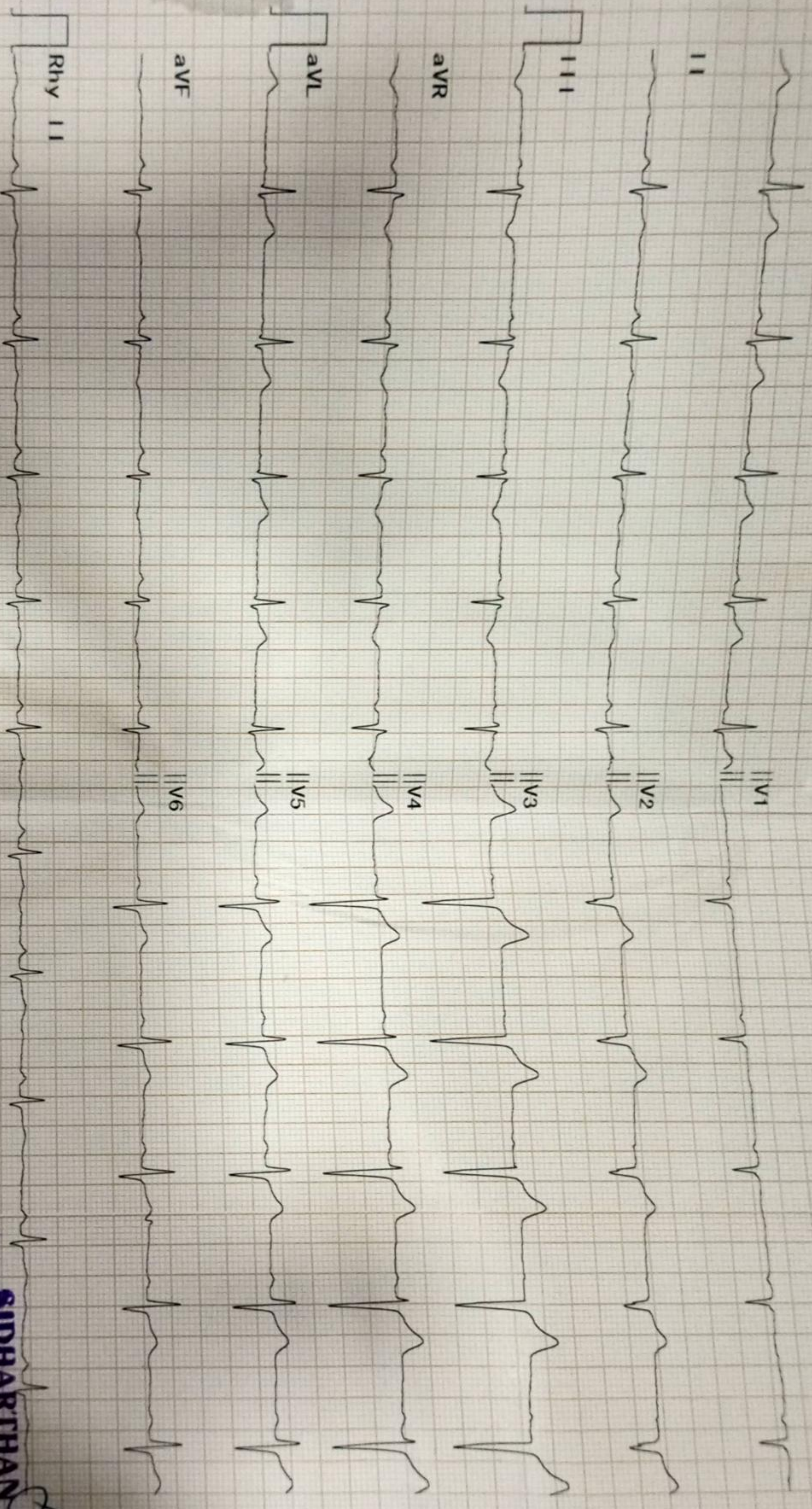
ID : 2211210005
 Name : MR. ANBUKUMAR
 Sex : Male
 Divisions :

Date/Time : 2022-11-21 10:16
 Age : 33
 BP : 120/80 mmHg
 Bed No. :
 RV5/SV1 amp 0.455/0.535mV
 RV5+SV1 amp 0.990mV
 RV6/SV2 amp 0.612/0.549mV

patient ID: 41695
 Height : 174 cm
 Weight : 93 kg
 Hospital No. :
 Minnesota Code
 1-1-2 (V1, V2)
 9-4-2 (V4)

Hospital : MURUGAN HOSPITALS
 Diagnosis Info
 800: Sinus Rhythm

HR : 66 bpm
 P Dur/PR int : 94 / 157ms
 QRS Dur : 99 ms
 QT/QTc : 378 / 396 ms
 P/QRS/T axis : 53 / 4 / -3 °



Diagnosis for reference, ask your doctor to confirm
 AUTO PRINT 6X2+1R 66bpm 10 mm/mV 0.50Hz-35Hz AC 50Hz 25 mm/sec

Confirmed By :

SIDHARTHAN MD DM
 Consultant Cardiologist
 Reg No: 62979



MURUGAN HOSPITALS

HEALING HANDS



LAB REPORT

Patient Name : Mr. ANBUK KUMAR.G
Age / Gender : 33-Years / Male
UHID ID : MH20220041695
Doctor Name : Dr. ARUN PRAKASH

OP Report No. : INVA2107821
Bill No. : INV2205482
Sample Date : 21/11/2022 - 09:11 AM
Report Date : 21/11/2022 - 04:04 PM

Test Name	Result	Units	Reference Interval
HAEMATOLOGY			
Complete Blood Cell Count(CBC)			
HAEMOGLOBIN	15.0	gms/dl	male :13.0 - 17.0 female :12.0 - 15.0
PACKED CELL VOLUME	48.5	%	male : 40 - 50 female : 36 - 46
RBC COUNT	<u>5.62</u>	millions cells/cu.mm	female: 3.8 - 4.8 male : 4.5 - 5.5
TOTAL WBC	10,300	Cells/Cumm	4,000 - 11,000
Differential Count			
NEUTROPHILS	63	%	40 - 65
LYMPHOCYTES	33	%	30-50
EOSINOPHILS	04	%	01-06
MONOCYTES	<u>00</u>	%	1-10
BASOPHILS	00	%	0-2
ESR 60 MTS	<u>04</u>	mm	5 - 20
PLATELET COUNT	3.32	Lakhs/cumm	1.5 - 4.5
MCV	86.3	fL	76 - 96
MCH	<u>26.6</u>	pg	27 - 32
MCHC	30.4	gms/dl	30 - 36

INTERPRETATION: Test done on automated three part cell counter, all abnormal results are reviewed and confirmed microscopically

BLOOD GROUPING & RH TYPING " A " POSITIVE

Healing Hearts and Lives

264/125, Kilpauk Garden Road, Kilpauk, Chennai - 600 010.
Phone : +91 44 4644 8989 / 75500 53335 | Email : muruganhosp@gmail.com
Website : www.muruganhospitals.in



MURUGAN HOSPITALS

HEALING HANDS



LAB REPORT

Patient Name : Mr. ANBUK KUMAR.G
Age / Gender : 33-Years / Male
UHID ID : MH20220041695
Doctor Name : Dr. ARUN PRAKASH

OP Report No. : INVA2107821
Bill No. : INV2205482
Sample Date : 21/11/2022 - 09:11 AM
Report Date : 21/11/2022 - 04:04 PM

Test Name	Result	Units	Reference Interval
BIO CHEMISTRY			
BLOOD SUGAR FASTING	<u>129</u>	mgs/dl	70-110
BLOOD SUGAR POST PRANDIAL	<u>176</u>	mgs/dl	80- 160
SERUM CREATININE	0.9	mg/dl	0.6-1.4
SERUM URIC ACID	4.7	mg/dl	male 3.1-7.0 , female 2.5-5.6
LIPID PROFILE			
TOTALCHOLESTEROL	<u>250</u>	mg/dl	< 200
TRIGLYCERIDE	190	mg/dl	< 150
HDL	39	mg/dl	35 - 80
VLDL	<u>38</u>	mg/dl	2 to 30
LDL	173	mg/dl	<130
CHOLESTEROL/ HDL RATIO	6.4	mg/dl	



MURUGAN HOSPITALS

HEALING HANDS



LAB REPORT

Patient Name : Mr. ANBUK KUMAR.G
 Age / Gender : 33-Years / Male
 UHID ID : MH20220041695
 Doctor Name : Dr. ARUN PRAKASH

OP Report No. : INVA2107821
 Bill No. : INV2205482
 Sample Date : 21/11/2022 - 09:11 AM
 Report Date : 21/11/2022 - 04:04 PM

Test Name	Result	Units	Reference Interval
LIVER FUNCTION TEST			
BILLIRUBIN(TOTAL)	0.6	mg/dl	0.0 -1.0
BILLIRUBIN(DIRECT)	0.2	mg/dl	0.1- 0.30
BILLIRUBIN(INDIRECT)	0.4	mg/dl	0.2-0.8
SGOT	27	IU/L	0-38
SGPT	18	IU/L	0.0-40
ALKALINE PHOSPHATASE	64	IU/L	40-140 4-6Years 93-309 13-15Years 74-390
TOTAL PROTEIN	7.9	gm/dl	6.6-8.7
ALBUMIN	4.8	gm/dl	3.5 - 5.5
GLOBULIN	3.1	gm/dl	2.0-3.5
AG RATIO	1.5		
GAMMA G T	19	U/L	male<49 female<32
BLOOD UREA NITROGEN	7.0	mg/dl	7-21
HBA1C	6.2	%	normal: <6.0 good control: 6.1-7.0 fair control: 7.1- 8.0 poor control:8.1 -10.0 unsatisfactory: >10.0

Healing Hearts and Lives

264/125, Kilpauk Garden Road, Kilpauk, Chennai - 600 010.
 Phone : +91 44 4644 8989 / 75500 53335 | Email : muruganhosp@gmail.com
 Website : www.muruganhospitals.in



MURUGAN HOSPITALS

HEALING HANDS



LAB REPORT

Patient Name : Mr. ANBUK KUMAR.G
 Age / Gender : 33-Years / Male
 UHID ID : MH20220041695
 Doctor Name : Dr. ARUN PRAKASH

OP Report No. : INVA2107821
 Bill No. : INV2205482
 Sample Date : 21/11/2022 - 09:11 AM
 Report Date : 21/11/2022 - 04:04 PM

Test Name	Result	Units	Reference Interval
CLINICAL PATHOLOGY			
URINE SUGAR (F)	NIL		
URINE SUGAR (PP)	++		
URINE ROUTINE			
COLOUR	STRAW YELLOW		
APPEARANCE	CLEAR		
REACTION	ACIDIC		
SUGAR	NIL		
ALBUMIN	NIL		
DEPOSITES			
PUS CELLS	3-4	/ HPF	
EPI CELLS	2 - 3	/ HPF	
RBC COUNT	NIL	/ HPF	
CAST	NIL		
CRYSTALS	NIL		
OTHERS	NIL		

SHENBAGAVALLI
 Verified by

*** End of Report ***



Healing Hearts and Lives

264/125, Kilpauk Garden Road, Kilpauk, Chennai - 600 010.
 Phone : +91 44 4644 8989 / 75500 53335 | Email : muruganhosp@gmail.com
 Website : www.muruganhospitals.in



MURUGAN HOSPITALS

HEALING HANDS



LAB REPORT

NAME : MR. ANBUK KUMAR G (4509)
PIN : AND22380174391
AGE/GENDER : 33 Year(s)/Male
REFERRED BY : Dr.ARUN PRAKASH
CLIENT NAME : MURUGAN HOSPITAL

SAMPLE NO : 3822115218
COLLECTED ON : 21/11/2022 03:19 PM
RECEIVED ON : 21/11/2022 03:19 PM
REPORTED ON : 21/11/2022 04:26 PM
REPRINT DATE : 21/11/2022 04:26 PM

Test	Obtained Value	Units	Bio.Ref.Intervals
IMMUNOASSAY			
PSA(Prostate Specific Antigen) - Total, Serum (SERUM,ECLIA)	0.476	ng/mL	<= 1.4

-- End of Report --




Dr. E. Uma MD, DCP
Consultant Biochemist

Page 1 / 1

Healing Hearts and Lives

264/125, Kilpauk Garden Road, Kilpauk, Chennai - 600 010.
Phone : +91 44 4644 8989 / 75500 53335 | Email : muruganhosp@gmail.com
Website : www.muruganhospitals.in



MURUGAN HOSPITALS

HEALING HANDS

NAME : MR.ANUBUKKUMAR
AGE /GENDER:33YRS/ MALE
CONSULTANT: DR.ARUNPRAKASH

UHID : MH20220041695
IP/OP : OP
DATE : 21.11.2022

X-RAY CHEST (PA VIEW)

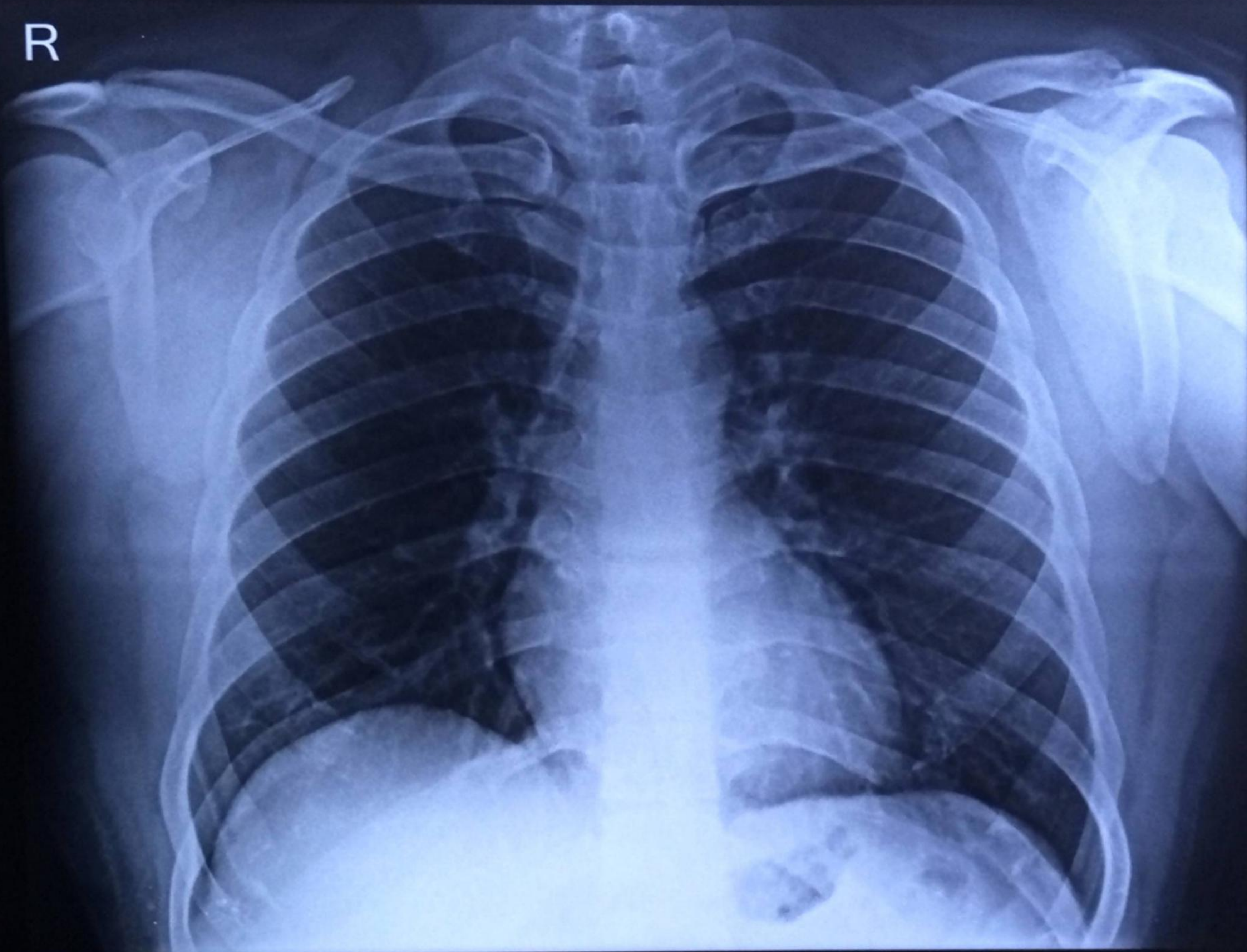
- The cardio thoracic ratio is normal
- The heart size and configuration are within normal limits
- The aortic arch is normal
- The lung fields show normal broncho- Vascular markings
- Both the pulmonary hila are normal in size
- The costophrenic and cardiophrenic recesses and the domes of diaphragm are normal
- The bones and soft tissues of the chest wall show no abnormality

IMPRESSION:

Normal Study



R



MR.ANBUK KUMAR.G 33YRS 41695 CHEST-PA 21-11-2022

MURUGAN HOSPITALS, KILPAUK CHENNAI-10 PH NO: 7550053335 / 46448989