



PARKLINE DIAGNOSTICS PVT. LTD.

L.G. 3, 4 & 5, Bhuvana Towers, S.D. Road, Secunderabad - 500 003.

Tel : +91 40-2784 5852, 6649 1787, 7995421787, 7093445852, Fax : +91 40 2784 7864

Email parklinediagnostics@gmail.com www.parklinediagnostics.com



NABL Accredited
Certificate No.MC-2566

MEDICAL EXAMINATION REPORT

Name	Mr. Gattu Venkata Ramana		Date :	11/12/2021	
Company	D.O. Mediowheel		Reg. No. :	1570773	
Contact No.	9909981898		Sex	<input checked="" type="checkbox"/> M	Age : <input type="checkbox"/> 42
Type	Pre-Emp		Emp. No.:	96305	
	Overseas		Height	168 cm	
	Annual	<input checked="" type="checkbox"/>	Weight	73 kgs	
Remarks	Hyperecholesterolemia . Advice follow up. Test all physical & lab parameters within (N) limits.				
Fitness Status	Medically Fit / Unfit		DR. PRIYANKA SANNIDHI Physician's Signature Regn. No : 11351		

COMPREHENSIVE MEDICAL EXAMINATION REPORT

NAME Mr. Battu Venkata Ramana

AGE 47 / Male

MARITAL STATUS married CHILDREN : M F 2

IDENTIFICATION (IF ANY) A mole on the Neck Left.

PAST HISTORY

Any family H/o : High Blood Pressure, Heart Disease, Tuberculosis, Diabetes, Asthma, Cancer

Any personal H/o Major illness like : Typhoid..... Nil Jaundice..... 1993 Etc.

Any H/o STD..... Skin infection..... NIL

H/o Blood Transfusion..... NAD Recent Vaccination..... COVISHIELD 2 doses ✓

H/o Epilepsy..... Giddiness..... NIL

H/o Surgery..... Hydrocele operator in 2009 Fracture in the past..... NIL

Any Personal H/O.

High Blood Pressure, Heart Disease Tuberculosis, Diabetes, Asthma, Cancer

Drug Abuse, Drug Allergy, Micturition, Bowels, Alcohol, Smoking, Sleep, MC, Wt. Loss/Wt. Gain

Present illness / Medication

GENERAL EXAMINATION

Conjunctiva :

Skin :

Ears :

Nose :

Throat & Oral Cavity :

NAD

Bone, Joints : NO

Nutritional Status : well Nourished

Lymph Nodes : NAD

Edema Feet : NIL

Varicose Veins : NIL

Distant Vision : Near Vision :

Right Eye: 6/6

With glasses / Without glasses

left Eye: 6/6

with glasses / without glasses

Colour Vision: Normal

Right Ear

Hearing: (N)

Rinee's Test ;

Weber Test :

Discharge : NIL

Right Eye: Ng + 1.75 sph Ng

With glasses / Without glasses

left Eye: Ng + 1.75 sph Ng

with glasses / without glasses

Ophthalmologist's Signature

Dr. KATTA
M.B.B., D.O., F.R.F.
Reg. M.S. (AMC)

Left Ear

(N)

NIL

SYSTEMIC EXAMINATION

Pulse : 80 bpm

B.P. : 140/90 mmHg

Lungs : A. Shape of Chest B/L symmetrical
B. Breath Sounds B/L clear ⊕
C. Adventitious Sounds No

Heart : A. Sounds S₁ S₂ ⊕
B. Murmurs No murmurs

Abdomen : A. Liver NP
B. Spleen NP
C. Piles No
D. Any Lump No

Nervous System

A. Higher Function :
B. Cranial Nerves :
C. Sensory System :
D. Motor System :
E. Jerks : (N)

General : A. Hernia - NO
B. Hydrocele - Hydrocele operated 2009
C. Varicocele - NIL & no herniation seen.

Breast : Rt — Lt —

CANDIDATE'S DECLARATION

I hereby solemnly declare that I am not suffering from Asthma, Hypertension, Diabetes, Occult Psychological disorders or any other ailment which can be suppressed without my voluntary declaration.

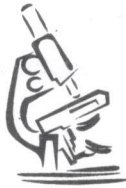Date :



Signature

Place :

Note : General Physical Examination and Investigation included in the health check-up Have certain limitations and may not be able to detect all latent and asymptomatic diseases. Any new symptoms developing after the health check-up or persisting thereafter should be brought to the attention of the treating physician.



PARKLINE DIAGNOSTICS PVT. LTD.

L.G. 3, 4 & 5, Bhuvana Towers, S.D. Road, Secunderabad - 500 003. Tel : +91 40-2784 5852, 6649 1787, 7995421787, 7093445852, Fax : +91 40 2784 7864 Email parklinediagnostics@gmail.com www.parklinediagnostics.com



NABL Accredited
Certificate No.MC-2566

ENT CONSULTATION

S.No. 1570773

Emp.No. 96305

Date 11/12/2021

Name Mr. Gattu Venkata
Ramana

Age 47 Yrs

Sex M/F

EARS :

Right

Left

EAC : patent, no Cerumen

-do-

TM : Intact, pearly white.

-do-

TFT : Cone of light (+)

Rinne's test

Rinne's test

Weber's - Central

NOSE

: Septum (N) Bil. Turbinate (N) Nos (N) non tend

THROAT

: Oropharynx: (N) Bil. v.c.s (N) moving

NECK

: (N) Any tenderness bil

IMPRESSION:

ENT clinically NAD.

Dr. D. Hari Krishna Reddy
MS (ENT)

Head & Neck Surgeon
Reg. No: 88379



Phone: 27844043
66339096

SECUNDERABAD DENTAL HOSPITAL

CENTRE FOR ADVANCED DENTAL CARE

12/12/2021

ORAL & MAXILLOFACIAL SURGEONS

Dr. Kazim Himathi M.D.S.

Dr. Gautam Dendukuri

FDSRCS (Eng), FFDRCS (Ire),
FFDRCS (OMFS), (Ire)

PROSTHODONTIST

Dr. Chandrakanth Reddy M.D.S.

ENDODONTIST

Dr. Ram Narayan Reddy M.D.S.

ORTHODONTIST

Dr. Rajesh Reddy M.D.S., M.Orth RCS.

Dr. Sudeep Bhalerao M.D.S.

PERIODONTIST

Dr. Veerendranath Reddy M.D.S.

PERIODONTIST

Dr. Mounika M.D.S.

DENTAL SURGEONS

Dr. N. Jagadish Rao B.D.S.

Dr. Baisakhi Saha B.D.S.

Mr. Gattu Venkata Ramana

doc :- PA of Mr. came for regular
dental checkup

O/E :- Start

Adv :- Scaling





PARKLINE DIAGNOSTICS PVT. LTD.

L.G. 3, 4 & 5, Bhuvana Towers, Sarojini Devi Road, Secunderabad - 500 003 Tel. +91 40-2784 5852
6649 1787 Fax : +91 40 2784 7864 Email : parklinediagnostics@gmail.com www.parklinediagnostics.com



NABL Accredited
Certificate No. MC-2566

TEST REPORT

Name : Mr . GATTU VENKATA RAMANA [96305]
Age / Gender : 47 Years / Male
Ref.By : Medi Wheel
Req. No : BIL1570773

TID : UMR0617848
Registered on : 11-Dec-2021 08:58 AM
Reported On : 11-Dec-2021 10:41 AM

DEPARTMENT OF ULTRASOUND Ultrasound Whole Abdomen

LIVER : Measuring 13.85 cms. Normal in size and increased echotexture. No focal lesions.
No IHBD /CBD dilatation. Portal vein is normal in size.

SPLEEN : Normal in size and echotexture. No focal lesion seen.

GALL BLADDER : Well distended. No sludge / gall stones / sol.
Gall bladder -Wall thickness is normal.
No pericholecystic oedema.

PANCREAS : Normal in size and echotexture.No calcification / sol.
Pancreatic duct is normal. No peripancreatic fluid collection.

RIGHT KIDNEY : 11.42 x 5.02 cms
Normal in size and echotexture.
Cortical thickness is normal.
No evidence of calculi / sol.
Pelvi calyceal system is normal.


LEFT KIDNEY : 10.44 x 5.55 cms
Normal in size and echotexture.
Cortical thickness is normal.
No evidence of calculi / sol.
Pelvi calyceal system is normal.

URINARY BLADDER : Well distended. Normal ii contour.
Wall thickness is normal. No calculus / sol.

PROSTATE : Measuring 3.67 x 3.08 x 3.34 cms (Vol : 19.76 cc) Normal in size and echotexture.
No calcification / sol.
No pre or para aortic adenopathy / ascites noted.

IMPRESSION : Grade I fatty liver.

Clinical correlation


Dr. D.J. MOHAN
MD DMRD
(Reg No. 8995)
Consultant Radiologist

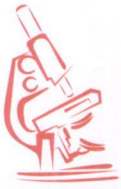The Test marked with*are not accredited by NABL

Lab Timings (Weekdays) : 7.00 am to 8.30 pm

Sundays & Holidays : 7.00 am to 1.00 pm

Radiologists Timings (Weekdays) : 7.30 am to 1.30 pm
& 5.30 pm to 7.45 pm

Sundays & Holidays : 7.30 am to 9.30 am



PARKLINE DIAGNOSTICS PVT. LTD.

L.G. 3, 4 & 5, Bhuvana Towers, Sarojini Devi Road, Secunderabad - 500 003 Tel. +91 40-2784 5852
6649 1787 Fax : +91 40 2784 7864 Email : parklinediagnostics@gmail.com www.parklinediagnostics.com



NABL Accredited
Certificate No. MC-2566

TEST REPORT

Name : Mr . GATTU VENKATA RAMANA [96305]
Age / Gender : 47 Years / Male
Ref.By : Medi Wheel
Req. No : BIL1570773

TID : UMR0617848
Registered on : 11-Dec-2021 08:58 AM
Reported On : 11-Dec-2021 10:05 AM

DEPARTMENT OF X-RAY X-Ray Chest PA View

Lung fields are clear.

Cardia is normal.


Unfolding of aorta.

Hila are normal.

C P angles are free.

Bony cage is normal.

Soft tissues are normal.


Dr. D.J. MOHAN
MD DMRD
(Reg No. 8995)
Consultant Radiologist

The Test marked with*are not accredited by NABL

Lab Timings (Weekdays) : 7.00 am to 8.30 pm
Sundays & Holidays : 7.00 am to 1.00 pm

Radiologists Timings (Weekdays) : 7.30 am to 1.30 pm
& 5.30 pm to 7.45 pm
Sundays & Holidays : 7.30 am to 9.30 am

ID: 1570773

11-12-2021 09:25:34 AM

BPL-12

MR GATTU VENKATA RAMANA

Male 47Years

HR : 61 bpm
P : 107 ms
PR : 141 ms
QRS : 80 ms
QT/QTc : 379/384 ms
P/QRST : 8/25/45 °
RV5/SV1 : 1.511/1.116 mV

NSR
WNL
Ce

Dr. NAVEEN KUMAR .C
M.D., D.M.
Consultant Cardiologist
Reg. No. 52291

Diagnosis Information:
Sinus Rhythm
Normal ECG

Report Confirmed by:

PATIENT SUMMARY REPORT

RKLINE DIAGNOSTICS PVT.LTD

: 1570773
ME : **MR.GATTU VENKATA RAMANA**
E / SEX : 47 / MALE

HEIGHT (cm) : 168
WEIGHT (kg) : 73
PROTOCOL : BRUCE

REF. BY : MEDIWHEEL
DONE BY : DR.NAVEEN KUMAR C
TECHNICIAN : G.M.SURESH

2-2021, 14:16:
C

SE HISTORY :

INDICATION :

OBJECT OF TEST : Routine Check Up.

RISK FACTOR : None.

ACTIVITY : Very Active.

OTHER INVESTIGATION : ECG

REASON FOR TERMINATION : THR ACHIEVED

EXERCISE TOLERANCE : Good (> 10 METS).

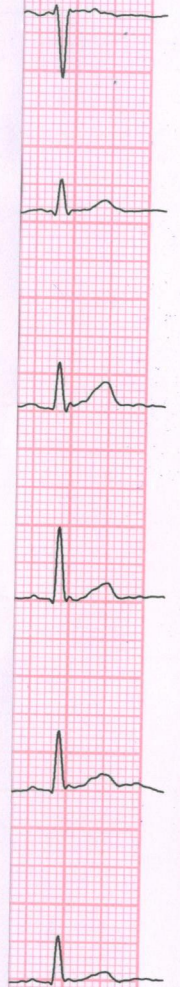
EXERCISE INDUCED ARRHYTHMIAS : No.

STIMULO RESPONSE : Normal.

REPERFUSION RESPONSE : Normal.

GENERAL IMPRESSION :

ADDITIONAL COMMENTS : *negative for inducible ischemia*



Dr. NAVEEN KUMAR .C
M.D., D.M.
Consultant Cardiologist
Reg. No. 52291

Confirmed By : _____

Signature