

# CHIRAG

## IMAGING CENTRE

Opp. Dr. Manke Hospital, Lic Godhra-389001. Ph : 02672-252425



*Date:26/02/2022*

Name:SHABNUM KUMARI 29 Years / Female  
Ref By:DR. DISHA LAB

### X-RAY CHEST (PA VIEW)

Both lung fields appear normal.

No evidence of koch's lesion or consolidation seen.

Both cardiophrenic, costophrenic angles and domes of the diaphragm are normal.


The cardiac size is within normal limit.

Trachea is central, no mediastinal shift is seen .

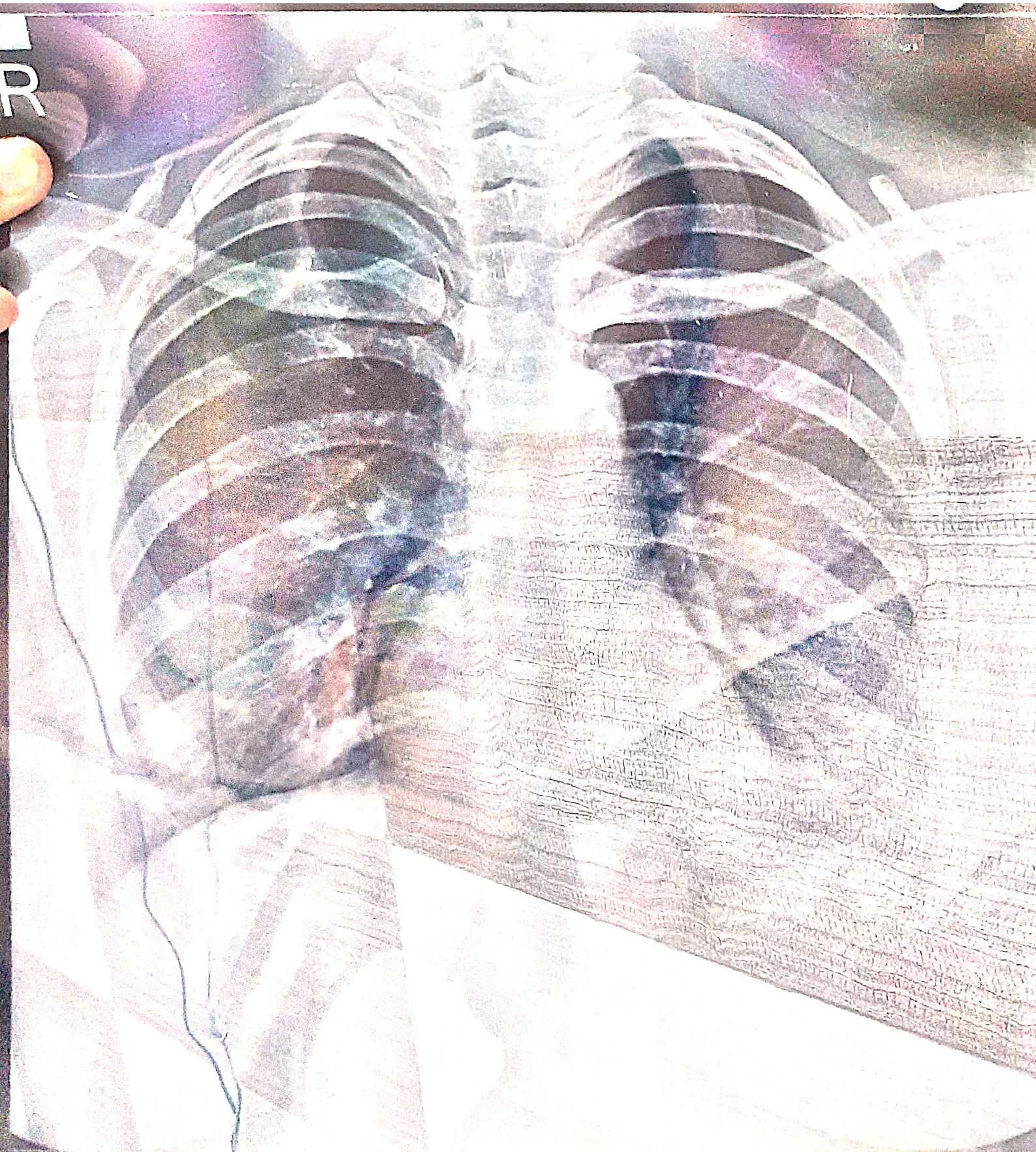
Mediastinal outlines do not show any abnormality.

Bony thorax and soft tissues of the chest wall are normal.

**IMPRESSION: No abnormality noted.**



  
**Dr. Chirag J. Muniya**  
M.D., Radiology  
Reg No. 18177



SHABNUM KUMARI 29 YRS 26022207 DISHA LAB F CHEST PA 26-02-2022 11:35 AM  
CHIRAG IMAGING CENTRE GODHRA, PH NO-02672 252425  
CHIRAG IMAGING CENTRE, GODHARA. PH: (02672)252425

Date:26/02/2022

Name:SHABNUM KUMARI 29 Years / Female  
Ref By:DR. DISHA LAB

### ULTRASOUND WHOLE ABDOMEN

**LIVER:** 140mm in mid axillary line and appears normal in size and in echo pattern.  
No focal intra-hepatic lesion detected. Intra-hepatic biliary radicals are not dilated.  
Portal vein appears normal in course and caliber.

**GALL BLADDER:** Appears distended and appears studded with multiple calculi of average size 3mm.

Posterior wall not seen due to acoustic shadow.

Common Bile duct measures 5mm. No evidence of calculus or mass lesion seen within CBD.

**PANCREAS:** Appears normal in size and echo pattern.

**SPLEEN:** 87mm along long axis and appears normal in size & echo pattern.

#### KIDNEYS:

Right kidney measures 88 X 36 mm and appears normal in position, size and in outline.  
Corticomedullary differentiation maintained. No e/o focal mass lesion.  
No evidence of calculus or hydronephrosis seen.

Left kidney measures 91 X 44 mm and appears normal in position, size and in outline.  
Corticomedullary differentiation maintained. No e/o focal mass lesion.  
No evidence of calculus or hydronephrosis seen.

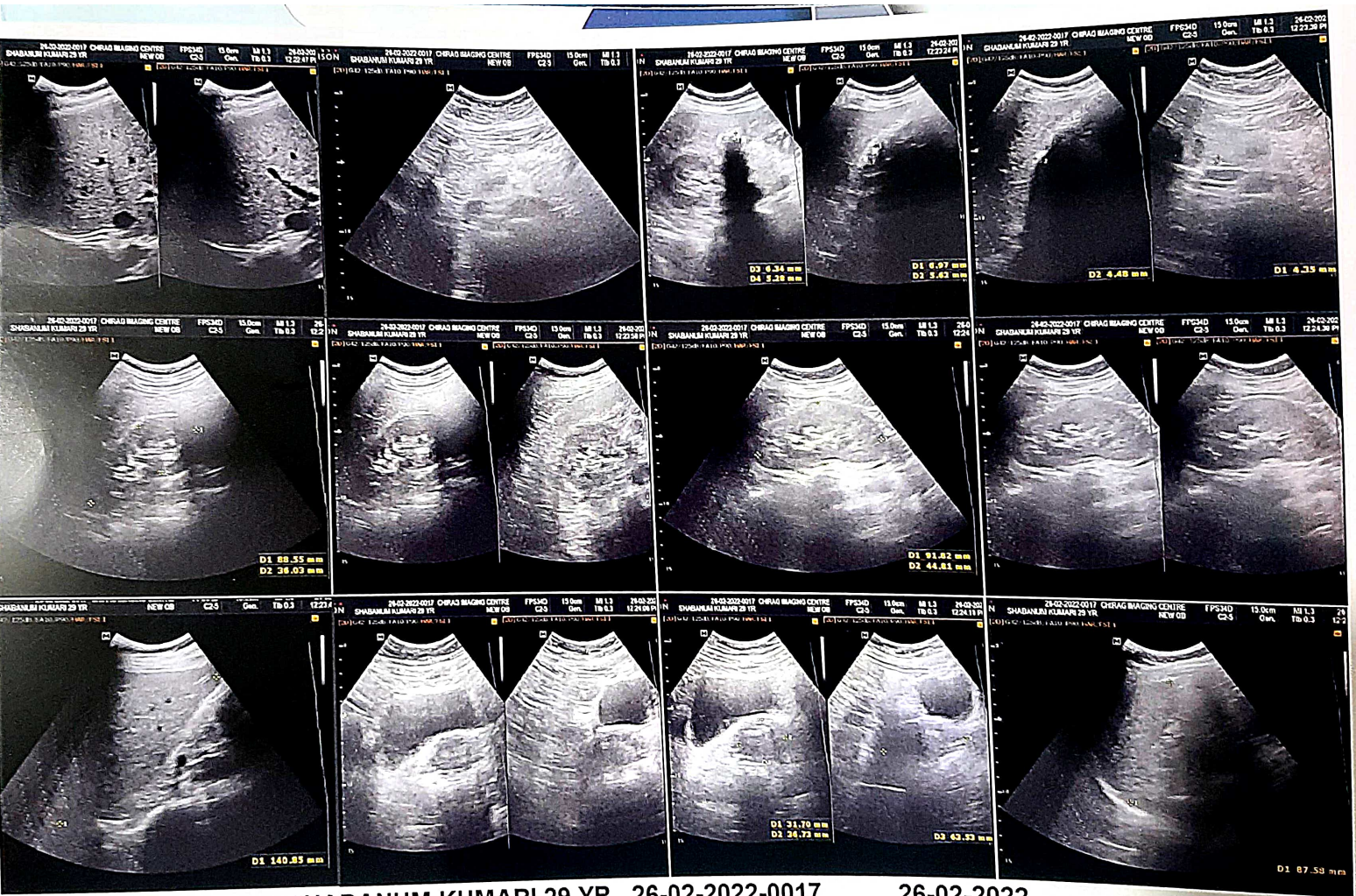
**URINARY BLADDER:** Appears distended with clear contents and wall thickness WNL.  
No evidence of calculus or mass lesion seen.

Uterus is anteverted appears normal in size and measures 31 X 36 X 63mm.  
Endometrium is central and normal in thickness. Myometrial echogenicity appears normal.  
No evidence of adnexal mass lesion seen on either side.  
No free fluid detected in pouch of Douglas and Morrison's pouch.  
Visualized parts of retro peritoneum do not reveal any lymphadenopathy.  
No evidence of abnormal dilatation or wall thickening of bowel loops seen.  
No evidence of collection or mass lesion seen in RIF

**IMPRESSION :** Multiple Gall bladder calculi.



Dr. Chirag J. Muniya  
M.D., Radiology  
Reg No. 18177



SHABANUM KUMARI 29 YR 26-02-2022-0017 26-02-2022  
CHIRAG IMAGING CENTRE