

CLUMAX DIAGNOSTICS

3



--- A MEDALL COMPANY ---

Date 10-Dec-2021 8:20 AM

Complementary breakfast
4th floor

Customer Name : MR.PRAVEEN KUMAR V D

DOB : 10 Jul 1982

Ref Dr Name : MediWheel

Age : 39Y/MALE

Customer Id : MED110794586

Visit ID : 421093656

Email Id : Praveenkumarvakde@gmail.com

Phone No : 9886428086

Corp Name : MediWheel

Address :

Dom V/S - do-2

ht 170
wt 78
BP 130/80 hip 100
Pulse 82 low alt 105

Package Name : Mediwheel Full Body Health Checkup Male Below 40

S.No	Modality	Study	Accession No	Time	Seq	Signature
1	LAB	BLOOD UREA NITROGEN (BUN)				
2	LAB	CREATININE				
3	LAB	GLUCOSE - FASTING				
4	LAB	GLUCOSE - POSTPRANDIAL (2 HRS)				
5	LAB	GLYCOSYLATED HAEMOGLOBIN (HbA1c)				
6	LAB	URIC ACID				
7	LAB	LIPID PROFILE				
8	LAB	LIVER FUNCTION TEST (LFT)				
9	LAB	THYROID PROFILE/ TFT(T3, T4, TSH)				
10	LAB	URINE GLUCOSE - FASTING				
11	LAB	URINE GLUCOSE - POSTPRANDIAL (2 Hrs)				
12	LAB	COMPLETE BLOOD COUNT WITH ESR				
13	LAB	STOOL ANALYSIS - ROUTINE				
14	LAB	URINE ROUTINE				
15	LAB	BUN/CREATININE RATIO				
16	LAB	BLOOD GROUP & RH TYPE (Forward Reverse)				
17	OTHERS	Treadmill / 2D Echo	IND127590014690			

19	US	ULTRASOUND ABDOMEN	IND127590015292			
20	OTHERS	EYE CHECKUP	IND127590017756			
21	X-RAY	X RAY CHEST	IND127590018659			
22	ECG	ELECTROCARDIOGRAM ECG	IND127590018721			
23	OTHERS	Consultation Physician	IND127590018736			

Registered By

(POOJA.SHEKAR)

Customer Name	MR.PRAVEEN KUMAR V D	Customer ID	MED110794586
Age & Gender	39Y/MALE	Visit Date	10/12/2021
Ref Doctor	MediWheel		

X - RAY CHEST PA VIEW

Bilateral lung fields appear normal.

Cardiac size is within normal limits.

Bilateral hilar regions appear normal.

Bilateral domes of diaphragm and costophrenic angles are normal.

Visualised bones and soft tissues appear normal.

IMPRESSION:

➤ **No significant abnormality detected.**

DR. H.K. ANAND
CONSULTANT RADIOLOGISTS
A/da


DR. APARNA



Customer Name	MR.PRAVEEN KUMAR V D	Customer ID	MED110794586
Age & Gender	39Y/MALE	Visit Date	10/12/2021
Ref Doctor	MediWheel		

ABDOMINO-PELVIC ULTRASONOGRAPHY

LIVER is normal in shape, size and has uniform echopattern. No evidence of focal lesion or intrahepatic biliary ductal dilatation. Hepatic and portal vein radicals are normal.

GALL BLADDER shows normal shape and has clear contents. Gall bladder wall is of normal thickness. CBD is of normal calibre.

PANCREAS has normal shape, size and uniform echopattern. No evidence of ductal dilatation or calcification.

SPLEEN shows normal shape, size and echopattern. No demonstrable Para -aortic lymphadenopathy.

KIDNEYS move well with respiration and have normal shape, size and echopattern. Cortico- medullary differentiations are well madeout. No evidence of calculus or hydronephrosis.

The kidney measures as follows:

	Bipolar length (cms)	Parenchymal thickness (cms)
Right Kidney	10.4	1.7
Left Kidney	12.0	1.2

URINARY BLADDER shows normal shape and wall thickness. It has clear contents. No evidence of diverticula.

PROSTATE shows normal shape, size and echopattern. It measures 3.3 x 3.2 x 3.6cms (Vol:19cc).

No evidence of ascites / pleural effusion.

IMPRESSION:

➤ **NO SIGNIFICANT ABNORMALITY DETECTED.**

DR. H.K. ANAND
CONSULTANT RADIOLOGISTS:
A/up



DR. APARNA



39 Years Male

10.12.2021 10.20.37
CLUMAX DIAGNOSTICS
THIRUPASANDRA
BANGALORE

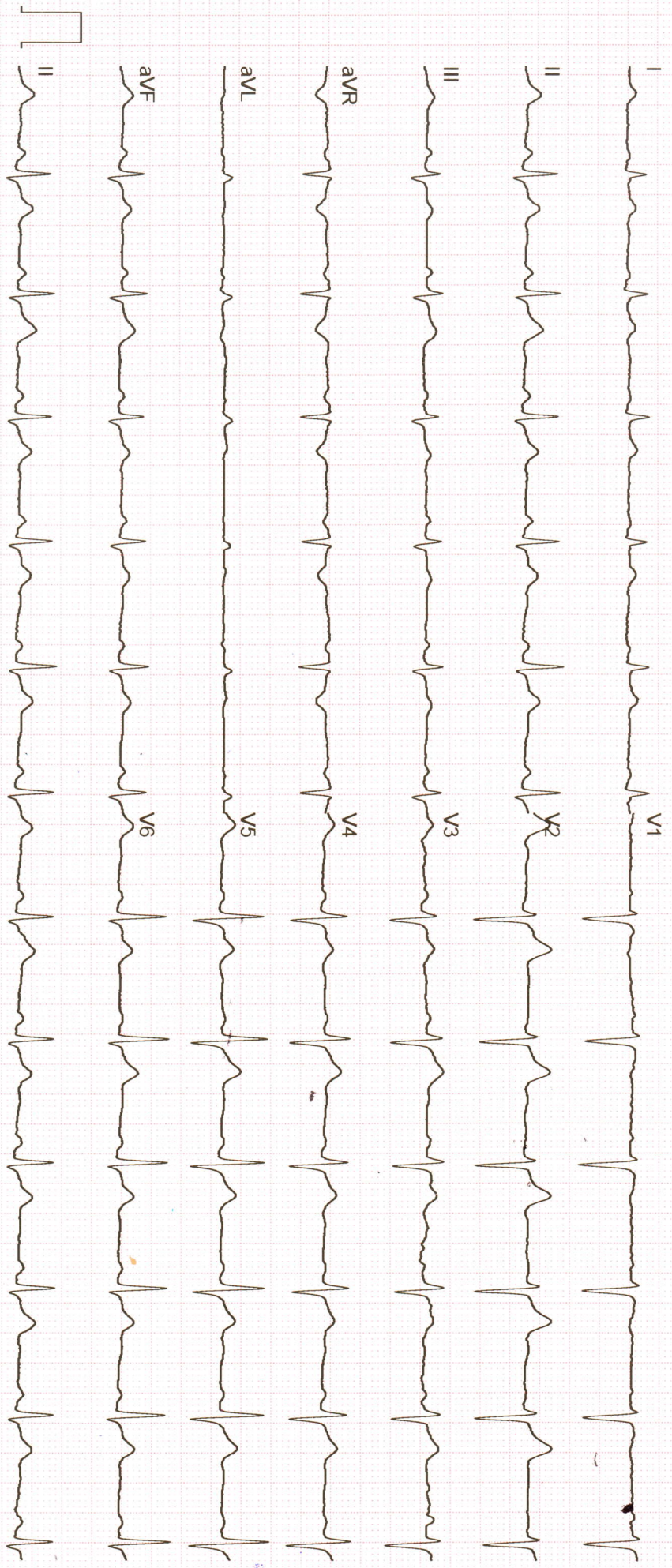
QRS : 94 ms
QT / QTcBaz : 368 / 402 ms
PR : 142 ms
P : 92 ms
RR / PP : 832 / 833 ms
P / QRS / T : 60 / 51 / 54 degrees

Praveen Kumar

U

SUBRAMANIAM K.S.
CLUMAX DIAGNOSTICS
THIRUPASANDRA
BANGALORE

72 bpm
-- / -- mmHg



GE MAC2000 1.1 12SL™ V241 25 mm/s 10 mm/mV ADS 0.56-20 Hz 50 Hz 2x5x6_25_R1 1/1

Unconfirmed

Customer Name	MR.PRAVEEN KUMAR V D	Customer ID	MED110794586
Age & Gender	39Y/MALE	Visit Date	10/12/2021
Ref Doctor	MediWheel		

2 D ECHOCARDIOGRAPHIC STUDY

M mode measurement:

AORTA		: 3.0cms
LEFT ATRIUM		: 3.2cms
AVS		: ----
LEFT VENTRICLE	(DIASTOLE)	: 4.5cms
	(SYSTOLE)	: 3.0cms
VENTRICULAR SEPTUM	(DIASTOLE)	: 1.0cms
	(SYSTOLE)	: 1.4cms
POSTERIOR WALL	(DIASTOLE)	: 1.0cms
	(SYSTOLE)	: 1.2cms
EDV		: 92ml
ESV		: 34ml
FRACTIONAL SHORTENING		: 34%
EJECTION FRACTION		: 63%
EPSS		: ---
RVID		: 1.8cms

DOPPLER MEASUREMENTS:

MITRAL VALVE	: 'E' 0.73 m/s	'A' 0.54 m/s	NO MR
AORTIC VALVE	: 1.06 m/s		NO AR
TRICUSPID VALVE	: 'E' 2.02 m/s	'A' - m/s	NO TR
PULMONARY VALVE	: 0.85 m/s		NO PR



Customer Name	MR.PRAVEEN KUMAR V D	Customer ID	MED110794586
Age & Gender	39Y/MALE	Visit Date	10/12/2021
Ref Doctor	MediWheel		

2D ECHOCARDIOGRAPHY FINDINGS:

Left ventricle : Normal size, Normal systolic function.
No regional wall motion abnormalities.

Left Atrium : Normal.

Right Ventricle : Normal.

Right Atrium : Normal.

Mitral valve : Normal, No mitral valve prolapsed.

Aortic valve : Normal, Trileaflet.

Tricuspid valve : Normal.

Pulmonary valve : Normal.

IAS : Intact.

IVS : Intact.

Pericardium : No pericardial effusion.

IMPRESSION:

- NORMAL SIZED CARDIAC CHAMBERS.
- NORMAL LV SYSTOLIC FUNCTION. EF: 63%.
- NO REGIONAL WALL MOTION ABNORMALITIES.
- NORMAL VALVES.
- NO CLOTS / PERICARDIAL EFFUSION / VEGETATION.

DR. K.S. SUBRAMANI. MBBS, MD, DM (CARDIOLOGY) FESC, FICC
SENIOR CONSULTANT INTERVENTIONAL CARDIOLOGIST
Kss/up

Note:

- * Report to be interpreted by qualified medical professional.
- * To be correlated with other clinical findings.
- * Parameters may be subjected to inter and intra observer variations.

SUBRAMANI.K.S.
MBBS, MD, DM (CARDIOLOGY)
Consultant Interventional Cardiologist
KMC Reg No: 46604
Glumax Diagnostics





ಶ್ರೀ ಪಾರ್ವತಿ ಆಪ್ಟಿಕ್ಸ್

Mahesh
Mob: 8618385220
9901569756

SRI PARVATHI OPTICS

Multi Branded Optical Store

Computerized Eye Testing & Spectacles Clinic

333.8th Main 5th Cross Near Cambridge & Miranda School HAL 3rd Stage
Behind Vishveshvariah Park New Thippasandra, Bangalore - 560075,
Email: parvathiopticals@gmail.com

SPECTACLE PRESCRIPTION

Name: MR. Praveen Kumar

No. 070

Mobil No: 9886428086

Date: 10/12/21

Age / Gender 39Y/M

Ref. No.

	RIGHT EYE				LEFT EYE			
	SPH	CYL	AXIS	VISION	SPH	CYL	AXIS	VISION
DISTANCE	0.75	0.75	125	6/6	0.50	0.75	80	6/6
NEAR								

PD 68mm

Advice to use glasses for:

DISTANCE FAR & NEAR READING COMPUTER PURPOSE

We Care Your Eyes

SRI PARVATHI OPTICS

NEW THIPPASANDRA

(Signature)