

HEALTH CHECKUP REPORT

Patient Name: RAKSH BHRAMBHATT
Age/Gender: 52/M
Reg. No: 390567
Package: MEDIWHEEL

DATE: 26/11/2022

COMPLAINTS (IF ANY):

- Lower back pain

HISTORY OF HEALTH STATUS:

- LSCS

PRESENT MEDICATIONS: No

HYPERSENSITIVITY TO ANY DRUG: No

PERSONAL HISTORY:

- | | | | | | |
|---------------|---|----------|-------------------------------------|---|-----|
| - Bowel | : | Regular | Diet | : | Veg |
| - Micturition | : | Normal | Habits | : | No |
| - Sleep | : | Adequate | Physical Activity/Exercise: Walking | | |
| - Appetite | : | Adequate | | | |

HISTORY OF ILLNESS (WITH PAST MEDICATIONS):

- LMP :- menopause

FAMILY HISTORY:

- Farther :- DM2

VITAL SIGNS:

- | | | | |
|------------|---------|---------|------------|
| - Height : | 157 cms | Pulse : | 74/min. |
| - Weight : | 69 Kgs | B.P.: | 130/68mmHg |

PHYSICIAN CONSULTATION:

1) Clinical Impression

- Pre diabetic
- Subclinical hypothyroidism
- Small fibro abdomen in right Brest

2) Recommendations

- 1 hr walk daily
- Diabetic diet
- FBS, PPBS, HBA1C, TSH after 3 month and follow up
- Healthy life style

(Dr. RASHMI chovatia)

OPHTHALMO CONSULTATION:

RE

LE

Best corrected visual acuity

6/6

6/6

(Dr. Jignesh Shah)

DENTAL CONSULTATION:

Adv:

- Cleaning

(Dr. Parvin Chandarana)

GYNEC CONSULTATION: DONE

Please take regular medicine as prescribed by the Doctor. (If given)





Reg. No : CIMS/A/2022/390567	Visit No : HC/261122/3 [HCV]
Patient Name : Mrs. RAKSHA S BHRAMBHATT	Age(Y-M-D)/Sex : 52 Y 4 M 13 D. / Female
Referring Doctor : Dr. CIMS DOCTOR	Doctor
Ward/Room :	Bed
ORD/261122/341 Lab No : 2022174530 LSN : 937166 (Whole Blood) Sample Quality : Normal	
Collection Time : 26/11/2022 8:15:39 Arrival : 26/11/2022 9:05:40 Validation Time : 26/11/2022 11:19:10AM	

	Result	Unit	Reference Range
CBC With ESR			
TOTAL COUNT			
Hemoglobin <i>(SLS Hemoglobin Detection method)</i>	13	g/dl	12.5 - 15.0 g/dl
Total RBC Count <i>(Hydro Dynamic Focusing Method)</i>	4.75	mill/Cmm	4.2 - 5.4 mill/Cmm
HCT <i>(Hydro Dynamic Focusing Method)</i>	39.6	%	37 - 47 %
Total WBC Count <i>(Flow Cytometry)</i>	7390	/Cmm	4000 - 10500 /Cmm
Platelet Count <i>(Hydro Dynamic Focusing Method)</i>	301000	/Cmm	150000 - 450000 /Cmm
DIFFERENTIAL COUNT (by Flow Cytometry)			
Polymorphs	65	%	40 - 70 %
Lymphocytes	28	%	22 - 45 %
Eosinophils	01	%	01 - 04 %
Monocytes	06	%	01 - 06 %
Basophils	00	%	00 - 01 %
Immature Granulocytes	00	%	0 - 2 %
Smear Study	RBCs are Normochromic & Normocytic. Platelets are adequate in number. Malarial Parasites are not seen. No Premature cells are seen.		
BLOOD INDICES (by Calculated Method)			
M.C.V	83.4	fl	78 - 100 fl
M.C.H	27.4	pg	27 - 31 pg
M.C.H.C.	32.8	gm/dl	32 - 36 gm/dl
RDW-CV	13	%	11.5 - 14.0 %
ESR (Red Cell Aggregation)			
After One Hour	45	mm	0 - 19 mm
Blood Group Rh			
ABO	"B"		

(Signature)

Dr. Shreya Patel
MD(Path)
Consultant Pathologist

Dr. Manisha Shah
MD (Path & Bact)
Consultant Pathologist
Reg. No. : G-15496

Dr. Jitendra Nayak
MD (Path)
Consultant Pathologist
Reg. No. : G-14786





**Marengo CIMS
Hospital**

Reg. No : CIMS/A/2022/390567

Patient Name : Mrs. RAKSHA S BHRAMBHATT

Referring Doctor : Dr. CIMS DOCTOR

Ward/Room :

Visit No : HC/261122/3 [HCV]

Age(Y-M-D)/Sex : 52 Y 4 M 13 D. / Female

Doctor :

Bed :

ORD/261122/341 Lab No : 2022174530

LSN : 937166 (Whole Blood)

Sample Quality : Normal

Collection Time : 26/11/2022 8:15:39

Arrival : 26/11/2022 9:05:40

Validation Time: 26/11/2022 11:19:10AM

Rh POSITIVE

HbA1c (Glycosylated Haemoglobin)

TEST

HbA1c (Glyoco Hb)
(Immuno Turbidimetric)

6.38

%

4.8-5.9% Normal

5.9-7.0% Good diabetic control

7.0-10.0% Fair diabetic control

>10.0% Poor diabetic control

Mean Plasma Glucose

150


mg/dL

80 - 140 mg/dL

*** END OF REPORT ***

Dr. Manisha Shah
MD (Path & Bact)
Consultant Pathologist
Reg. No. : G-15495

Dr. Jitendra Nayak
MD (Path)
Consultant Pathologist
Reg. No. : G-14786


Dr. Shreya Patel
MD(Path)
Consultant Pathologist



CIMS Hospital Private Limited

Plot No 67/1, Opp. Panchamrut Bungalows, Near Shukan Mall, Off Science City Road, Sola, Ahmedabad - 380060, Gujarat

☎ 1800 309 9999 CIN No. U85110GJ2001PTC039962

Print By : anvita rajput



Reg. No : CIMS/A/2022/390567	VisitNo : HC/261122/3 [HCV]
Patient Name : Mrs. RAKSHA S BHRAMBHATT	Age(Y-M-D)/Sex : 52 Y 4 M 13 D. / Female
Referring Doctor : Dr. CIMS DOCTOR	Doctor
Ward/Room	Bed

ORD/261122/341 Lab No : 2022174531 LSN : 937166 (SERUM) Sample Quality : Normal
 Collection Time : 26/11/2022 8:15:39 Arrival : 26/11/2022 9:05:40 Validation Time : 26/11/2022 11:11:13AM

Liver Function Test

100% PATIENT SATISFACTION GUARANTEED

	<u>Result</u>	<u>Unit</u>	<u>Reference Range</u>
Alkaline Phosphatase <i>(PNPP, AMP Buffer Method, Colorimetric)</i>	139.7	U/L	35 - 104 U/L
Billirubin			
Total Billirubin <i>(Diazospecial Iazonium Iron with Blank)</i>	0.37	mg/dL	0.0 - 1.0 mg/dL
Direct Billirubin <i>(Diaso. Evelyn Malloy) with Blank)</i>	0.17	mg/dL	0.0 - 0.2 mg/dL
Indirect Billirubin <i>(Calculated from Total and Direct Billirubin)</i>	0.2	mg/dL	0.0 - 0.8 mg/dL
SGPT (ALT) <i>(IFCC without pyridoxal phosphate)</i>	21	U/L	0 - 33 U/L
SGOT (AST) <i>(IFCC without pyridoxal 5 phosphate)</i>	21.5	U/L	0 - 32 U/L
Total Protein			
Total Proteins <i>(Biuret Method)</i>	8.17	gm/dl	6.4 - 8.3 gm/dl
Albumin <i>(Bromocresol Green Colorimetric)</i>	4.54	gm/dl	3.97 - 4.95 gm/dl
Globulin	3.63	gm/dl	2.2 - 3.5 gm/dl
A/G Ratio	1.25		0.9 - 2.1

Dr. Shreya Patel
MD(Path)
Consultant Pathologist



Dr. Manisha Shah
MD (Path & Bact)
Consultant Pathologist
Reg. No. : G-15496

Dr. Jitendra Nayak
MD (Path)
Consultant Pathologist
Reg. No. : G-14786

CIMS Hospital Private Limited

Plot No 67/1, Opp. Pancharrud Bunglows, Near Shukari Mall, Off Science City Road, Sola, Ahmedabad - 380060, Gujarat

© 1800 309 9999 CIN No. U8510GJ2001PTC039962

Print By : ankita rainut



**Marengo CIMS
Hospital.**

cims.org


Reg. No : CIMS/A/2022/390567	VisitNo : HC/261122/3 [HCV]
Patient Name : Mrs. RAKSHA S BHRAMBHATT	Age(Y-M-D)/Sex : 52 Y 4 M 13 D. / Female
Referring Doctor : Dr. CIMS DOCTOR	Doctor
Ward/Room :	Bed
ORD/261122/341 Lab No : 2022174531 LSN :937166 (SERUM)	Sample Quality : Normal
Collection Time :26/11/2022 8:15:39 Arrival : 26/11/2022 9:05:40	Validation Time: 26/11/2022 11:11:12AM

	<u>Result</u>	<u>Unit</u>	<u>Reference Range</u>
Creatinine <i>(Buffered Jaffe Reaction Kinetic Compensated)</i>	0.74	mg/dL	0.6 - 0.9 mg/dL
Estimated GFR	96.87	mL/min/1.73m2	50 - 102 mL/min/1.73m2
Fasting Glucose <i>(Hexokinase)</i>	<u>112.2</u>	mg/dL	70 - 100 mg/dL
Thyroid Function Test			
TOTAL T3 (T3) * <i>(Electrochemiluminescence Assay)</i>	1.04	ng/ml	0.846 - 2.02 ng/ml
TOTAL T4 (T4) * <i>(Electrochemiluminescence Assay)</i>	6.93	µg/dl	5.13 - 14.06 µg/dl
TSH <i>(Electrochemiluminescence Assay)</i>	5.63	µIU/ml	0.27- 4.20 µIU/ml
Uric Acid <i>(Uricase Colorimetric Enzymatic)</i>	4.95	mg/dL	2.4 - 5.7 mg/dL

*** END OF REPORT ***

Dr. Manisha Shah
MD (Path & Bact)
Consultant Pathologist
Reg. No. : G-15496

Dr. Jitendra Nayak
MD (Path)
Consultant Pathologist
Reg. No. : G-14786


Dr. Shreya Patel
MD (Path)
Consultant Pathologist



CIMS Hospital Private Limited

Plot No 67/1, Opp. Panchamrut Bunglows, Near Shukan Mall, Off Science City Road, Sola, Ahmedabad - 380060, Gujarat

☎ 3800 309 9999 CIN No. U85110GJ2001PTC039962



**Marengo CIMS
Hospital**

Reg. No : CIMS/A/2022/390567	VisitNo : HC/261122/3 [HCV]
Patient Name : Mrs. RAKSHA S BHRAMBHATT	Age(Y-M-D)/Sex : 52 Y 4 M 13 D. / Female
Referring Doctor : Dr. CIMS DOCTOR	Doctor
Ward/Room	Bed

ORD/261122/341 Lab No : 2022174532 LSN : 937166 (SERUM) Sample Quality : Normal
 Collection Time : 26/11/2022 8:15:39 Arrival : 26/11/2022 9:05:40 Validation Time: 26/11/2022 11:19:24AM


	<u>Result</u>	<u>Unit</u>	<u>Reference Range</u>
BUN* (Ureas with UV)	9.0	mg/dL	6 - 20 mg/dL

*** END OF REPORT ***

P&D H/OLOGY REPORTS

Dr. Manisha Shah
MD (Path & Bact)
Consultant Pathologist
Reg. No. : G-15496

Dr. Jitendra Nayak
MD (Path)
Consultant Pathologist
Reg. No. : G-14786


Dr. Shreya Patel
MD(Path)
Consultant Pathologist





Marengo CIMS Hospital

cims.org

Reg. No : CIMS/A/2022/390567	Visit No : HC/261122/3 [HCV]
Patient Name : Mrs. RAKSHA S BHRAMBHATT	Age(Y-M-D)/Sex : 52 Y 4 M 13 D, / Female
Referring Doctor : Dr. CIMS DOCTOR	Doctor :
Ward/Room :	Bed :

ORD/261122/341 Lab No : 2022174531 LSN : 937166 (SERUM) Sample Quality : Normal
 Collection : 26/11/2022 8:15:39AM Arrival: 26/11/2022 9:06:45 Validation Time 26/11/2022 11:08:33

<u>Lipid Profile (With Direct LDL)</u>	<u>Result</u>	<u>Unit</u>	<u>Reference Range</u>
Type of Sample	: Fasting		
Cholesterol <i>(Enzymatic/Colorimetric, Cholesterol Oxidase, Esterase, Peroxidase Gen.2)</i>	: 190.8	mg/dL	Less than 160 mg/dl Excellent Less than 200 mg/dl Desirable 200-239 mg/dl Borderline High 240 mg/dl & over High
Triglyceride <i>(Enzymatic Colorimetric without Glycerol Blank without Serum Blank)</i>	: 129.8	mg/dL	Less than 150 mg/dl Normal 150 - 199 mg/dl Borderline High 200-499 mg/dl High 500 mg/dl or greater Very High
HDL Cholesterol <i>(Direct Measured Homogenous Technique Modified Enzymatic Colorimetric Gen. 3)</i>	: 43	mg/dL	Less than 40 mg/dl Low 60 mg/dl or above Excellent
LDL Cholesterol (DIRECT) <i>(Homogenous Enzymatic colorimetric Assay)</i>	: 136.3 <i><130</i>	mg/dL	Less than 80 mg/dl Excellent Less than 100 mg/dl Optimal 100 - 129 mg/dl Near or above optimal 130 - 159 mg/dl Borderline High 160 - 189 mg/dl High 190 mg/dl & above Very High
VLDL Cholesterol <i>(Calculated)</i>	: 25.96	mg/dL	18 - 30 mg/dL
Cholesterol/HDL Ratio <i>(Calculated)</i>	: 4.44		Normal upto 4.5
LDL/HDL Ratio <i>(Calculated)</i>	: 3.17		Less than 3.5

Remarks :



Dr. Shreya Patel
MD(Path)
Consultant Pathologist

Dr. Manisha Shah
MD (Path & Bact)
Consultant Pathologist
Reg. No. : G-15496

Dr. Jitendra Nayak
MD (Path)
Consultant Pathologist
Reg. No. : G-14786





**Marengo CIMS
Hospital**

CIMS.org


Reg. No : CIMS/A/2022/390567	VisitNo : HC/261122/3 [HCV]
Patient Name : Mrs. RAKSHA S BHRAMBHATT	Age(Y-M-D)/Sex : 52 Y 4 M 13 D. / Female
Referring Doctor : Dr. CIMS DOCTOR	Doctor
Ward/Room :	Bed
ORD/261122/341 Lab No : 2022174628 LSN : 937166 (Urine)	Sample Quality : Normal
Collection Time : 26/11/2022 9:51:58 Arrival : 26/11/2022 9:55:57	Validation Time : 26/11/2022 11:08:35AM

	Result	Unit	Reference Range
Urine R & M			
PHYSICAL EXAMINATION			
Quantity	20 cc		
Colour	Pale Yellow		
Transperancy	Clear		
Reaction	5.0		
(QDS-10 Strip)			
Sp. Gravity	1.015		1.005 - 1.035
(QDS-10 Strip)			
CHEMICAL EXAMINATION			
U. Albumin	Nil		
(QDS-10 Strip/Manual)			
U. Glucose	Nil		
(QDS-10 Strip/Manual)			
U. Acelone	Absent		
(QDS-10 Strip/Manual)			
BS/BP	Absent		
(QDS-10 Strip/Manual)			
MICROSCOPIC EXAMINATION			
Pus Cell	Occasional	/H.P.F.	/H.P.F.
Red Blood Cell	Nil	/H.P.F.	/H.P.F.
Epithelial Cell	1-2	/H.P.F.	/H.P.F.
Cast	Not Seen		
Crystals	Not Seen		
Amorphous	Absent		
Monilia	Absent		

*** END OF REPORT ***

Dr. Manisha Shah
MD (Path & Bact)
Consultant Pathologist
Reg. No. : G-15496

Dr. Jitendra Nayak
MD (Path)
Consultant Pathologist
Reg. No. : G-14786


Dr. Shreya Patel
MD(Path)
Consultant Pathologist



CIMS Hospital Private Limited

Plot No 67/1, Opp. Panchamrut Bungalows, Near-Shukan Mall, Off Science City Road, Sola, Ahmedabad - 380060, Gujarat

☎ 1800 509 9999 CIN No. U8510GJ2001PTC039962

Print By : ankita rajput

Name : Mrs. RAKSHA S
BHRAMBHATT
Reg No : CIMS/A/2022/390567
DoB /Sex : 13/07/1970 / Female

ECHO Report

Dt : 26/11/2022

Patient Details

Patient ID : 321885
Name : Mrs. RAKSHA S BHRAMBHATT
Age : 52 Years
Gender : Female
Blood Group :
Referral Doctor :

ECHO Identification Detail

Doctor Incharge : Dr. VIPUL KAPOOR
Clinical Status Of Patient :
ECHO Code : RP
Finding Description :
1. Normal cardiac chambers dimensions.
2. Normal LV systolic function, LVEF: 55-60%.
3. No significant RVMA.
4. Stage I diastolic dysfunction.
5. All cardiac valves are structurally normal.
6. Mild MR, Mild TR, Trivial PR, No AR.
7. Mild PAH, RVSP: 37 mmHg.
8. No clob/vegetation/pericardial effusion.

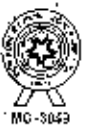Dr. VIPUL KAPOOR



ISE (ISE)



NABH



MO-3043

HUMAN ACCREDITED INSTITUTION

CIMS Hospital Private Limited

Plot No 57/1, Opposite Panchmurt Bungalows Near Shakun Mall, Off Science City Road, Sola, Ahmedabad, Gujarat 380060

☎ : 800 309 9999 CIN No. U85110GJ2001PTC039962

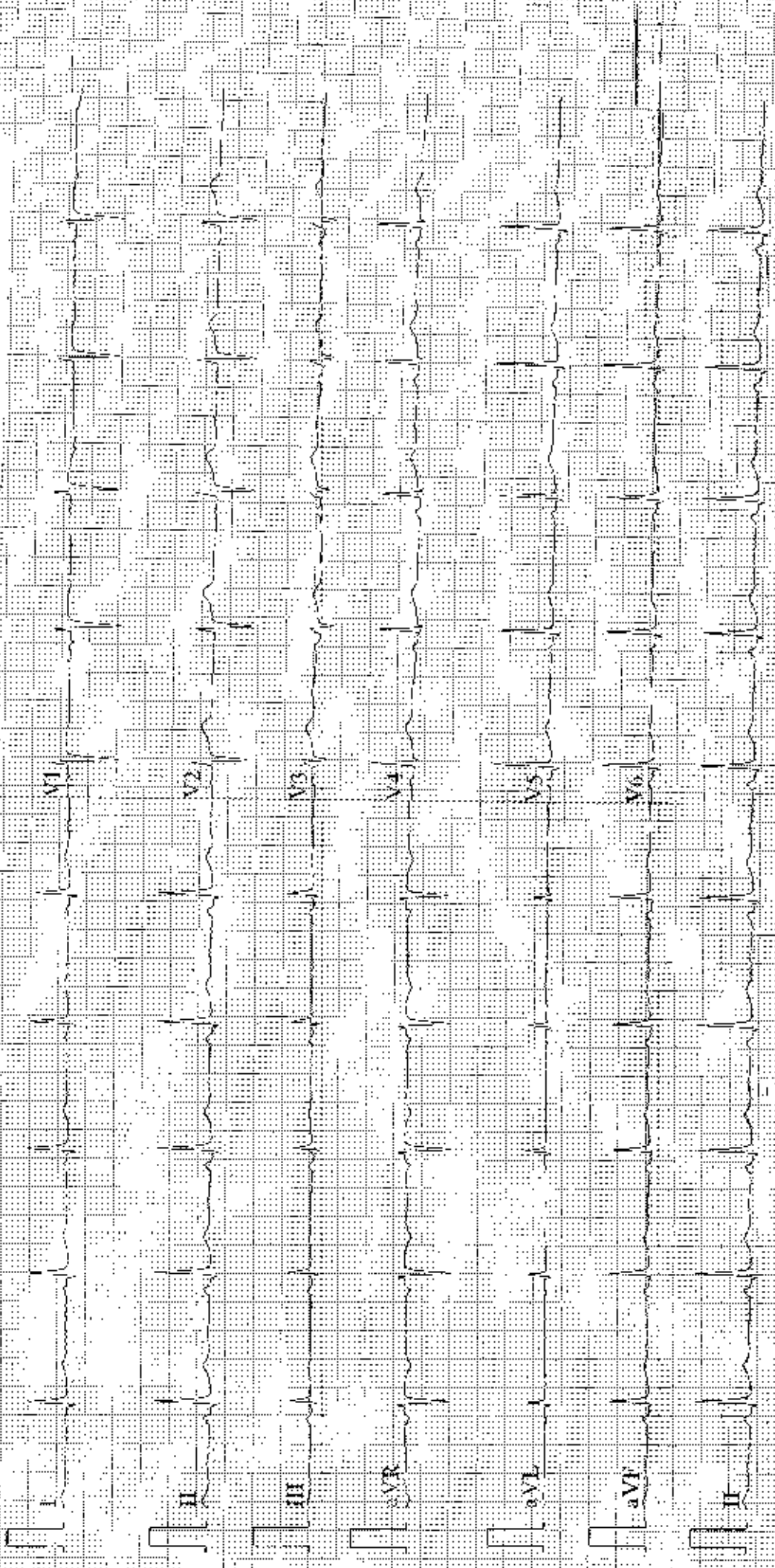
HR 64 bpm
 P 85 ms
 PR 128 ms
 QRS 82 ms
 QT/QTc 383/398 ms
 T/QTc 171/163 ms
 RV5/SV1 1.020/0.864 mV

Diagnosis Inform on

Name : Mrs. RAKSHA S
 SHRAMBHATT
 Reg No : CIMS/A/2022/320567
 DoB /Sex : 13/07/1970 / : male

NSR / wNL

Report Confirmed by



Patient's Name : RAKSHA S BHRAMBHATT	Age, Sex : 52Y/F
Reg. No. (IP/OP): HC-390567	Date : 26/11/2022
Referred By Dr. : CIMS	

BILATERAL MAMMOGRAPHY:

Bilateral mammogram has been obtained using a low radiation dose film screen technique in the craniocaudal and oblique projections. Film markers are in the axillary / lateral portions of both breasts.

Both breasts reveal mixed fatty and fibroglandular parenchyma.
Presence of a low-density circumscribed small opacity noted in medial central quadrant of right breast.

No obvious evidence of focal spiculated mass lesion, retraction of tissues or clusters of micro calcification.

No definite evidence of skin thickening seen.

SONOMAMMOGRAPHY:

- A well-defined hypoechoic lesion measuring 7x2x5mm sized noted in right breast at 4 o'clock position, likely fibroadenoma.
- No evidence of any other solid or cystic mass lesion in either breast.
- No evidence of axillary lymphadenopathy on either side.

CONCLUSION: Appearances suggest,

- Circumscribed small solid cyst in right breast at 4 o'clock position, likely fibroadenoma.

BI-RADS Assessment Categories: Category 3: probably benign. Ultrasound follow up is suggested after 3-6 months.



DR KIRTAN SHAH M.D. RADIOLOGIST CONS. RADIOLOGIST	DR DEEPA SHAH M.D., D.M.R.E CONS. RADIOLOGIST	DR UMA MEHTA D.M.R.D. F.R.C.R CONS. RADIOLOGIST	DR NIMISH SHARMA D.M.R.D. (D.N.B.) CONS. RADIOLOGIST	DR RAVINA CHAUHAN M.D. RADIOLOGIST CONS. RADIOLOGIST	DR YASH PATEL M.D., D.N.B. CONS. RADIOLOGIST	DR SUNALI DESAI MD, DNB, DM, FRCR CONS. RADIOLOGIST NEURORADIOLOGIST
---	---	---	--	--	--	--

Note: This is only a radiological impression and not the final diagnosis. All diagnostic modalities have their own limitations. Therefore radiological modality report should be interpreted in correlation with clinical and pathological findings.

BI-RADS Assessment Categories: (0=Requires additional evaluation, 1=Negative, 2=Benign findings, 3=Probably benign findings, 4=Suspicious abnormality, 5=Highly suggestive of malignancy)

NOTE: False negative rate of mammography is approximately 10%. Management of a palpable abnormality must be based on clinical grounds. If you detect a lump or any other change in your breast before your next screening mammogram, consult your doctor immediately.



CIMS Hospital Private Limited

Plot No 67/1, Opp. Panchamrut Bungalows, Near Shukan Mail, Off Science City Road, Sola, Ahmedabad - 380060, Gujarat

☎ 800 309 9999 CIN No. U85110GJ2001PTC039962

FOR RADIOLOGY REPORTS ONLY

Patient's Name : RAKSHA S BHRAMBHATT	Age, Sex : 52Y/F
Reg. No. (IP/OP): HC-390567	Date : 26/11/2022
Referred By Dr. : CIMS	

USG OF ABDOMEN & PELVIS

LIVER: Liver is normal in size and echotexture. No evidence of focal SOL or dilatation of IHBR seen. Porta hepatis appear normal.

GALLBLADDER: Gallbladder appeared normal. No calculus or mass lesion seen.

PANCREAS: Visualised pancreas appeared normal in size and echotexture. No focal lesion, mass or pancreatitis.

SPLEEN: Spleen appears normal in size and echotexture.

PARAAORTIC REGION: Aorta grossly appeared normal. No paraaortic lymphnodes seen.

KIDNEYS: Both kidneys appear normal in size, shape and in position.

Cortex and collecting system of both kidneys appeared normal.

No evidence of calculus or obstructive uropathy on either side.

Right kidney: 96x34mm. Left kidney: 94x37mm.

URINARY BLADDER: Bladder is partially filled and appeared normal. No calculus or mass lesion is seen.

UTERUS: Uterus appears postmenopausal in status.

Endometrial thickness appears normal.

No fibroid seen.

No adnexal mass lesion seen on either side.

No evidence of free fluid or collection is seen in peritoneal spaces.

Normal small bowel peristalsis noted.

COMMENTS:

- No significant abnormality detected.

Kindly correlate clinically.

DR KIRTAN SHAH M.D. RADIOLOG. CONS. RADIOLOGIST	DR DEEPA SHAH M.D., D.M.R.E CONS. RADIOLOGIST	DR UMA MEHTA D.M.R.D. F.R.C.R CONS. RADIOLOGIST	DR NIMISH SHARMA D.M.R.D. (D.N.B.) CONS. RADIOLOGIST	DR RAVINA CHAUHAN M.D. RADIOLOG. CONS. RADIOLOGIST	DR YASH PATEL M.D., D.N.B. CONS. RADIOLOGIST	DR SUNALI DESAI MD, DNB, DM, FRCR CONS. RADIOLOGIST-NEURORADIOLOGIST
---	---	---	--	--	--	--

Note: This is only a radiological impression and not the final diagnosis. All diagnostic modalities have their own limitations. Therefore radiological modality report should be interpreted in correlation with clinical and pathological findings.

FOR RADIOLOGY REPORTS ONLY



Patient's Name : RAKSHA S BHRAMBHATT	Age, Sex : 52Y/F
Reg. No. (IP/OP): HC-390567	Date : 26/11/2022
Referred By Dr. : CIMS	

Plain Skiagram of Chest PA Standing View:
 (Serial No-B-6743)

Respiratory blur.

Both lung fields appear normal.

No evidence of pleural effusion or pneumothorax is seen on either side.

Mediastinal shadow appears normal.

Heart size and aorta appear normal.

Domes of diaphragm appear normal.

Degenerative changes are seen in visualized spine.

Kindly correlate clinically.



DR KIRTAN SHAH M.D. RADIOLOGIST CONS. RADIOLOGIST	DR DEEPA SHAH M.D., D.M.R.E CONS. RADIOLOGIST	DR UMA MEHTA D.M.R.D. F.R.C.R CONS. RADIOLOGIST	DR NIMISH SHARMA D.M.R.D. (D.N.B.) CONS. RADIOLOGIST	DR RAVINA CHAUHAN M.D. RADIOLOGIST CONS. RADIOLOGIST	DR YASH PATEL M.D., D.N.B. CONS. RADIOLOGIST	DR SUNALI DESAI MD, DNB, DM, FRCR CONS. RADIOLOGIST NEURORADIOLOGIST
---	---	---	--	--	--	--

Note: This is only a radiological impression and not the final diagnosis. All diagnostic modalities have their own limitations. Therefore radiological modality report should be interpreted in correlation with clinical and pathological findings.

FOR RADIOLOGY REPORTS ONLY

