

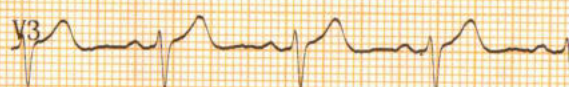
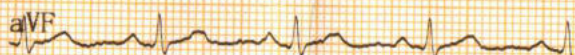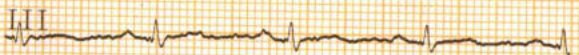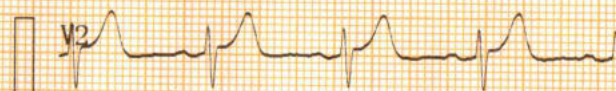
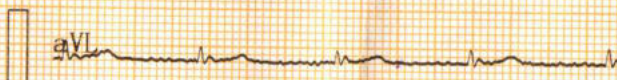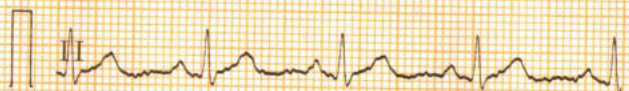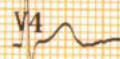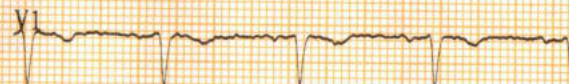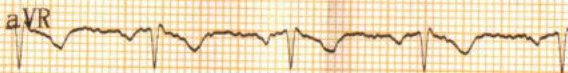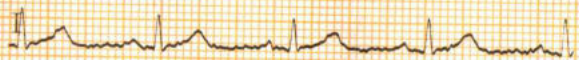BPL

AUTO 10mm/mV

10mm/mV

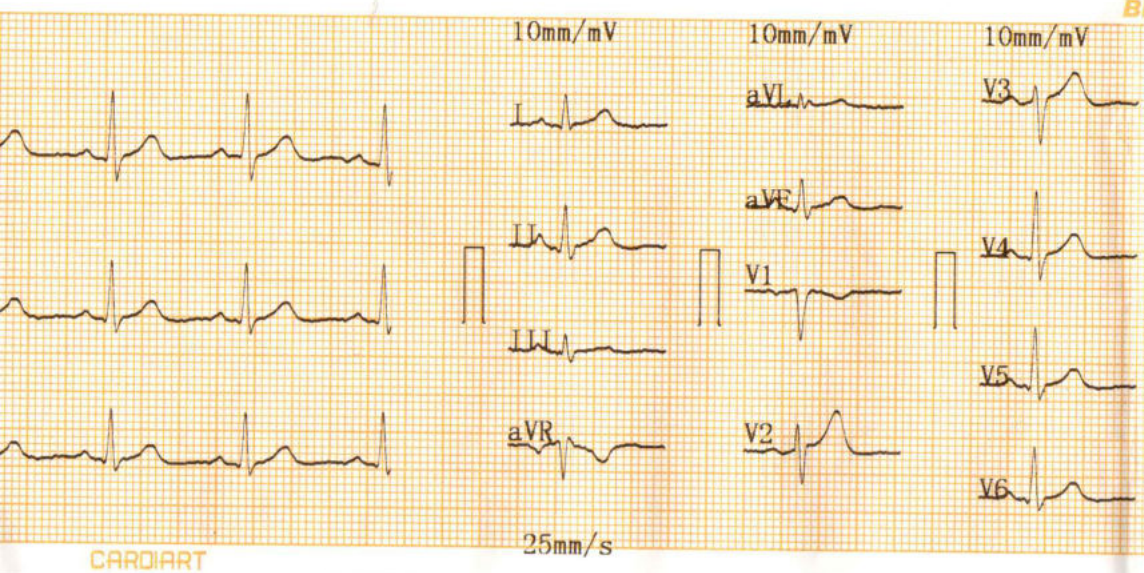
10mm/mV

10mm/mV



25mm/s AC50Hz+EMG35Hz+DFT

051012V8



BPL

2022-03-30 11:19

<< Conclusions >>

ID :  
 Name : **VINAY Kumar BOB**  
 Sex : **M** Age : **48**  
 Height : \_\_\_\_\_ Weight : \_\_\_\_\_ kg  
 SYS : \_\_\_\_\_  
 DIA : \_\_\_\_\_

Normal Sinus Rhythm.  
 Cardiac electric axis normal.  
 \*\*Report need physician confirm\*\*

HR : 83 bpm  
 PR Interval : 174 ms  
 P Duration : 120 ms  
 QRS Duration : 76 ms  
 T Duration : 167 ms  
 QT/QTc : 309/364 ms  
 P/QRS/T Axis : 63.7/40.6/47.5 deg  
 R(V5)/S(V1) : 0.79/0.66 mV  
 R(V5)+S(V1) : 1.45 mV

*Pallavi*  
**DR. PALLAVI MISHRA**  
 MBBS, MD (GENERAL MEDICINE)  
 MCI Reg. No. 52033

Physician \_\_\_\_\_

CARDIART



Call Now - 1800-123-3070

# PANACEA HOSPITAL

*A shelter for many hearts A Home for many lives*

(An ISO 9001:2008 Certified Organisation)

Lab Attached with CMC Vellore Under EQAS Scheme

PATIENT'S NAME : MR.VIJAY KUMAR AGE/SEX: 48 Y/M  
REF. BY : Dr. ASHUTOSH MISHRA(MD) Friday, March 31, 2023

## Echo - Cardiography

MITRAL VALVE Doppler	AML - normal morphology MV Flow - E - 0.7 A-0.5 E/A=1.54	PML - normal morphology MVA - 3.0 cm <sup>2</sup> Mitral Regurgitation - <b>No</b>
TRICUSPID VALVE Doppler	Normal TV Flow -No	Tricuspid Regurgitation - <b>No</b>
PULMONARY VALVE Doppler	Normal PV Flow -No	Pulmonary Regurgitation - No
AORTIC VALVE Doppler	Trileaflet-No AV Flow - no	Aortic Regurgitation - no
MEASUREMENT	Aorta - 29.1 (20-38) mm IVS ed - 12.0 (6 -12) mm LVID ed -36.6 (35 - 55) mm LVPW ed - 9.7 (6 -12) mm OA - 7 (> 5) mm	LA - 32.0 (24-32) mm IVS es -14.3 (6 - 12) mm LVID es - 26.8 (24 - 40) mm LVPW es -12.8 (6 -12) mm EPSS - 4 (< 9) mm

CONCLUSION All cardiac chamber dimensions are WNL  
No valvular abnormalities  
Normal LV systolic function present Modified Simpson's method (4C, 2C) (LVEF=53%)  
No diastolic dysfunction present (E/A = 1.54) by tissue Doppler (E/e'=6.2)  
No RWMA  
No pericardial effusion  
Intact IAS / IV  
No PAH  
No intra cardiac mass /thrombus /vegetation

IMPRESSION **Normal Echocardiogram**

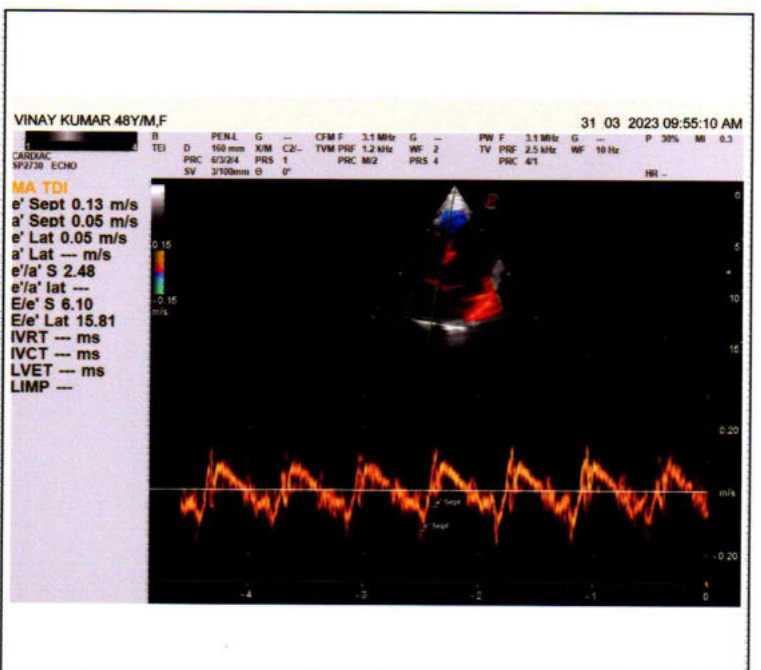
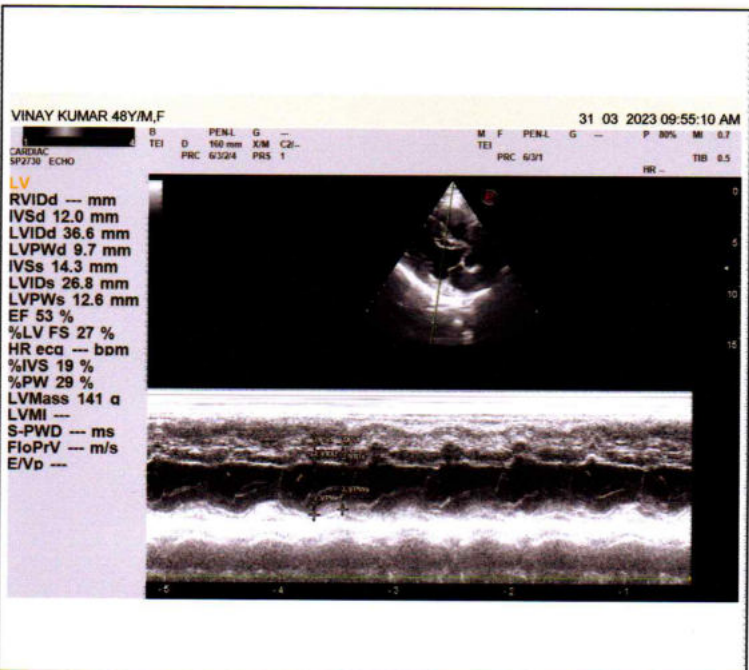
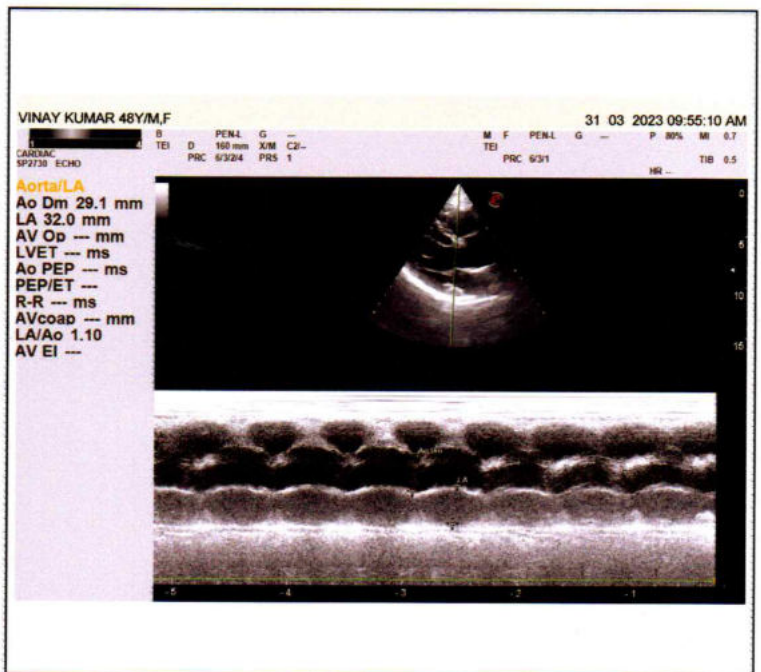
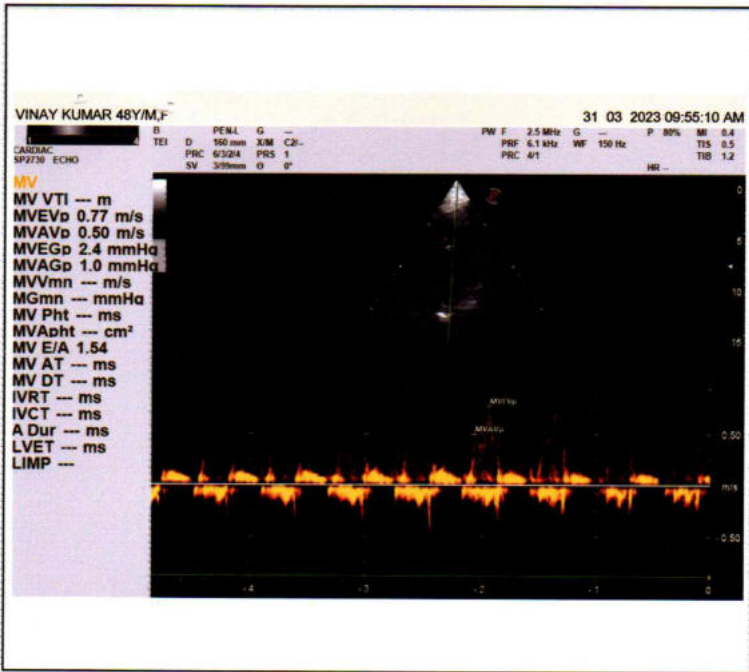
  
Niraj Mishra  
Physician Assistant  
(PIIRE)

Dr. Pallavi Mishra  
MBBS, MD (MED) Lucknow  
Echocardiography Specialist, MIAE  
Non-invasive cardiologist  
Women Cardiologist  
Diabetocardiologist

Address : Kabir Nagar (Near Sanjay Shiksha Niketan), Durgakund, Varanasi

Mobile : 9554572190 / 9453837595 / Recpn. 9389994334

E-mail : dramishra@gmail.com, drpallaviojha@gmail.com, Website: www.piire.org





Call Now - 1800-123-3070

# PANACEA HOSPITAL

*A shelter for many hearts A Home for many lives*

(An ISO 9001:2008 Certified Organisation)

Lab Attached with CMC Vellore Under EQAS Scheme

PATIENT'S NAME : VINAY KUMAR AGE/SEX: 48 Y/M  
REF. BY : Dr. ASHUTOSH MISHRA(MD) Friday, March 31, 2023

## U/S. WHOLE ABDOMEN

- LIVER** : Liver is normal in size(12.2 cm), shape & echotexture. Intra hepatic biliary radicals are normal. Portal venous channels are normal.
- G. B.** : Gall bladder is normal in size, lumen is clear. Wall thickness normal.
- C.B.D.** : C.B.D. is normal in caliber.
- PANCREAS** : Pancreas is normal in size, shape and echotexture. No evidence of any inflammatory disease or mass.
- SPLEEN** : Spleen is normal in size, shape and echotexture.
- Rt. KIDNEY** : Normal in size, shape and echotexture. Renal sinus is normal  
Cortico medullary differentiation is normal. P. C. system is normal.
- Lt. KIDNEY** : Normal in size, shape and echotexture. Renal sinus is normal  
Cortico medullary differentiation is normal. P. C. system is normal.
- URI. BLADDER** : Urinary bladder is normal in size, position. Wall thickness normal.
- PROSTATE** : Prostate is normal in size.  
No ascites & retro peritoneal lymphadenopathy seen.
- IMPRESSION** : **NO OBVIOUS SONOLOGICAL ABNORMALITY SEEN.**

*DR. R. TIWARI*  
(M.B.B.S, M.D.(KGMU, LKO)  
(RADIODIAGNOSIS).

*Thanks for reference.*

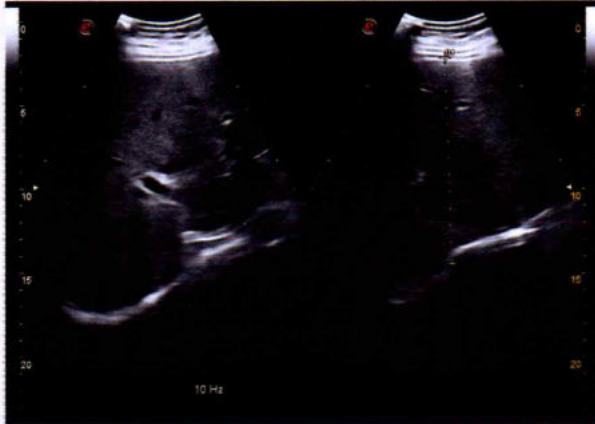Address : Kabir Nagar (Near Sanjay Shiksha Niketan), Durgakund, Varanasi

Mobile : 9554572190 / 9453837595 / Recpn. 9389994334

E-mail : dramishra@gmail.com, drpallaviojha@gmail.com, Website: www.piire.org

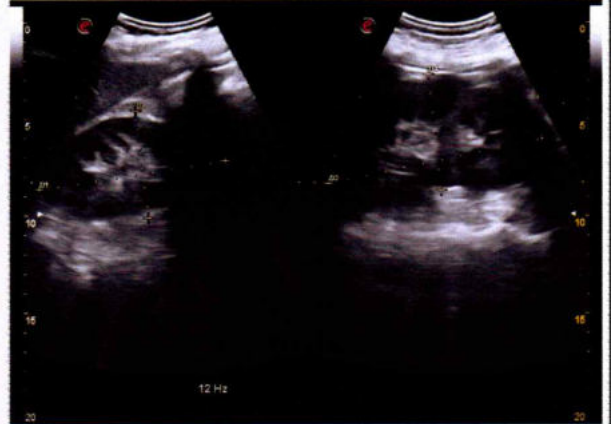VINAY KUMAR 48Y/M,F 31 03 2023 09:58:23 AM  
B GEN M G — P 60% M 0.8  
TEI D 211 mm X/M C2-  
ABDOMINAL AC2541 ABD PRC 19/2/3/5 PRS 4

D1  
122.6 mm



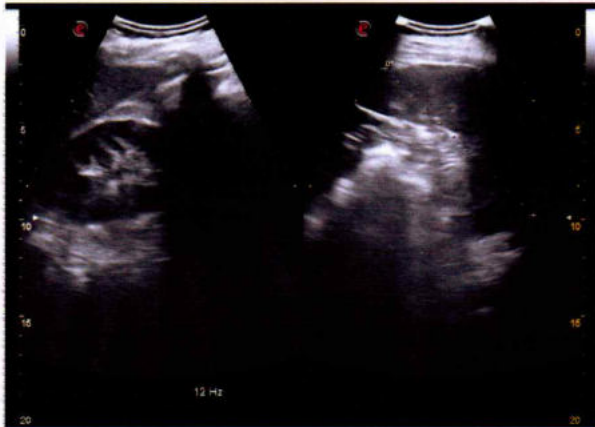VINAY KUMAR 48Y/M,F 31 03 2023 09:58:23 AM  
B GEN M G — P 60% M 0.8  
TEI D 183 mm X/M C2-  
ABDOMINAL AC2541 ABD PRC 19/2/3/5 PRS 4

D-Ratio  
D1  
97.7 mm  
D2  
55.8 mm  
D/D  
175 %  
D-Ratio  
D3  
112.5 mm  
D4  
80.4 mm  
D/D  
186 %

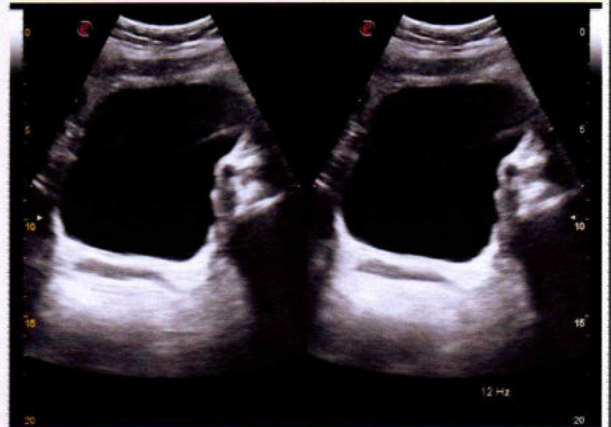


VINAY KUMAR 48Y/M,F 31 03 2023 09:58:23 AM  
B GEN M G — P 60% M 0.8  
TEI D 183 mm X/M C2-  
ABDOMINAL AC2541 ABD PRC 19/2/3/5 PRS 4

D1  
108.2 mm

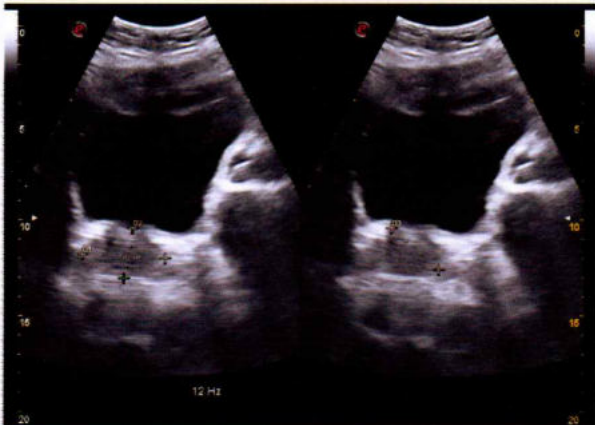

VINAY KUMAR 48Y/M,F 31 03 2023 09:58:23 AM  
B GEN M G — P 60% M 0.8  
TEI D 183 mm X/M C2-  
ABDOMINAL AC2541 ABD PRC 19/2/3/5 PRS 4



VINAY KUMAR 48Y/M,F 31 03 2023 09:58:23 AM  
B GEN M G — P 60% M 0.8  
TEI D 183 mm X/M C2-  
ABDOMINAL AC2541 ABD PRC 19/2/3/5 PRS 4

BI-Volume  
D1  
43.0 mm  
D2  
26.5 mm  
D3  
32.7 mm  
V  
19.5 ml



**Facilities:**

All clinical Biomedical & Hematology Investigations  
including Bone Marrow Examination  
VPT, Podiascan & Complete Foot Care (First Time in Purvanchal)  
All Hormonal Investigation by Chemiluminescent Method  
Visceral Fat by (AB-140) Ambulatory BP Monitoring  
CGMS & Insulin Pump Available  
PFT, 2D-ECHO (Color Doppler), Holter, TMT, Cardiac-3 available  
VIA, VILI, Colposcopy available  
Special Endocrinological Investigation Protocols.

ISO 9001:2008 Certified  
Mobile: 9389994334, 9554572190, 9453837595



# Panacea Pathology

## Clinical Reference Lab

Persistence, Preparedness and Precision  
EQAS (CMC Vellore Attached) & IQAS System  
पूर्वाचल की सर्वोत्तम गुणवत्ता वाली पैथोलॉजी

PATIENT NAME : VINAY KUMAR

AGE/GENDER : 47 YRS/MALE

REFD BY DR. : ARCO FEMI HEALTHCARE LTD.

RECEIVED DATE : 30-03-2023 (10:00 AM)

SAMPLE : BLOOD & URINE

REPORT DATE : 01-04-2023 (07:00 PM)

### PATHOLOGY REPORT

#### COMPLETE BLOOD COUNT (CBC)

TEST	LAB TEST VALUES	NORMAL RANGE
<b>HEMOGRAM</b>		
HEMOGLOBIN (FLOW CYTOMETRY)	16.3	13 – 16 gm/dl
TOTAL LEUCOCYTE COUNT (TLC)	7,000	4000 – 11000
RBC COUNT	5.26	3.5 – 5.5
PCV (HCT)	50.3	37 – 47
MCV	95.6	80 – 95
MCH	31.0	28 – 34
MCHC	32.4	30 – 36
PLATELET COUNT	1,56,000	1,50,000 – 4,00,000
E.S.R. (WINTROBE FIRST HOURS)	10.0	20 mm/1 <sup>st</sup> hr
<b>DIFFERENTIAL LEUCOCYTE</b>		
NEUTROPHILS	58	40 – 75%
LYMPHOCYTES	37	20 – 45%
EOSINOPHILS	02	1 – 6%
MONOCYTES	03	2 – 8%
BASOPHILS	00	< 2%

#### FASTING BLOOD SUGAR

TEST	LAB TEST VALUES	NORMAL RANGE
FBS		
FASTING BLOOD SUGAR	210.0	70-125 mg/dl

#### GLYCOSYLATED HEMOGLOBIN (HBA1C)

TEST	LAB TEST VALUES	NORMAL RANGE
HBA1C	8.3	Normal : <5.97 % Good Control : 5.97 – 6.81% Fair Control : 6.81 – 7.65% Poor Control : >7.65%

PAGE 1

Lab Technician

**PANACEA HOSPITAL**  
(A UNIT OF AAROHA HEALTHCARE PVT. L<sup>T</sup>)  
REG. NO.: AL-1500  
B.36/44, B-4, KABIR NAGAR  
DURGAKUND, VARANASI  
M.D. Pathology

Timing : 8.00 a.m. to 9.00 p.m. (Sunday 8.00 a.m. to 3.00 p.m.)

This Report is not valid for medico legal purpose

**Note:** These tests have technical limitations. Clinico-pathological interpretation is necessary. In case of any disparity test may be repeated immediately.

Address : 36/44 FK Kabir Nagar, Durgakund, Varanasi – 221005

Email: [dramishra@gmail.com](mailto:dramishra@gmail.com), [drpallaviojha@gmail.com](mailto:drpallaviojha@gmail.com) Website: [panaceahospital.org](http://panaceahospital.org)

**Facilities:**

All clinical Biomedical & Hematology Investigations including Bone Marrow Examination  
VPT, Podiascan & Complete Foot Care (First Time in Purvanchal)  
All Hormonal Investigation by Chemiluminescent Method  
Visceral Fat by (AB-140) Ambulatory BP Monitoring  
CGMS & Insulin Pump Available  
PFT, 2D-ECHO (Color Doppler), Holter, TMT, Cardiac-3 available  
VIA, VILI, Colposcopy available  
Special Endocrinological Investigation Protocols.

ISO 9001:2008 Certified  
Mobile: 9389994334, 9554572190, 9453837595



# Panacea Pathology

## Clinical Reference Lab

Persistence, Preparedness and Precision  
EQAS (CMC Vellore Attached) & IQAS System  
पूर्वाचल की सर्वोत्तम गुणवत्ता वाली पैथोलॉजी

PATIENT NAME : VINAY KUMAR

AGE/GENDER : 47 YRS/MALE

REFD BY DR. : ARCO FEMI HEALTHCARE LTD.

RECEIVED DATE : 30-03-2023 (10:00 AM)

SAMPLE : BLOOD & URINE

REPORT DATE : 01-04-2023 (07:00 PM)

### PATHOLOGY REPORT

#### LIPID PROFILE, SERUM

TEST	LAB TEST VALUES	NORMAL RANGE
<b>BLOOD CHEMISTRY</b>		
TOTAL CHOLESTEROL (SERUM)	176.0	Desirable:- &lt; 200 mg/dl Borderline:- 200 – 239 mg/dl High:- &gt; 240 mg/dl
TRIGLYCERIDES (SERUM)	165.0	35 – 170 mg/dl
HDL CHOLESTEROL (SERUM)	48.0	35.30 – 79.50 mg/dl
LDL CHOLESTEROL (SERUM)	95.0	&lt; 130 mg/dl
VLDL	33.0	&lt; 40 mg/dl
CHOLESTROL/HDL RATIO	3.66	&lt; 3.0 Low Risk Ratio 3.0 – 5.0 Avg Risk &lt; 5.0 High Risk
LDL/HDL RATIO	1.97	&lt; 3 Ratio

#### BLOOD GROUP

TEST	LAB TEST VALUES
<b>BLOOD GROUP ABO &amp; RH FACTOR</b>	
BLOOD GROUP	"B"
RH FACTOR	POSITIVE

#### LIVER PROFILE TEST, SERUM

TEST	LAB TEST VALUES	NORMAL RANGE
<b>BIO CHEMISTRY</b>		
TOTAL BILIRUBIN	0.79	0.0 – 1.1 mg/dl
DIRECT BILIRUBIN	0.29	0.0 – 0.2 mg/dl
INDIRECT BILIRUBIN	0.50	< 0.90 mg/dl
SGOT (AST)	21.0	0 – 52 mg/dl
SGPT (ALT)	23.0	0 – 39 mg/dl
GGT (GYT)	21.0	< 55 U/L

#### THYROID PROFILE (T3, T4, TSH)

TEST	LAB TEST VALUES	NORMAL RANGE
<b>THYROID FUNCTION TEST</b>		
T3	1.16	0.60 – 1.81 ng/ml
T4	7.82	4.50 – 10.90 ug/dl
TSH	2.56	0.39 – 6.10 uIU/mL

PAGE 2

Lab Technician

PANACEA HOSPITAL  
(A UNIT OF AAROHA HEALTH CARE PVT. LTD)  
REG. NO. 1500  
B.36/44 M.D. Pathology  
DURGAKUND, VARANASI

Timing : 8.00 a.m. to 9.00 p.m. (Sunday 8.00 a.m. to 3.00 p.m.)

This Report is not valid for medico legal purpose

**Note:** These tests have technical limitations. Clinico-pathological interpretation is necessary. In case of any disparity test may be repeated immediately.

Address : 36/44 FK Kabir Nagar, Durgakund, Varanasi – 221005

Email: [dramishra@gmail.com](mailto:dramishra@gmail.com), [drpallaviojha@gmail.com](mailto:drpallaviojha@gmail.com) Website: [panaceahospital.org](http://panaceahospital.org)



**Facilities:**

All clinical Biomedical & Hematology Investigations including Bone Marrow Examination  
VPT, Podiascan & Complete Foot Care (First Time in Purvanchal)  
All Hormonal Investigation by Chemiluminescent Method  
Visceral Fat by (AB-140) Ambulatory BP Monitoring  
CGMS & Insulin Pump Available  
PFT, 2D-ECHO (Color Doppler), Holter, TMT, Cardiac-3 available  
VIA, VILI, Colposcopy available  
Special Endocrinological Investigation Protocols.

ISO 9001:2008 Certified  
Mobile: 9389994334, 9554572190, 9453837595



# Panacea Pathology

## Clinical Reference Lab

Persistence, Preparedness and Precision  
EQAS (CMC Vellore Attached) & IQAS System  
पूर्वाचल की सर्वोत्तम गुणवत्ता वाली पैथोलॉजी

PATIENT NAME : VINAY KUMAR

AGE/GENDER : 47 YRS/MALE

REFD BY DR. : ARCO FEMI HEALTHCARE LTD.

RECEIVED DATE : 30-03-2023 (10:00 AM)

SAMPLE : BLOOD & URINE

REPORT DATE : 01-04-2023 (07:00 PM)

## PATHOLOGY REPORT

### RENAL & KIDNEY PROFILE, SERUM

TEST	LAB TEST VALUES	NORMAL RANGE
<b>RENAL FUNCTION TESTS</b>		
BLOOD UREA NITROGEN (BUN)	10.2	10 – 50 mg/dl
SERUM CREATININE	0.77	0.60 – 1.60 mg/dl
URIC ACID	3.99	3.60 – 7.70 mg/dl
ALKALINE PHOSPHATASE (ALP)	65.0	142 – 353 mg/dl
TOTAL PROTIENS	7.49	0 – 39 mg/dl
ALBUMIN	4.29	3.8 – 5.4 mg/dl
SERUM GLOBULIN	3.20	2.1 – 3.5 mg/dl
AG RATIO	1.34	-
CALCIUM	9.02	8.80 – 10.20
PHOSPHORUS	3.04	2.50 – 5.00
SERUM SODIUM NA+	137.6	135.00 – 155.00 mEq/Ltr
SERUM POTASIUUM K+	4.32	3.60 – 5.50 mEq/Ltr
ICALCIUM	1.24	1.10 – 1.35 mmol/L
SERUM CHLORIDE CL+	105.9	98.00 – 110.00 mEq/Ltr

### URINE ROUTINE EXAMINATION

TEST	LAB TEST VALUES	NORMAL RANGE
<b>PHYSICAL EXAMINATION</b>		
QUANTITY	30	ML
COLOUR	STRAW	PALE YELLOW
APPEARANCE	CLEAR	CLEAR
SPECIFIC GRAVITY	1.010	1.01 – 1.03
PH	6.5	4.7 – 7.5
<b>CHEMICAL EXAMINATION</b>		
GLUCOSE	Not Detected	Not Detected
PROTEIN	NIL	Not Detected
<b>MICROSCOPIC EXAMINATION</b>		
PUS CELLS	01-02	0-5
RBC	Not Detected	Not Detected
EPITHELIAL CELLS	01-05	0-5
CASTS	Not Detected	Not Detected
CRYSTALS	Not Detected	Not Detected
BACTERIA	Not Detected	Not Detected

----- End of Report -----

**PANACEA HOSPITAL**  
(A UNIT OF AAROH HEALTHCARE PVT. LT.)  
REG. NO.: RL-1500  
B.36/44 B-4 KABIR NAGAR  
DURGAKUND, VARANASI  
M.D. Pathology

Lab Technician

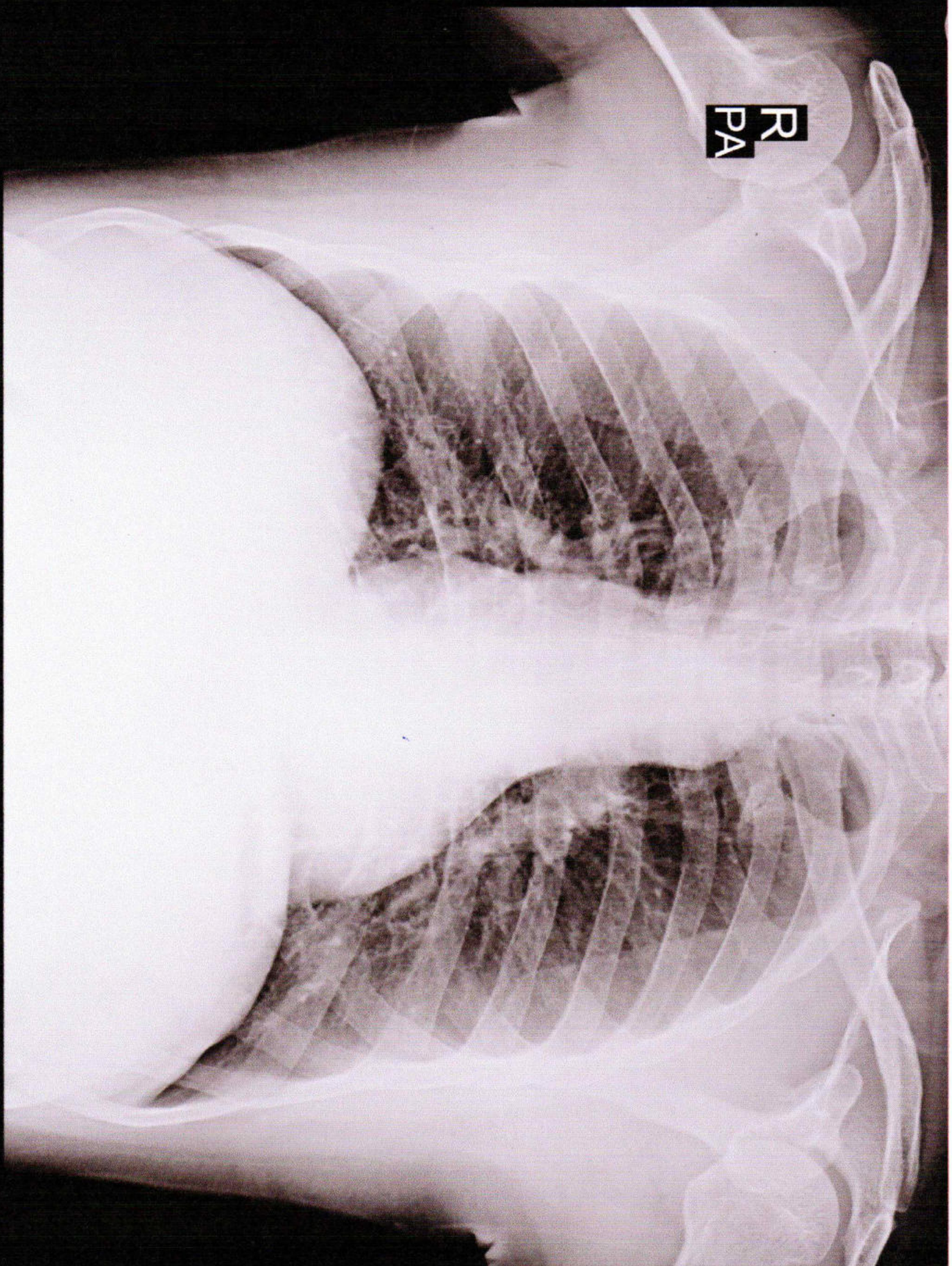
Timing : 8.00 a.m. to 9.00 p.m. (Sunday 8.00 a.m. to 3.00 p.m.)

This Report is not valid for medico legal purpose

**Note:** These tests have technical limitations. Clinico-pathological interpretation is necessary. In case of any disparity test may be repeated immediately.

Address : 36/44 FK Kabir Nagar, Durgakund, Varanasi – 221005

Email: [dramishra@gmail.com](mailto:dramishra@gmail.com), [drpallaviojha@gmail.com](mailto:drpallaviojha@gmail.com) Website: [panaceahospital.org](http://panaceahospital.org)



VINAY KUMAR 48Y1M 4220 O CHEST P.A. 30-Mar-23 10:59 AM

PANACEA HOSPITAL, KABIR NAGAR, DURGAKUND, VARANASI



Call Now - 1800-123-3070

# PANACEA HOSPITAL

*A shelter for many hearts A Home for many lives*

(An ISO 9001:2008 Certified Organisation)

Lab Attached with CMC Vellore Under EQAS Scheme

<b>PATIENT'S NAME</b> : Mrs.VINAY KUMAR	<b>AGE/SEX:</b> 48 Y/M
<b>REF. BY</b> : Dr. ASHUTOSH MISHRA (M.D.)	<b>Friday, March 31, 2023</b>

## X-RAY CHEST (PA VIEW)

### BOTH LUNG FIELDS AND PLEURAE:

Both lungs show normal bronchovascular pattern.

Right & left hila are normal

No focal mass or calcification is seen

There is no evidence of any fluid in the both the pleural cavities.

Both domes of diaphragms are normal in position.

### MEDIASTINUM:

Trachea is central in position.


Cardiac silhouette is of normal size and configuration.

No evidence of pericardial effusion.

No significant lymphadenopathy is seen.

Visualized skeleton is normal.

-----

  
**DR. R.K.TIWARI**  
M.B.B.S, M.D.(KGMU,LKO)  
(RADIOLOGIST)

*Thanks for reference.*

**Address : Kabir Nagar (Near Sanjay Shiksha Niketan), Durgakund, Varanasi**

**Mobile : 9554572190 / 9453837595 / Recpn. 9389994334**

**E-mail : dramishra@gmail.com, drpallaviojha@gmail.com, Website: www.piire.org**