



भारत सरकार  
GOVERNMENT OF INDIA



दिव्याशु श्रीवास्तव  
Divyanshu Srivastav  
जन्म वर्ष / Year of Birth : 1992  
पुरुष / Male



3229 9438 2563

आधार – आम आदमी का अधिकार



भारतीय विशिष्ट पहचान प्राधिकरण  
UNIQUE IDENTIFICATION AUTHORITY OF INDIA

पता: S/O ब्रिजेन्द्र कुमार श्रीवास्तव, ३,  
नियर विजय सिंह बाबा मंदिर, कृष्णा  
इन्क्लेव नन्दपुरा, झांसी खाम, सीपरी  
बाजार, झांसी, उत्तर प्रदेश, 284003

Address: S/O Brijendra Kumar  
Srivastav, 3, near vijay singh baba  
mandir, krishna enclave  
nandanpura, Jhansi Khas, Sipri  
Bazar, Jhansi, Uttar Pradesh,  
284003

1947  
1800 180 1947

help@uidai.gov.in

www.uidai.gov.in

P.O. Box No.1947,  
Bengaluru-560 001

*Signature*

Malik Radix Health Care Pvt. Ltd.  
C-217, C-218, Nirman Vihar  
Delhi-110092  
Ph. : 011-22011196, 22011192  
Regd. No. 607



# MALIK RADIX HEALTHCARE PVT LTD

UNI-EMC-217/218 NIRMAN VIHAR VIKAS MARG

DELHI 110092

DIVYANSHU SRIVASTAV

ID : 1406  
AGE/SEX : 30-Yr-M  
HT/WT : / /  
DATE : 25-03-2023 11:13:22 AM  
REF BY : Dr

MACHINE INTERPRETATION : Normal ECG.

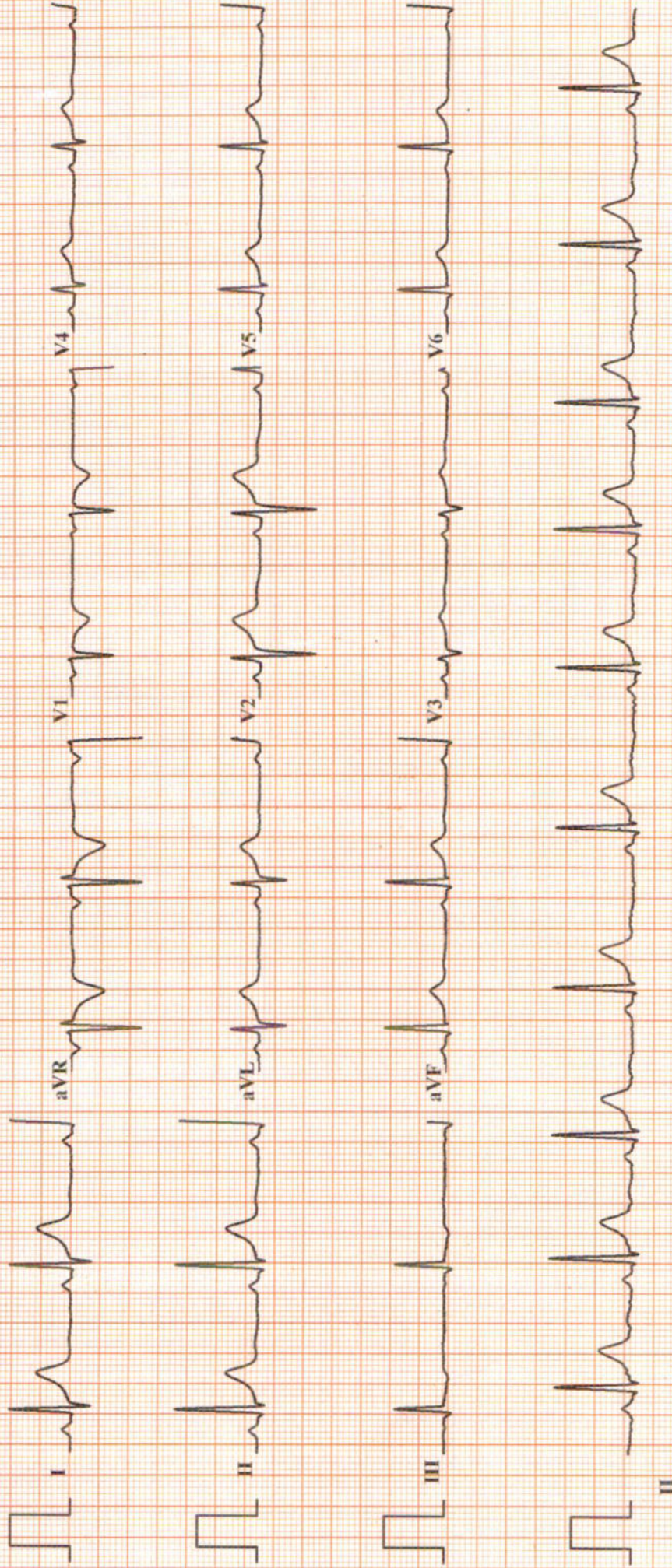
RATE : 63 bpm

P Duration : 89 ms

PR Duration : 139 ms  
QRS Duration : 82 ms  
QT Interval : 353 ms  
QTc Interval : 362 ms

Linked Median

Speed : 25 mm/s  
Sensitivity : 10 mm/mV



Conclu :- Normal ECG.

Dr. SHEIKH NAZIR AHMED  
M.D. - Physician

PGDCC



# MALIK RADIX HEALTHCARE PVT LTD

C-217/218 NIRMAN VIHAR  
VIKAS MARG DELHI 110092

**DIVYANSHU SRIVASTAV**  
ID : 1067  
DATE : 25-03-2023  
AGE/SEX : 30 / M  
HT/WT : 0 / 0  
REF. BY :

**TREADMILL TEST REPORT**  
PROTOCOL : Bruce  
HISTORY :  
INDICATION :  
MEDICATION :

PHASE	TOTAL TIME	STAGE TIME	SPEED Km/Hr	GRADE %	H.R. bpm	B.P. mmHg	RPP x100	ST LEVEL(MM)			METS	
								II	VI	V5		
SUPINE												
STANDING					62	120 / 80	74					0.5
HYPERVENT		0:32			64	120 / 80	76					0.5
Stage 1	2:55		2.7	10	66	120 / 80	79		1.1			0.6
Stage 2	5:55		4	12	109	124 / 82	135		1.2			0.6
Stage 3	8:55		5.4	14	142	126 / 84	178		0.5			0.2
PK-EXERCISE	9:51	0:51	6.7	16	174	130 / 86	226		0.9			0.4
RECOVERY	12:56	2:55			187	134 / 88	250		0.8			0.7
RECOVERY	15:56	5:55			105	134 / 88	140		1.6			0.8
					97	130 / 86	126		0.5			0.3

## RESULTS

EXERCISE DURATION : 9:51  
MAX HEART RATE : 187 bpm 98 % of target heart rate 190 bpm  
MAX BLOOD PRESSURE : 134 / 88 mm Hg  
REASON OF TERMINATION :

*Ther Achieved*  
*That is Negative for RMB*

BP RESPONSE :  
ARRHYTHMIA :  
H.R. RESPONSE :  
IMPRESSIONS :

MAX WORK LOAD : 11.13 METS

Technician :

**Dr. NISHU MALIK**  
MD Medicine, DNB Cardiology  
Senior Consultant, Cardiology  
DMC No.- 20902



# MALIK RADIX HEALTHCARE PVT LTD

DIVYANSHU SRIVASTAV

I.D. 1067

Age 30/M

Date 25-03-2023

RATE 62bpm

B.P. 120/80

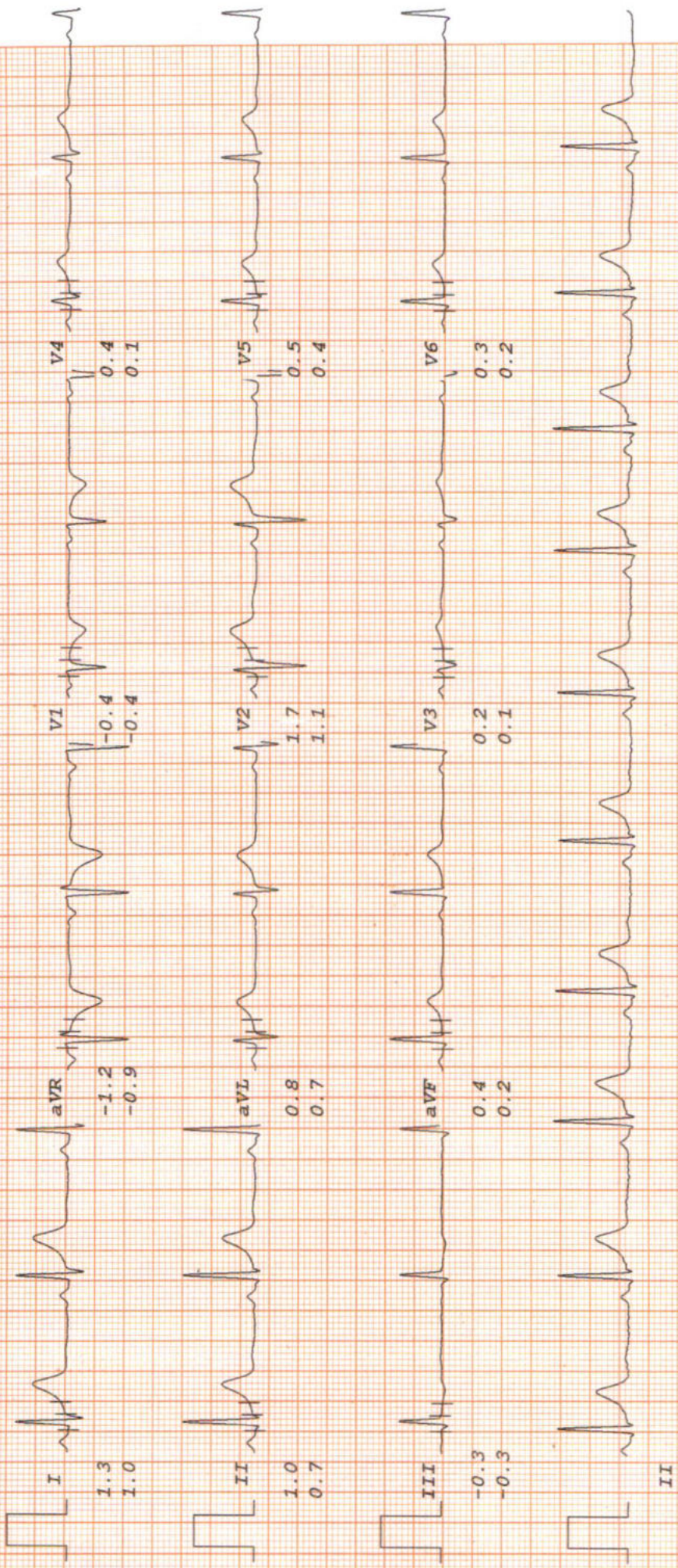
PRETEST

SUPINE

ST @ 10mm/mV

80ms PostJ

LINKED MEDIAN





# MALIK RADIX HEALTHCARE PVT LTD

DIVYANSHU SRIVASTAV

I.D. 1067

Age 30/M

Date 25-03-2023

RATE 64bpm

B.P. 120/80

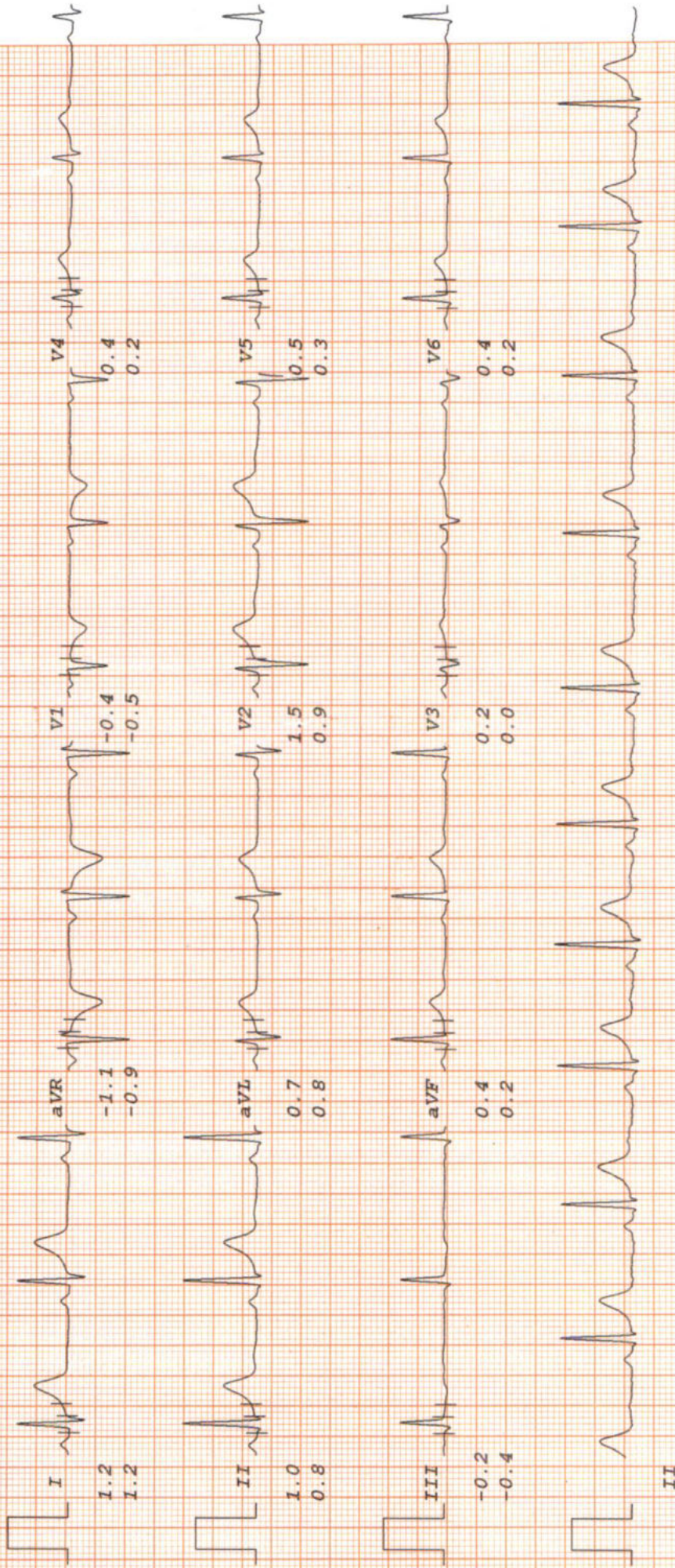
PRETEST

STANDING

ST @ 10mm/mV

80ms PostJ

LINKED MEDIAN





# MALIK RADIX HEALTHCARE PVT LTD

DIVYANSHU SRIVASTAV

I.D. 1067

Age 30/M

Date 25-03-2023

RATE 66bpm

B.P. 120/80

PRETEST

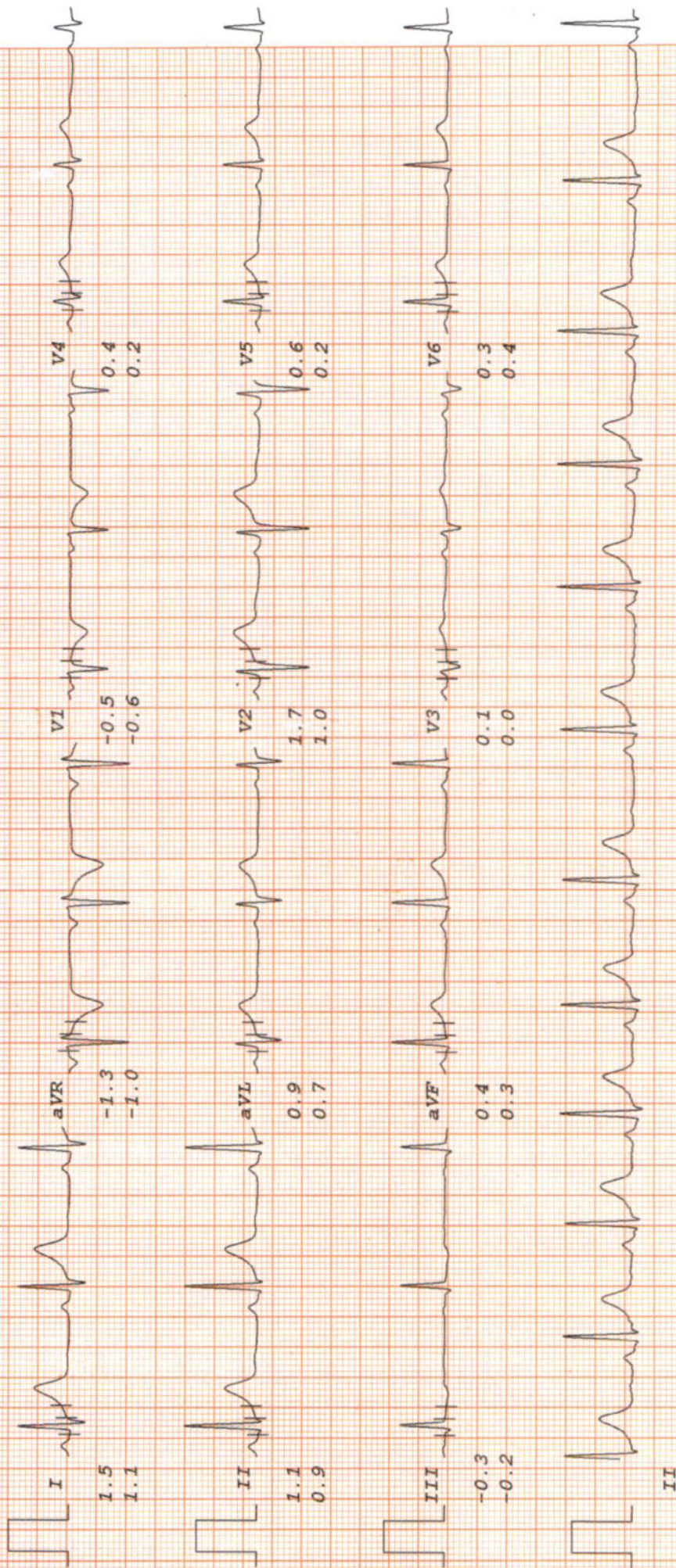
HYPERTENT

PHASE TIME 0:32

ST @ 10mm/mV

80ms PostJ

LINKED MEDIAN



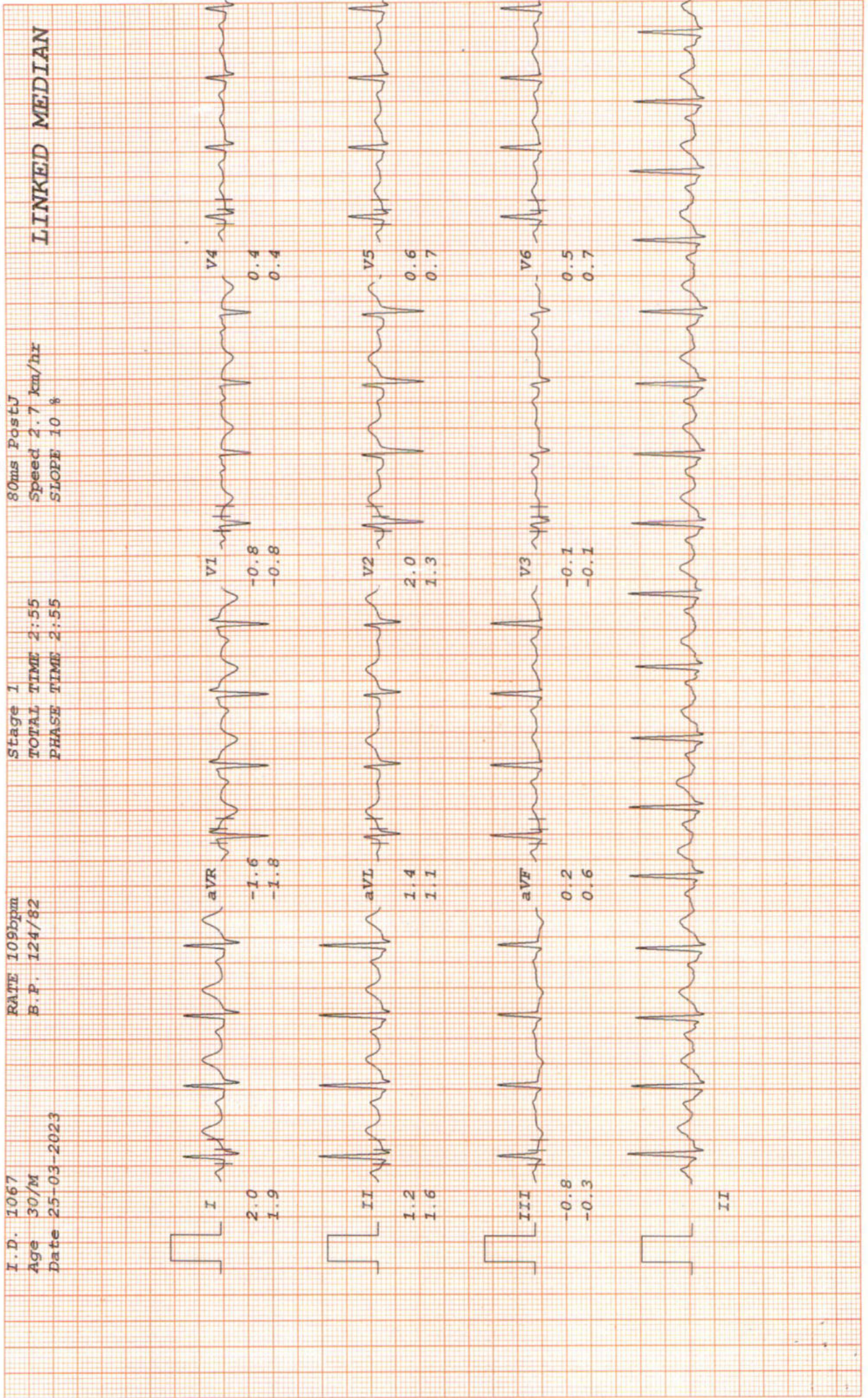


# MALIK RADIX HEALTHCARE PVT LTD

DIVYANSHU SRIVASTAV

Bruce

ST @ 10mm/mV





# MALIK RADIX HEALTHCARE PVT LTD

**DIVYANSHU SRIVASTAV**

I.D. 1067

Age 30/M

Date 25-03-2023

RATE 142bpm

B.P. 126/84

**Bruce**

Stage 2

TOTAL TIME 5:55

PHASE TIME 2:55

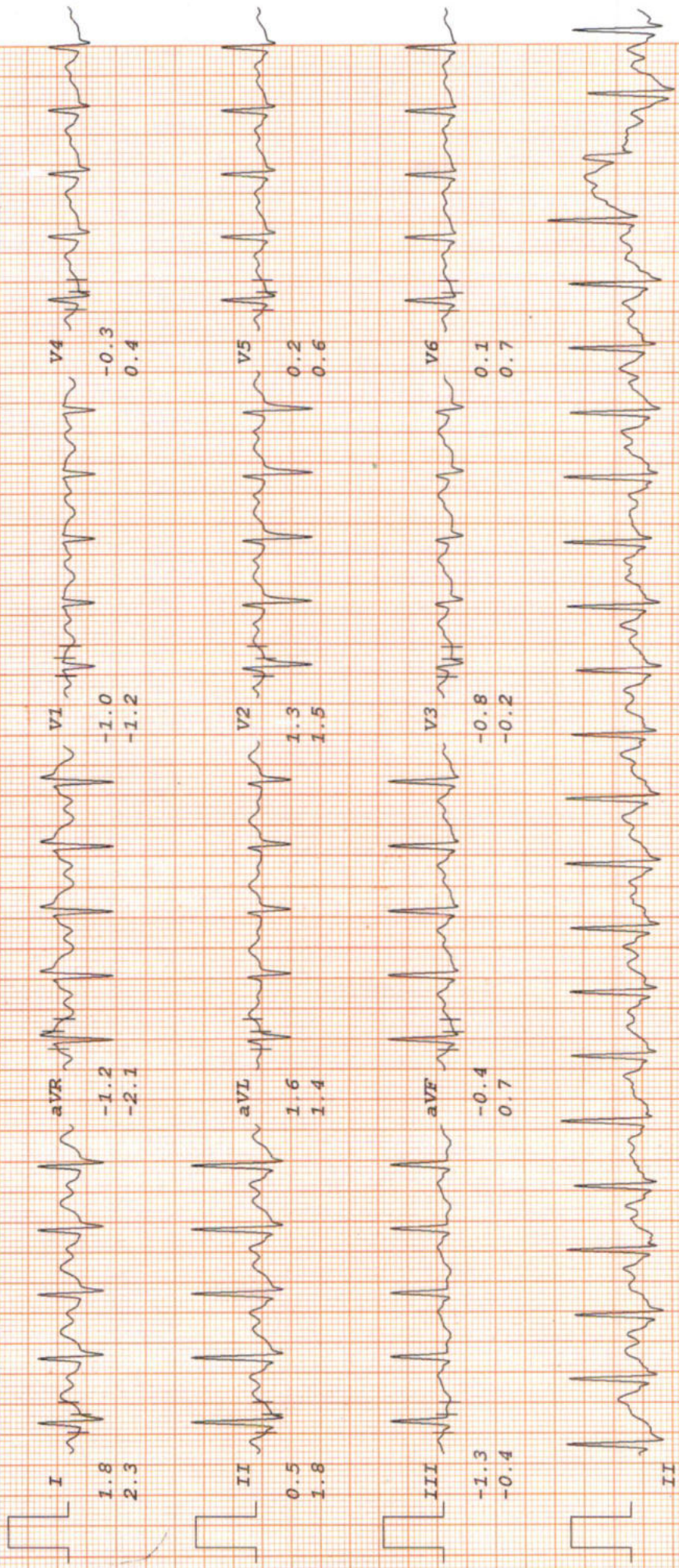
ST @ 10mm/mV

80ms PostJ

Speed 4 km/hr

SLOPE 12 %

**LINKED MEDIAN**







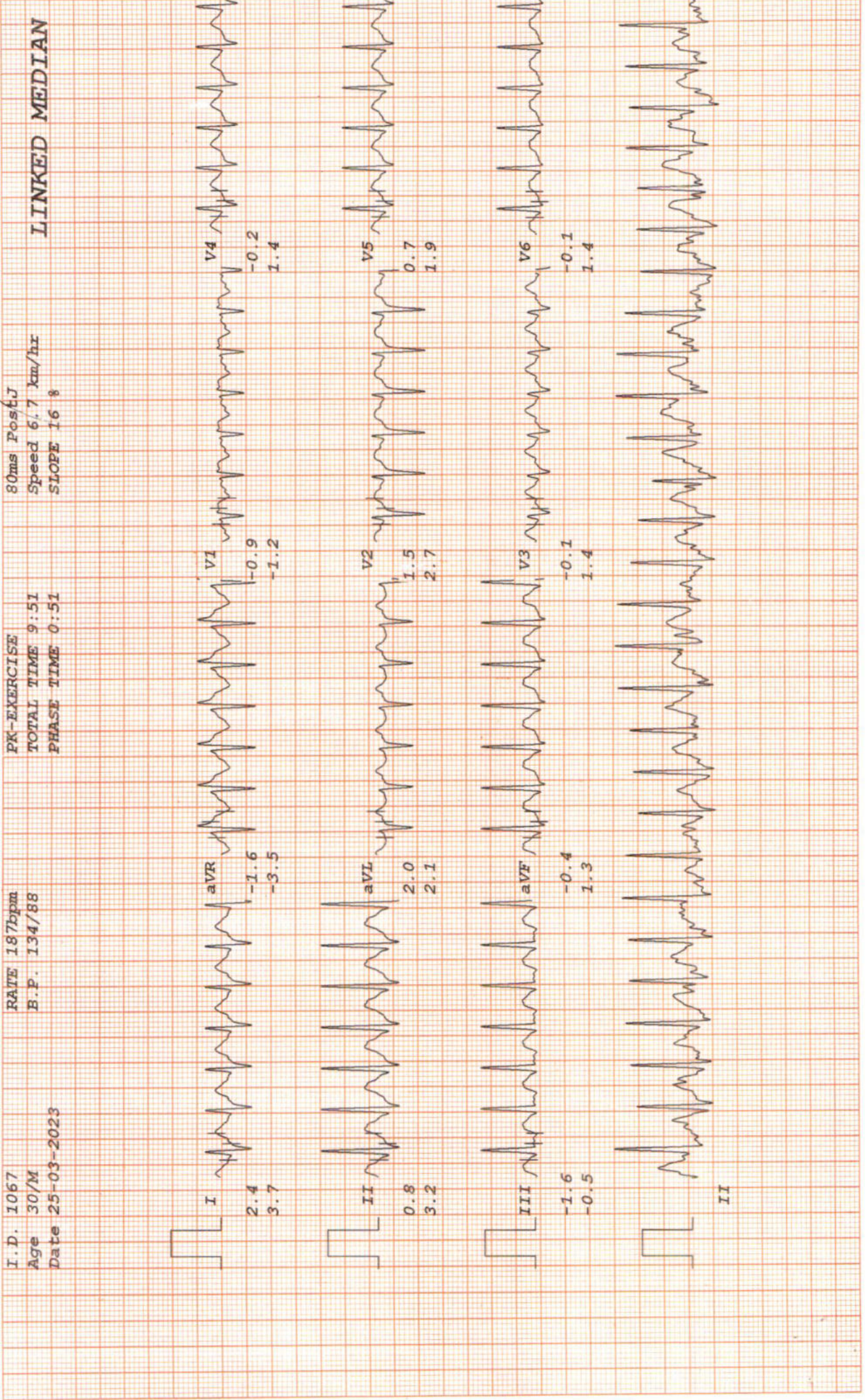


# MALIK RADIX HEALTHCARE PVT LTD

**DIVYANSHU SRIVASTAV**

**Bruce**

**ST @ 10mm/mV**



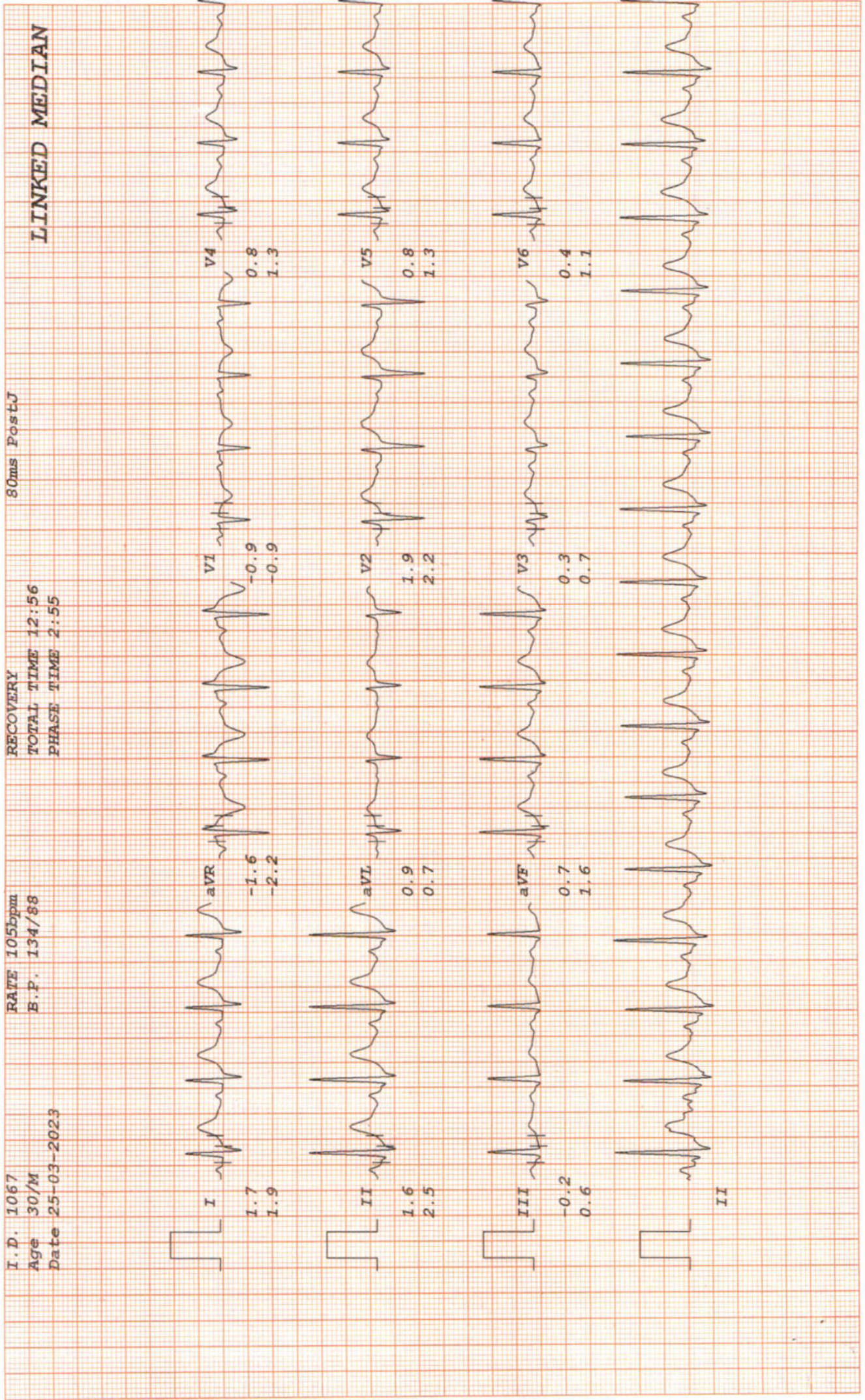


# MALIK RADIX HEALTHCARE PVT LTD

DIVYANSHU SRIVASTAV

Bruce

ST @ 10mm/mV



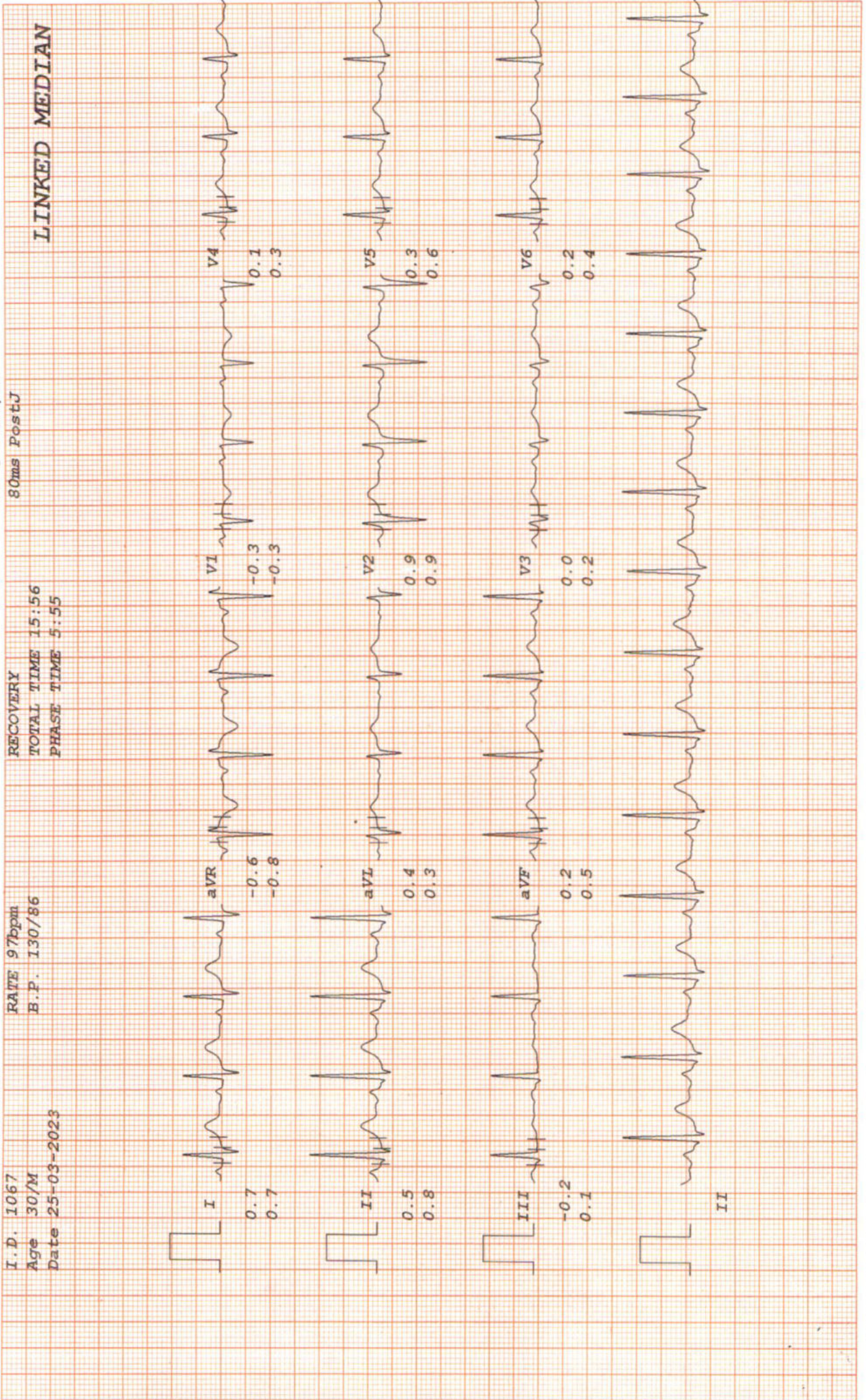


# MALIK RADIX HEALTHCARE PVT LTD

DIVYANSHU SRIVASTAV

Bruce

ST @ 10mm/mV







Name - ~~Mr. Srinivas~~ Divyanshu  
Age - 35/m  
Date - 25/3/23

Insurance Status

Eye  
exam  
6/6 ~~1~~  
6/8 ~~2~~

Near V ~~No~~  
NO

Ad

9 Year Tears - HA

Abd ophthalmology

Dr. Nishi Gupta  
MBBS, MS, DNB  
Casualty Ophthalmologist  
Malik Radix Healthcare Pvt. Ltd.  
DMC No. 121661

Facilities Available

- Multispeciality Hospital - 24 Hours Emergency - X-Ray/ ECG/ Ultrasound/ CT Scan - Dental - Fully Equipped Operation Theatre
- Fully Functional Lab - 24/7 Casualty/ ICU-Nursery 24/7 Pharmacy - Labour Room - All Speciality OPD - Laproscopic Surgery - ECHO - Plastic Surgery





**LAB REPORT**

Reg. Date	25/03/2023	Patient Id	2303250006	DOB.	
Name	MR. DIVYANSHU SRIVASTAV	Gender	M	Perm. ID	
Age	30 Yrs.	Panel	MEDIWHEEL	Reported	25/03/2023 16:38:09
Ref. By	MEDIWHEEL				

Test Name	Result	Units	Ref. Range
-----------	--------	-------	------------

MEDIWHEEL M BELOW 40

**HAEMATOLOGY**

**COMPLETE HAEMOGRAM**

HAEMOGLOBIN (HB%)	13.6	gm/dl	13 - 18
TOTAL LEUCOCYTE COUNT (TLC)	6,700	/cumm	4000 - 11000

**DIFFERENTIAL LEUCOCYTE COUNT (DLC)**

NEUTROPHIL	48	%	40 - 80
LYMPHOCYTE	46	%	28 - 55
MONOCYTE	05	%	02 - 10
EOSINOPHIL	01	%	01 - 06
BASOPHIL	00	%	0 - 0
ESR (WESTEGREN'S METHOD)	12	mm/1st hr.	0 - 10
R B C COUNT	5.24	Millions/cmm	4.247 - 5.4
P.C.V / HAEMATOCRIT	46.7	%	40 - 54
M C V	89.1	fl.	80 - 100
M C H	26.0	Picogram	27.0 - 31.0
M C H C	29.1	gm/dl	33 - 37
PLATELET COUNT	2.19	Lakh/cu mm	1.50 - 4.50

Urine Routine Examination

**PHYSICAL EXAMINATION**

QUANTITY	30	ml.	
COLOUR	Pale Yellow		Pale Yellow
TRANSPARENCY	Clear		
SPECIFIC GRAVITY	1.015		
PH	6.0		

Checked by : \_\_\_\_\_  
Page 1 Contd...2

If test results are alarming or unexpected, patient is advised to contact the laboratory immediately for possible remedial action.

**Facilities Available**

- Multispeciality Hospital - 24 Hours Emergency - X-Ray/ ECG/ Ultrasound/ CT Scan - Dental - Fully Equiped Operation Theatre  
- Fully Functional Lab - Casualty/ ICU-Nursery - Labour Room - All Speciality OPD - Laproscopic Surgery - ECHO - Plastic Surgery





**LAB REPORT**

Reg. Date	25/03/2023	Patient Id	2303250006	DOB.	
Name	MR. DIVYANSHU SRIVASTAV	Gender	M	Perm. ID	
Age	30 Yrs.	Panel	MEDIWHEEL	Reported	25/03/2023 16:38:09
Ref. By	MEDIWHEEL				

Test Name	Result	Units	Ref. Range
<b>CHEMICAL EXAMINATION</b>			
ALBUMIN	Nil		
SUGAR	Nil		
<b>MICROSCOPIC EXAMINATION</b>			
PUS CELLS	1-2	/HPF	
RBC'S	Nil	/HPF	
CASTS	Nil		
CRYSTALS	NIL		
EPITHELIAL CELLS	1-2	/HPF	
BACTERIA	Nil		
OTHERS	Nil		
Stool Examination Report			
BLOOD GROUP ABO	" A "		
RH TYPING	Positive		
BLOOD SUGAR FASTING	83.12	mg/dl	70 - 100
BLOOD SUGAR PP	114.39	mg/dl	90 - 140
HB A1C	5.12	%	

**Interpretation**

Non Diabetic	: 4-6%
Good Diabetic Control	: 6-8%
Fair Control	: 8-10%

Checked by : \_\_\_\_\_  
Page 2 Contd...3

If test results are alarming or unexpected, patient is advised to contact the laboratory immediately for possible remedial action.

**Facilities Available**

- Multispeciality Hospital - 24 Hours Emergency - X-Ray/ ECG/ Ultrasound/ CT Scan - Dental - Fully Equiped Operation Theatre  
- Fully Functional Lab - Casualty/ ICU-Nursery - Labour Room - All Speciality OPD - Laproscopic Surgery - ECHO - Plastic Surgery





**LAB REPORT**

Reg. Date	25/03/2023	Patient Id	2303250006	DOB.	
Name	MR. DIVYANSHU SRIVASTAV	Gender	M	Perm. ID	
Age	30 Yrs.	Panel	MEDIWHEEL	Reported	25/03/2023 16:38:09
Ref. By	MEDIWHEEL				

Test Name	Result	Units	Ref. Range
Poor Control	: >10%		

The Glycosylated haemoglobin assay has been validated as a reliable indicator Of mean blood glucose levels for a period of 8-12 week period. ADA recommended the testing twice a year in patients with stable blood glucose and quarterly. If treatment change, or if blood glucose levels are unstable.

**TO BE CORRELATED CLINICALLY.**

**THYROID PROFILE**

Free T3 ELFA	2.50	ng/ml	02 - 04
Free T4 ELFA	0.95	ug/dl	0.8 - 2.7
TSH Serum/ELFA	2.600	uIU/ml	0.25 - 5.50 uIU/ml

**Interpretation**

**Clinical Use**

- Diagnose Hypothyroidism and Hyperthyroidism
- Monitor T4 replacement or T4 suppressive Therapy
- Quantify TSH levels in the subnormal range

Increased Levels : Primary Hypothyroidism Subclinical Hypothyroidism, TSH dependent, Thyroid Hormone Resistance.

Decreased Levels : Grave's Disease, Autonomous Thyroid Hormone Secretion, TSH Deficiency

**LIPID PROFILE**

TOTAL CHOLESTEROL	161.50	mg/dL	130.0 - 200.0 (<200)
-------------------	--------	-------	-------------------------

Checked by : \_\_\_\_\_  
Page 3 Contd...4

If test results are alarming or unexpected, patient is advised to contact the laboratory immediately for possible remedial action.

**Facilities Available**

- Multispeciality Hospital - 24 Hours Emergency - X-Ray/ ECG/ Ultrasound/ CT Scan - Dental - Fully Equiped Operation Theatre  
- Fully Functional Lab - Casualty/ ICU-Nursery - Labour Room - All Speciality OPD - Laproscopic Surgery - ECHO - Plastic Surgery





## LAB REPORT

Reg. Date	25/03/2023	Patient Id	2303250006	DOB.	
Name	MR. DIVYANSHU SRIVASTAV	Gender	M	Perm. ID	
Age	30 Yrs.	Panel	MEDIWHEEL	Reported	25/03/2023 16:38:09
Ref. By	MEDIWHEEL				

Test Name	Result	Units	Ref. Range
TRIGLYCERIDES	81.40	mg/dL	80.5 - 150.0 (<150)
H D L CHOLESTEROL DIRECT	38.62	mg/dL	35.0 - 60.0 (<40->59)
V L D L	16.3	mg/dL	4.0 - 30. (23-45)
L D L CHOLESTEROL	106.6	mg/dL	50.0 - 150.0 (50-150)
TOTAL CHOLESTEROL / HDL RATIO	4.2		3.3 - 5.1
LDL / HDL CHOLESTEROL RATIO	2.8		1.5 - 3.5
SERUM URIC ACID	3.61	mg/dl	3.4 - 7.0
BLOOD UREA NITROGEN (BUN)	14.21	mg/dl	6.0 - 21.0
SERUM CREATININE	0.80	mg/dl	0.7 - 1.4
BUN/CREAT RATIO	17.7	mg/dl	10 - 20
<b><u>LIVER FUNCTION TEST (LFT)</u></b>			
BILIRUBIN TOTAL	0.83	mg/dl	0.2 - 1.2
CONJUGATED (D. BILIRUBIN)	0.25	mg/dl	0.00 - 0.3
UNCONJUGATED (I.D.BILIRUBIN)	0.58	mg/dl	0.2 - 0.9
SGOT / AST	16.09	IU/L	0 - 35
SGPT / ALT	34.42	IU/L	0 - 35
ALKALINE PHOSPHATASE	101.60	U/L	64 - 306
TOTAL PROTEIN	7.46	gm/dl	6.0 - 8.3
ALBUMIN	4.44	gm/dl	3.2 - 5.0
GLOBULIN	3.02	gm/dl	2.5 - 5.6
A/G RATIO	1.47		0.9 - 2.0
GAMMA GT	22.36	IU/L	0.0 - 45.0

Dr. REEMA DAHIYA

M.B.B.S., MD (Path)

Malik Radix Healthcare Pvt. Ltd.

DR. REEMA DAHIYA

C-217, C-218, Nirman Vihar,

M.B.B.S., MD (Path.)

Checked by

Page 4 of 4

DR. MEENU AGGARWAL  
M.B.B.S., MD (Path.)

If test results are alarming or unexpected, patient is advised to contact the laboratory immediately for possible remedial action.

## Facilities Available

- Multispeciality Hospital - 24 Hours Emergency - X-Ray/ ECG/ Ultrasound/ CT Scan - Dental - Fully Equiped Operation Theatre  
- Fully Functional Lab - Casualty/ ICU-Nursery - Labour Room - All Speciality OPD - Laproscopic Surgery - ECHO - Plastic Surgery




R

DIVYANSHU 30 Y/M. PT 184046 CHEST PA 25/Mar/2023 10:24 AM  
RADIOLIT AFFILIATES 10018 HERMAN DRIVE FT. LAUDERDALE, FL 33309



UHID	PT184046	LAB No.	XRY2210951
Name	Mr. DIVYANSHU SRIVASTAV	Regn. No.	GEN2243338
Age / Sex	30 Yrs / M	Receiving Dt/Time	25/Mar/2023 10:24
		Reporting Dt/Time	25/Mar/2023 10:53 AM

**XRAY**

CHEST (PA)

Both lung fields are normal.

Cp angles are clear.

Hila are normal...


Heart size appears within normal limits.

Soft tissue shadows and bony thorax are normal.

IMP- NORMAL CHEST X-RAY

Advised....please correlate clinically.

\*\*\*\*\* END OF REPORT \*\*\*\*\*



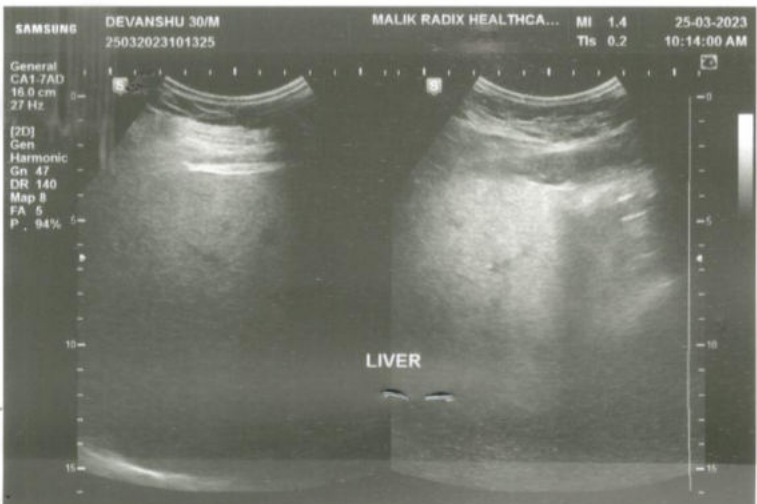
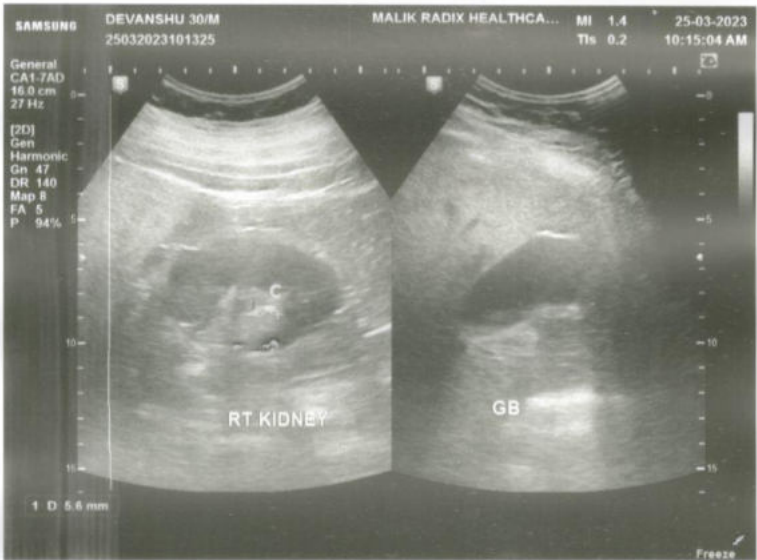
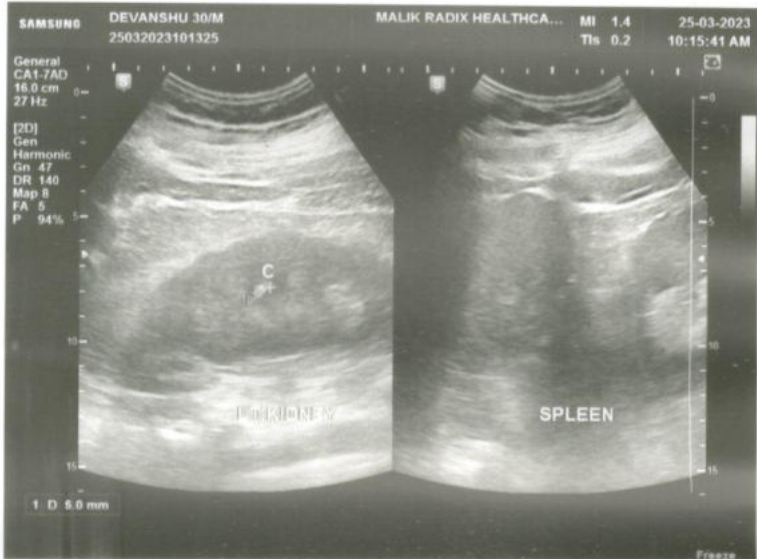
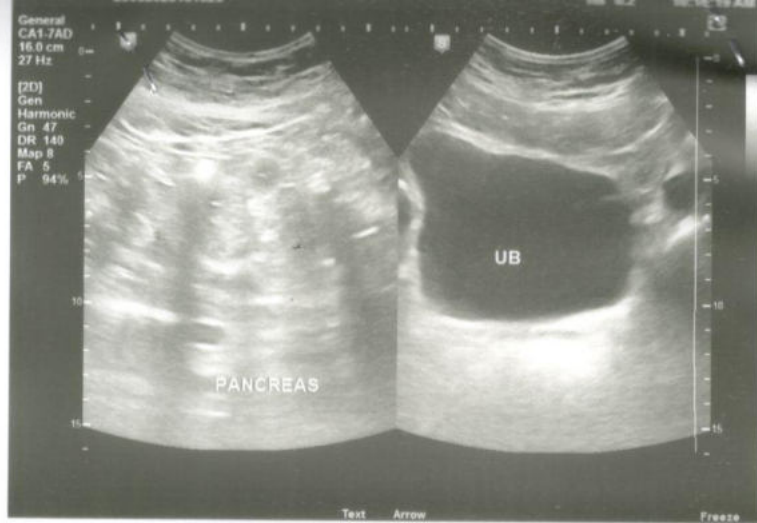DR. K.K. SINHA  
M.B.B.S./D.M.R.D.  
SENIOR CONSULTANT  
Reg. No. 25437 (DMC)

DR. RAJESH MALHOTRA  
MBBS, MD (RADIOLOGY)  
CONSULTANT RADIOLOGY  
Reg.No.DMC9299

DR. T. K VOHRA  
MD (RADIODIAGNOSIS)  
SENIOR CONSULTANT  
Reg. No. 3272 (DMC)

DR. MUKESH KOSHAL  
MBBS, MD (RADIOLOGY)  
CONSULTANT RADIOLOGY  
Reg.No.DMC10407









NAME	MR DIVYANSHU	AGE	30 YRS/M
REFD. BY.	HEALTH CHECK UP	DATE	25.03.23

### Ultrasound Examination of Whole Abdomen:

**Liver:** Liver shows grade 2 fatty change . No focal SOL is seen in liver. IHBR & portal radicles are normal.

**Gallbladder:** Gallbladder shows normal anechoic pattern. No evidence of cholecystitis or cholelithiasis seen. Common bile duct is normal in course & caliber.

**Pancreas:** Pancreas shows normal size & echotexture.

**Spleen:** Spleen shows normal size, outline & echotexture.

**Kidneys:** Kidneys show normal size, shape, position & echotexture. No hydronephrosis or SOL is seen in kidneys. Cortico- medullary differentiation and cortical thickness is normal on both sides. **Right kidney shows calculus of 5.6mm & Left kidney shows calculus of 6mm**

No supra- renal mass seen.

Great abdominal vessels are normal.

Domes of diaphragm are seen to move normally & synchronously in respiration. No infra- or supradiaphragmatic collection seen.

No ascites or pericardial effusion seen.

No para aortic lymph nodes seen.

**Urinary bladder:** Urinary bladder shows normal anechoic pattern. No calculus, SOL or diverticulum seen.

**Prostate:** Prostate and seminal vesicles are sonographically normal.

IMP—1)GRADE 2 FATTY LIVER  
2) B/L RENAL CALCULUS

Regards.

**Dr Mukesh Koshal MD ( Rad- diag)**

Regn. No. DMC 10407

RADIOLOGIST :

### Facilities Available

- Multispeciality Hospital - 24 Hours Emergency - X-Ray/ ECG/ Ultrasound/ CT Scan - Dental - Fully Equipped Operation Theatre  
- Fully Functional Lab - 24/7 Casualty/ ICU-Nursery 24/7 Pharmacy - Labour Room - All Speciality OPD - Laproscopic Surgery -  
ECHO - Plastic Surgery