
भारत निर्वाचन आयोग
 Election Commission of India
IDENTITY CARD
 ZFK0909515

मतदारता का नाम : कृतिका नागदेव रायसेठिया
 Elector's Name : KRITIKA NAGDEV RAISETHIA
 पति का नाम : विजय कुमार रायसेठिया
 Husband's Name : VIJAY KUMAR RAISETHIA / Female
 लिंग / Sex : महिला / Female
 1.1.2016 को आयु : 26 Years
 Age as on 1.1.2016 :

Kaus



Dr. NITIN AGARWAL
 MBBS, MD
 Regn. No. DMC-R-1436

ZFK0909515
 Address :
 106-SF, BLOCK B L (WEST)
 SHAELIMAR BAGH, DELHI
 Date : 16/08/2016

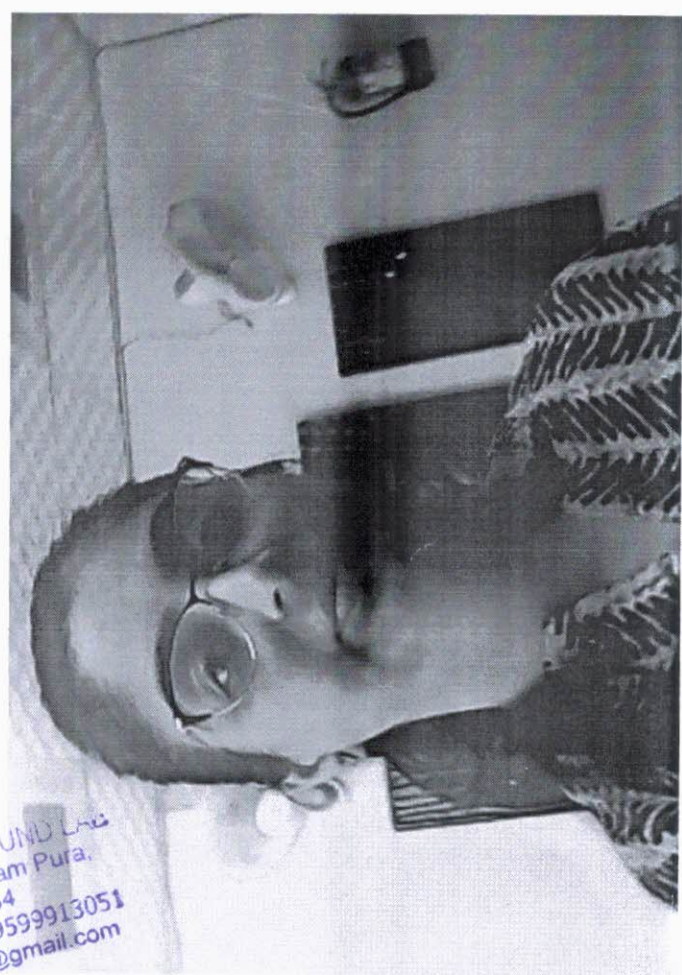14-संविधान संशोधन अधिनियम
 अधिनियम संख्या 14/1973 के अंतर्गत
 भारत निर्वाचन आयोग के अधीन
 कार्यरत अधिकारी का हस्ताक्षर
 और नाम
 Registration Officer for 14 SHALIMAR
 BAGH/Assembly Constituency
 ERODIA

यदि मतदार को मत देने के लिए अपने नाम
 पर कोई समस्या है तो मत देने के लिए मतदान
 कार्ड को बदलने के लिए मतदान आयोग के
 कार्यालय में मतदान आयोग के कार्यालय में
 सूचना देनी चाहिए।
 In case of change in address, mention the card
 number in the relevant Form for including your name
 in the roll at the changed address and to obtain that
 card with the same number. 130731

ONEPLUS ULTRASOUND LAB
 47, Harsh Vihar, Pitam Pura,
 Delhi-110034
 Ph. 011-42480101, 9599913051
 E-mail: oneplusul@gmail.com

Dr. NITIN AGARWAL
MBBS, MD
Regn. No. DMC-R-1436

Kailo



ONEPLUS ULTRASOUND LMS
47, Harsh Vihar, Pitam Pura,
Delhi-110034
Ph. 011-42480101, 9599913051
E-mail: oneplusul@gmail.com



OnePLUS
Ultrasound Lab
— QUALITY FIRST... ALWAYS! —

Dr. Nitin Agarwal

Pathologist & Director
Ex. Sr. Res. MAMC
& Lok Nayak Hospital
Ex. Chief of Lab Dr. Lal Path Labs.

Dr. Pooja (Garg) Agarwal

Radiologist & Director
MAMC & Lok Nayak Hospital

I, Keetika Nagdev Raicheta donot
wish to go for stool sample Test.
& BSPP.

Regards,
Keetika Nagdev Raicheta

Km/12
6/3/23.

DR. NITIN AGARWAL
MBBS, MD
Regn. No. DMC-R-1436

47, Harsh Vihar, Pitampura, New Delhi-110034 | Ph.: 011-42480101, 9599913051
E-mail: oneplusul@gmail.com | Web.: www.oneplusul.in

Clinical correlation is essential for final diagnosis. • If test results are unsatisfactory please contact personally or on phone. • This report is for perusal of doctors only
• All disputes Subject to Delhi Jurisdiction only. • Not for medicolegal purposes. • All congenital anomalies in a foetus may not be diagnosed in routine obstetric ultrasound

ONEPLUS ULTRASOUND LAB

47, HARSH VIHAR, PITAMPURA, DELHI- 110034

Ms. KRITIKA NAGDEV
 Age : 34/F
 Ref. by : MEDIMHEEL
 Indication1 :
 Indication2 :
 Indication3 :
 COMMENTS : Normal ECG.

ID : 2133
 H/Wt : 156/56
 Recorded : 6-3-2023 9:48
 Medication1 :
 Medication2 :
 Medication3 :

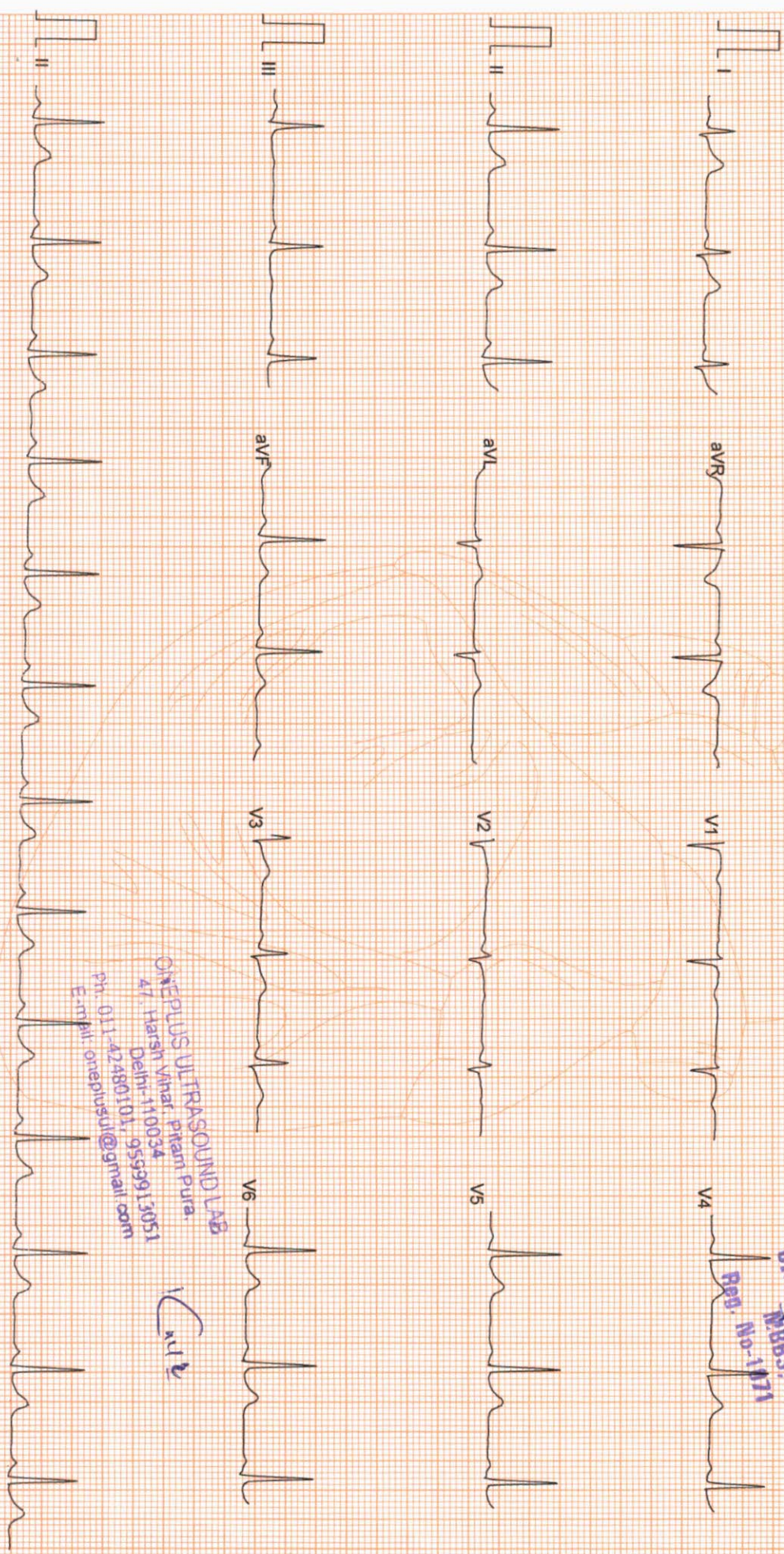
BPM : 81
 BP : 110/72
 P Axis : 67 deg
 QRS Axis : 73 deg
 T Axis : 30 deg

P duration : 90 msec
 PR duration : 133 msec
 QRS duration : 96 msec
 QT interval : 310 msec
 QTc interval : 346 msec

Unconfirmed Report Reviewed By:
 Cardiologist

Raw E.C.G.(Seq)

Dr. P.K. KRITIKA
 MBBS, MD
 Reg. No-1171



Filtered

25mm/sec 10mm/mV GREEN INDIA

CardiCom, INDIA

ONEPLUS ULTRASOUND LAB
 47 Harsh Vihar Pitampura,
 Delhi-110034
 Ph. 011-42480101, 9599913051
 Email: oneplusul@gmail.com

IC 2112

ONEPLUS ULTRASOUND LAB

47, HARSH VIHAR PITAMPURA DELHI 110034

ID: 991
 H/W: 156/56
 Recorded: 6-3-2023 9:55

TREADMILL TEST SUMMARY REPORT
 Protocol: BRUCE
 History:
 Medication1:
 Medication2:
 Medication3:

Ms. KRITIKA NAGDEV
 Age: 34/F
 Ref. by: MEDIWHEEL
 Indication1:
 Indication2:
 Indication3:

PHASE	PHASE TIME	STAGE TIME	SPEED (Km./Hr.)	GRADE (%)	H.R. (BPM)	B.P. (mmHg)	RPP X100	II	ST LEVEL (mm) V2	V5	METS
STANDING SUPINE					85 84	110/72 110/72	93 92	0.4 0.4	0.3 0.3	0.3 0.3	
STAGE 1	2:59	2:59	2.70	10.00	104	122/74	126	0.3	0.3	0.3	4.80
STAGE 2	5:59	2:59	4.00	12.00	114	134/78	152	0.0	0.0	0.0	7.10
STAGE 3	8:59	2:59	5.40	14.00	133	144/80	191	0.1	0.1	-0.2	10.00
STAGE 4	9:29	0:29	6.70	16.00	154	150/84	231	0.2	-0.2	-0.1	10.65
PEAK EXER	9:39	0:39			167	150/84	250	0.2	-0.1	-0.2	
RECOVERY	2:59	2:59	0.00	0.00	79	116/74	91	0.0	0.4	0.1	10.87

RESULTS
 Exercise Duration: 9:39 Minutes
 Max Heart Rate: 167 bpm 89% of target heart rate 186 bpm
 Max Blood Pressure: 150/84 mmHg
 Max Work Load: 10.87 METS
 Reason of Termination: ..
IMPRESSIONS ..
Negative for ischemia

[Signature]
Dr. P.K. GUPTA
 Cardiology MD
 Reg. No-1071

[Signature]
ONEPLUS ULTRASOUND LAB
 47, Harsh Vihar, Pitampura, Delhi-110034
 Ph: 011-23480101, 95569913051
 E-mail: onepuls@icloud.com

ONEPLUS ULTRASOUND LAB

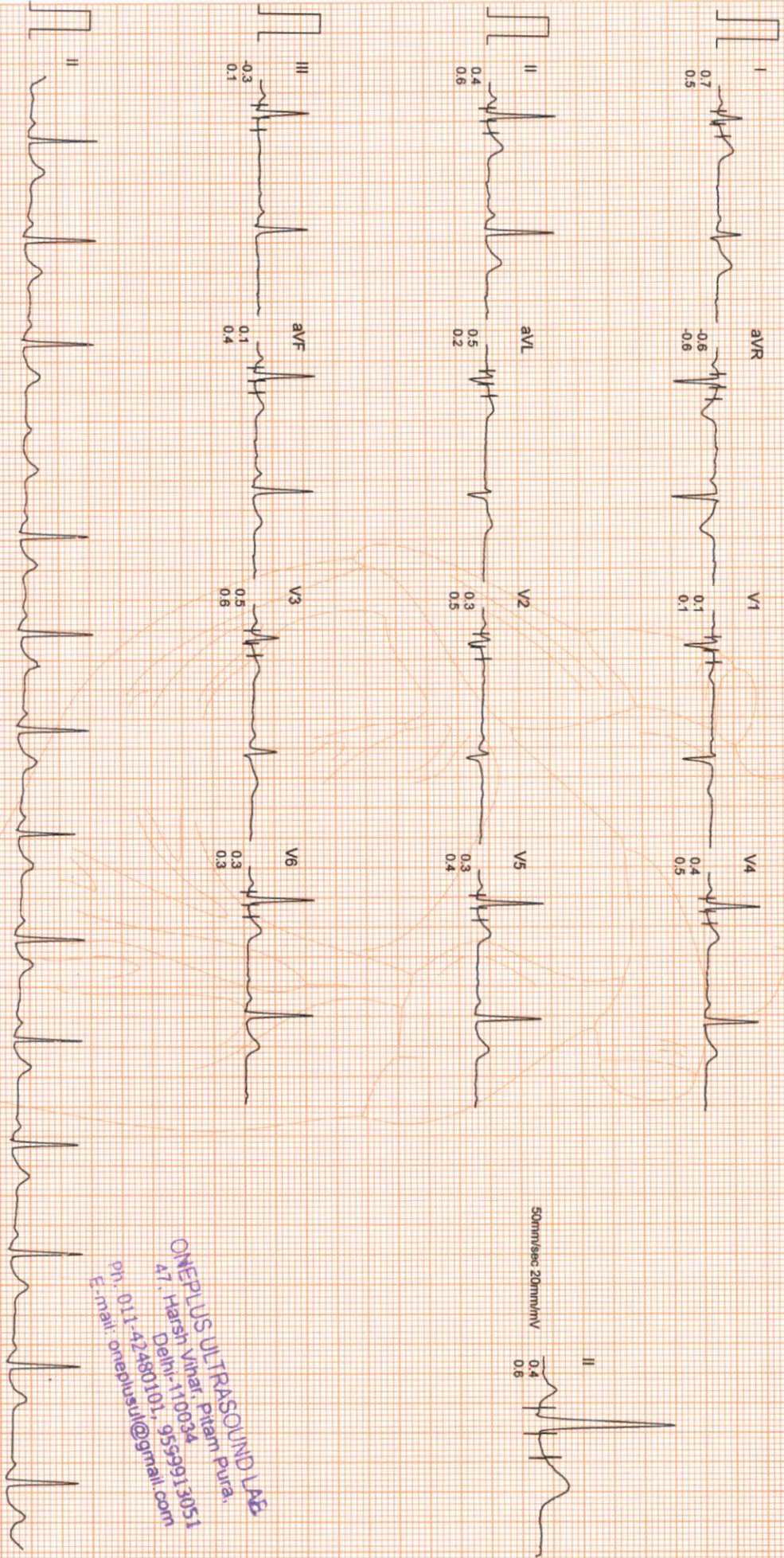
STANDING
PRETEST

ST @ 10mm/mV
80ms PostJ

Ms. KRITIKA NAGDEV
I.D. : 991
AGE/SEX : 34/F

RECORDED : 6-3-2023 9:55
RATE : 85 BPM
B.P. : 110/72 mmHg

LINKED MEDIAN



ONEPLUS ULTRASOUND LAB
A-1, Harsih Vihar, Pitampura,
Delhi-110034
Ph: 011-22480101, 9555550913051
E-mail: oneplusul@gmail.com

Filtered Computer Corrected Baseline

25mm/sec 10mm/mV

GREEN INDIA

CardiCom, INDIA Ph.:091-731-2620740, TeleFax:091-731-2431214

ONEPLUS ULTRASOUND LAB

SUPINE
PRETEST

ST @ 10mm/mV
80ms PostJ

Ms. KRITIKA NAGDEV

I.D. : 991

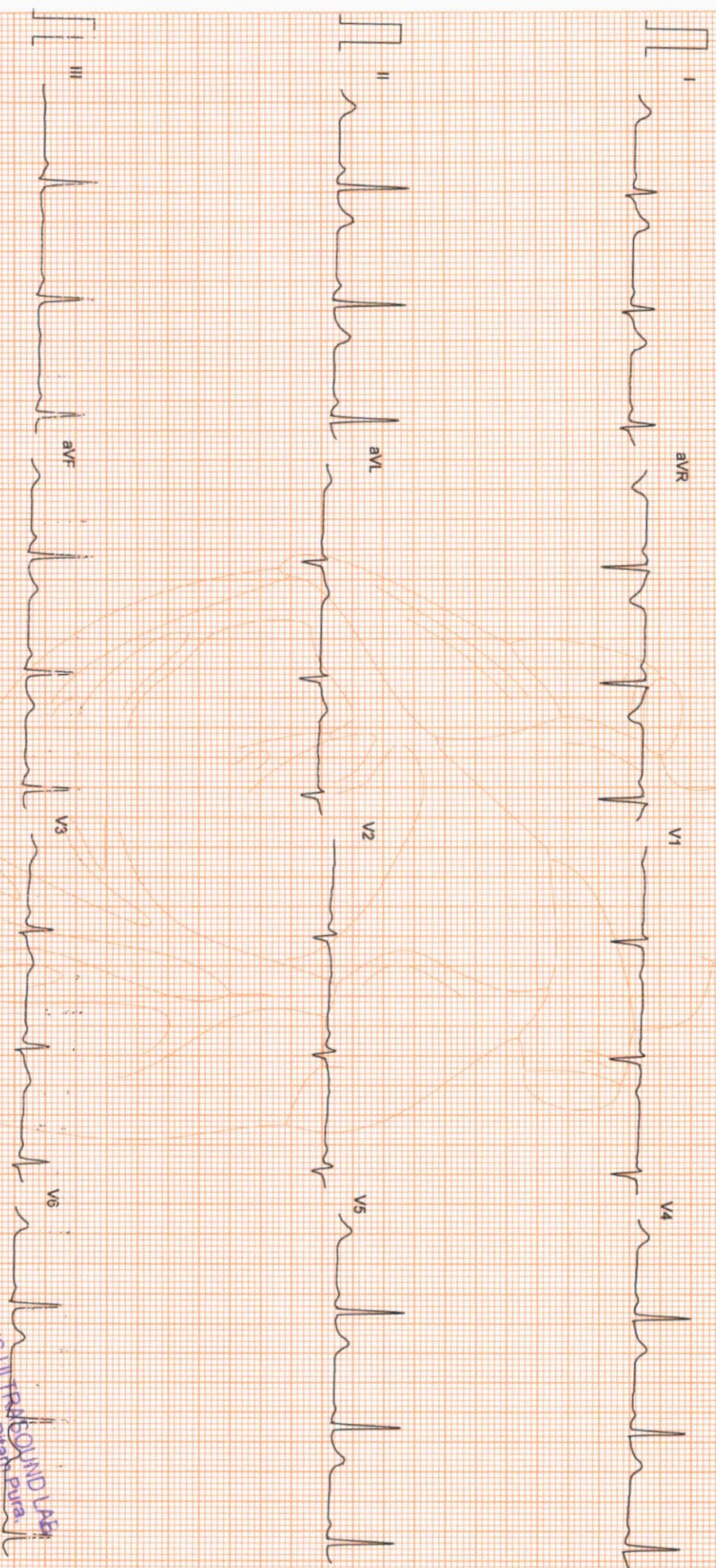
AGE/SEX : 34/F

RECORDED : 6-3-2023 9:55

RATE : 84 BPM

B.P. : 110/72 mmHg

RAW E.C.G.



ONEPLUS ULTRASOUND LAB
47, Hrishikesh, Pimpri
Near Chhatrapati Shivaji Maharaj
D. Tel: 011-42480101, 65956691305
Ph: 011-42480101, 65956691305
E-mail: oneplusultrasoundlab@gmail.com

Filtered

25mm/sec 10mm/mV

GREEN INDIA

CardCom, INDIA Ph.:091-731-2620740, Telefax:091-731-2431214

ONEPLUS ULTRASOUND LAB

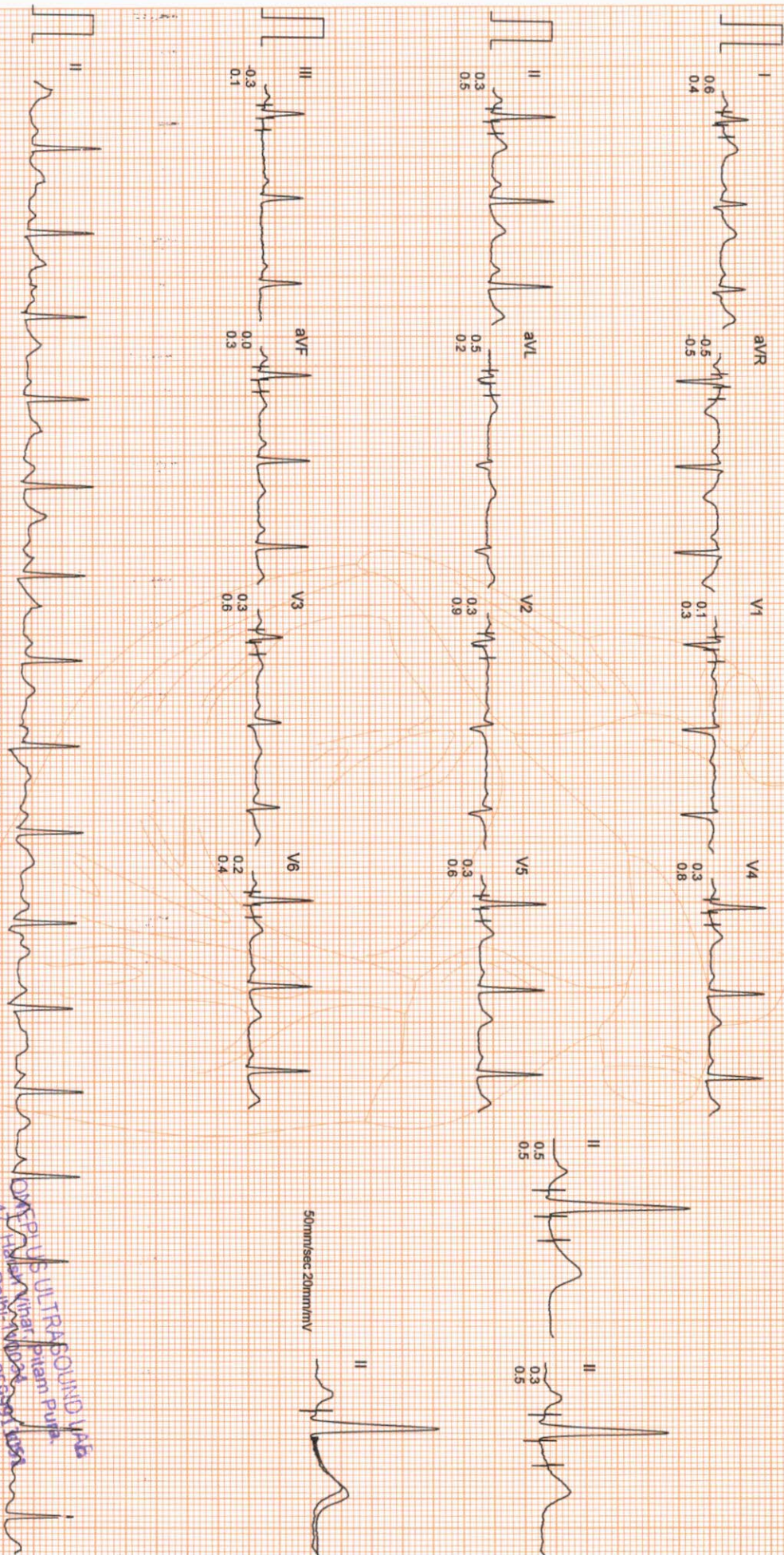
Ms. KRITIKA NAGDEV
I.D. : 991
AGE/SEX : 34/F
RECORDED : 6-3-2023 9:55

RATE : 104 BPM
B.P. : 122/74 mmHg

BRUCE
EXERCISE 1
PHASE TIME : 2:59
STAGE TIME : 2:59

ST @ 10mm/mV
80ms PostJ
SPEED : 2.7 Km/Hr.
GRADE : 10.0 %

LINKED MEDIAN



ONEPLUS ULTRASOUND LAB
47, Haryana Vihar, Pitampura,
Delhi-110034
Ph. 011-42480101, 9553991135
E-mail: oneplusul@gmail.com

ONEPLUS ULTRASOUND LAB

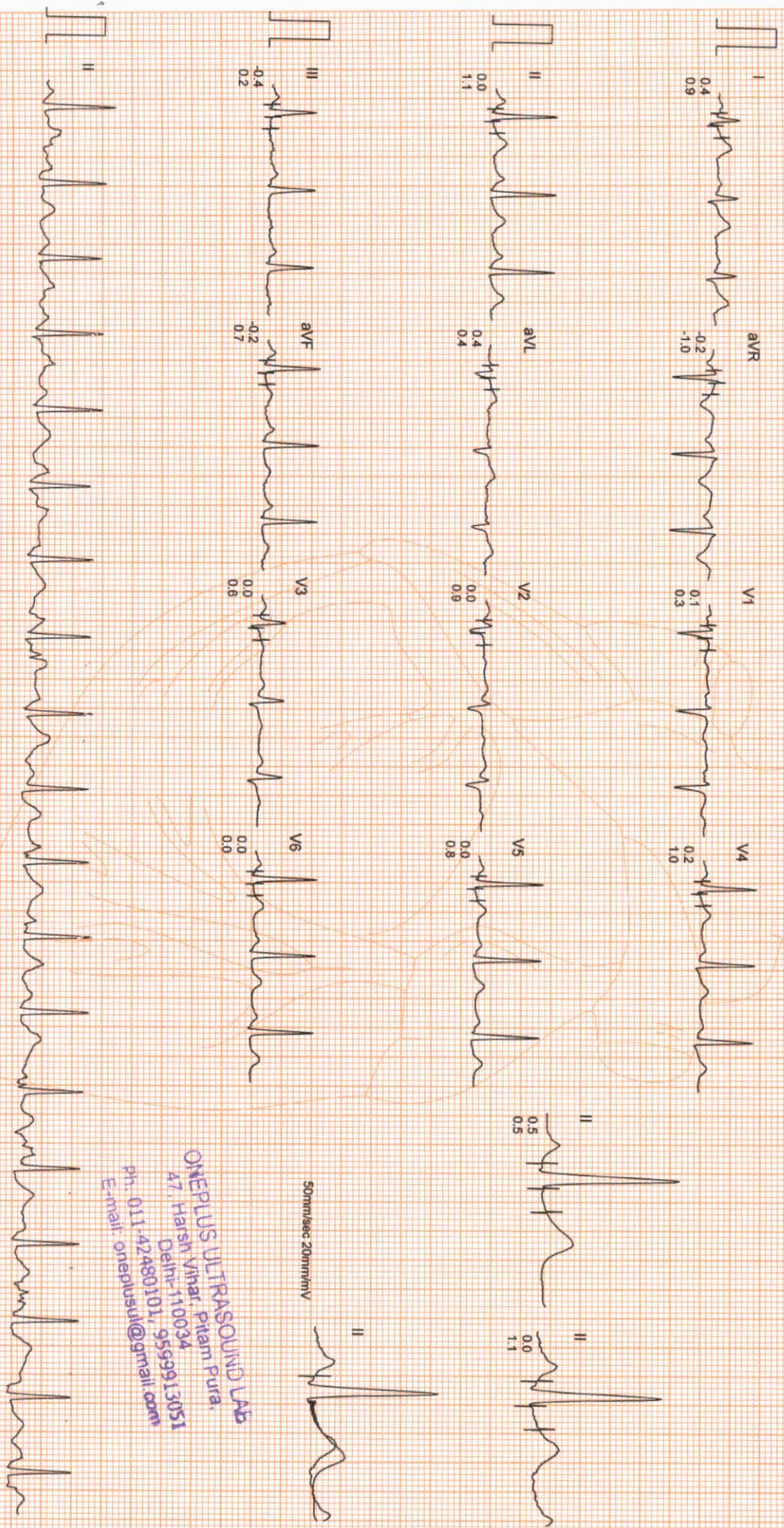
Ms. KRITIKA NAGDEV
I.D. : 991
AGE/SEX : 34/F
RECORDED : 6-3-2023 9:55

RATE : 114 BPM
B.P. : 134/78 mmHg

BRUCE
EXERCISE 2
PHASE TIME : 5:59
STAGE TIME : 2:59

ST @ 10mm/mV
80ms PostI
SPEED : 4.0 Km./Hr.
GRADE : 12.0 %

LINKED MEDIAN



ONEPLUS ULTRASOUND LAB
47, Harsh Vihar, Pitam Pura,
Delhi-110034
Ph. 011-42480101, 9599913051
E-mail: oneplusul@gmail.com

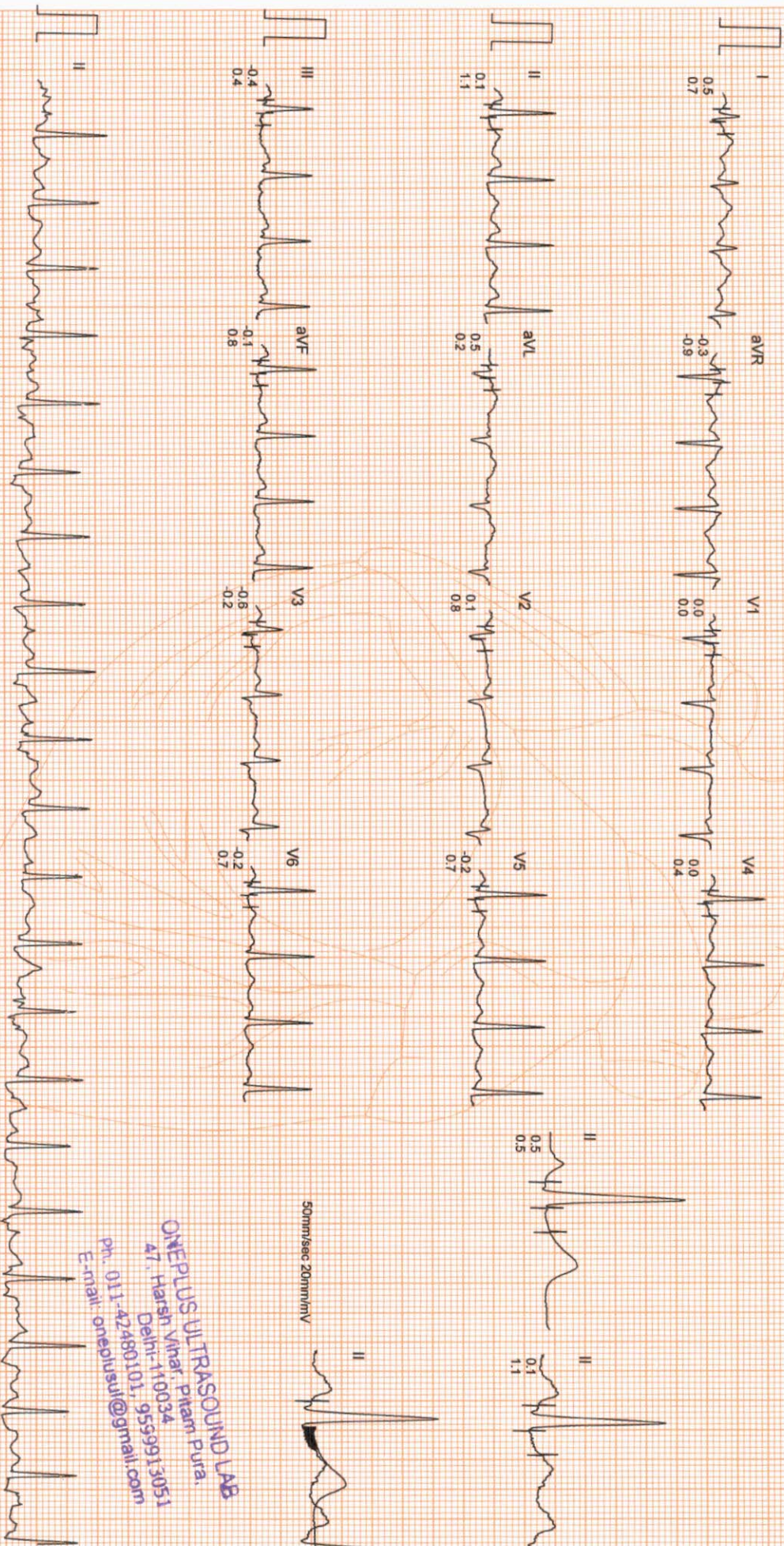
ONEPLUS ULTRASOUND LAB

Ms. KRITIKA NAGDEV
ID : 991
AGE/SEX : 34/F
RECORDED : 6-3-2023 9:55

RATE : 133 BPM
B.P. : 144/80 mmHg

BRUCE
EXERCISE 3
PHASE TIME : 8:59
STAGE TIME : 2:59

ST @ 10mm/mV
80ms PostI
SPEED : 5.4 Km/HR
GRADE : 14.0 %
LINKED MEDIAN



ONEPLUS ULTRASOUND LAB
47, Harsh Vihar, Pitampura,
Delhi-110034
Ph. 011-42480101, 9559913051
E-mail: oneplusul@gmail.com

Filtered Computer Corrected Baseline

25mm/sec 10mm/mV

GREEN INDIA

CardiCom, INDIA Ph.:091-731-2620740, TeleFax:091-731-2431214

ONEPLUS ULTRASOUND LAB

Ms. KRITIKA NAGDEV

I.D. : 991

AGE/SEX : 34/F

RECORDED : 6-3-2023 9:55

RATE : 159 BPM

B.P. : 144/80 mmHg

BRUCE

EXERCISE 4

PHASE TIME : 9:14

STAGE TIME : 0:14

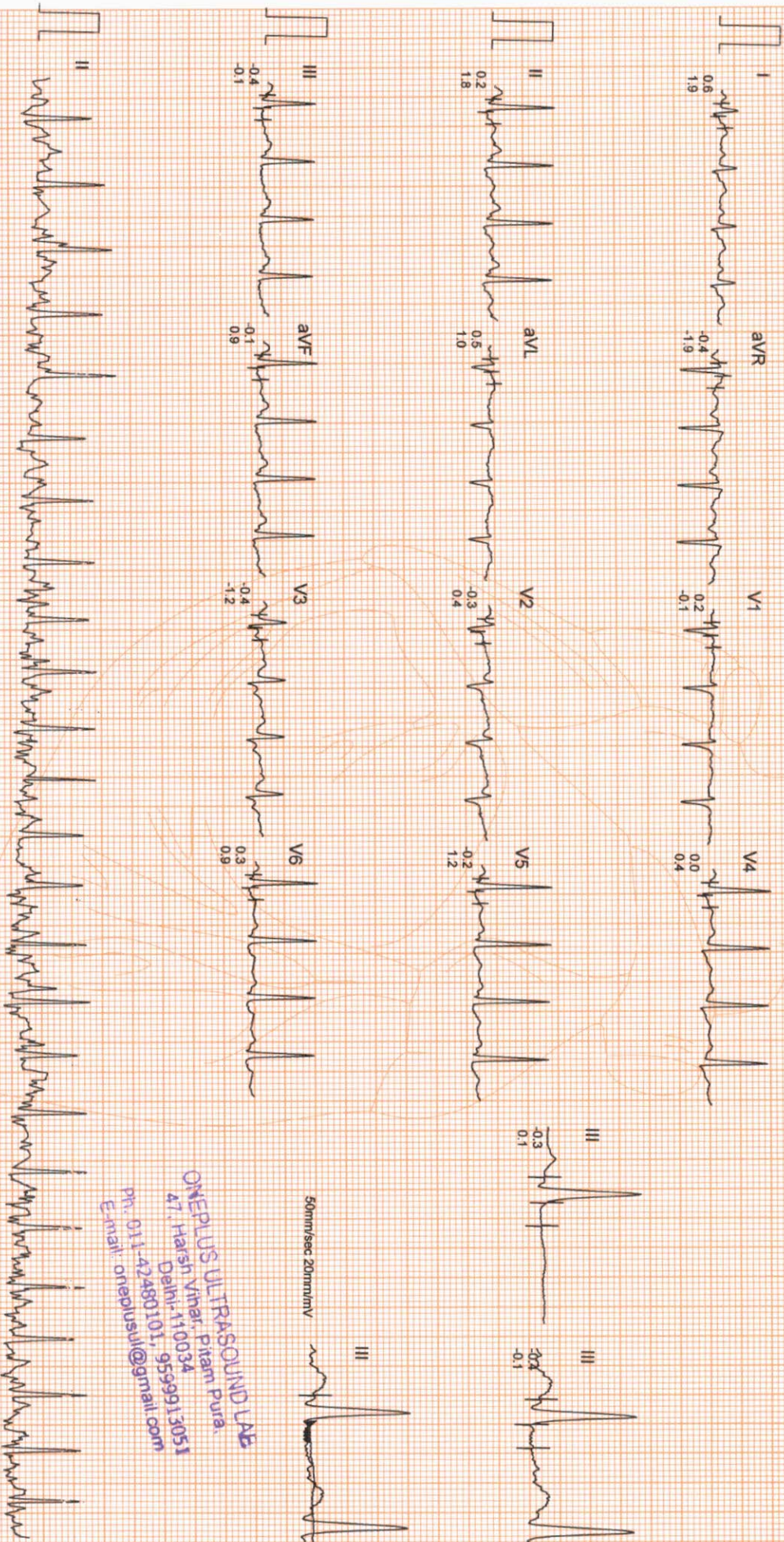
ST @ 10mm/mV

80ms PostJ

SPEED : 6.7 Km./Hr.

GRADE : 16.0 %

LINKED MEDIAN



50mm/sec 20mm/mV

ONEPLUS ULTRASOUND LAB
47, Harsh Vihar, Pitam Pura,
Delhi-110034
Ph: 011-42480101, 9599913051
E-mail: oneplusul@gmail.com

Filtered

Computer-Corrected Baseline

25mm/sec 10mm/mV

GREEN INDIA

CardiCom, INDIA Ph.:091-731-2620740, Telefax:091-731-2431214

ONEPLUS ULTRASOUND LAB

Ms. KRITIKA NAGDEV

I.D. : 991

AGE/SEX : 34/F

RECORDED : 6-3-2023 9:55

RATE : 167 BPM

B.P. : 150/84 mmHg

BRUCE
PEAK EXER

PHASE TIME : 9:39

STAGE TIME : 0:39

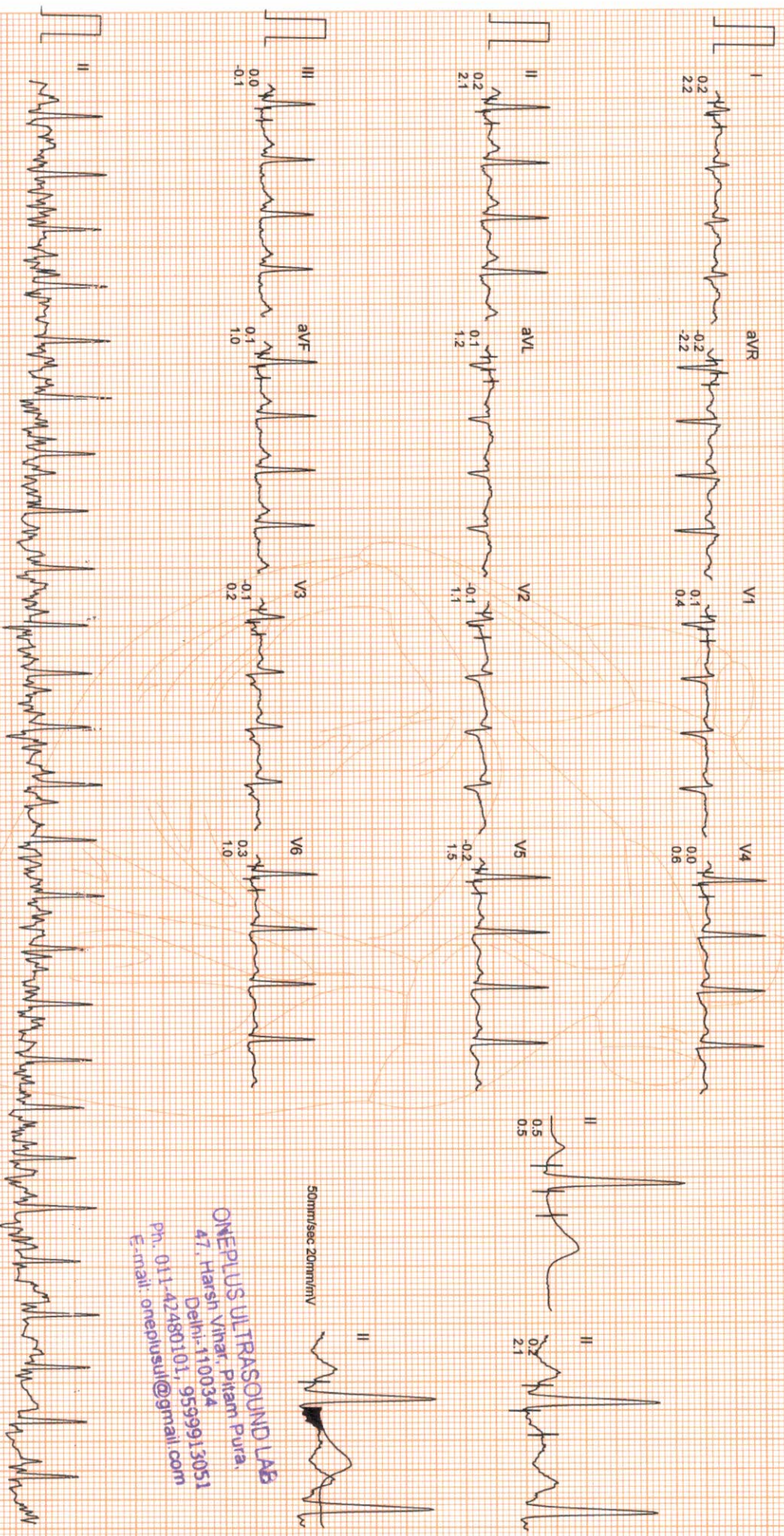
ST @ 10mm/mV

80ms PostJ

SPEED : 6.7 Km /Hr.

GRADE : 16.0 %

LINKED MEDIAN



50mm/sec 20mm/mV

ONEPLUS ULTRASOUND LAB
47, Harsh Vihar, Pitam Pura,
Delhi-110034
Ph. 011-42480101, 9599913051
E-mail: oneplusul@gmail.com

Ms. KRITIKA MAGDEV

I.D. : 991

AGE/SEX : 34/F

RECORDED : 6-3-2023 9:55

RATE : 79 BPM

B.P. : 116/74 mmHg

ONEPLUS ULTRASOUND LAB

BRUCE

RECOVERY

PHASE TIME : 2:59

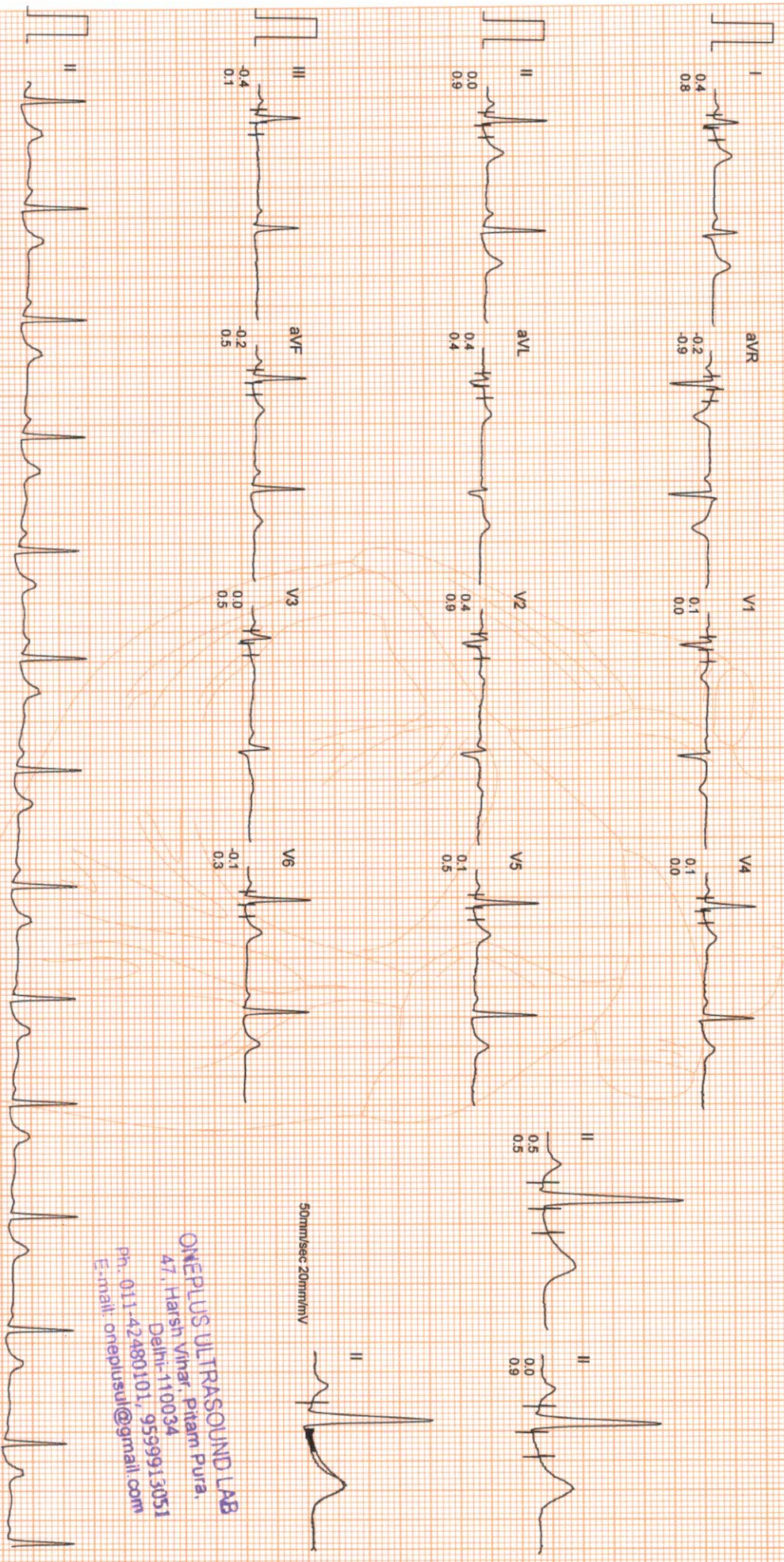
ST @ 10mm/mV

80ms PostJ

SPEED : 0.0 Km./Hr.

GRADE : 0.0 %

LINKED MEDIAN



50mm/sec 20mm/mV

ONEPLUS ULTRASOUND LAB
 47, Harsh Vihar, Pitam Pura,
 Delhi-110034
 Ph. 011-42480101, 9399913051
 E-mail: oneplusul@gmail.com

Filtered

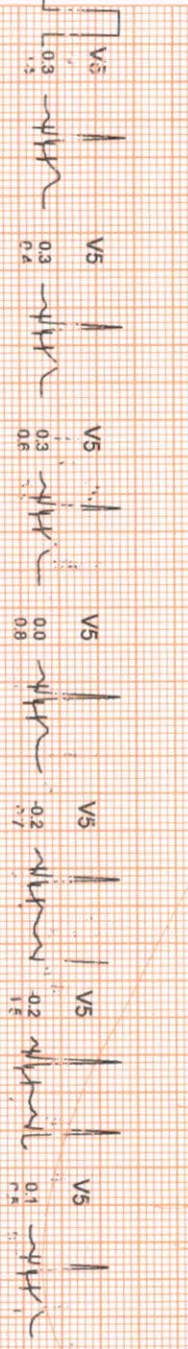
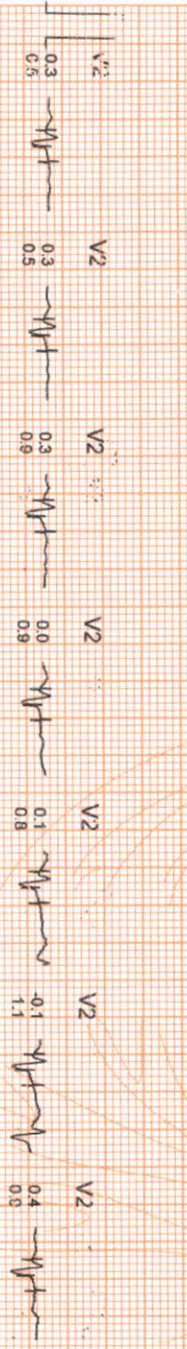
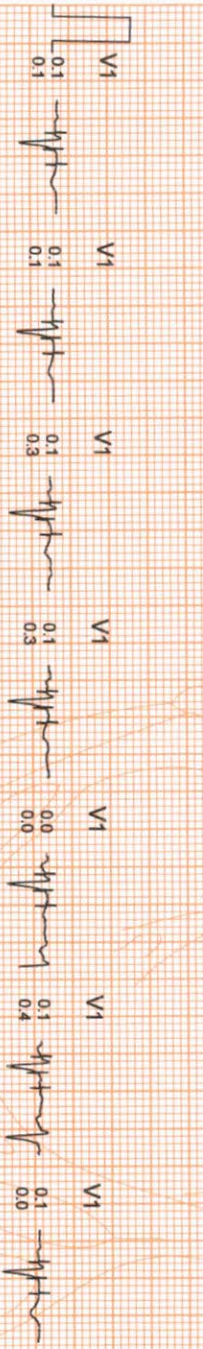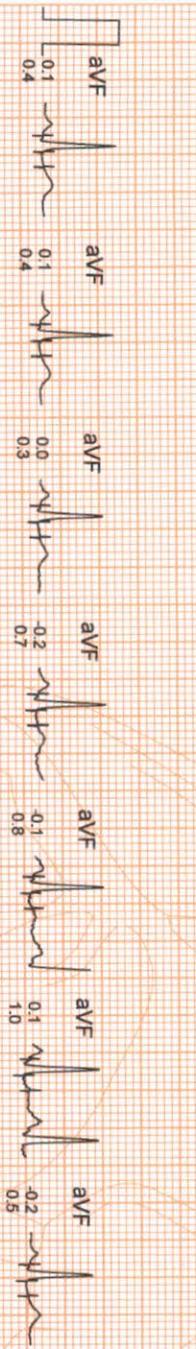
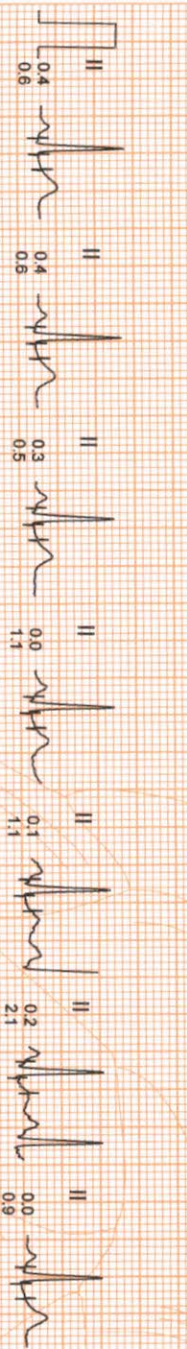
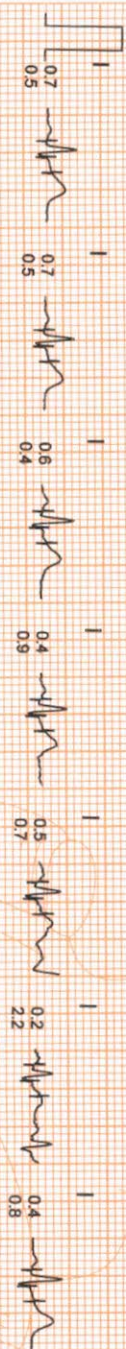
Computer Corrected Baseline

25mm/sec 10mm/mV

GREEN INDIA

CardiCom, INDIA Ph.:091-731-2620740, TeleFax:091-731-2431214

STANDING	SUPINE	STAGE 1	STAGE 2	STAGE 3	PEAK EXERCISE	RECOVERY
0.0kmph 0.0% 85 bpm B.P. 110/72 80ms Postu	0.0kmph 0.0% 84 bpm B.P. 110/72 80ms Postu	2:59 2:59 2.7kmph 10.0% 104 bpm B.P. 122/74 80ms Postu	5:59 2:59 4.0kmph 12.0% 114 bpm B.P. 134/78 80ms Postu	8:59 2:59 5.4kmph 14.0% 133 bpm B.P. 144/80 80ms Postu	9:39 0:39 6.7kmph 16.0% 167 bpm B.P. 150/84 80ms Postu	2:59 0:0% 79 bpm B.P. 116/74 80ms Postu



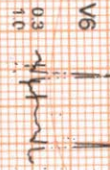

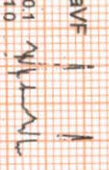
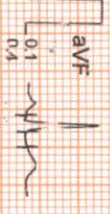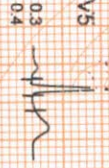
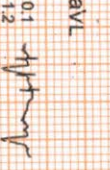

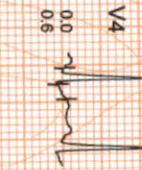
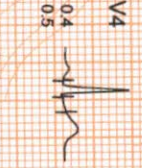
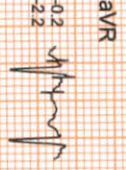
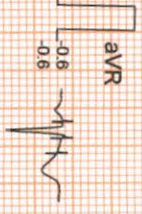
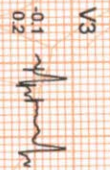
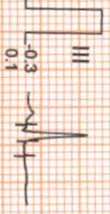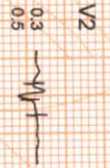
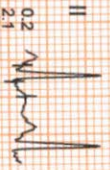
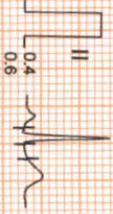
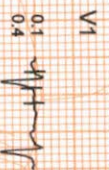
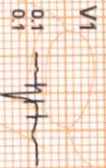
ONEPLUS ULTRASOUND LAB
 47, Harsih Vihar, Pitambur, Pune.
 Delhi-1100034
 Ph. 011-42480101, 9536969135
 Email: onepplus@oneplusultrasound.com

SUPINE
 0.0kmph
 0.0%
 84 bpm
 B.P. 110/72
 80ms PostJ

PEAK EXERCISE
 9:39
 0:39
 6.7kmph
 16.0%
 187 bpm
 B.P. 150/84
 80ms PostJ

SUPINE
 0.0kmph
 0.0%
 84 bpm
 B.P. 110/72
 80ms PostJ

PEAK EXERCISE
 9:39
 0:39
 6.7kmph
 16.0%
 167 bpm
 B.P. 150/84
 80ms PostJ



ONEPLUS ULTRASOUND LAB
 47, Hansh Vihar, Pitam Pura
 Delhi-110034
 Ph. 011-42480101, 42480102
 E-mail: oneplusul@gmail.com



OnePLUS
Ultrasound Lab

— QUALITY FIRST... ALWAYS! —

Dr. Nitin Agarwal

Pathologist & Director
Ex. Sr. Res. MAMC
& Lok Nayak Hospital
Ex. Chief of Lab Dr. Lal Path Labs.

Dr. Pooja (Garg) Agarwal

Radiologist & Director
MAMC & Lok Nayak Hospital

Name	: Mrs. KRITIKA NAGDEV RAISETIA	Age/Sex	: 35 YRS/Female
Ref. By	: Dr. MEDIWHEEL	Lab No	: 012303060007
Date	: 06-Mar-2023	Patient ID	: LSHHI110221

ULTRASOUND EXAMINATION----WHOLE ABDOMEN

Liver is normal in size (13.6 cm) and outline with normal echopattern. No abscess or mass lesion seen. Hepatic veins, portal vein, IVC and aorta are normal. Intrahepatic biliary radicles are not dilated. CBD is normal in caliber.

Gall bladder is partially distended. **A single mobile calculus is seen in the gallbladder neck measuring upto 14 mm.** Gallbladder walls are not thickened. Local tenderness over gallbladder is absent.

Both kidneys are normal in size, shape, position, outline and echopattern. Corticomedullary differentiation is maintained. No pelvicalyceal dilation or calculus or mass lesion is seen.

Spleen is normal in size and echotexture. No mass lesion seen.

Pancreas is normal in size, outline and echotexture

Urinary bladder is normal in shape and position. No evidence of intravesical stone or mass seen.

Uterus is normal in size (measures 6.9 x 4.7 x 3.0 cm), shape, position and echopattern. No mass seen.

Uterine cavity is empty. **Endometrial thickness** is 4.4 mm.

Both ovaries appear normal in size, shape and echopattern. No tubo-ovarian mass seen.

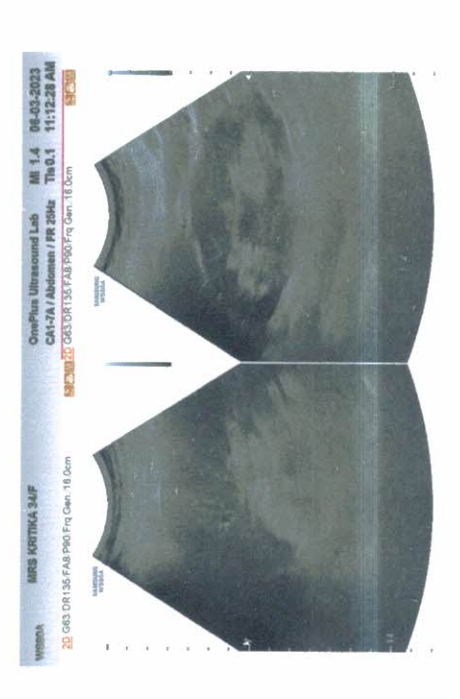
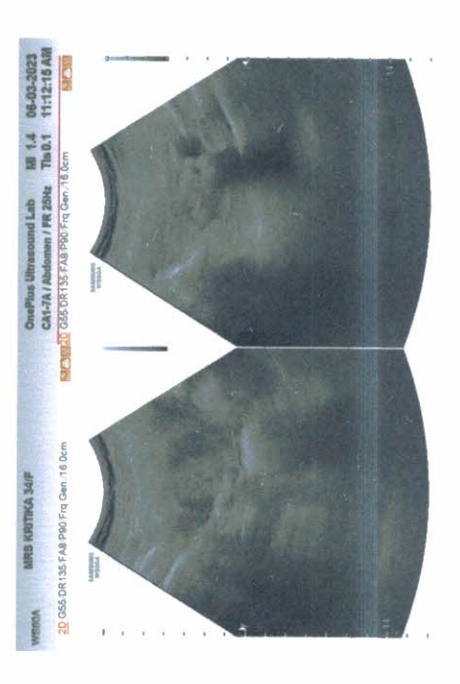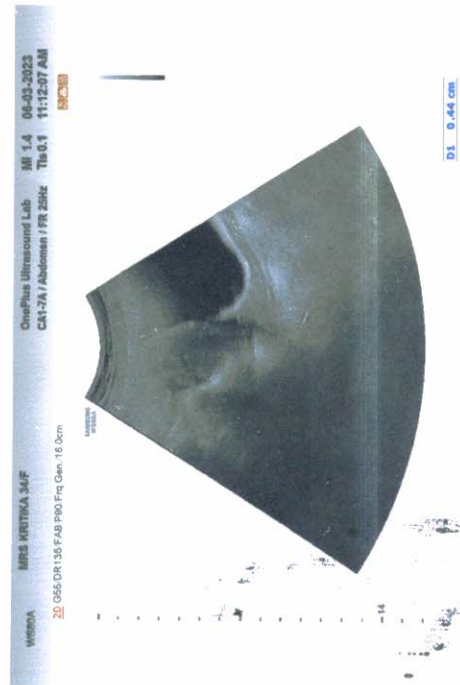
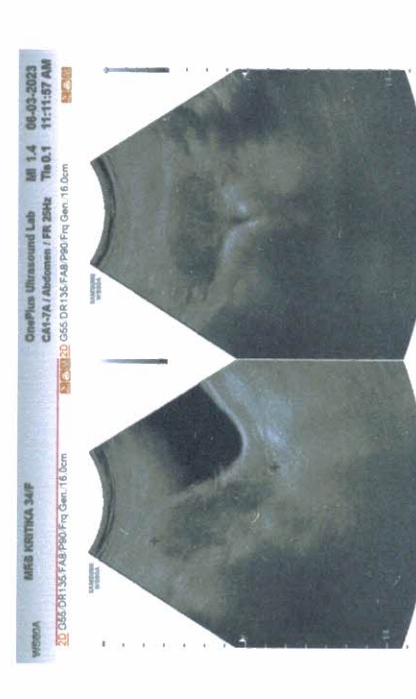
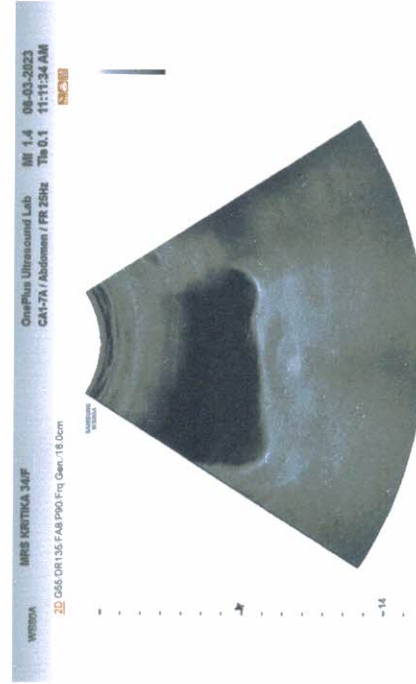
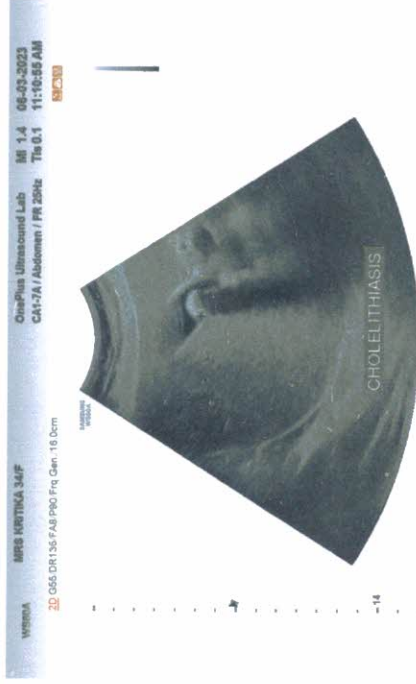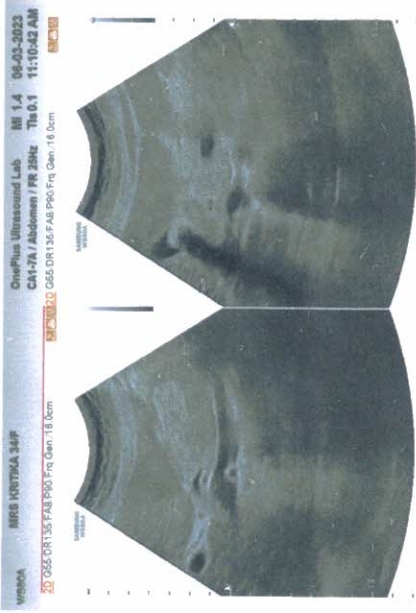No abnormal bowel wall thickening seen in right iliac fossa.
No free fluid seen anywhere in abdomen.

IMPRESSION: Cholelithiasis.

Dr. POOJA GARG
M.B.B.S., D.M.R.D.
Reg No. DMC/R/03398
Radiologist
REG NO. DMC/R/03398

Type By : darshita

47, Harsh Vihar, Pitampura, New Delhi-110034 | Ph.: 011-42480101, 9599913051
E-mail: oneplusul@gmail.com | Web.: www.oneplusul.in



D1 13.39 cm

D1 6.08 cm
D2 3.08 cm
D3 4.78 cm

D1 0.44 cm



OnePLUS Ultrasound Lab

— QUALITY FIRST... ALWAYS! —

Dr. Nitin Agarwal
Pathologist & Director
Ex. Sr. Res. MAMC
& Lok Nayak Hospital
Ex. Chief of Lab Dr. Lal Path Labs.

Dr. Pooja (Garg) Agarwal
Radiologist & Director
MAMC & Lok Nayak Hospital



NAME	:Mrs. KRITIKA NAGDEV RAISETIA	Barcode No	:10139315
AGE/GENDER	:35 YRS/Female	SPECIMEN DATE	:06/Mar/2023 09:13AM
PATIENT ID	:110221	SPECIMEN RECEIVED	:06/Mar/2023 09:18AM
REFERRED BY	:Dr. MEDIWHEEL	REPORT DATE	:06/Mar/2023 11:27AM
CENTRE NAME	:ONEPLUS ULTRASOUND LAB	LAB NO.	:012303060007

Test Name	Result	Unit	Ref. Range
-----------	--------	------	------------

HAEMATOLOGY

Medi Wheel Health checkup < 40 Female

Glycosylated Hemoglobin (HbA1c)	5.1	%	Non Diabetic adults <5.7 Prediabetic (at risk) 5.7-6.4 Diabetes >6.4
--	-----	---	--

Estimated average blood glucose (eag)	100
--	-----

Reference range (mg/dl):

90 - 120:Excellent control, 121 - 150:Good Control, 151 - 180:Average Control, 181 - 210:Action Suggested

>211:Panic value

BLOOD GROUP (ABO)	O
Rh typing	POSITIVE

NOTE :

- * Apart from major A,B,H antigens which are used for ABO grouping and Rh typing, many minor blood group antigens exist. Agglutination may also vary according to titre of antigen and antibody.
- * So before transfusion, reconfirmation of blood group as well as cross-matching is needed.
- * Presence of maternal antibodies in newborns, may interfere with blood grouping.
- * Auto agglutination (due to cold antibody, falciparum malaria, sepsis, internal malignancy etc.) may also cause erroneous result.

CBC

Haemoglobin	11.8	g/dl	11.5-15.0
Total Leucocyte Count	7900	/cumm	4000-10000
Differential leucocyte count			
Neutrophils	66.9	%	40-80
Lymphocyte	28.50	%	20-40
Monocytes	2.00	%	2-10
Eosinophils	2.0	%	1-6
Basophils	0.6	%	0-2
RBC Count	4.40	million/cumm	3.8-4.8

Checked By.

Dr. NITIN AGARWAL
MBBS, MD (PATHOLOGIST)
DMC/R/01436

47, Harsh Vihar, Pitampura, New Delhi-110034 | Ph.: 011-42480101, 9599913051

E-mail: oneplusul@gmail.com | Web.: www.oneplusul.in

Page 1 of 5



OnePLUS Ultrasound Lab

— QUALITY FIRST... ALWAYS! —

Dr. Nitin Agarwal
Pathologist & Director
Ex. Sr. Res. MAMC
& Lok Nayak Hospital
Ex. Chief of Lab Dr. Lal Path Labs.

Dr. Pooja (Garg) Agarwal
Radiologist & Director
MAMC & Lok Nayak Hospital



NAME	:Mrs. KRITIKA NAGDEV RAISETIA	Barcode No	:10139315
AGE/GENDER	:35 YRS/Female	SPECIMEN DATE	:06/Mar/2023 09:13AM
PATIENT ID	:110221	SPECIMEN RECEIVED	:06/Mar/2023 09:18AM
REFERRED BY	:Dr. MEDIWHEEL	REPORT DATE	:06/Mar/2023 11:27AM
CENTRE NAME	:ONEPLUS ULTRASOUND LAB	LAB NO.	:012303060007

Test Name	Result	Unit	Ref. Range
PCV(Hematocrit)	39.3	%	36-46
MCV	89.8	fL	83-101
MCH	27	Pg	27-32
MCHC	30	G/dL	32-35
Platelet count	277000	/cumm	150000-450000
RDW-CV	14.1	%	11.4-14.0
ESR(WESTEGRENs METHOD)	10	mm/1hr	<20

BIOCHEMISTRY

<u>Blood sugar fasting</u>	91	mg/dL	70-110
<u>Bun (blood urea nitrogen)</u>	14.30	mg/dl	7-18.7
<u>Uric acid, serum</u>	4.2	mg/dl	2.6-6.0
<u>Creatinine, serum</u>	0.5	mg/dl	0.50-1.0

LFT(LIVER FUNCTION TEST)

Bilirubin Total	0.54	mg/dl	0.1-1.2
Bilirubin Conjugated	0.21	mg/dl	0-0.4
Bilirubin Unconjugated	0.33	mg/dl	up to 0.7
SGOT (AST)	42	U/L	0-46
SGPT (ALT)	41	U/L	0-49
Alkaline phosphatase	95	U/L	35-104
Gamma glutamyl transpeptidase	26	U/L	5.0-32.0
Total Protein	6.9	gm/dl	6.60 - 8.70
Albumin serum	3.9	g/dL	3.0-5.2
Globulin	3.00	gm/dl	1.8-3.4
Albumin/Globulin Ratio	1.30		1.10 - 2.50

LIPID PROFILE

Cholesterol	144	mg/dl	50-200
Triglycerides	50	mg/dL	25-150
HDL Cholesterol	47	mg/dL	40 - 60

Checked By.

Dr. NITIN AGARWAL
MBBS, MD (Pathology)
DMC/R/01436
MBBS, MD (PATHOLOGIST)

47, Harsh Vihar, Pitampura, New Delhi-110034 | Ph.: 011-42480101, 9599913051

E-mail: oneplusul@gmail.com | Web.: www.oneplusul.in

Page 2 of 5



OnePLUS
Ultrasound Lab
— QUALITY FIRST... ALWAYS! —

Dr. Nitin Agarwal

Pathologist & Director
Ex. Sr. Res. MAMC
& Lok Nayak Hospital
Ex. Chief of Lab Dr. Lal Path Labs.

Dr. Pooja (Garg) Agarwal

Radiologist & Director
MAMC & Lok Nayak Hospital



NAME	:Mrs. KRITIKA NAGDEV RAISETIA	Barcode No	:10139315
AGE/GENDER	:35 YRS/Female	SPECIMEN DATE	:06/Mar/2023 09:13AM
PATIENT ID	:110221	SPECIMEN RECEIVED	:06/Mar/2023 09:18AM
REFERRED BY	:Dr. MEDIWHEEL	REPORT DATE	:06/Mar/2023 11:27AM
CENTRE NAME	:ONEPLUS ULTRASOUND LAB	LAB NO.	:012303060007

Test Name	Result	Unit	Ref. Range
LDL cholesterol	87	mg/dL	< 130
VLDL cholesterol	10.0	mg/dL	5-40
Cholesterol/HDL Ratio	3.1		Low Risk 3.3-4.97 Average Risk 4.4-7.1 Moderate Risk 7.1-11.0 High Risk >11.0
LDL/HDL Ratio	1.8		0 - 3.55

According to ATP III and NCEP guidelines

Parameter	Normal	Desirable	Borderline	High
Total cholesterol	<200		200-239	240
Triglycerides	<150	150-199	200-499	500
LDL	Optimal <100 Near Optimal 100-129	130-159	160-180	190
HDL	<40 : LOW 60 : HIGH			

BUN/Creatinine ratio

Bun (blood urea nitrogen)	14.30	mg/dl	7-18.7
CREATININE	0.50	mg/dl	0.30-1.10
BUN/Creatinine ratio	28.60		10.0 - 20.0

ENDOCRINOLOGY

THYROID PROFILE(T3,T4,TSH)

Triiodothyronine total [t3]	0.86	ng/dl	0.52-1.9
Thyroxine total [t4]	9.50	µg/dl	4.8-11.6
TSH (Thyroid Stimulating Hormone)	3.10	µIU/ml	0.25-5.0

AGE WISE VARIATION IN TSH

AGE	TSH(µIU/ml)	AGE	TSH(µIU/ml)
-----	-------------	-----	-------------

Checked By.

Dr. NITIN AGARWAL
M B B S , MD (Path)
MBBS,MD(PATHOLOGIST)
DMC/R/01436

47, Harsh Vihar, Pitampura, New Delhi-110034 | Ph.: 011-42480101, 9599913051

E-mail: oneplusul@gmail.com | Web.: www.oneplusul.in



OnePLUS
Ultrasound Lab
— QUALITY FIRST... ALWAYS! —

Dr. Nitin Agarwal

Pathologist & Director
Ex. Sr. Res. MAMC
& Lok Nayak Hospital
Ex. Chief of Lab Dr. Lal Path Labs.

Dr. Pooja (Garg) Agarwal

Radiologist & Director
MAMC & Lok Nayak Hospital



NAME	:Mrs. KRITIKA NAGDEV RASETIA	Barcode No	:10139315
AGE/GENDER	:35 YRS/Female	SPECIMEN DATE	:06/Mar/2023 09:13AM
PATIENT ID	:110221	SPECIMEN RECEIVED	:06/Mar/2023 09:18AM
REFERRED BY	:Dr. MEDIWHEEL	REPORT DATE	:06/Mar/2023 11:27AM
CENTRE NAME	:ONEPLUS ULTRASOUND LAB	LAB NO.	:012303060007

Test Name	Result	Unit	Ref. Range
1-4 weeks	1.00 - 19.0	16-20 yrs	0.25 - 5.0
1-12 mths	1.70 - 9.1	21 - 80 yrs	0.25 - 5.0
1-5 yrs	0.80 - 8.2	I st trimester	0.25 - 5.0
6-10 yrs	0.25 - 5.0	II nd trimester	0.50 - 5.0
11-15 yrs	0.25 - 5.0	II rd trimester	0.4 - 6.0

Reference ranges - Interpretation of Diagnostic tests - (Jacques Wallach)

1. Primary hypothyroidism is accompanied by depressed serum T3 and T4 values and elevated serum TSH level.
2. Primary hyperthyroidism is accompanied by elevated serum T3 and T4 levels along with depressed TSH values.
3. Slightly elevated T3 levels may be found in pregnancy and estrogen therapy, while depressed levels may be encountered in severe illness, renal failure and during therapy with drugs like propranolol and propyl thiouracil.
4. Although elevated TSH levels are nearly always indicative of primary hypothyroidism, and may be seen in secondary thyrotoxicosis

Checked By.

Dr. NITIN AGARWAL
M B B S , MD (Path)
DMC/R/01436
DR. NITIN AGARWAL
MBBS,MD(PATHOLOGIST)

47, Harsh Vihar, Pitampura, New Delhi-110034 | Ph.: 011-42480101, 9599913051
E-mail: oneplusul@gmail.com | Web.: www.oneplusul.in

Page 4 of 5

Clinical correlation is essential for final diagnosis. • If test results are unsatisfactory please contact personally or on phone. • This report is for perusal of doctors only.
• All disputes Subject to Delhi Jurisdiction only. • Not for medicolegal purposes. • All congenital anomalies in a foetus may not be diagnosed in routine obstetric ultrasound.



OnePLUS Ultrasound Lab

— QUALITY FIRST... ALWAYS! —

Dr. Nitin Agarwal
Pathologist & Director
Ex. Sr. Res. MAMC
& Lok Nayak Hospital
Ex. Chief of Lab Dr. Lal Path Labs.

Dr. Pooja (Garg) Agarwal
Radiologist & Director
MAMC & Lok Nayak Hospital



NAME	:Mrs. KRITIKA NAGDEV RAISETIA	Barcode No	:10139315
AGE/GENDER	:35 YRS/Female	SPECIMEN DATE	:06/Mar/2023 09:13AM
PATIENT ID	:110221	SPECIMEN RECEIVED	:06/Mar/2023 09:18AM
REFERRED BY	:Dr. MEDIWHEEL	REPORT DATE	:06/Mar/2023 04:21PM
CENTRE NAME	:ONEPLUS ULTRASOUND LAB	LAB NO.	:012303060007

Test Name	Result	Unit	Ref. Range
-----------	--------	------	------------

CLINICAL PATHOLOGY

URINE ROUTINE

Physical examination

Quantity	20		ML
Colour	PALE YELLOW		
Transparency	CLEAR		CLEAR
Sp.gravity	1.015		1.010-1.030
pH	6.00		
Reaction	ACIDIC		ACIDIC

Chemical examination

Urine protein	NIL		NIL
Urine sugar	NIL		NIL
Bilirubin, urine	NEGATIVE		NEGATIVE
Urobilinogen	NORMAL		NORMAL
Ketones	NEGATIVE		NEGATIVE

Microscopic examination

Pus cells.	1-2	/HPF	1-2
Epithelial cells	1-2	/HPF	0-5
R.B.C.	NIL	/HPF	NIL
Casts	NIL	/HPF	NIL
Crystals	NIL	/HPF	NIL
Bacteria	NIL	/HPF	NIL
Others.	NIL		NIL

*** End Of Report ***

Checked By.

Dr. NITIN AGARWAL
M B B S, MD (Path)
DMC/R/01436
DR. NITIN AGARWAL
MBBS, MD (PATHOLOGIST)

47, Harsh Vihar, Pitampura, New Delhi-110034 | Ph.: 011-42480101, 9599913051

E-mail: oneplusul@gmail.com | Web.: www.oneplusul.in

Page 5 of 5

Name	: Mrs. KRITIKA NAGDEV RAISETIA	Age/Sex	: 35 YRS/Female
Ref. By	: Dr. MEDIWHEEL	Lab No	: 012303060007
Date	: 06-Mar-2023	Patient ID	: LSHHI110221

X-ray-Chest PA view

Bony cage and soft tissues are normal.
Cardiothoracic ratio is normal.
Mediastinum is normal.
Both hila are normal.
Both costophrenic angles are clear.
Both domes of diaphragm are normal.
Lung fields are clear. No parenchymal lesion seen.

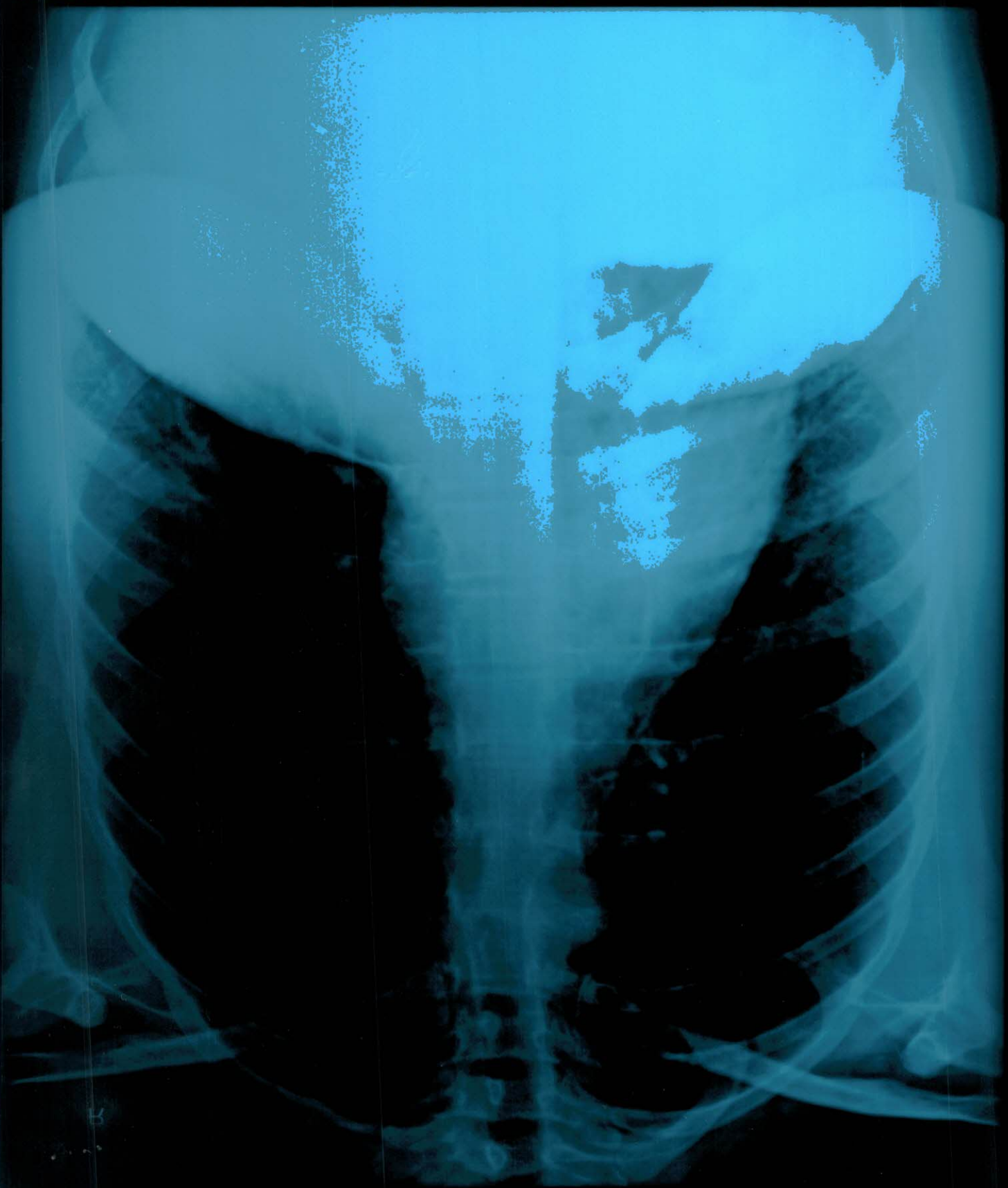
IMPRESSION: Normal Study.

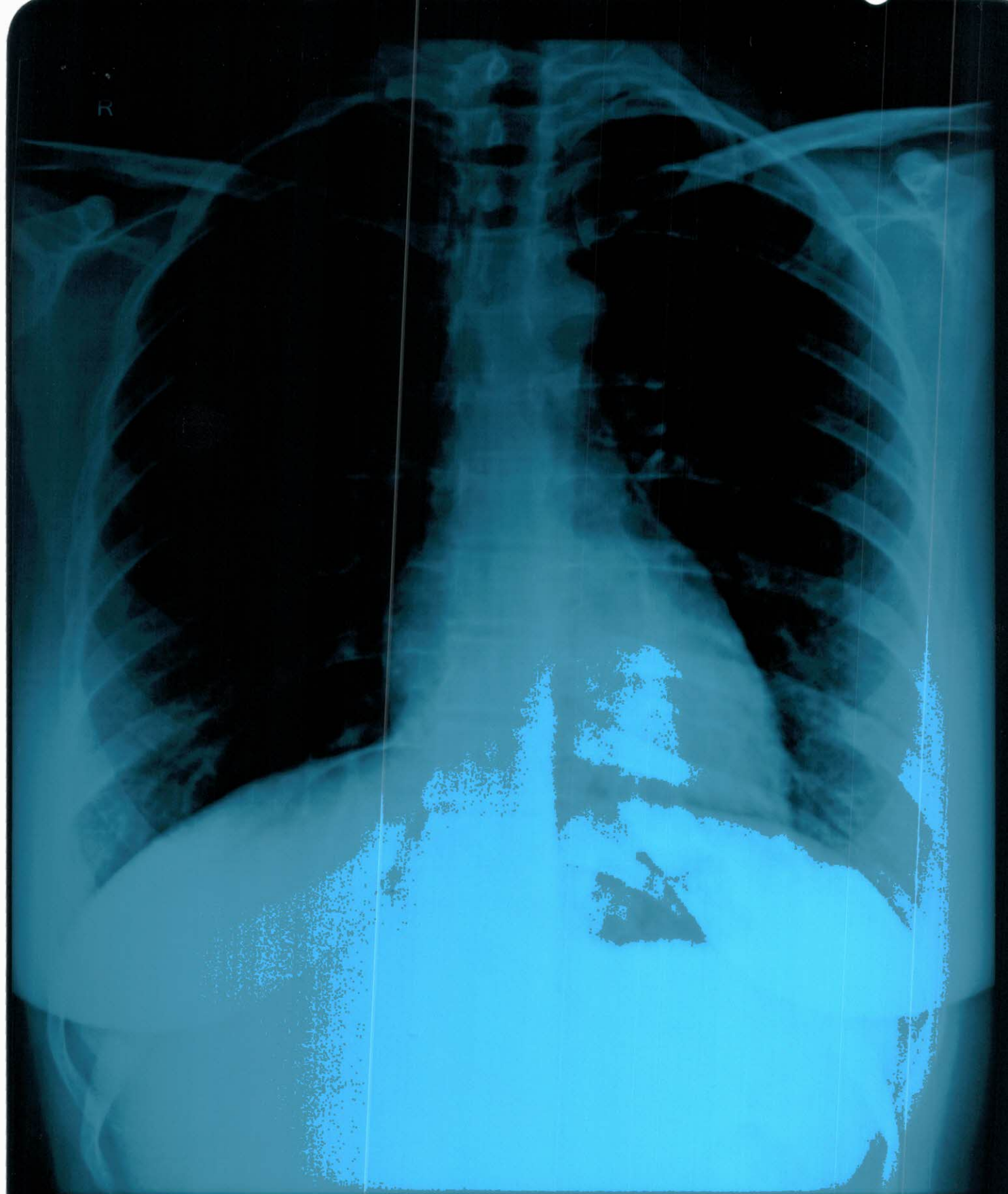
Dr. POOJA GARG
M.B.B.S., D.M.R.D.
Reg No. DMC/R/03398
Radiologist
REG NO. DMC/R/03398

Type By : POOJA

47, Harsh Vihar, Pitampura, New Delhi-110034 | Ph.: 011-42480101, 9599913051
E-mail: onepusul@gmail.com | Web.: www.oneplusul.in

ОИЕБГУС ПГТРАСОИИД ГАВ АТ НАРГН АИНАР ПТАМЬУРА
МБС КВІІКА ИАСДЕЛ 34 УРС 01315033 Е CHEST PA VIEW





MRS. KRITIKA NAGDEV 34 YRS 6/3/2023 F CHEST PA VIEW
ONEPLUS ULTRASOUND LAB.47-HARSH VIHAR.PITAMPURA