



Shubham Imaging & ALC Diagnostic Center

ISO 9001:2015 Certified center

(A Unit of P.K. Arogyam Health & Wellness Center)

E-95, P.C. Colony, Near Sai Netryalaya Transformer, Kankarbagh, Patna - 20

alcdiagnostics@gmail.com

www.pkarogayamhealthcheckup.com

7050037694, 8271206196


OPINION MUST BE CORRELATES WITH CLINICALLY & OTHER INVESTIGATION FOR FINAL DIAGNOSIS. NOT FOR MEDICO LEGAL PURPOSE

PATIENT NAME : Mr. KUMAR AJAY PATIENT ID: 1757
COL DATE : 23/09/2023 REPORTING DATE: 23/09/2023 AGE SEX : 30 YRS/F
REF.BY : DR. / MEDIWHEEL

| TEST NAME | RESULT | Unit | REF.RANGE |
|--------------------|-------------|------|----------------|
| BLOOD SUGAR (F) | 82.0 mg/dl | | 70 - 110 mg/dl |
| BLOOD SUGAR (PP) | 129.0 mg/dl | | 70 - 140 mg/dl |

LIPID PROFILE:-

| | | | |
|------------------|-------------|--|----------------|
| TOTAL CHOLESTROL | 198.5 mg/dl | | 130 -250 mg/dl |
| TRIGLYCERIDE | 145.2 mg/dl | | 50 -160 mg/dl |
| HDL CHOLESTROL | 45.6 mg/dl | | 30 - 60 mg/dl |
| LDL CHOLESTROL | 123.9 mg/dl | | 80 -130 mg/dl |
| VLDL CHOLESTROL | 29.0 mg/dl | | 15 - 40 mg/dl |
| T.CH./HDL RATIO | 4.3 : 1 | | Upto 5 :1 |
| LDL /HDL RATIO | 2.7 : 1 | | 2 - 4:1 |


23/09/2024
Consultant Radiologist

ESTB BY:-

Dr. P. K. Tiwari
MD, M.Sc (Radio Imaging)
Ph.D (Alt Nuclear Medicine)
Consultant Imagonologist & Sonologist

Dr. S. Kumar
MD (Pat)
Consultant Pathologist

Dr. Abhishek Kumar
MBBS, MD
Consultant Neuropatho Physiologist

Dr. Kumari Suman
MBBS, DGO, MD
Consultant (TVS & HSG Specialist)

Dr. A. K. Singh
MBBS, PGDMCH
Consultant Radiologist & Sonologist

PRINTING MISTAKE SHOULD BE REPORTED BACK IMMEDIATELY/यहाँ जन्म से पहले भ्रुण का लिंग जाँच नहीं होता

Shubham Imaging & ALC Diagnostic Center

ISO 9001:2015 Certified center

(A Unit of P.K. Arogyam Health & Wellness Center)

E-95, P.C. Colony, Near Sai Netryalaya Transformer, Kankarbagh, Patna - 20

cdiagnostics@gmail.com

www.pkarogyamhealthcheckup.com

7050037694, 8271206196

OPINION MUST BE CORRELATES WITH CLINICALLY & OTHER INVESTIGATION FOR FINAL DIAGNOSIS. NOT FOR MEDICO LEGAL PURPOSE

PATIENT NAME : Mr. KUMAR AJAY

PATIENT ID: 1757

COL DATE : 23/09/2023 REPORTING DATE: 23/09/2023 AGE SEX:- 34 YRS/M

REF.BY : DR. / MEDIWHEEL .

| TEST NAME | RESULT | Unit | REF.RANGE |
|---------------------------|--------|-------|--|
| LFT:- | | | |
| SGPT | 48.6 | IU/L | 5 - 40 IU/L |
| SGOT | 35.2 | IU/L | 5 - 40 IU/L |
| ALKALINE PHOSPHATASE | 77.8 | IU/L | M - 53 - 165 IU/L F - 42 - 136 IU/L |
| TOTAL PROTIN | 7.8 | g/dl | 6.0 - 8.7 g/dl |
| SERUM ALBUMIN | 4.7 | g/dl | 3.5 - 5.4 g/dl |
| SERIUM GLUBLINE | 3.1 | g/dl | 2.3 - 3.6 g/dl |
| AG RATIO | 1.5: 1 | | 1.0 - 2.3 g/dl |
| BILIRUBIN | | | |
| TOTAL | 0.51 | mg/dl | 0.1 - 1.1 mg/dl |
| DIRECT | 0.22 | mg/dl | 0.0 - 0.32 mg/dl |
| INDIRECT | 0.29 | mg/dl | 0.0 - 0.78 mg/dl |
| GGTP(GGT) | 19.9 | iu/L | 8 - 38 iu/L |
| KFT/RFT | | | |
| URIC ACID | 4.9 | mg/dl | 3.2 - 7.0 mg/dl |
| SERUM CREATNINE | 1.1 | mg/dl | 0.6 - 1.5 mg/dl |
| BLOOD URIA | 34.4 | mg/dl | 5 - 45 mg/dl |
| BLOOD URIA NITROZEN(BUN). | 16.0 | mg/dl | 5 - 23 mg/dl |

A.K.S.
23/09/2023

Consultant Radiologist

ESTB BY:-

Dr. P. K. Tiwari
MD, M.Sc (Radio Imaging)
Ph.D (Alt Nuclear Medicine)
Consultant Imagonologist & Sonologist

Dr. S. Kumar
MD (Pat)
Consultant Pathologist

Dr. Abhishek Kumar
MBBS, MD
Consultant Neuropatho Physiologist

Dr. Kumari Suman
MBBS, DGO, MD
Consultant (TVS & HSG Specialist)

Dr. A. K. Singh
MBBS, PGDMCH
Consultant Radiologist & Sonologist

PRINTING MISTAKE SHOULD BE REPORTED BACK IMMEDIATELY/ यहाँ जन्म से पहले भ्रुण का लिंग जाँच नहीं होता है

Shubham Imaging & ALC Diagnostic Center

ISO 9001:2015 Certified center

(A Unit of P.K. Arogyam Health & Wellness Center)

E-95, P.C. Colony, Near Sai Netryalaya Transformer, Kankarbagh, Patna - 20

diagnostics@gmail.com

www.pkarogayamhealthcheckup.com

7050037694, 8271206196

OPINION MUST BE CORRELATES WITH CLINICALLY & OTHER INVESTIGATION FOR FINAL DIAGNOSIS. NOT FOR MEDICO LEGAL PURPOSE


PATIENT NAME : KUMAR AJAY

PATIENT ID: 2055

COL DATE : 08/10/2022 REPORTING DATE: 08/10/2022 AGE SEX:- 30 YRS/F

REF.BY : DR. / MEDIWHEEL .

| TEST NAME | RESULT | Unit | REF.RANGE |
|-------------------------------------|------------------------|------|----------------------|
| ESR | 10 mm/hr | | <20 mm/hr |
| CBC | | | |
| Total W.B.C. Count | 8,700 /cumm | | 4000 - 11,000 /cumm |
| R B C COUNT | 5.04 Million/ CUmm | | 4 - 7 Million/ CUmm |
| Platelets count | 1.76 Lakh/ cumm | | 1.5 - 5.0 Lakh/ cumm |
| Differential Count of W.B.C. | | | |
| Neutrophils | 65 % | | 40 -70% |
| Lymphocytes | 31 % | | 25 - 40% |
| Eosinophils | 03 % | | 01 - 05% |
| Mnonocytes | 01 % | | 00 - 02% |
| Basophiles | 00 % | | 00 - 0% |
| HAEMOGLOBIN | 14.9 gm/dl (102.0 %) | | 14.6 gm/dl = 100% |
| PCV | 47.6 % | | 35 - 47 % |
| MCV | 89.6 fl | | 76 - 96 fl |
| MCH | 31.5 pg | | 29 - 35 pg |
| MCHC | 34.7 % | | 30 - 38 % |


22/09/2023

Consultant Radiologist

ESTB BY:-

Dr. P. K. Tiwari
MD, M.Sc (Radio Imaging)
Ph.D (Alt Nuclear Medicine)
Consultant Imagonologist & Sonologist

Dr. S. Kumar
MD (Pat)
Consultant Pathologist

Dr. Abhishek Kumar
MBBS, MD
Consultant Neuropatho Physiologist

Dr. Kumari Suman
MBBS, DGO, MD
Consultant (TVS & HSG Specialist)

Dr. A. K. Singh
MBBS, PGDMCH
Consultant Radiologist & Sonologist

PRINTING MISTAKE SHOULD BE REPORTED BACK IMMEDIATELY/ यहाँ जन्म से पहले भ्रुण का लिंग जाँच नहीं होता है

Shubham Imaging & ALC Diagnostic Center

ISO 9001:2015 Certified center

(A Unit of P.K. Arogyam Health & Wellness Center)

E-95, P.C. Colony, Near Sai Netryalaya Transformer, Kankarbagh, Patna - 20

alcdiagnostics@gmail.com

www.pkarogayamhealthcheckup.com

7050037694, 8271206196

OPINION MUST BE CORRELATES WITH CLINICALLY & OTHER INVESTIGATION FOR FINAL DIAGNOSIS. NOT FOR MEDICO LEGAL PURPOSE

PATIENT NAME : KUMAR AJAY

PATIENT ID : 1757

COL DATE : 24/09/2023 REPORTING DATE: 24/09/2023 AGE SEX : 34 YRS/M

REF.BY : DR./ MEDIWHEEL.

GLYCOSYLATED HEMOGLOBIN

| TEST NAME | RESULT | Unit | REF.RANGE |
|------------------------|-------------|------|---|
| HbA1c | 4.6 % | | Below 5.7 % : Normal 5.7 – 6.4 % : Prediabetic > = 6.5 % : Diabetic |
| AVERAGE PLASMA GLUCOSE | 102.0 mg/dl | | 90 – 120 mg/dl : Good Control 121– 150 mg/dl : Fair Control 151- 180 mg/dl: Unsatisfactory Control >180 mg/dl : Poor Control |

AK
24/09/2023

Consultant Radiologist

ESTB BY:-

Dr. P. K. Tiwari
MD, M.Sc (Radio Imaging)
Ph.D (Alt Nuclear Medicine)
Consultant Imagonologist & Sonologist

Dr. S. Kumar
MD (Pat)
Consultant Pathologist

Dr. Abhishek Kumar
MBBS, MD
Consultant Neuropatho Physiologist

Dr. Kumari Suman
MBBS, DGO, MD
Consultant (TVS & HSG Specialist)

Dr. A. K. Singh
MBBS, PGDMCH
Consultant Radiologist & Sonologist

PRINTING MISTAKE SHOULD BE REPORTED BACK IMMEDIATELY/यहाँ जन्म से पहले भ्रुण का लिंग जाँच नहीं होता है

Shubham Imaging & ALC Diagnostic Center

ISO 9001:2015 Certified center

(A Unit of P.K. Arogyam Health & Wellness Center)

E-95, P.C. Colony, Near Sai Netryalaya Transformer, Kankarbagh, Patna - 20

alcdiagnostics@gmail.com

www.pkarogyamhealthcheckup.com

7050037694, 8271206196

OPINION MUST BE CORRELATES WITH CLINICALLY & OTHER INVESTIGATION FOR FINAL DIAGNOSIS. NOT FOR MEDICO LEGAL PURPOSE

PATIENT NAME : Mr.KUMAR AJAY

PATIENT ID: 1757

COL DATE : 23/09/2023 REPORTING DATE: 23/09/2023 AGE SEX : 34 YRS/M

REF.BY : DR. / MEDIWHEEL.

| TEST NAME | RESULT | Unit | REF.RANGE |
|-----------|--------|------|-----------|
|-----------|--------|------|-----------|

BLOOD GROUP : ' B '

Rh Typing : POSITIVE

Note: Do always cross – matching before blood transfusion

ATD
23/09/2023

Consultant Radiologist

ESTB BY:-

Dr. P. K. Tiwari
MD, M.Sc (Radio Imaging)
Ph.D (Alt Nuclear Medicine)
Consultant Imagonologist & Sonologist

Dr. S. Kumar
MD (Pat)
Consultant Pathologist

Dr. Abhishek Kumar
MBBS, MD
Consultant Neuropatho Physiologist

Dr. Kumari Suman
MBBS, DGO, MD
Consultant (TVS & HSG Specialist)

Dr. A. K. Singh
MBBS, PGDMCH
Consultant Radiologist

Shubham Imaging & ALC Diagnostic Center

ISO 9001:2015 Certified center

(A Unit of P.K. Arogyam Health & Wellness Center)

E-95, P.C. Colony, Near Sai Netryalaya Transformer, Kankarbagh, Patna - 20

shubhamdiagnostics@gmail.com

www.pkarogyamhealthcheckup.com

7050037694, 8271206196

OPINION MUST BE CORRELATES WITH CLINICALLY & OTHER INVESTIGATION FOR FINAL DIAGNOSIS. NOT FOR MEDICO LEGAL PURPOSE

PATIENT NAME : Mr. KUMAR AJAY

PATIENT ID: 1757

COL DATE : 23/09/2023

REPORTING DATE: 23/09/2023

AGE SEX : 34 YRS/M

REF.BY : DR. / MEDIWHEEL..

ROUTINE EXAMINATION OF URINE

PHYSICAL EXAMINATION


| | | | |
|----------------------|-------|--------------|-------------|
| Quantity | 30 ml | Colour.... | Pale Yellow |
| Appearance... | Clear | Sediment ... | Nil |
| Specific gravity.... | 1.010 | | |

CHEMICAL EXAMINATION

| | | | |
|-------------------------|----------|------------------|----------|
| Reaction | 6.0 | Nitrite..... | Not done |
| Sugar | Nil | Bile Pigment ... | Not done |
| Albumin | Nil | Urobilinogen.... | Not done |
| Excess of Phosphate.... | Nil | Chile..... | Not done |
| Bile Salt | Not Done | Acetone... | Not done |

MICROSCOPIC EXAMINATION

| | | | |
|------------------|-----------|--------------|-----|
| Erythrocytes.... | Nil | Casts | Nil |
| Leucocytes | 1-3 / HPE | Crystals.... | Nil |
| Epith. Cell | A, Few | Others | Nil |


Consultant Radiologist

ESTB BY:-

Dr. P. K. Tiwari
MD, M.Sc (Radio Imaging)
Ph.D (Alt Nuclear Medicine)
Consultant Imaginationist & Sonologist

Dr. S. Kumar
MD (Pat)
Consultant Pathologist

Dr. Abhishek Kumar
MBBS, MD
Consultant Neuropathology & Physiologist

Dr. Kumari Suman
MBBS, DGO, MD
Consultant (TVS & HSG Specialist)

Dr. A. K. Singh
MBBS, PGDMCH
Consultant Radiologist & Sonologist

PRINTING MISTAKE SHOULD BE REPORTED BACK IMMEDIATELY/ यहाँ जन्म से पहले भ्रुण का लिंग जाँच नहीं होता है

Shubham Imaging & ALC Diagnostic Center

ISO 9001:2015 Certified center

(A Unit of P.K. Arogyam Health & Wellness Center)

E-95, P.C. Colony, Near Sai Netryalaya Transformer, Kankarbagh, Patna - 20

diagnostics@gmail.com

www.pkarogayamhealthcheckup.com

7050037694, 8271206196

OPINION MUST BE CORRELATES WITH CLINICALLY & OTHER INVESTIGATION FOR FINAL DIAGNOSIS. NOT FOR MEDICO LEGAL PURPOSE

PATIENT NAME : Mr. KUMAR AJAY

PATIENT ID : 1757

COL DATE : 23/09/2023 REPORTING DATE: 23/09/2023

AGE SEX : 34 YRS/M

REF.BY : DR. / MEDIWHEEL.

| Investigation | Result | Normal Range |
|--------------------------|------------|---------------------|
| Total Triiodothyronin T3 | 1.36 ng/mL | 0.80 - 2.00 µ ng/mL |
| Total Thyroxin T4 | 9.22 ug/mL | 5.10 - 14.10 ug/dL |
| Serum TSH | 3.73 µg/mL | 0.27 - 4.20 µg/mL |

THYROID DISORDER (>: Increase: < Decrease: n Normal

1. T3(n) T4(n) TSH(n) :EUTHYROID STATE:
2. T3(>) T4(>) TSH(<): HYPERTHYROIDISM:
3. T3(<)T4(<) TSH(>): HYPOTHYROIDISM:
4. T3(n)T4(n) TSH(>) : SUB-CLINICAL HYPO-THYROIDISM:
5. T3(n)T4(n) TSH(<): SUB-CLINICAL HYPER-THYROIDISM:
6. T3(>) T4(n) TSH(<): T3 THYROTOXICOSIS:

Total T3/T4 level is dependent on Level:

So determination of free T3/T4is a better MARKER of Thyroid Function.

*FREE T3/T4 ESTIMATION FACILITY IS AVAILABALE ON REQUEST.:

ESTB BY:-

Dr. P. K. Tiwari
MAD, M.Sc (Radio Imaging)
Ph.D (Alt Nuclear Medicine)
Consultant Imagianologist & Sonologist

Dr. S. Kumar
MD (Pat)
Consultant Pathologist

Dr. Abhishek Kumar
MBBS, MD
Consultant Neuropatho Physiologist

Dr. Kumari Suman
MBBS, DGO, MD
Consultant (TVS & HSG Specialist)

Dr. A. K. Singh
MBBS, PGDMCH
Consultant Radiologist & Sonologist

Consultant Radiologist

PRINTING MISTAKE SHOULD BE REPORTED BACK IMMEDIATELY/ यहाँ जन्म से पहले मरण का विनाश नहीं होता



Shubham Imaging & ALC Diagnostic Center

ISO 9001:2015 Certified center

(A Unit of P.K. Arogyam Health & Wellness Center)

E-95, P.C. Colony, Near Sai Netryalaya Transformer, Kankarbagh, Patna - 20

alcdiagnostics@gmail.com

www.pkarogayamhealthcheckup.com

7050037694, 8271206196

OPINION MUST BE CORRELATES WITH CLINICALLY & OTHER INVESTIGATION FOR FINAL DIAGNOSIS. NOT FOR MEDICO LEGAL PURPOSE

Pt. Name :- KUMAR AJAY
Ref. By :- DR. /MEDIWHEEL

Date:- 23-Sep-23
Age / Sex - 34 Yrs. M.

REAL TIME U.S.G. OF WHOLE ABDOMEN

Thanks for your kind referral

(Report.)

- LIVER** :- Measures 15.73 cm. Mild Enlarged in shape, size and echo texture fatty change seen in liver parenchyma .I.H.B.R. are not dilated. Hepatic veins are normal. No SOL seen.
- G.BL. :- Lumen is echo free. Wall thickness appears normal.
- C.B.D. :- Measures 3.5 mm in diameter with echo free lumen. No calculi or mass seen.
- P.V. :- Measures 7.7 mm in diameter. Appears normal. No thrombus seen.
- PANCREAS :- Normal in shape, size and echo texture. No calcification mass seen.
- SPLEEN :- Measures 10.99 cm. Normal in shape, size and echo texture.No SOL seen.
- KIDNEY :- Both kidney shows normal shape, size & echotexture. C.M.D.intact.
P.C.S.is not dilated.No calculi, cyst hydonephrosis mass seen. on either side.
Right Kidney :- Measures 9.12 X 4.40 cm.
Left Kidney :- Measures 9.14 X 4.50 cm.
- URETER :- Not dilated .No apparent calculi seen.
- U.BLADDER:- Shows normal in outline with echo free lumen. No calculi or mass seen.
Pre void - 350 ml. Post void - is in significant
- PROSTATE** :- Measures 10 gms.(approx). Appears Normal in size, shape, and echo texture. No calcification, mass, growth seen. capsule is intact.
- R.I.F. :- Son graphically no appendicular mass or collection seen.
- OTHERS :- No Ascites . no Lymph Adenopathy. No pleural effusion seen on either side .

IMPRESSION

- **Mild Hepatomegaly With Fatty Liver G-I**
- **Adv:- Further Work Up Other Investigation**
Otherwise son graphically normal scan. of rest organs

23/9/23

ESTB BY:-

Consultant Radiologist

Dr. P. K. Tiwari
MD, M.Sc (Radio Imaging)
Ph.D (Alt Nuclear Medicine)
Consultant Imajionologist & Sonologist

Dr. S. Kumar
MD (Pat)
Consultant Pathologist

Dr. Abhishek Kumar
MBBS, MD
Consultant Neuropatho Physiologist

Dr. Kumari Suman
MBBS, DGO, MD
Consultant (TVS & HSG Specialist)

Dr. A. K. Singh
MBBS, PGDMCH
Consultant Radiologist & Sonologist

CARDIOPRINT

ID: 1757 CASE: KUMAR AJAY
AGE: 34Y 0M 0D MALE
156Cms 84Kg

23/09/2023 10:45:45
ALC ADVANCE IMAGING DIAGNOSTICS
E95 PC COLONY KANKARBAGH PATNA

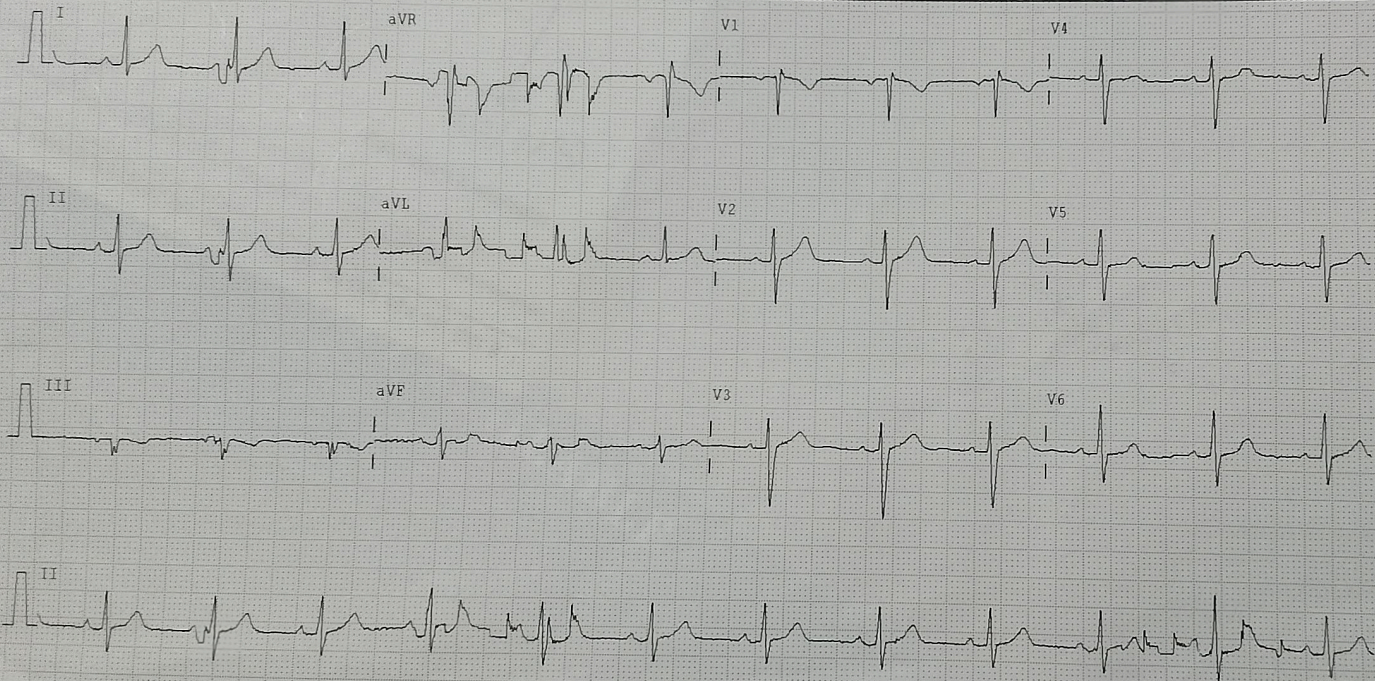
RATE : 73 bpm SINUS RHYTHM
R-R : 817 ms
P-R : 148 ms
QRS : 86 ms
QT : 376 ms
QTc : 399 ms

--AXIS--
P : 16°
QRS : 02° NORMAL ECG
T : 16°

12 SL: REPORT FORMAT: 3x4+1L SQ

REF: DR BOB

Dr. DR ABHISHEK KUMAR MD





Shubham Imaging & ALC Diagnostic Center

ISO 9001:2015 Certified center

(A Unit of P.K. Arogyam Health & Wellness Center)

E-95, P.C. Colony, Near Sai Netryalaya Transformer, Kankarbagh, Patna - 20

www.pkarogayamhealthcheckup.com

7050037694, 8271206196

alcdiagnostics@gmail.com

OPINION MUST BE CORRELATES WITH CLINICALLY & OTHER INVESTIGATION FOR FINAL DIAGNOSIS. NOT FOR MEDICO LEGAL PURPOSE

ECHOCARDIOGRAPHY & COLOR DOPPLER REPORT

Patient's Name: KUMAR AJAY

Age/Sex: 26 Yrs /M

Ref. by - Dr. / MEDIWHEEL

Date : 23-Sep-23

ECHO CARDIOGRAPHIC WINDOW : Good

2D & M MODE ECHOCARDIOGRAPHY

Left ventricle

| | | | | | |
|---------------------------|-----|------------------------------------|-------------|----|----------------------------------|
| EDD: | 44 | mm (20 - 28 mm / m ²) | ESD: | 29 | mm(13 - 21 mm / m ²) |
| IVS : | 10 | mm (6 - 11 mm) | PW: | 10 | mm(6 - 11 mm) |
| Ejection fraction: | 62% | (67 ± 8%) | FS: | 42 | %(34 - 44 %) |

Left atrium/ Aorta 35/25 mm

Right ventricle Normal

Right atrium Normal

Pericardium Normal with no pericardial effusion

2D: Normal LA & LV Size and normally contracting left ventricle. No, RWMA, No LVH

Mitral valve

AML/ PML: Normal

Tricuspid valve Normal

Aortic valve Normal

Pulmonary valve Normal

Continuous & Pulse Wave Doppler study

| Valve | Velocity (m/sec) | | | Gradient (mmHg) | | | Valve area (PHT Method) | Regurg. |
|-----------|------------------|------|-----|-----------------|------|-----|----------------------------|---------|
| | Peak | Mean | EDV | Peak | Mean | EDG | | |
| Mitral | E=0.6 A=1.0 | | | 4.0 | 2.0 | | | Nil |
| Tricuspid | E=0.5 A=0.3 | | | 1 | 0.2 | | | Trivial |
| Aortic | 1.12 | | | 5.0 | 2.5 | | | Nil |
| Pulmonary | 0.9 | | | 3.5 | 1.7 | | | Nil |

ESTB BY:-

Consultant Radiologist

Dr. P. K. Tiwari

MD, M.Sc (Radio Imaging)

Ph.D (All Nuclear Medicine)

Consultant Imagiologist & Sonologist

Dr. S. Kumar

MD (Pat)

Consultant Pathologist

Dr. Abhishek Kumar

MBBS, MD

Consultant Neuropatho Physiologist

Dr. Kumari Suman

MBBS, DGO, MD

Consultant (TVS & HSG Specialist)

Dr. A. K. Singh

MBBS, PGDMCH

Consultant Radiologist & Sonologist

PRINTING MISTAKE SHOULD BE REPORTED BACK IMMEDIATELY/ यहाँ जन्म से पहले भुण का लिंग जाँच नहीं होता है ।

Shubham Imaging & ALC Diagnostic Center

ISO 9001:2015 Certified center

(A Unit of P.K. Arogyam Health & Wellness Center)

E-95, P.C. Colony, Near Sai Netryalaya Transformer, Kankarbagh, Patna - 20

cdiagnostics@gmail.com

www.pkarogayamhealthcheckup.com

7050037694, 8271206196

OPINION MUST BE CORRELATES WITH CLINICALLY & OTHER INVESTIGATION FOR FINAL DIAGNOSIS. NOT FOR MEDICO LEGAL PURPOSE

Colour Flow Imaging

No PR/AR/MR, Trivial TR,
No shunt flow

COMMENTS :

- ◆ Normal LA & LV Size
- ◆ Normal LV filling Pressure
- ◆ No RWMA , No LVH
- ◆ Normal LV systolic function
- ◆ Global LVEF = 63%
- ◆ Diastolic function Normal in Limits
- ◆ All cardiac valves are normal
- ◆ No MS / TS / AS / PS/PR
- ◆ No clot / vegetation / pericardial effusion
- ◆ Trivial TR, No PAH

IMPRESSION:

Normal LV Size & normally Contracting
Normal LV/RV systolic function, LVEF – 63%
Trivial TR, No PAH

Please correlate clinically

Ranjeet Kumar
23/9/23
DR. RANJEET KUMAR
MBBS, PGDCC, CCEBDM
CONSULTANT CARDIOLOGIST
EX- SENIOR REGISTRAR, RTIICS, KOLKATA

ESTB BY:-

Dr. P. K. Tiwari
MD, M.Sc (Radio Imaging)
Ph.D (Alt Nuclear Medicine)
Consultant Imagiologist & Sonologist

Dr. S. Kumar
MD (Pat)
Consultant Pathologist

Dr. Abhishek Kumar
MBBS, MD
Consultant Neuropatho Physiologist

Dr. Kumari Suman
MBBS, DGO, MD
Consultant (TVS & HSG Specialist)

Dr. A. K. Singh
MBBS, PGDMCH
Consultant Radiologist & Sonologist

Consultant Radiologist



Shubham Imaging & ALC Diagnostic Center

ISO 9001:2015 Certified center

(A Unit of P.K. Arogyam Health & Wellness Center)

E-95, P.C. Colony, Near Sai Netryalaya Transformer, Kankarbagh, Patna - 20

alcdiagnostics@gmail.com

www.pkarogayamhealthcheckup.com

7050037694, 8271206196

OPINION MUST BE CORRELATES WITH CLINICALLY & OTHER INVESTIGATION FOR FINAL DIAGNOSIS. NOT FOR MEDICO LEGAL PURPOSE

Pt. Name :- KUMAR AJAY
Ref. By :- DR. /MEDIWHEEL

Date:- 23-Sep-23
Age / Sex - 23 Yrs. M.

Thanks for your kind referral

(Report)

X-RAYCHEST (P.A.VIEW)

- The lungs on the either side show equal translucency.
- The peripheral pulmonary vasculature is normal.
- No focal lung lesion is seen.
- The pleural spaces are normal.
- Both hila are normal in size, have equal density and bear normal relationship.
- The heart and trachea are central in position and no mediastinal abnormality is visible.
- The cardiac size is normal.
- The domes of the diaphragms are normal in position, and show smooth outline.

IMPRESSION

- NO EVIDENCE OF PULMONARY OR CARDIAC PATHOLOGY IS NOTED.

ESTB BY:-

Dr. P. K. Tiwari
MD, M.Sc (Radio Imaging)
Ph.D (Al Nuclear Medicine)

Dr. S. Kumar
MD (Pat)
Consultant Pathologist

Dr. Abhishek Kumar
MBBS, MD
Consultant Neuropathologist & Sonologist

Dr. Kumari Suman
MBBS, DGO, MD
Consultant (TVS & HSG Specialist)

Dr. A. K. Singh
MBBS, PGDMCH
Consultant Radiologist & Sonologist

23/9/23
Consultant Radiologist

PRINTING MISTAKE SHOULD BE REPORTED BACK IMMEDIATELY/ यहाँ जन्म से पहले भ्रुण का लिंग जाँच नहीं होता है ।