



भारत सरकार
GOVERNMENT OF INDIA

Download Date: 21/07/2022



विवेक कुमार
Vivek Kumar
जन्म तिथि/DOB: 18/12/1988
पुरुष/ MALE
Mobile No: 9178772890

Issue Date: 13/11/2014

2510 8151 3957
VID : 9179 2497 7233 9650

मेरा आधार , मेरी पहचान

Dr. NITIN AGARWAL
MBBS, MD
Regn. No. DMC-R-1436.



भारतीय विशिष्ट पहचान प्राधिकरण
UNIQUE IDENTIFICATION AUTHORITY OF INDIA

पता:
फ्लैट नं. 81D, जंग अपार्टमेंट, डीडीए
सेक्टर 13, नॉर्थ वेस्ट डेही,
दिल्ली - 110085

Address :
Flat No. 81D, Jhang Apartment, Opp. DDA
Park, Rohini Sector 13, North West Delhi,
Delhi - 110085



2510 8151 3957
VID : 9179 2497 7233 9650




helpline@uidai.gov.in



www.uidai.gov.in

P.O. Box No. 1947
Delhi-110016

JNEPLUS ULTRASOUND LAB
47, Harsh Vihar, Pitam Pura,
Delhi-110034
Ph. 011-42480101, 9599913051
E-mail: oneplusul@gmail.com



Dr. NITIN AGARWAL
MBBS, MD
Regn. No. DMC-R-1436

ONEPLUS ULTRASCOUND LAB
#7, Harsh Vihar, Pitam Pura,
Delhi-110034
Ph. 011-42480101, 959991305
E-mail: oneplusul@gmail.com

ONEPLUS ULTRASOUND LAB

47, HARSH VIHAR, PITAMPURA, DELHI- 110034

Mr. VIVEK KUMAR

Age : 34/M
Ref. by : MEDIWHEEL
Indication1 :
Indication2 :
Indication3 :
COMMENTS :

ID : 2165

H/WV1 : 177776

Recorded : 25-3-2023 10:06

Medication1 :

Medication2 :

Medication3 :

BPWF : 63

BP : 122/84

P Axis : 70 deg

QRS Axis : 83 deg

T Axis : 59 deg

P duration : 83 msec

PR duration : 103 msec

QRS duration : 113 msec

QT interval : 326 msec

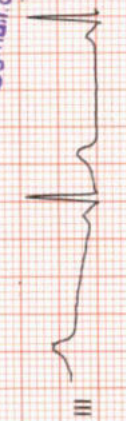
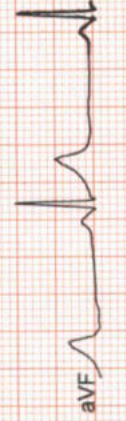
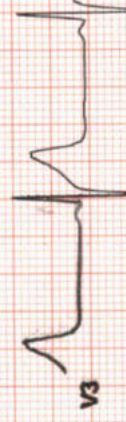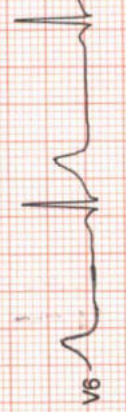
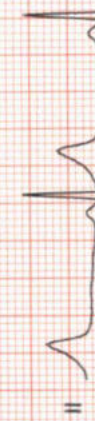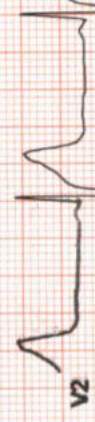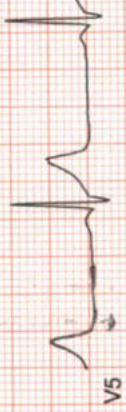QTc interval : 331 msec

Raw E.C.G. (Seq)

Unconfirmed Report Reviewed By:

Cardiologist

Dr. V.K. GUPTA
MBBS, MD
Reg. No-1071



ONEPLUS ULTRASOUND
47, Harsh Vihar, Pitam Pura,
Delhi-110034
Ph. 011-42487701, 9599913051
E-mail: oneplusul@gmail.com

ONEPLUS ULTRASOUND LAB

47, HARSH VIHAR PITAMPURA DELHI 110034

Mr. VIVEK KUMAR

Age/Sex : 34/M

Ref. by : MEDWHEEL

Indication1 :

Indication2 :

Indication3 :

ID : 993

HW/WT : 177/76

Recorded : 25-3-2023 10:09

TREADMILL TEST SUMMARY REPORT

Protocol: BRUCE

History:

Medication1 :

Medication2 :

Medication3 :

PHASE	PHASE TIME	STAGE TIME	SPEED (Km./Hr.)	GRADE (%)	H.R. (BPM)	B.P. (mmHg)	RPP X100	II	ST LEVEL (mm) V2	V5	METS
SUPINE					65	122/84	79	-0.5	2.2	1.5	
STANDING					64	122/84	78	-0.1	3.5	1.0	
STAGE 1	2:59	2:59	2.70	10.00	101	122/84	123	1.1	3.9	2.3	4.80
STAGE 2	5:59	2:59	4.00	12.00	113	134/88	151	0.6	4.6	2.3	7.10
STAGE 3	8:59	2:59	5.40	14.00	133	150/90	199	1.3	5.3	2.7	10.00
STAGE 4	10:59	1:59	6.70	16.00	162	160/94	259	1.5	5.7	3.1	12.66
PEAK EXER	11:01	2:01			163	160/94	260	1.5	5.7	3.1	12.70
RECOVERY	2:59	2:59	0.00	0.00	88	124/84	99	0.7	3.5	1.1	

RESULTS

Exercise Duration : 11:01 Minutes

Max Heart Rate : 163 bpm 87 % of target heart rate 186 bpm

Max Blood Pressure : 160/94 mmHg

Max Work Load : 12.70 METS

Reason of Termination :

IMPRESSIONS

Negative for ischemia only

ONEPLUS ULTRASOUND LAB

47, Harsh Vihar, Pitam Pura,

Delhi-110034

Ph. 011-42480101, 9599913051

E-mail. oneplusul@gmail.com

Dr. P.K. GUPTA

Cardiologist, MD

Reg. No-1071

ONEPLUS ULTRASOUND LAB

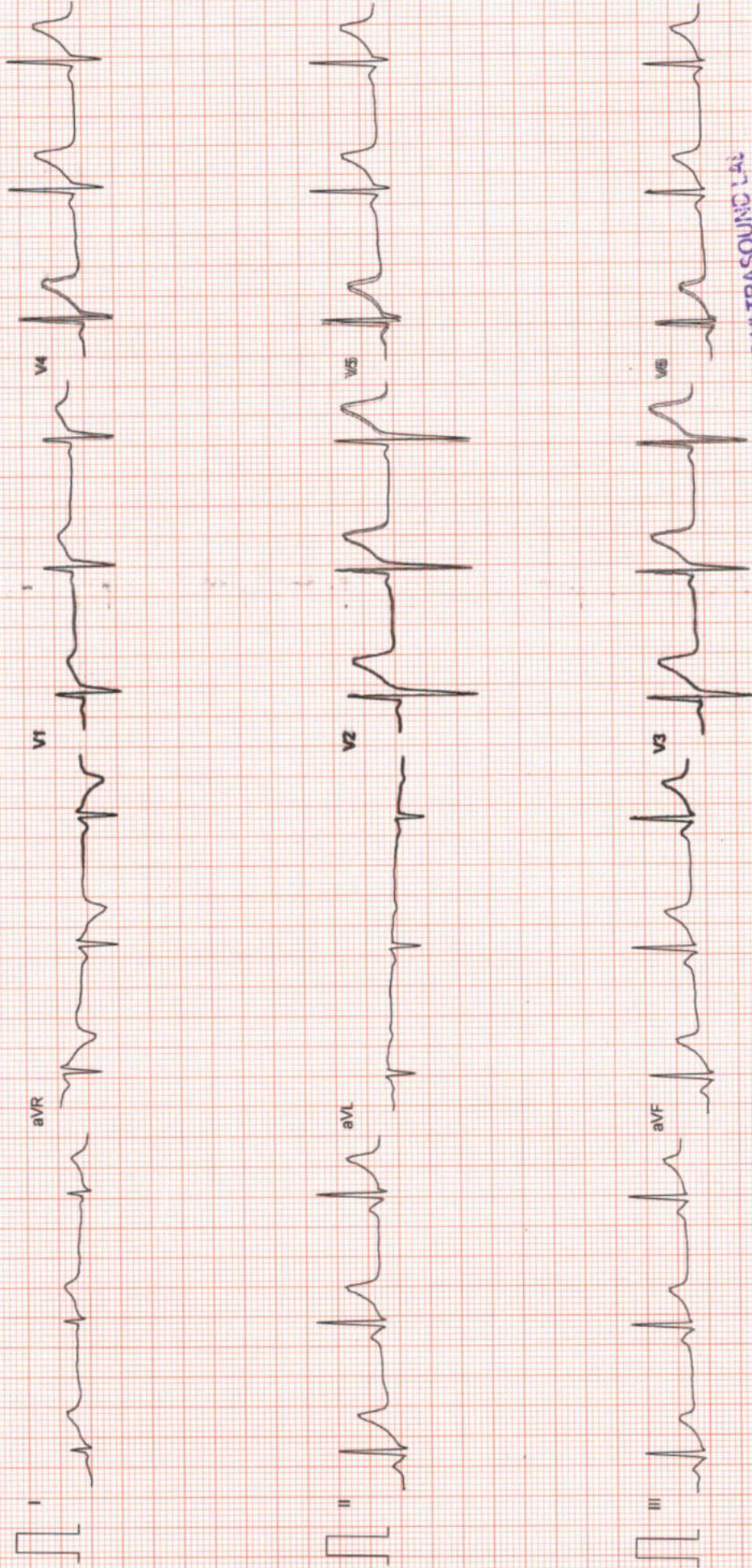
Mr. VIVEK KUMAR
I.D. : 993
AGE/SEX : 34/M
RECORDED : 25-3-2023 10:09

RATE : 65 BPM
B.P. : 122/84 mmHg

SUPINE
PRETEST

ST @ 10mm/mV
80ms PostJ

RAW E.C.G.



ONEPLUS ULTRASOUND LAB
7, Harsh Vihar, Pitam Pura,
Delhi-110034
Ph. 011-42480101, 9599913051
E-mail: oneplusul@gmail.com

ONEPLUS ULTRASOUND LAB

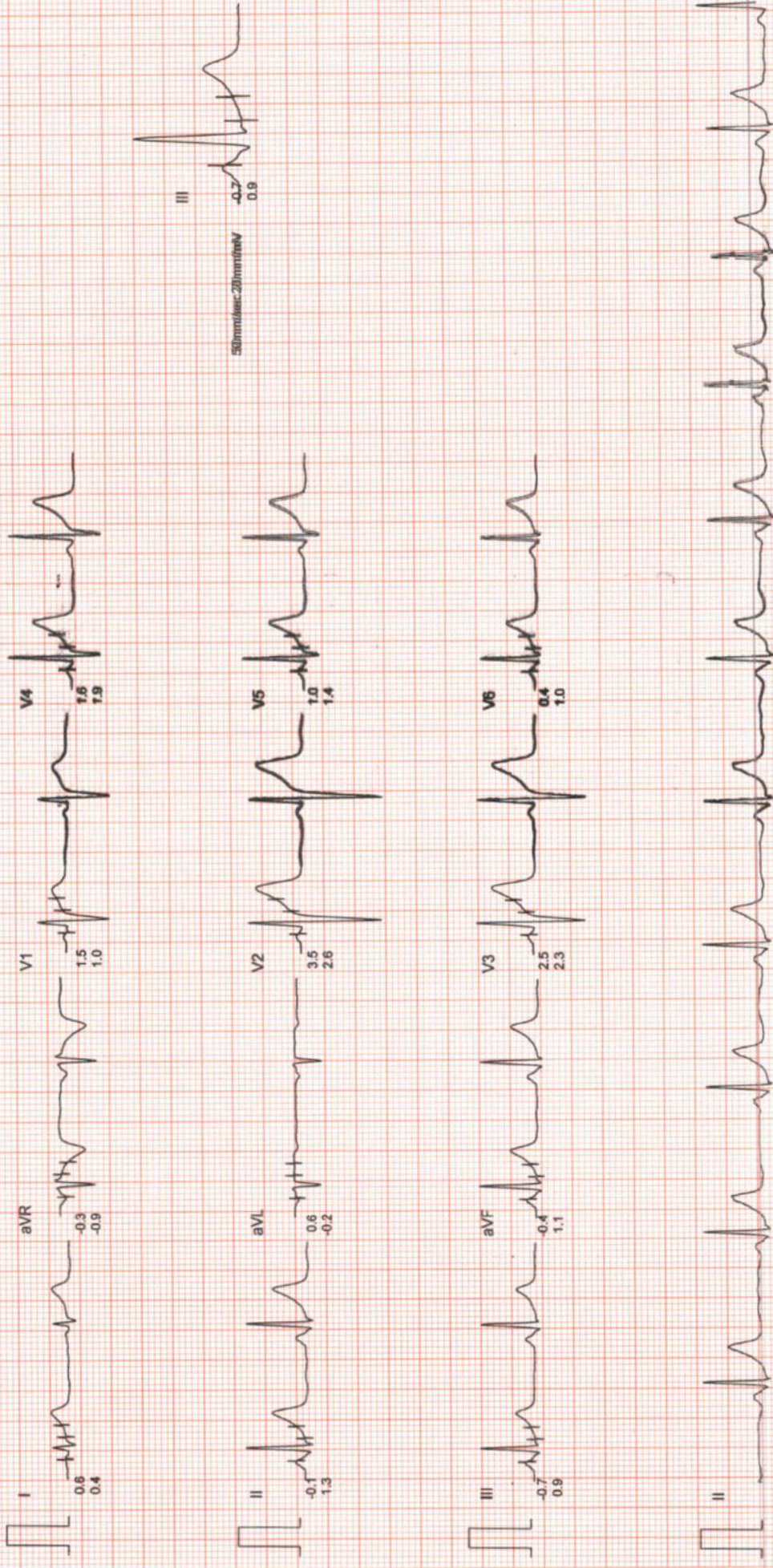Mr. VIVEK KUMAR
I.D. : 993
AGE/SEX : 34/M
RECORDED : 25- 3-2023 10:09

RATE : 64 BPM
B.P. : 122/84 mmHg

ST @ 10mm/mV
80ms PostJ

STANDING
PRETEST

LINKED MEDIAN



ONEPLUS ULTRASOUND LAB
47, Harsh Vihar, Pitam Pura
Delhi-110034
Ph: 011-42480101, 95599913051
E-mail: oneplusul@gmail.com

Filtered

Computer Corrected Baseline

25mm/sec 10mm/mV

CardCom. INDIA Ph:091-731-2620740, TeleFax:091-731-2431214

ONEPLUS ULTRASOUND LAB

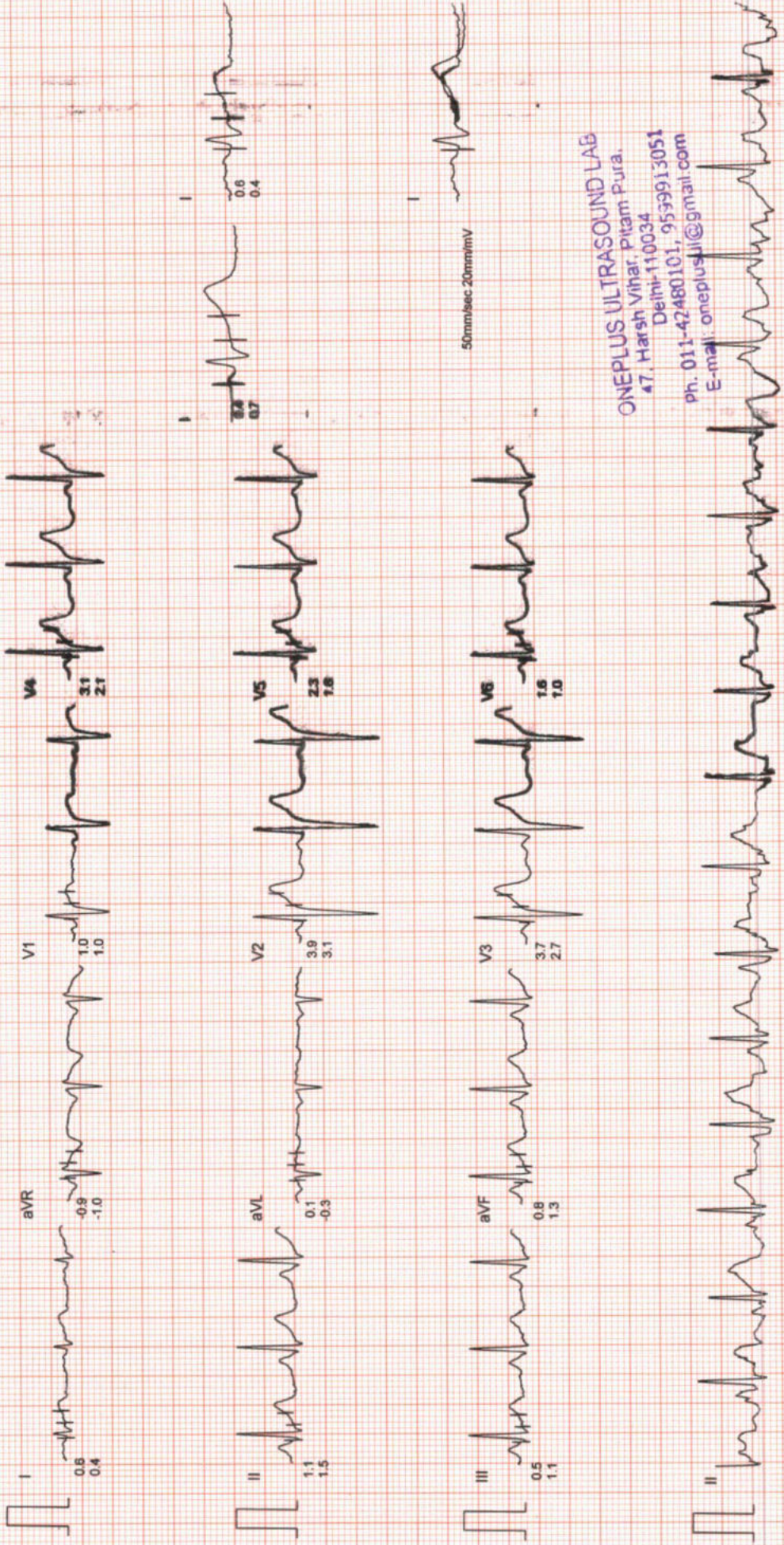
Mr. VIVEK KUMAR
I.D. : 993
AGE/SEX : 34/M
RECORDED : 25-3-2023 10:09

RATE : 101 BPM
B.P. : 122/84 mmHg

BRUCE
EXERCISE 1
PHASE TIME : 2:59
STAGE TIME : 2:59

ST @ 10mm/mV
80ms PostJ
SPEED : 2.7 Km./Mr.
GRADE : 10.0 %

LINKED MEDIAN



ONEPLUS ULTRASOUND LAB
47, Harsh Vihar, Pitam Pura,
Delhi-110034
Ph. 011-42480101, 9539913051
E-mail: oneplusul@gmail.com

ONEPLUS ULTRASOUND LAB

Mr. VIVEK KUMAR

I.D. : 993

AGE/SEX : 34/M

RECORDED : 25-3-2023 10:09

RATE : 113 BPM

B.P. : 134/88 mmHg

BRUCE

EXERCISE 2

PHASE TIME : 5:59

STAGE TIME : 2:59

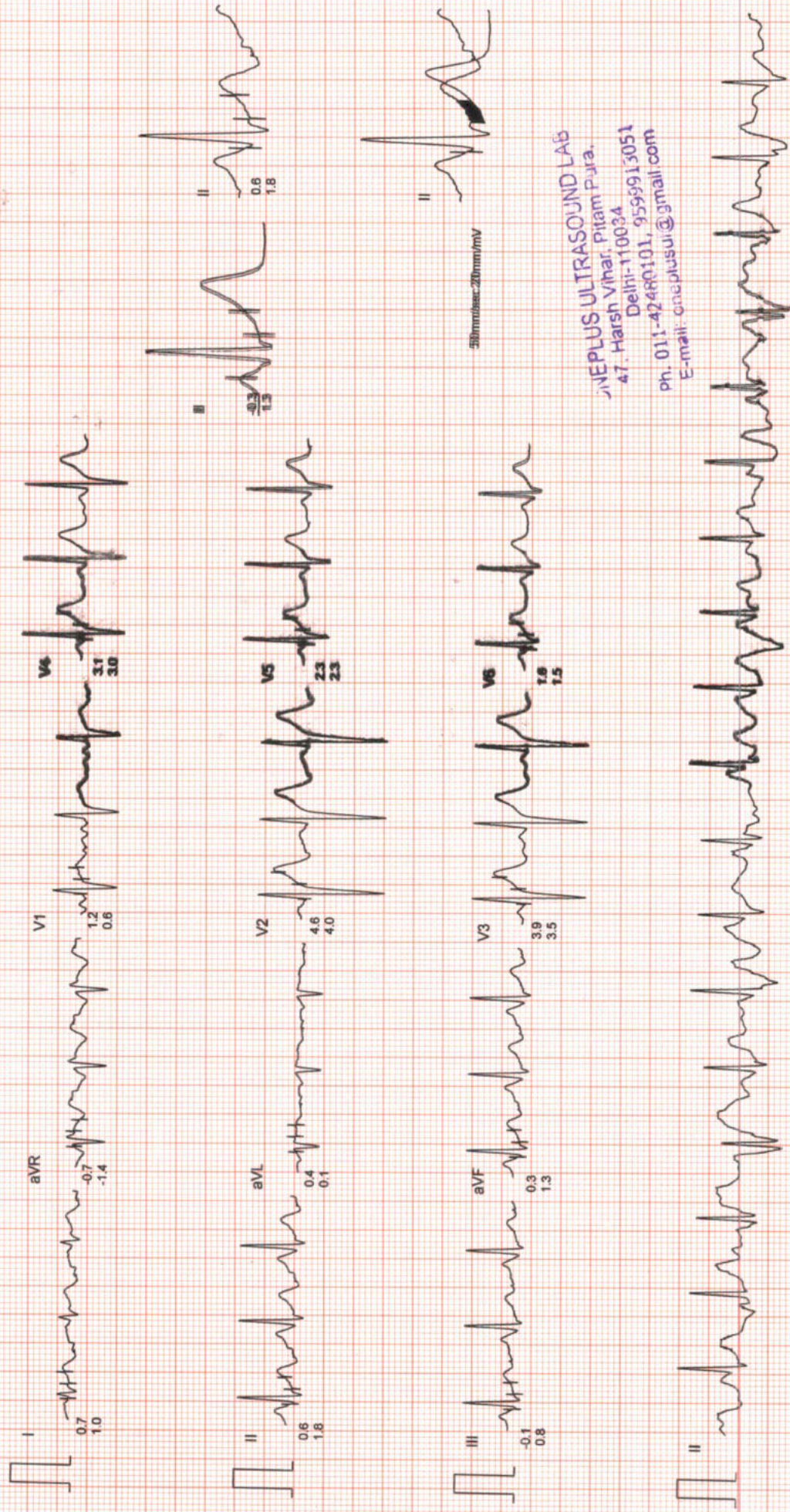ST @ 10mm/mV

80ms Post J

SPEED : 4.0 Km/Hr.

GRADE : 12.0 %

LINKED MEDIAN



ONEPLUS ULTRASOUND LAB

47, Harsh Vihar, Pitam Pura,

Delhi-110034

Ph. 011-42480101, 9599913051

E-mail: oneplusul@gmail.com

Filtered

Computer Corrected Baseline

25mm/sec 10mm/mV

CardiCom, INDIA Ph. 091-731-2620740, TeleFax: 091-731-2431214

ONEPLUS ULTRASOUND LAB

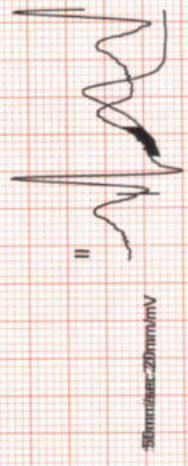
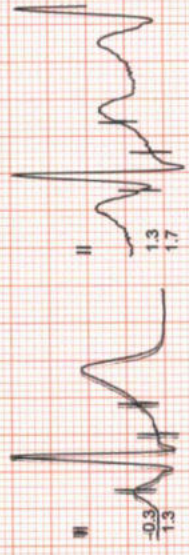
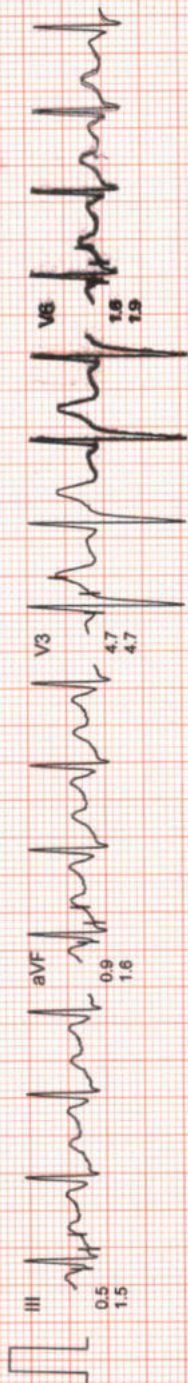
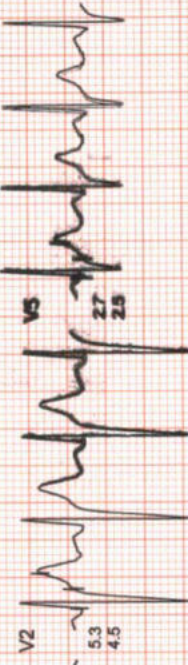
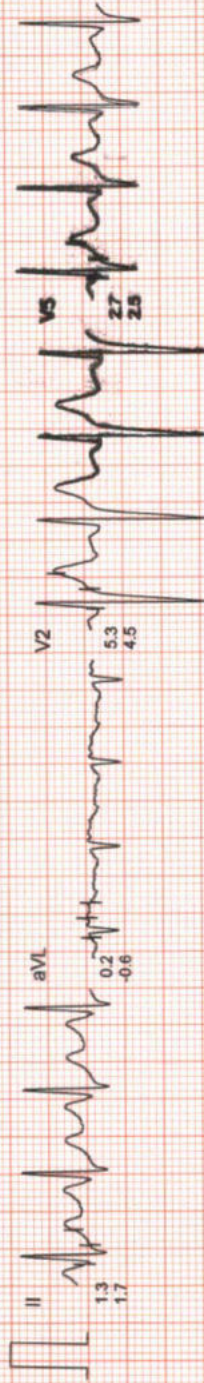
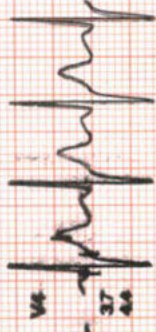
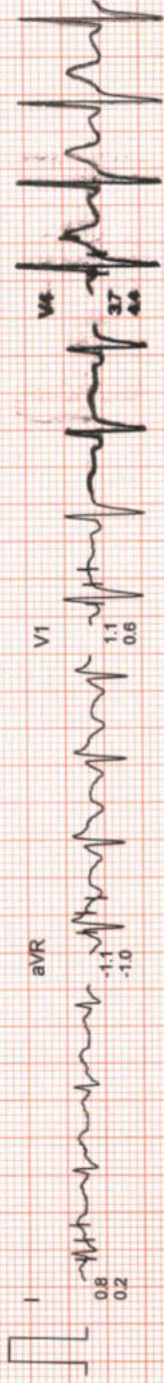
Mr. VIVEK KUMAR
I.D. : 993
AGE/SEX : 34/M
RECORDED : 25-3-2023 10:09

RATE : 133 BPM
B.P. : 150/90 mmHg

BRUCE
EXERCISE 3
PHASE TIME : 8:59
STAGE TIME : 2:59

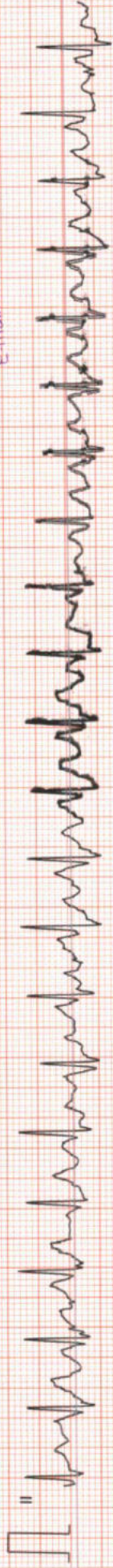
ST @ 10mm/mV
80ms PostJ
SPEED : 5.4 Km./Hr.
GRADE : 14.0 %

LINKED MEDIAN



50mm/sec 20mm/mV

JHEPLUS ULTRASOUND LAB
e7, Harsh Vihar, Pitam Pura,
Delhi-110034
Ph. 011-42491101, 9599913051
E-mail: oneplusul@gmail.com



Filtered

Computer Corrected Baseline

25mm/sec 10mm/mV

CardiCom, INDIA Ph..091-731-2620740, TeleFax:091-731-2431214

ONEPLUS ULTRASOUND LAB

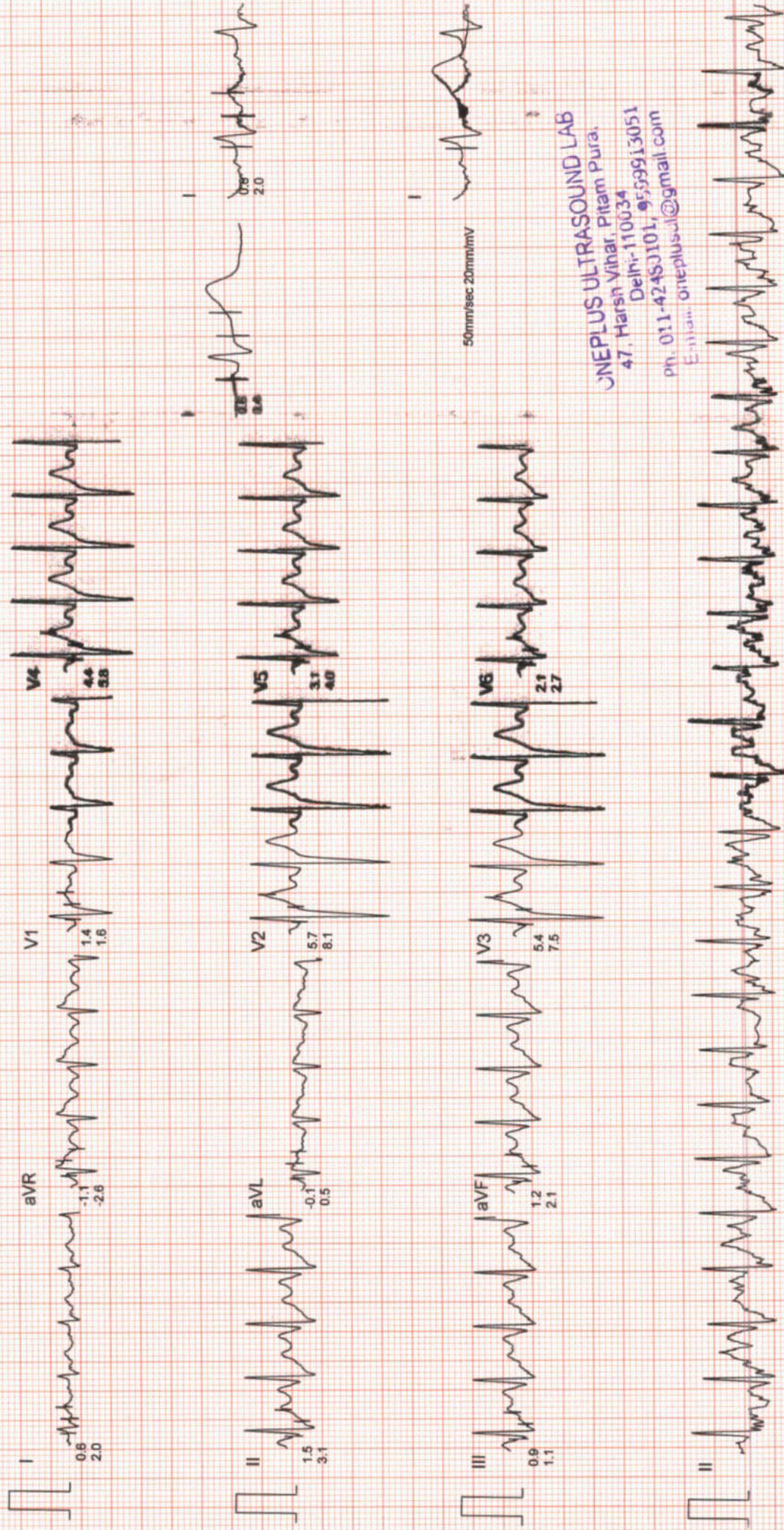
Mr. VIVEK KUMAR
I.D. : 993
AGE/SEX : 34/M
RECORDED : 25-3-2023 10:09

BRUCE
EXERCISE 4
PHASE TIME : 10:59
STAGE TIME : 1:59

RATE : 162 BPM
B.P. : 160/94 mmHg

ST @ 10mm/mV
80ms PostJ
SPEED : 6.7 Kmz/Hr.
GRADE : 16.0 %

LINKED MEDIAN



ONEPLUS ULTRASOUND LAB
47, Harsh Vihar, Pitam Pura,
Delhi-110034
Ph. 011-4245101, 9599913051
E-mail: oneplusul@gmail.com

ONEPLUS ULTRASOUND LAB

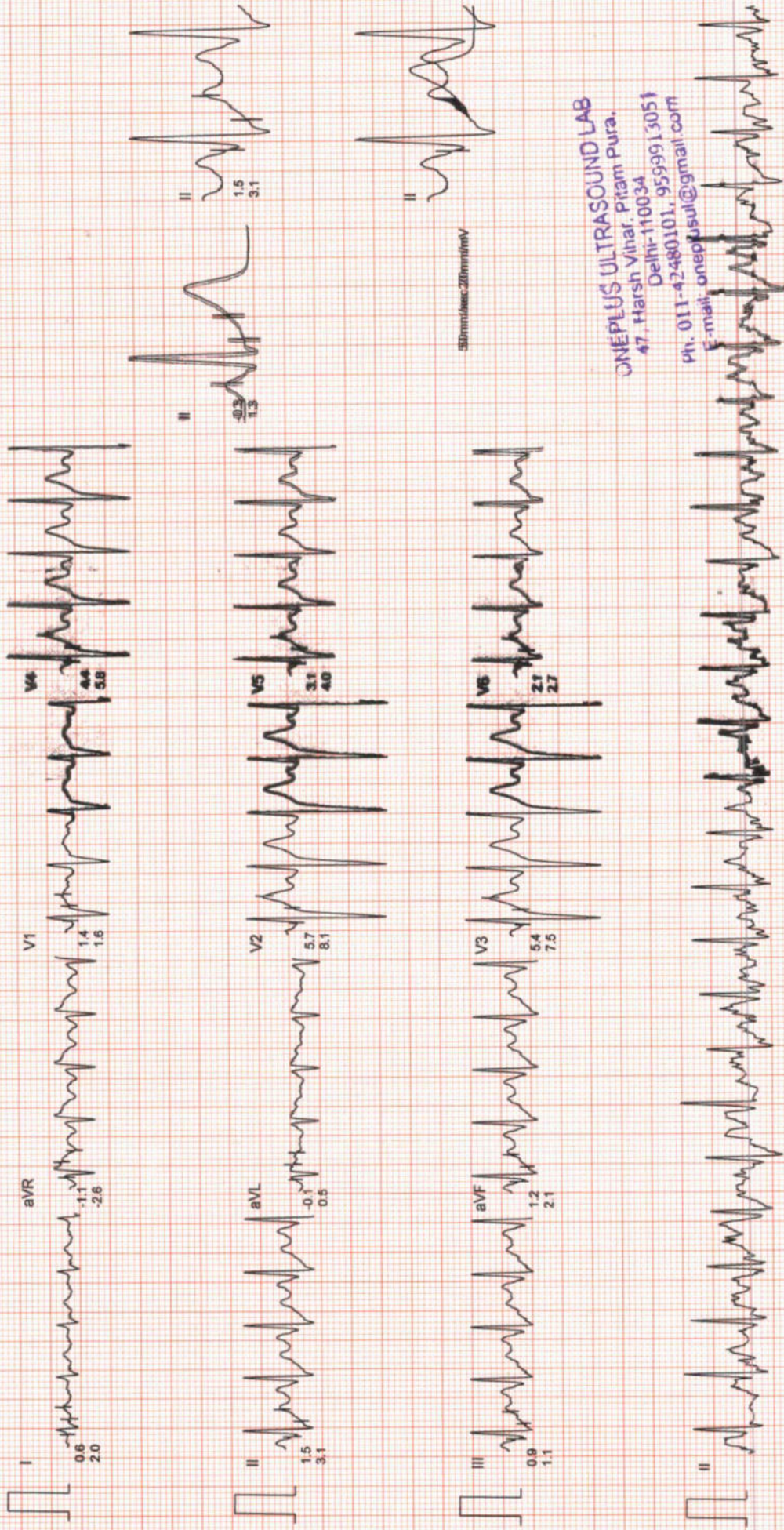
Mr. VIVEK KUMAR
I.D. : 993
AGE/SEX : 34/M
RECORDED : 25-3-2023 10:09

RATE : 163 BPM
B.P. : 160/94 mmHg

ST @ 10mm/mV
80ms PostJ
SPEED : 6.7 Km./Hr.
GRADE : 16.0 %

BRUCE
PEAK EXER
PHASE TIME : 11:01
STAGE TIME : 2:01

LINKED MEDIAN



ONEPLUS ULTRASOUND LAB
47, Harsh Vihar, Pitam Pura,
Delhi-110034
Ph. 011-42480101, 9599913051
E-mail: onepusul@gmail.com

ONEPLUS ULTRASOUND LAB

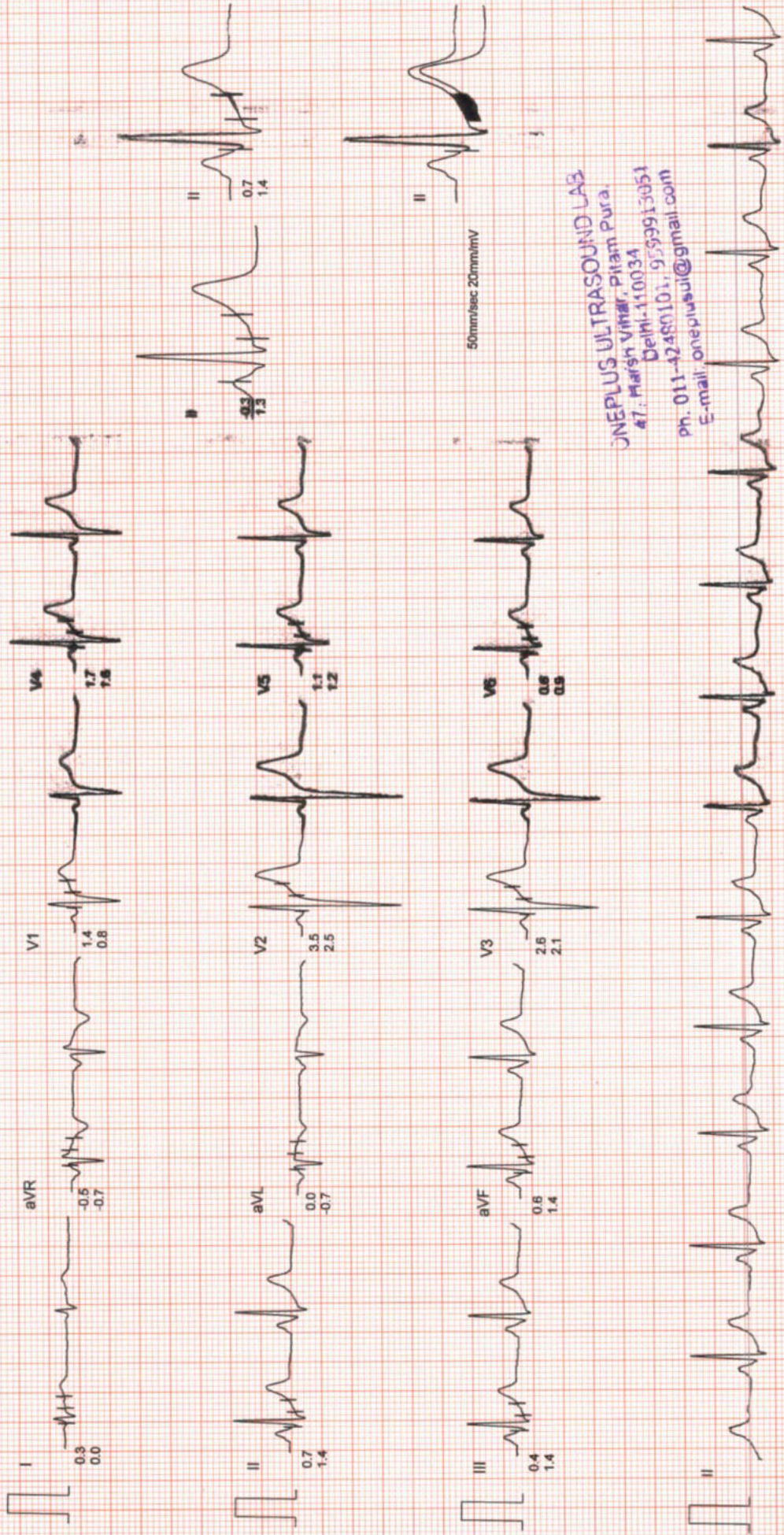
Mr. VIVEK KUMAR
I.D. : 993
AGE/SEX : 34/M
RECORDED : 25-3-2023 10:09

BRUCE
RECOVERY
PHASE TIME : 2:59

RATE : 80 BPM
B.P. : 124/84 mmHg

ST @ 10mm/mV
80ms PostJ
SPEED : 0.0 Km/Hr
GRADE : 0.0 %

LINKED MEDIUM



50mm/sec 20mm/mV

ONEPLUS ULTRASOUND LAB
47, Marish Vihar, Pitam Pura,
Delhi-110034
Ph. 011-42480101, 9599913051
E-mail: oneplusul@gmail.com

Filtered

Computer Corrected Baseline

25mm/sec 10mm/mV

Cardinal INDIA Ph. 091-731-2620740, TeleFax: 091-731-1212

ONEPLUS ULTRASOUND LAB

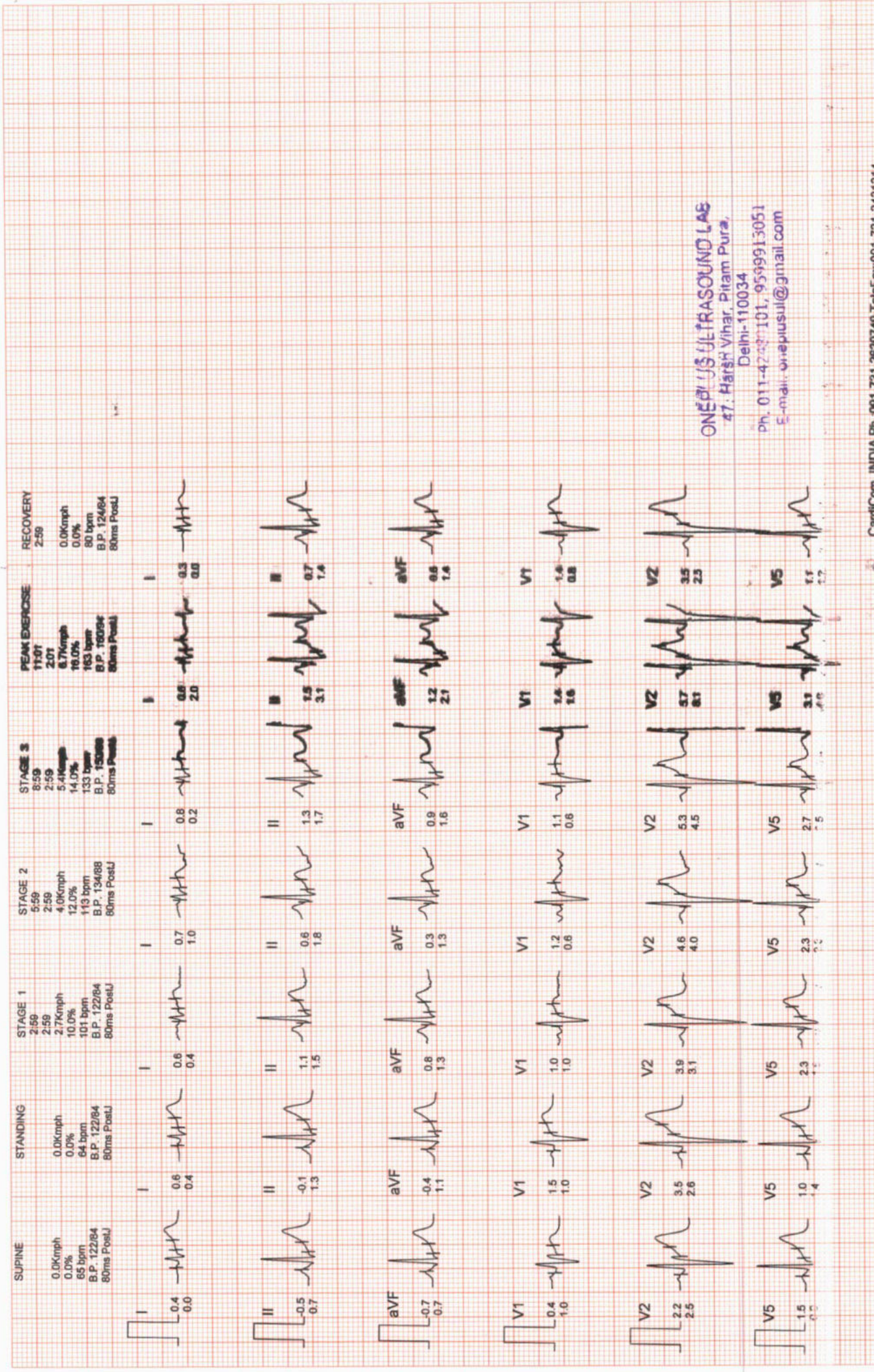
AGESEX : 34/M

I.D. : 993

Mr. VIVEK KUMAR

RECORDED : 25-3-2023 10:09

AVG E.C.G.



ONEPLUS ULTRASOUND LAB
 47, Harsh Vihar, Pitam Pura,
 Delhi-110034
 Ph. 011-4227101, 9599913051
 E-mail: vivekplus@gmail.com

ONEPLUS ULTRASOUND LAB

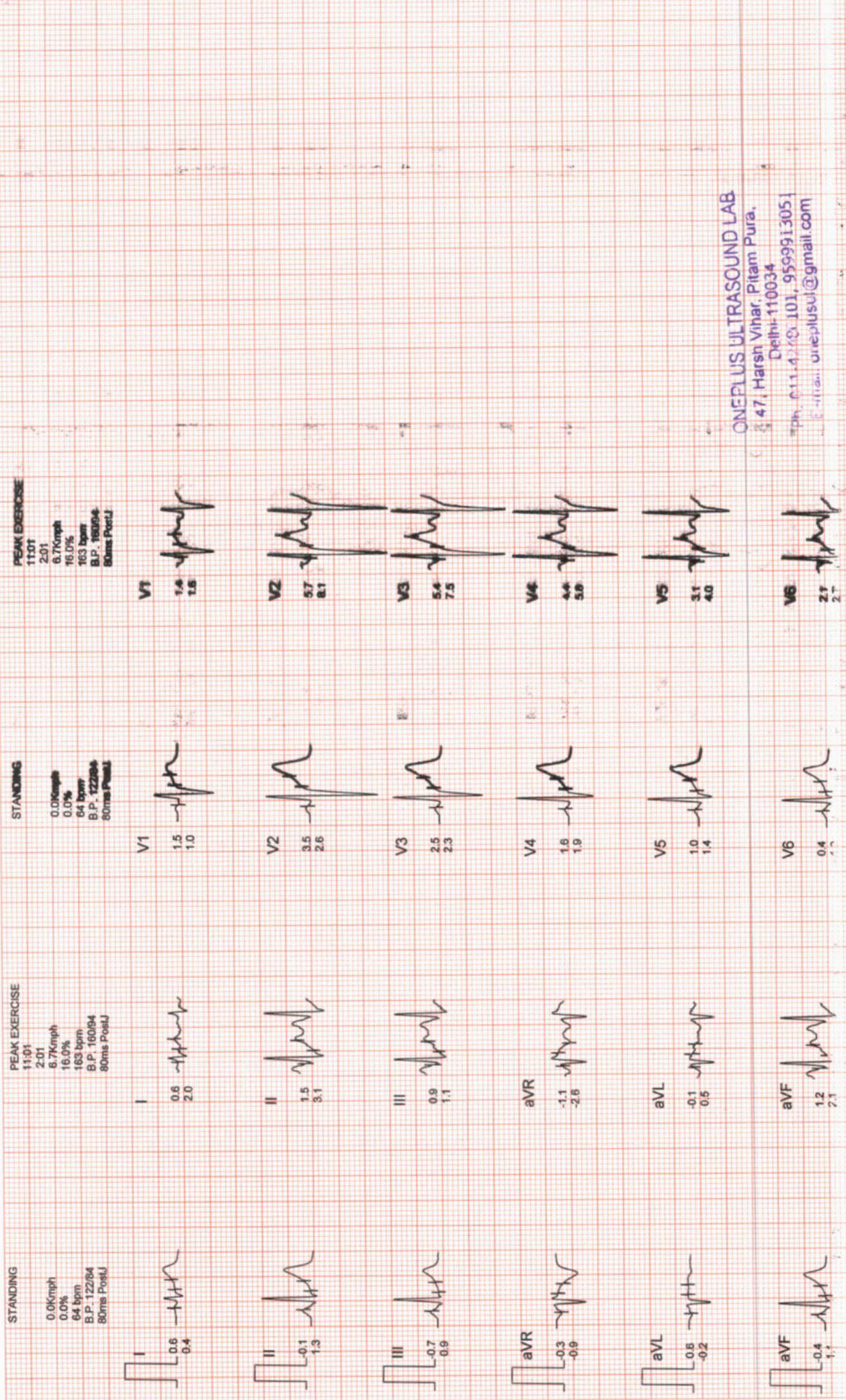
AGE/SEX : 34/M

I.D. : 993

Mr. VIVEK KUMAR

RECORDED : 25-3-2023 10:09

COMPARISON REPORT



PEAK EXERCISE
 11:01
 2:01
 6.7Kmph
 16.0%
 64 bpm
 B.P. 100/94
 80ms PostJ

STANDING
 0.0Kmph
 0.0%
 64 bpm
 B.P. 122/84
 80ms PostJ

PEAK EXERCISE
 11:01
 2:01
 6.7Kmph
 16.0%
 64 bpm
 B.P. 100/94
 80ms PostJ

STANDING
 0.0Kmph
 0.0%
 64 bpm
 B.P. 122/84
 80ms PostJ

ONEPLUS ULTRASOUND LAB
 47, Harsh Vihar, Pitam Pura,
 Delhi-110034
 Ph: 011-4710101, 9599913051
 E-mail: oneplusul@gmail.com



OnePLUS
Ultrasound Lab

— QUALITY FIRST... ALWAYS! —

Dr. Nitin Agarwal
Pathologist & Director
Ex. Sr. Res. MAMC
& Lok Nayak Hospital
Ex. Chief of Lab Dr. Lal Path Labs.

Dr. Pooja (Garg) Agarwal
Radiologist & Director
MAMC & Lok Nayak Hospital



NAME	:Mr. VIVEK KUMAR	Barcode No	:10140823
AGE/GENDER	:34 YRS/Male	SPECIMEN DATE	:25/Mar/2023 08:26AM
PATIENT ID	:111313	SPECIMEN RECEIVED	:25/Mar/2023 08:39AM
REFERRED BY	:Dr. MEDIWHEEL	REPORT DATE	:25/Mar/2023 01:15PM
CENTRE NAME	:ONEPLUS ULTRASOUND LAB	LAB NO.	:012303250006

Test Name	Result	Unit	Ref. Range
-----------	--------	------	------------

HAEMATOLOGY

Medi Wheel Health checkup < 40 Male

Glycosylated Hemoglobin (HbA1c)	5.0	%	Non Diabetic adults <5.7 Prediabetic (at risk) 5.7-6.4 Diabetes >6.4
--	-----	---	--

Estimated average blood glucose (eag)	97
--	----

Reference range (mg/dl):

90 - 120:Excellent control, 121 - 150:Good Control, 151 - 180:Average Control, 181 - 210:Action Suggested

>211:Panic value

BLOOD GROUP (ABO)	A
Rh typing	NEGATIVE

NOTE :

- * Apart from major A,B,H antigens which are used for ABO grouping and Rh typing, many minor blood group antigens exist. Agglutination may also vary according to titre of antigen and antibody.
- * So before transfusion, reconfirmation of blood group as well as cross-matching is needed.
- * Presence of maternal antibodies in newborns, may interfere with blood grouping.
- * Auto agglutination (due to cold antibody, falciparum malaria, sepsis, internal malignancy etc.) may also cause erroneous result.

CBC

Haemoglobin	12.7	g/dl	13.0-17.0
Total Leucocyte Count	5300	/cumm	4000-10000
Differential leucocyte count			
Neutrophils	69.2	%	40-80
Lymphocyte	25.20	%	20-40
Monocytes	3.60	%	2-10
Eosinophils	1.5	%	1-6
Basophils	0.5	%	0-2
RBC Count	4.40	million/cumm	4.5 - 5.5

Checked By.

Dr. NITIN AGARWAL
M B B S . MD (Path)
DMC/R/01436
DR. NITIN AGARWAL
MBBS,MD(PATHOLOGIST)

47, Harsh Vihar, Pitampura, New Delhi-110034 | Ph.: 011-42480101, 9599913051
E-mail: oneplusul@gmail.com | Web.: www.oneplusul.in



OnePLUS Ultrasound Lab

QUALITY FIRST... ALWAYS!

Dr. Nitin Agarwal
Pathologist & Director
Ex. Sr. Res. MAMC
& Lok Nayak Hospital
Ex. Chief of Lab Dr. Lal Path Labs.

Dr. Pooja (Garg) Agarwal
Radiologist & Director
MAMC & Lok Nayak Hospital



NAME	:Mr. VIVEK KUMAR	Barcode No	:10140823
AGE/GENDER	:34 YRS/Male	SPECIMEN DATE	:25/Mar/2023 08:26AM
PATIENT ID	:111313	SPECIMEN RECEIVED	:25/Mar/2023 08:39AM
REFERRED BY	:Dr. MEDIWHEEL	REPORT DATE	:25/Mar/2023 01:15PM
CENTRE NAME	:ONEPLUS ULTRASOUND LAB	LAB NO.	:012303250006

Test Name	Result	Unit	Ref. Range
PCV(Hematocrit)	42.0	%	40-50
MCV	94.6	fL	83-101
MCH	28.6	Pg	27-32
MCHC	30.2	G/dL	32-35
Platelet count	168000	/cumm	150000-450000
RDW-CV	13.4	%	11.4-14.0
ESR(WESTEGRENs METHOD)	15	mm in 1st hr	0-20

BIOCHEMISTRY

Blood sugar fasting	91	mg/dL	70-110
----------------------------	----	-------	--------

Checked By.

Dr. NITIN AGARWAL
M B B S, MD (P)
DMC/R/01435
DR. NITIN AGARWAL
MBBS, MD(PATHOLOGIST)

47, Harsh Vihar, Pitampura, New Delhi-110034 | Ph.: 011-42480101, 9599913051

E-mail: oneplusul@gmail.com | Web.: www.oneplusul.in

Page 2 of 7



OnePLUS Ultrasound Lab

QUALITY FIRST... ALWAYS!

Dr. Nitin Agarwal
Pathologist & Director
Ex. Sr. Res. MAMC
& Lok Nayak Hospital
Ex. Chief of Lab Dr. Lal Path Labs.

Dr. Pooja (Garg) Agarwal
Radiologist & Director
MAMC & Lok Nayak Hospital



NAME	:Mr. VIVEK KUMAR	Barcode No	:10140823
AGE/GENDER	:34 YRS/Male	SPECIMEN DATE	:25/Mar/2023 08:26AM
PATIENT ID	:111313	SPECIMEN RECEIVED	:25/Mar/2023 12:46PM
REFERRED BY	:Dr. MEDIWHEEL	REPORT DATE	:25/Mar/2023 02:15PM
CENTRE NAME	:ONEPLUS ULTRASOUND LAB	LAB NO.	:012303250006

Test Name	Result	Unit	Ref. Range
-----------	--------	------	------------

BIOCHEMISTRY

<u>Blood sugar pp</u>	94	mg/dL	70.0-140.0
-----------------------	----	-------	------------

Checked By.

Dr NITIN AGARWAL
MBBS, MD (Path)
DMC/R/01486

DR. NITIN AGARWAL
MBBS,MD(PATHOLOGIST)

47, Harsh Vihar, Pitampura, New Delhi-110034 | Ph.: 011-42480101, 9599913051
E-mail: oneplusul@gmail.com | Web.: www.oneplusul.in

Page 3 of 7

Clinical correlation is essential for final diagnosis. • If test results are unsatisfactory please contact personally or on phone. • This report is for perusal of doctors only.
• All disputes Subject to Delhi Jurisdiction only. • Not for medicolegal purposes. • All congenital anomalies in a foetus may not be diagnosed in routine obstetric ultrasound.



OnePLUS Ultrasound Lab

QUALITY FIRST... ALWAYS!

Dr. Nitin Agarwal
Pathologist & Director
Ex. Sr. Res. MAMC
& Lok Nayak Hospital
Ex. Chief of Lab Dr. Lal Path Labs.

Dr. Pooja (Garg) Agarwal
Radiologist & Director
MAMC & Lok Nayak Hospital



NAME	:Mr. VIVEK KUMAR	Barcode No	:10140823
AGE/GENDER	:34 YRS/Male	SPECIMEN DATE	:25/Mar/2023 08:26AM
PATIENT ID	:111313	SPECIMEN RECEIVED	:25/Mar/2023 11:54AM
REFERRED BY	:Dr. MEDIWHEEL	REPORT DATE	:25/Mar/2023 01:15PM
CENTRE NAME	:ONEPLUS ULTRASOUND LAB	LAB NO.	:012303250006

Test Name	Result	Unit	Ref. Range
BIOCHEMISTRY			
<u>Bun (blood urea nitrogen)</u>	14.20	mg/dl	8.9-21.6
<u>Uric acid, serum</u>	4.9	mg/dl	3.5-7.2
<u>Creatinine, serum</u>	0.8	mg/dl	0.60-1.2
LFT(LIVER FUNCTION TEST)			
Bilirubin Total	0.42	mg/dl	0.1-1.2
Bilirubin Conjugated	0.12	mg/dl	0-0.4
Bilirubin Unconjugated	0.3	mg/dl	up to 0.7
SGOT (AST)	26	U/L	0-46
SGPT (ALT)	29	U/L	0-49
Alkaline phosphatase	95	U/L	40-129
Gamma glutamyl transpeptidase	28	U/L	10-45
Total Protein	7.4	gm/dl	6.60 - 8.70
Albumin serum	4.5	g/dL	3.0-5.2
Globulin	2.90	gm/dl	1.8-3.4
Albumin/Globulin Ratio	1.55		1.10 - 2.50
LIPID PROFILE			
Cholesterol	270	mg/dl	50-200
Triglycerides	69	mg/dL	25-150
HDL Cholesterol	47	mg/dL	40 - 60
LDL cholesterol	209	mg/dL	<130
VLDL cholesterol	13.8	mg/dL	5-40
Cholesterol/HDL Ratio	5.7		Low Risk 3.3-4.97 Average Risk 4.4-7.1 Moderate Risk 7.1-11.0 High Risk >11.0
LDL/HDL Ratio	4.4		0 - 3.55

According to ATP III and NCEP guidelines

Checked By.

DR. NITIN AGARWAL
MBBS, MD(PATH)
DMC/R/01436
DR. NITIN AGARWAL
MBBS,MD(PATHOLOGIST)

47, Harsh Vihar, Pitampura, New Delhi-110034 | Ph.: 011-42480101, 9599913051
E-mail: onepusul@gmail.com | Web.: www.oneplusul.in

Page 4 of 7

Clinical correlation is essential for final diagnosis. • If test results are unsatisfactory please contact personally or on phone. • This report is for perusal of doctors only.
• All disputes Subject to Delhi Jurisdiction only. • Not for medicolegal purposes. • All congenital anomalies in a foetus may not be diagnosed in routine obstetric ultrasound.



OnePLUS Ultrasound Lab

QUALITY FIRST... ALWAYS!

Dr. Nitin Agarwal
Pathologist & Director
Ex. Sr. Res. MAMC
& Lok Nayak Hospital
Ex. Chief of Lab Dr. Lal Path Labs.

Dr. Pooja (Garg) Agarwal
Radiologist & Director
MAMC & Lok Nayak Hospital



NAME	:Mr. VIVEK KUMAR	Barcode No	:10140823
AGE/GENDER	:34 YRS/Male	SPECIMEN DATE	:25/Mar/2023 08:26AM
PATIENT ID	:111313	SPECIMEN RECEIVED	:25/Mar/2023 11:54AM
REFERRED BY	:Dr. MEDIWHEEL	REPORT DATE	:25/Mar/2023 01:15PM
CENTRE NAME	:ONEPLUS ULTRASOUND LAB	LAB NO.	:012303250006

Test Name	Result	Unit	Ref. Range
-----------	--------	------	------------

Parameter	Normal	Desirable	Borderline	High
-----------	--------	-----------	------------	------

Total cholesterol	<200		200-239	240
-------------------	------	--	---------	-----

Triglycerides	<150	150-199	200-499	500
---------------	------	---------	---------	-----

LDL	Optimal <100	130-159	160-180	190
-----	--------------	---------	---------	-----

Near Optimal 100-129

HDL	<40 : LOW 60 : HIGH
-----	---------------------

BUN/Creatinine ratio

Bun (blood urea nitrogen)	14.20	mg/dl	8.9-21.6
CREATININE	0.80	mg/dl	0.30-1.10
BUN/Creatinine ratio	17.75		10.0 - 20.0

ENDOCRINOLOGY

THYROID PROFILE(T3,T4,TSH)

Triiodothyronine total [t3]	0.68	ng/dl	0.52-1.9
Thyroxine total [t4]	6.50	µg/dl	4.4 - 10.8
TSH (Thyroid Stimulating Hormone)	2.90	µIU/ml	0.25-5.0

AGE WISE VARIATION IN TSH

AGE	TSH(µIU/ml)	AGE	TSH(µIU/ml)
1-4 weeks	1.00 - 19.0	16-20 yrs	0.25 - 5.0
1-12 mths	1.70 - 9.1	21 - 80 yrs	0.25 - 5.0
1-5 yrs	0.80 - 8.2	I st trimester	0.25 - 5.0
6-10 yrs	0.25 - 5.0	II nd trimester	0.50 - 5.0
11-15 yrs	0.25 - 5.0	II rd trimester	0.4 - 6.0

Reference ranges - Interpretation of Diagnostic tests - (Jacques Wallach)

1. Primary hypothyroidism is accompanied by depressed serum T3 and T4 values and elevated serum TSH level.

Checked By.

Dr. NITIN AGARWAL
MBBS, MD (Pathology)
DMC/R/01436
DR. NITIN AGARWAL
MBBS, MD (PATHOLOGIST)

47, Harsh Vihar, Pitampura, New Delhi-110034 | Ph.: 011-42480101, 9599913051

E-mail: oneplusul@gmail.com | Web.: www.oneplusul.in

Page 5 of 7



OnePLUS
Ultrasound Lab

QUALITY FIRST... ALWAYS!

Dr. Nitin Agarwal
Pathologist & Director
Ex. Sr. Res. MAMC
& Lok Nayak Hospital
Ex. Chief of Lab Dr. Lal Path Labs.

Dr. Pooja (Garg) Agarwal
Radiologist & Director
MAMC & Lok Nayak Hospital



NAME	:Mr. VIVEK KUMAR	Barcode No	:10140823
AGE/GENDER	:34 YRS/Male	SPECIMEN DATE	:25/Mar/2023 08:26AM
PATIENT ID	:111313	SPECIMEN RECEIVED	:25/Mar/2023 11:54AM
REFERRED BY	:Dr. MEDIWHEEL	REPORT DATE	:25/Mar/2023 01:15PM
CENTRE NAME	:ONEPLUS ULTRASOUND LAB	LAB NO.	:012303250006

Test Name	Result	Unit	Ref. Range
2. Primary hyperthyroidism is accompanied by elevated serum T3 and T4 levels along with depressed TSH values.			
3. Slightly elevated T3 levels may be found in pregnancy and estrogen therapy, while depressed levels may be encountered in severe illness, renal failure and during therapy with drugs like propranolol and propyl thiouracil.			
4. Although elevated TSH levels are nearly always indicative of primary hypothyroidism, and may be seen in secondary thyrotoxicosis			

CLINICAL PATHOLOGY

URINE ROUTINE

Physical examination

Quantity	20		ML
Colour	PALE YELLOW		
Transparency	CLEAR		CLEAR
Sp.gravity	1.015		1.010-1.030
pH	6.00		
Reaction	ACIDIC		ACIDIC

Chemical examination

Urine protein	NIL		NIL
Urine sugar	NIL		NIL
Bilirubin, urine	NEGATIVE		NEGATIVE
Urobilinogen	NORMAL		NORMAL
Ketones	NEGATIVE		NEGATIVE

Microscopic examination

Fus cells.	1-2	/HPF	0-2
Epithelial cells	1-2	/HPF	NIL
R.B.C.	NIL	/HPF	NIL
Casts	NIL	/HPF	NIL
Crystals	NIL	/HPF	NIL
Bacteria	NIL	/HPF	NIL
Others.	NIL	NIL	NIL

Checked By.

Dr. NITIN AGARWAL
M.B.B.S., MD (Path)
DMC/R/01436
DR. NITIN AGARWAL
MBBS, MD (PATHOLOGIST)

47, Harsh Vihar, Pitampura, New Delhi-110034 | Ph.: 011-42480101, 9599913051

E-mail: oneplusul@gmail.com | Web.: www.oneplusul.in

Page 6 of 7



OnePLUS

Ultrasound Lab

QUALITY FIRST... ALWAYS!

Dr. Nitin Agarwal
Pathologist & Director
Ex. Sr. Res. MAMC
& Lok Nayak Hospital
Ex. Chief of Lab Dr. Lal Path Labs.

Dr. Pooja (Garg) Agarwal
Radiologist & Director
MAMC & Lok Nayak Hospital



NAME	:Mr. VIVEK KUMAR	Barcode No	:10140823
AGE/GFENDER	:34 YRS/Male	SPECIMEN DATE	:25/Mar/2023 08:26AM
PATIENT ID	:111313	SPECIMEN RECEIVED	:25/Mar/2023 12:46PM
REFERRED BY	:Dr. MEDIWHEEL	REPORT DATE	:25/Mar/2023 02:15PM
CENTRE NAME	:ONEPLUS ULTRASOUND LAB	LAB NO.	:012303250006

Test Name	Result	Unit	Ref. Range
CLINICAL PATHOLOGY			
STOOL ROUTINE			
Physical examination			
Colour	BROWNISH		
Consistency	SEMI LOOSE		Semi Formed
Blood	ABSENT		Absent
Mucus	ABSENT		Absent
Chemical examination, stool			
pH	8.00		
Microscopic examination			
Pus cells	0-1	/HPF	
R.B.C.	NIL	/HPF	NIL
Ova	NIL		NIL
Cysts	NIL		NIL
Bacteria	PRESENT	/HPF	NIL
Others	NIL		

*** End Of Report ***

Checked By.

Dr. NITIN AGARWAL
MBBS, MD (Path)
DMC/R/01346
DR. NITIN AGARWAL
MBBS, MD (PATHOLOGIST)

47, Harsh Vihar, Pitampura, New Delhi-110034 | Ph.: 011-42480101, 9599913051
E-mail: oneplusul@gmail.com | Web.: www.oneplusul.in

Page 7 of 7

Clinical correlation is essential for final diagnosis. • If test results are unsatisfactory please contact personally or on phone. • This report is for perusal of doctors only. • All disputes Subject to Delhi Jurisdiction only. • Not for medicolegal purposes. • All congenital anomalies in a foetus may not be diagnosed in routine obstetric ultrasound.



OnePLUS
Ultrasound Lab
— QUALITY FIRST... ALWAYS! —

Dr. Nitin Agarwal
Pathologist & Director
Ex. Sr. Res. MAMC
& Lok Nayak Hospital
Ex. Chief of Lab Dr. Lal Path Labs.

Dr. Pooja (Garg) Agarwal
Radiologist & Director
MAMC & Lok Nayak Hospital

Name	: Mr. VIVEK KUMAR	Age/Sex	: 34 YRS/Male
Ref. By	: Dr. MEDIWHEEL	Lab No	: 012303250006
Date	: 25-Mar-2023	Patient ID	: LSHHI111313

ULTRASOUND EXAMINATION----WHOLE ABDOMEN

Liver is normal in size (15.0 cm) and outline with normal echopattern. No abscess or mass lesion seen. Hepatic veins, portal vein, IVC and aorta are normal. Intrahepatic biliary radicles are not dilated. CBD is normal in caliber.

Gall bladder is well distended with anechoic lumen. Wall thickness is normal.

Both kidneys are normal in size, shape, position, outline and echopattern. Corticomedullary differentiation is maintained. No pelvicalyceal dilation or calculus or mass lesion is seen.

Spleen is normal in size and echotexture. No mass lesion seen.

Pancreas is normal in size, outline and echotexture.

Urinary bladder is normal in shape and position. No evidence of intravesical stone or mass seen.

Prostate is normal in size, shape and echopattern.

Prostate measures 4.3 x 3.3 x 2.5 cm. **Weight of prostate is 18.6 grams.**

No abnormal bowel wall thickening seen in right iliac fossa.

No free fluid seen anywhere in abdomen.

IMPRESSION: Normal Study.

Dr. POOJA GARG
DR. POOJA GARG
M.B.B.S., D.M.R.D.
Reg No. DMGR/03398
Radiologist

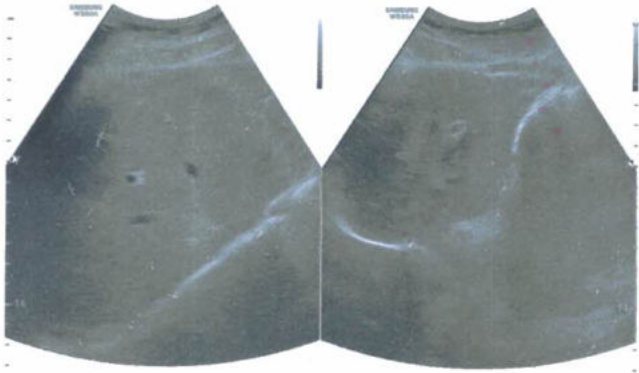
Type By : darshita

47, Harsh Vihar, Pitampura, New Delhi-110034 | Ph.: 011-42480101, 9599913051

E-mail: oneplusul@gmail.com | Web.: www.oneplusul.in

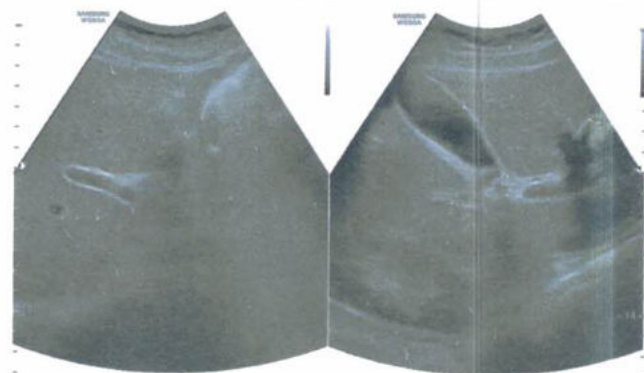
MR VIVEK 34/M
OnePlus Ultrasound Lab MI 1.4 25-03-2023
CA1-7A / Abdomen / FR 24Hz Tis 0.1 10:50:40 AM

G74 DR135-FAB P90 Frq Gen: 17.0cm



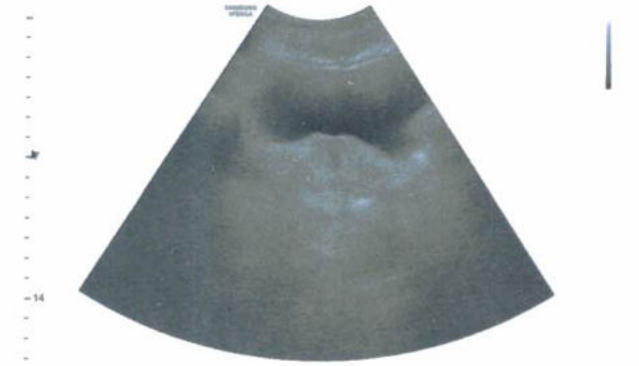MR VIVEK 34/M
OnePlus Ultrasound Lab MI 1.4 25-03-2023
CA1-7A / Abdomen / FR 24Hz Tis 0.1 10:50:57 AM

G74 DR135-FAB P90 Frq Gen: 17.0cm



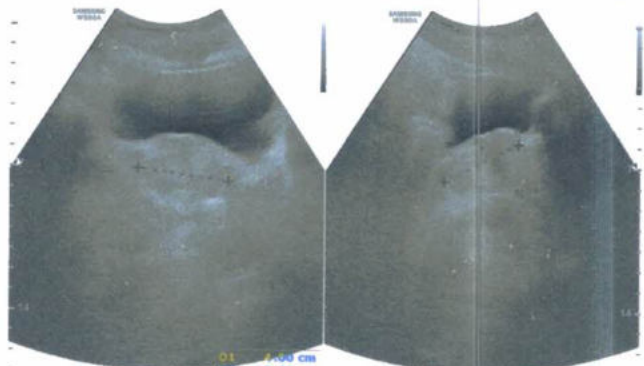MR VIVEK 34/M
OnePlus Ultrasound Lab MI 1.4 25-03-2023
CA1-7A / Abdomen / FR 24Hz Tis 0.1 10:51:02 AM

G74 DR135-FAB P90 Frq Gen: 17.0cm



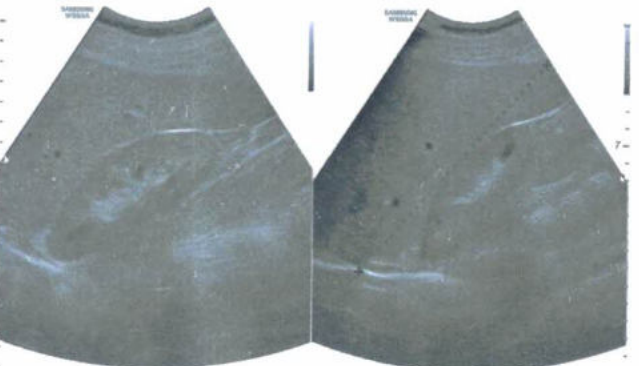MR VIVEK 34/M
OnePlus Ultrasound Lab MI 1.4 25-03-2023
CA1-7A / Abdomen / FR 24Hz Tis 0.1 10:51:15 AM

G74 DR135-FAB P90 Frq Gen: 17.0cm



MR VIVEK 34/M
OnePlus Ultrasound Lab MI 1.4 25-03-2023
CA1-7A / Abdomen / FR 21Hz Tis 0.1 10:51:34 AM

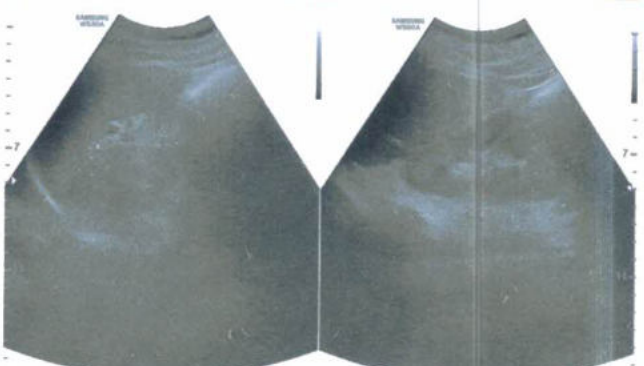G74 DR135-FAB P90 Frq Gen: 17.0cm



D1 15.97 cm

MR VIVEK 34/M
OnePlus Ultrasound Lab MI 1.4 25-03-2023
CA1-7A / Abdomen / FR 21Hz Tis 0.1 10:51:47 AM

G74 DR135-FAB P90 Frq Gen: 20.0cm



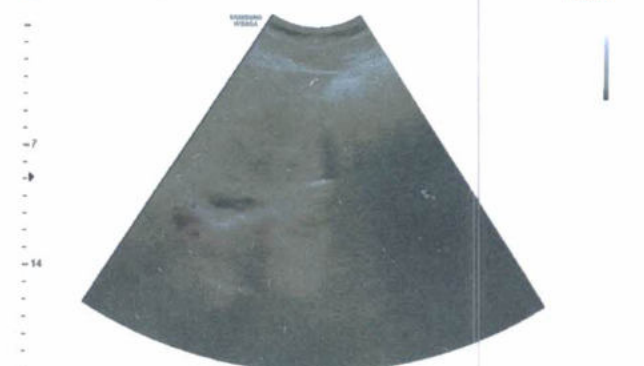
MR VIVEK 34/M
OnePlus Ultrasound Lab MI 1.4 25-03-2023
CA1-7A / Abdomen / FR 21Hz Tis 0.1 10:52:10 AM


G71 DR135-FAB P90 Frq Gen: 20.0cm



MR VIVEK 34/M
OnePlus Ultrasound Lab MI 1.4 25-03-2023
CA1-7A / Abdomen / FR 21Hz Tis 0.1 10:52:41 AM

G71 DR135-FAB P90 Frq Gen: 20.0cm





Name	: Mr. VIVEK KUMAR	Age/Sex	: 34 YRS/Male
Ref. By	: Dr. MEDIWHEEL	Lab No	: 012303250006
Date	: 25-Mar-2023	Patient ID	: LSHHI111313

X-ray-Chest PA view

Bony cage and soft tissues are normal.
Cardiothoracic ratio is normal.
Mediastinum is normal.
Both hila are normal.
Both costophrenic angles are clear.
Both domes of diaphragm are normal.
Lung fields are clear. No parenchymal lesion seen.

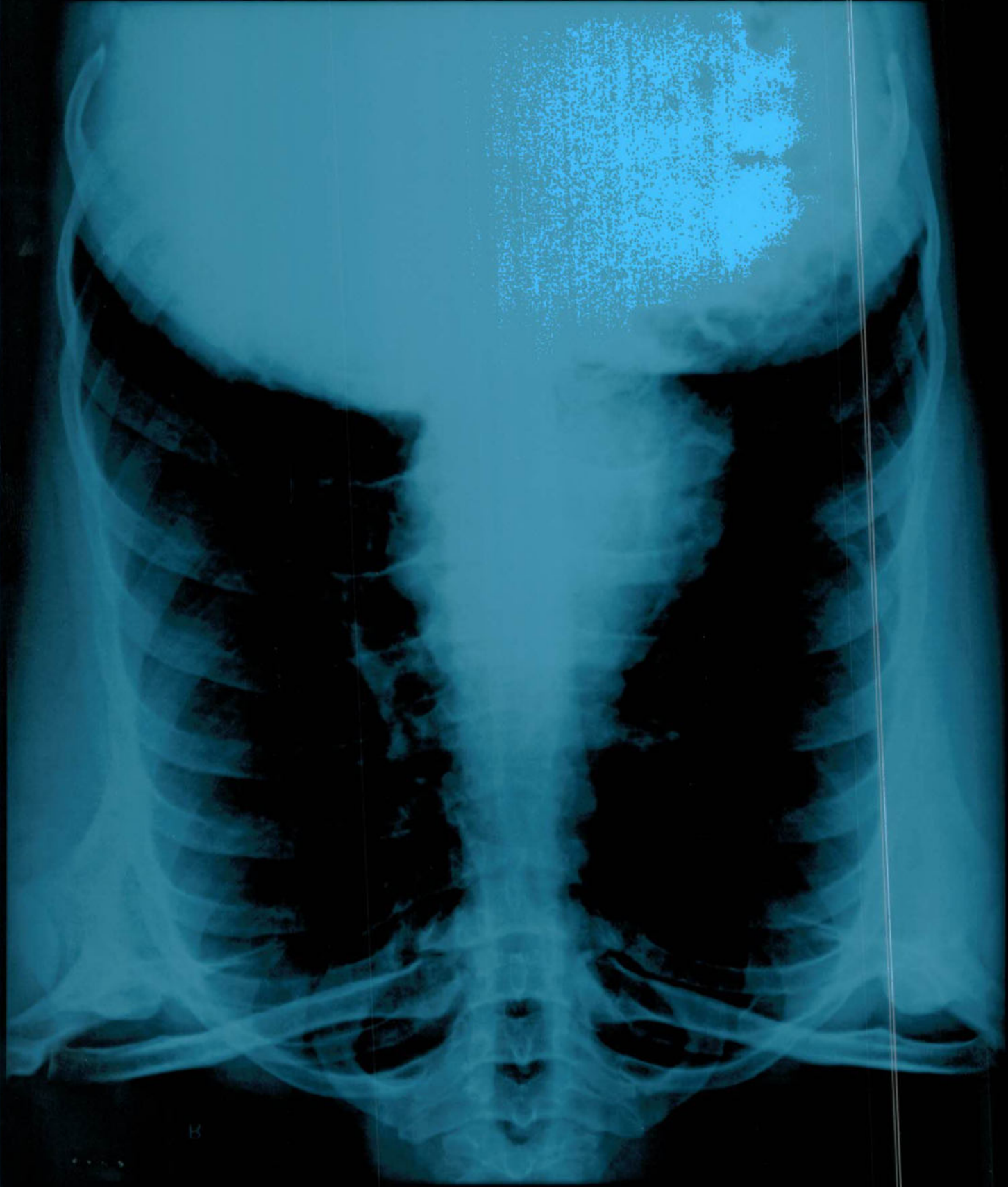
IMPRESSION: Normal Study.

Dr. POOJA GARG
M.B.B.S., D.M.R.D.
Reg No. DMC/R/03398
Radiologist
DR. POOJA GARG
RADIOLOGIST
REG NO. DMC/R/03398

Type By : darshita

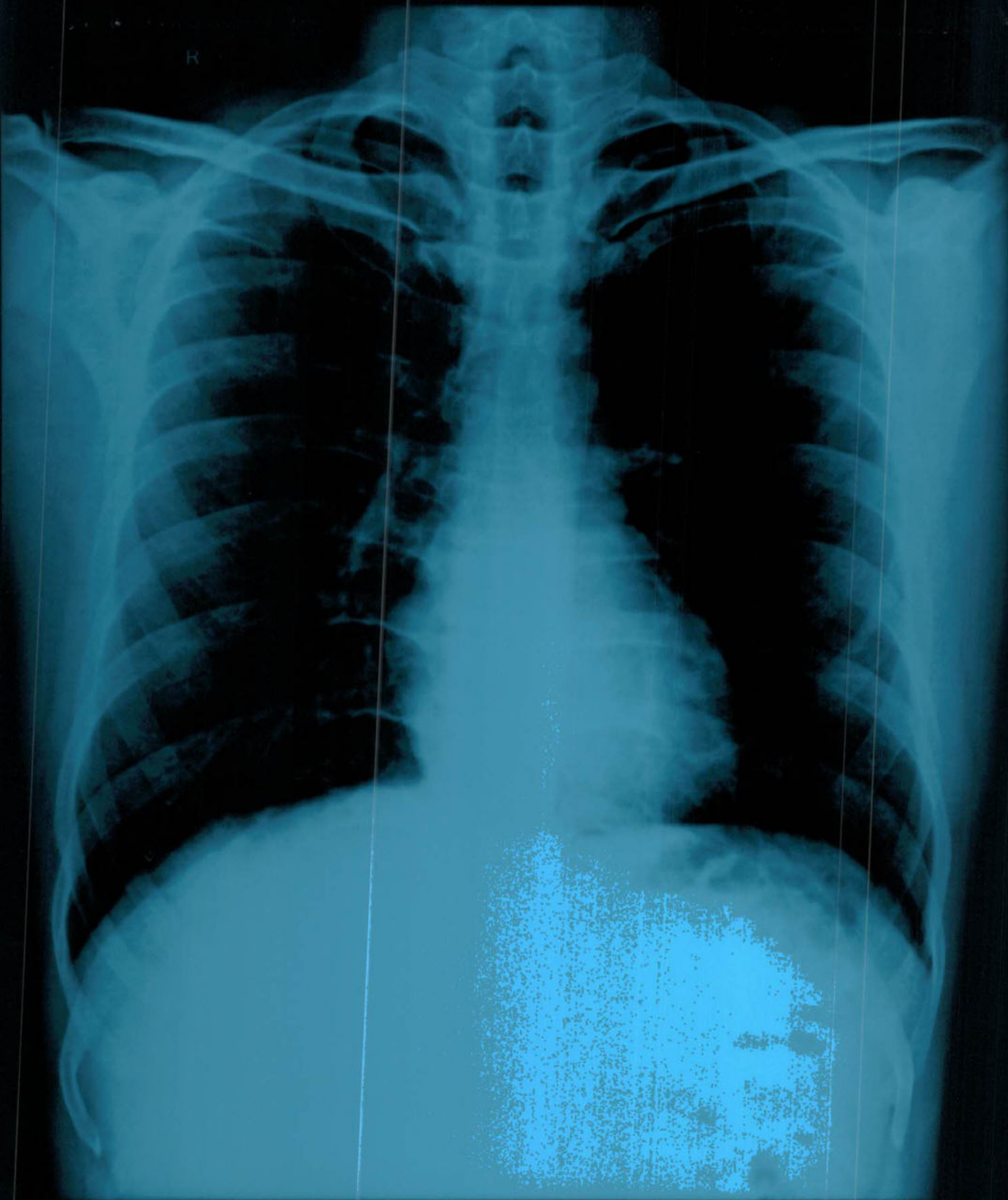47, Harsh Vihar, Pitampura, New Delhi-110034 | Ph.: 011-42480101, 9599913051
E-mail: oneplusul@gmail.com | Web.: www.oneplusul.in

ОИЕБГУС ПГТРАСОИИД ГАР 47 НАР2Н АИНАР 6ТАМБОВА
МБ АИЕК КУМАР 34 УРС 3210313033 M CHEST PA VIEW



H

R



MR VIVEK KUMAR 34 YRS 25/03/2023 M CHEST PA VIEW
ONEPLUS ULTRASOUND LAB.47-HARSH VIHAR.PITAMPURA