

भारतीय विशिष्ट पहचान प्राधिकरण
आधार Unique Identification Authority of India

पता:
 S/O: रमेश कुमार, बी एल 106
 सेकेंड फ्लोर, शालीमार बाग, शालीमार
 बाग, शालीमार बाग, उत्तर-पश्चिमी,
 दिल्ली, 110088

Address:
 S/O: Ramesh Kumar, b l 106
 second floor, shalimar bagh,
 Shalimar Bagh, Shalimar Bagh,
 North West Delhi, Delhi, 110088

4854 9838 0555

1947
 1800 300 1947

help@uidai.gov.in

www.uidai.gov.in

DR. NITIN AGARWAL
 M.B.B.S. MD
 Regn. No. DMC-R-1436

भारत सरकार
 Government of India

विजय कुमार रैसेतिया
 Vijay Kumar Raisetia
 जन्म तिथि / DOB : 21/12/1988
 पुरुष / Male

4854 9838 0555

आधार - आम आदमी का अधिकार

ONEPLUS ULTRASOUND LAB
 47, Harsh Vihar, Pitam Pura,
 Delhi-110034
 Ph. 011-42480101, 9599913051
 E-mail: oneplusul@gmail.com

[Handwritten signature]



Dr. NITIN AGARWAL
MBBS, MD
Regn. No. DMC-R-1436



ONEPLUS ULTRASOUND LAB
47, Harsh Vihar, Pitam Pura,
Delhi-110034
Ph. 011-42480101, 9599913051
E-mail: oneplusul@gmail.com



OnePLUS
Ultrasound Lab
— QUALITY FIRST... ALWAYS! —

Dr. Nitin Agarwal
Pathologist & Director
Ex. Sr. Res. MAMC
& Lok Nayak Hospital
Ex. Chief of Lab Dr. Lal Path Labs.

Dr. Pooja (Garg) Agarwal
Radiologist & Director
MAMC & Lok Nayak Hospital

I, Vijay Kumar Raisinghani do not wish to
go for stool samples Test & BSPP.

Regards

Vijay K. Raisinghani

Dr. NITIN AGARWAL
MBBS, MD
Regn. No. DMC-R-1436

47, Harsh Vihar, Pitampura, New Delhi-110034 | Ph.: 011-42480101, 9599913051
E-mail: oneplusul@gmail.com | Web.: www.oneplusul.in

Clinical correlation is essential for final diagnosis. • If test results are unsatisfactory please contact personally or on phone. • This report is for perusal of doctors only.
• All disputes Subject to Delhi Jurisdiction only. • Not for medicolegal purposes. • All congenital anomalies in a foetus may not be diagnosed in routine obstetric ultrasound.

ONEPLUS ULTRASOUND LAB

47, HARSH VIHAR, PITAMPURA, DELHI- 110034

Mr. VIJAY KUMAR RAISETHA
Age : 34M
Ref by :
Indication1 :
Indication2 :
Indication3 :
COMMENTS : Normal ECG

ID : 2132
H/W/M : 175/79
Recorded : 6-3-2023 9:25
Medication1 :
Medication2 :
Medication3 :

BPMM : 81
BP : 122/82
P Axis : 86 deg
QRS Axis : 70 deg
T Axis : 60 deg

P duration : 90 msec
PR duration : 120 msec
QRS duration : 100 msec
QT Interval : 303 msec
QTc Interval : 339 msec

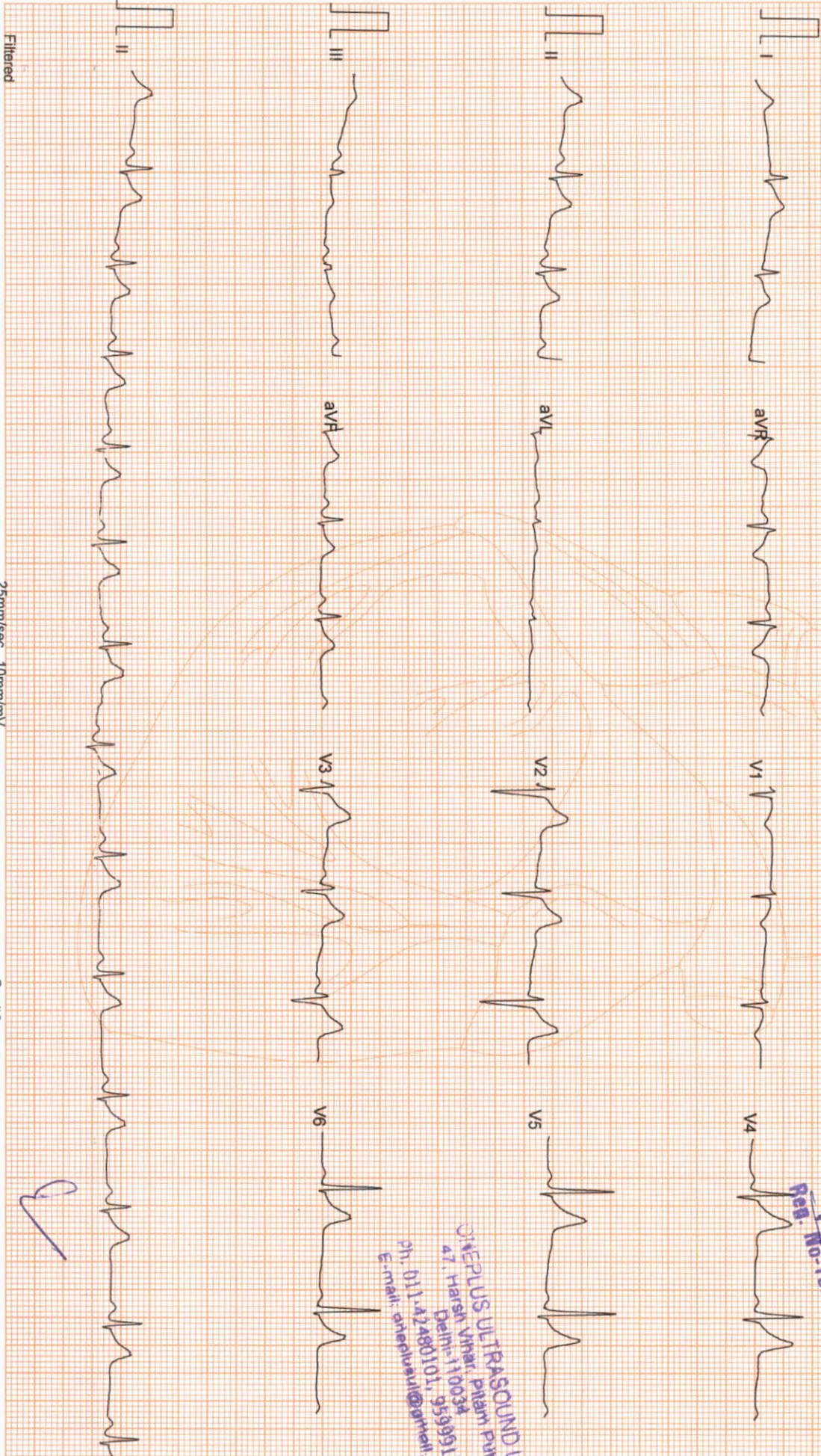
Raw E.C.G.(Seq)

Unconfirmed Report Reviewed By:

Cardiologist

Dr. P. K. GUPTA
MBBS, MD
Reg. No-1071

ONEPLUS ULTRASOUND LAB
47, Harsh Vihar, Pitampura,
Delhi-110034
Ph: 011-42480101, 9539913051
Email: onepplusai@gmail.com



Filtered

25mm/sec 10mm/mV

GREEN INDIA

CardiCom, INDIA

ONEPLUS ULTRASOUND LAB

47, HARSH VIHAR PITAMPURA DELHI 110034

Mr. VIJAY KUMAR RAISETTA

Age/Sex : 34/M
Ref. by : MEDIWHEEL

Indication1 :
Indication2 :
Indication3 :

ID : 990
HWWT : 75/79
Recorded : 6-3-2023 9:30

TREADMILL TEST SUMMARY REPORT
Protocol: BRUCE

History:
Medication1 :
Medication2 :
Medication3 :

PHASE	PHASE TIME	STAGE TIME	SPEED (Km./Hr.)	GRADE (%)	H.R. (BPM)	B.P. (mmHg)	RPP X100	II	ST LEVEL (mm) V2	V5	METS
STANDING SUPINE					80	122/82	97	1.6	2.8	2.4	
STAGE 1	2:59	2:59	2.70	10.00	80	122/82	97	1.6	2.8	2.4	
STAGE 2	5:59	2:59	4.00	12.00	108	132/84	142	2.0	2.6	3.0	4.80
STAGE 3	8:59	2:59	5.40	14.00	115	144/86	165	2.1	2.4	2.8	7.10
STAGE 4	9:29	0:29	6.70	16.00	141	154/88	217	2.0	2.6	3.2	10.00
PEAK EXER	9:30	0:30			165	170/90	280	1.9	2.2	2.7	10.65
RECOVERY	2:59	2:59	0.00	0.00	166	170/90	282	1.8	2.1	2.4	10.67
					86	126/82	108	1.0	1.3	1.2	

RESULTS

Exercise Duration : 9:30 Minutes
Max Heart Rate : 166 bpm 89 % of target heart rate 186 bpm
Max Blood Pressure : 170/90 mmHg
Max Work Load : 10.67 METS
Reason of Termination :

IMPRESSIONS

Normal for individual of this age

Cardiologist

Dr. P.K. GUPTA
MBBS, MD
Regd. No. 11071

ONEPLUS ULTRASOUND LAB
47, Harsh Vihar, Pitampura, Delhi-110034
Ph: 011-42490101, 95999153021
Email: oneplusul@oneplusul.com



Mr. VIJAY KUMAR RAISETTA

I.D. : 990

AGE/SEX : 34/M

RECORDED : 6-3-2023 9:30

RATE : 80 BPM

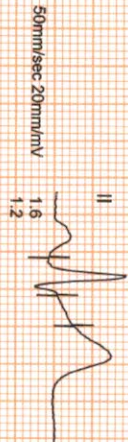
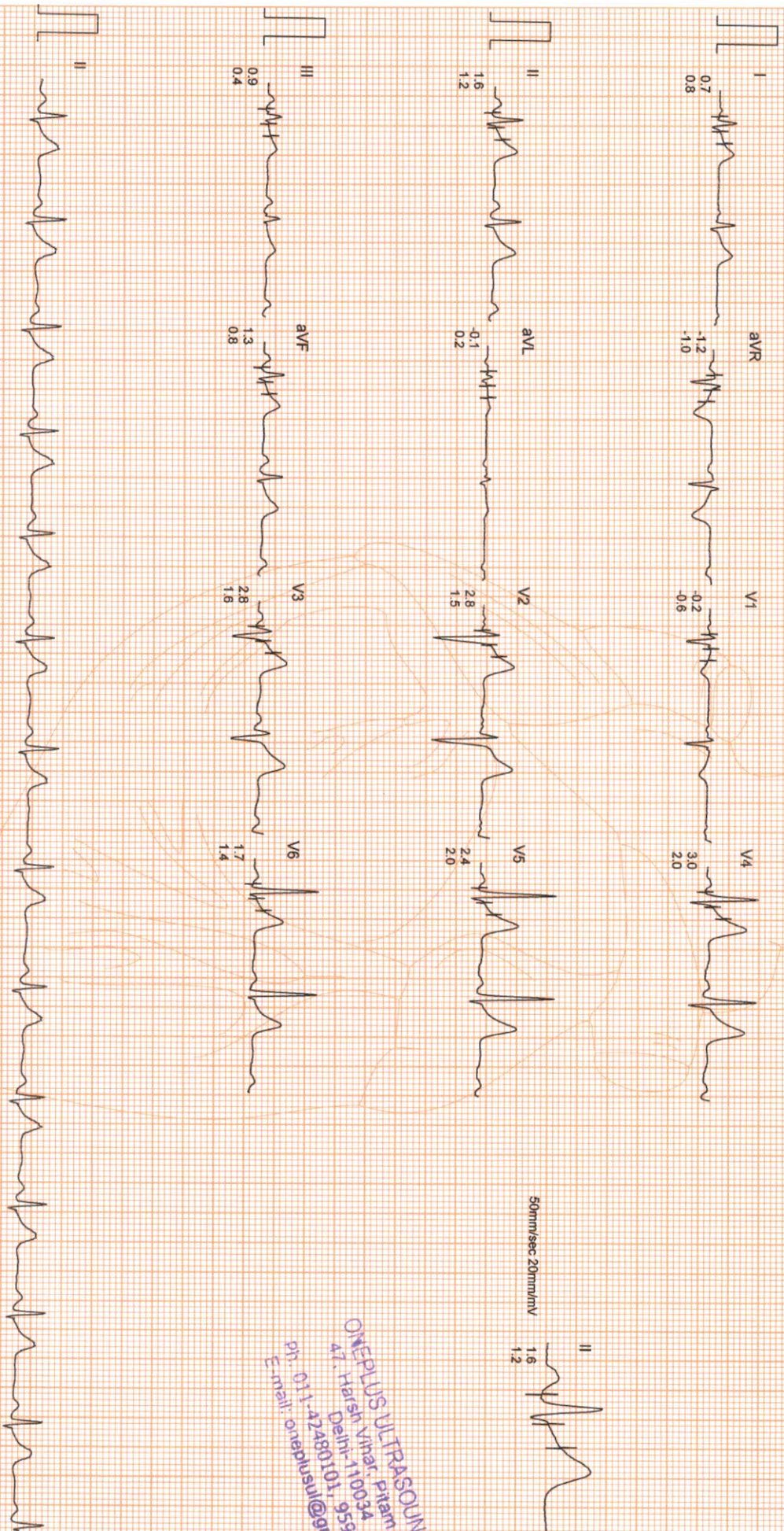
B.P. : 122/82 mmHg

ONEPLUS ULTRASOUND LAB

STANDING
PRETEST

ST @ 10mm/mV
80ms PostJ

LINKED MEDIUM



ONEPLUS ULTRASOUND LAB
 47, 1-Harsh Vihar, Pitam Pura,
 Delhi-110024
 Ph: 011-22480101, 9539913051
 E-mail: onepplus@gmail.com

ONEPLUS ULTRASOUND LAB

SUPINE
PRETEST

ST @ 10mm/mV
80ms PostJ

Mr. VIJAY KUMAR RAISETTA

I.D. : 990

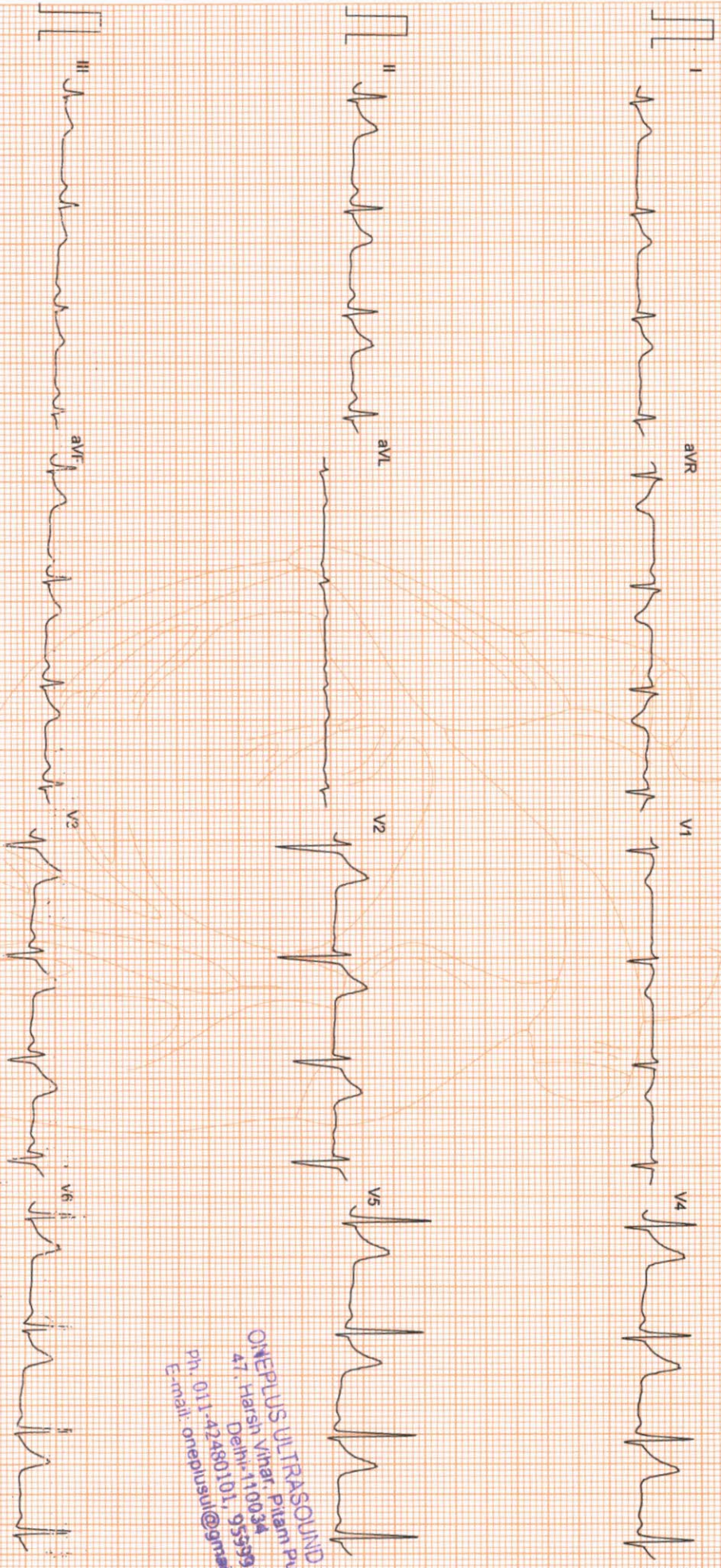
AGE/SEX : 34/M

RATE : 80 BPM

RECORDED : 6-3-2023 9:30

B.P. : 122/82 mmHg

RAW E.C.G.



ONEPLUS ULTRASOUND LAB
47, Harsh Vihar, Pitampura,
Delhi-110034 9559913051
Ph: 011-42480101, 9559913051
Email: oneplusul@gnrc.com

Filtered

25mm/sec 10mm/mV

GREEN INDIA

CardiCom, INDIA Ph.:091-731-2620740, TeleFax:091-731-2431214

ONEPLUS ULTRASOUND LAB

Mr. VIJAY KUMAR RAISETIA

I.D. : 990

AGE/SEX : 34/M

RECORDED : 6-3-2023 9:30

RATE : 108 BPM

B.P. : 132/84 mmHg

BRUCE

EXERCISE 1

PHASE TIME : 2:59

STAGE TIME : 2:59

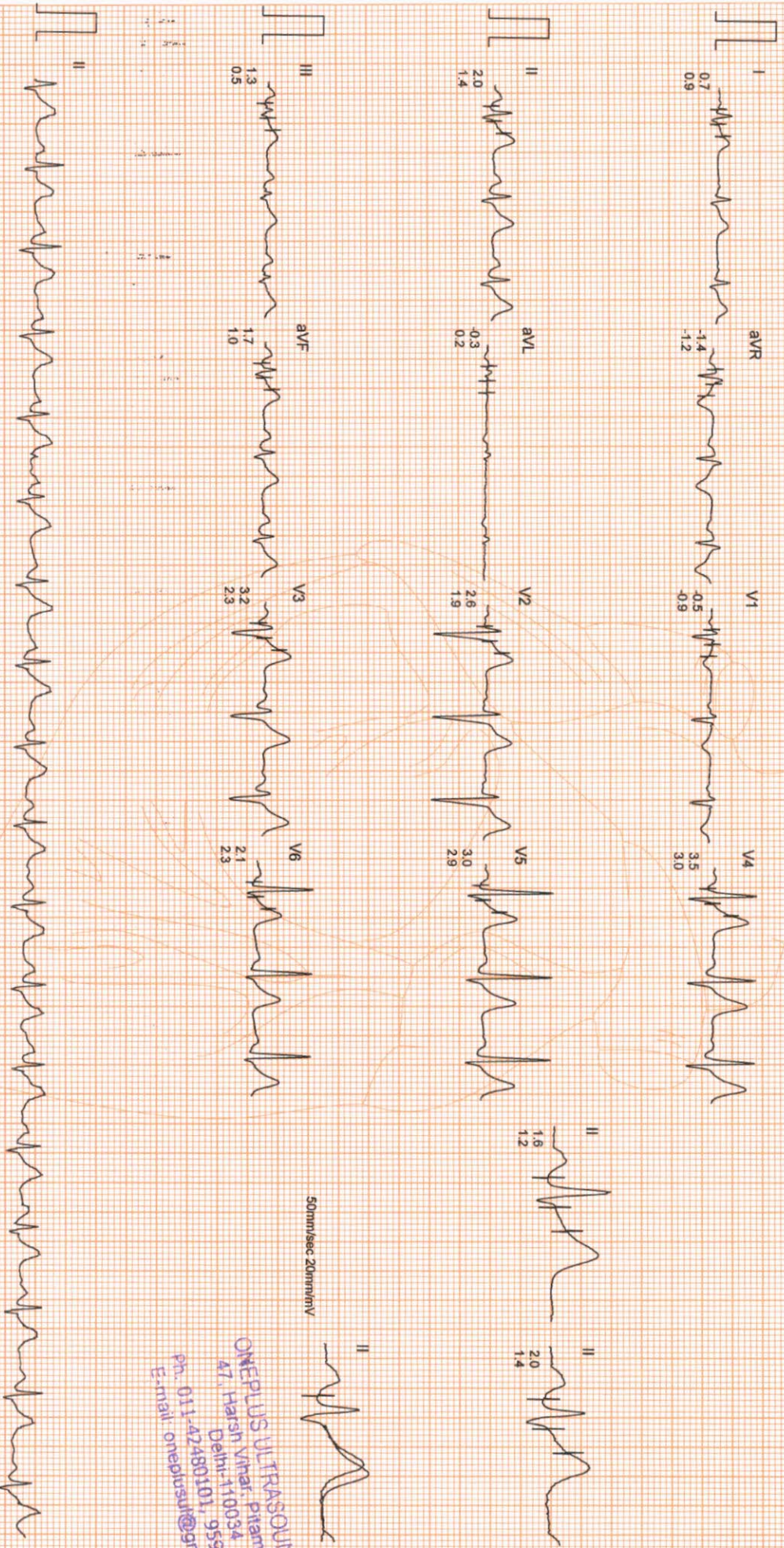
ST @ 10mm/mV

80ms PostJ

SPEED : 2.7 Km./Hr.

GRADE : 10.0 %

LINKED MEDIAN



50mm/sec 20mm/mV

ONEPLUS ULTRASOUND LAB
47, Harsh Vihar, Pitam Pura,
Delhi-110034
Ph. 011-42480101, 9599913051
E-mail: oneplusul@gmail.com

Filtered Computer Corrected Baseline

25mm/sec 10mm/mV

GREEN INDIA

CardiCom, INDIA Ph.:091-731-2620740, Telefax:091-731-2431214

ONEPLUS ULTRASOUND LAB

Mr. VIJAY KUMAR RAISETIA

I.D. : 990

AGE/SEX : 34/M

RECORDED : 6-3-2023 9:30

BRUCE

EXERCISE 2

PHASE TIME : 5:59

STAGE TIME : 2:59

ST @ 10mm/mV

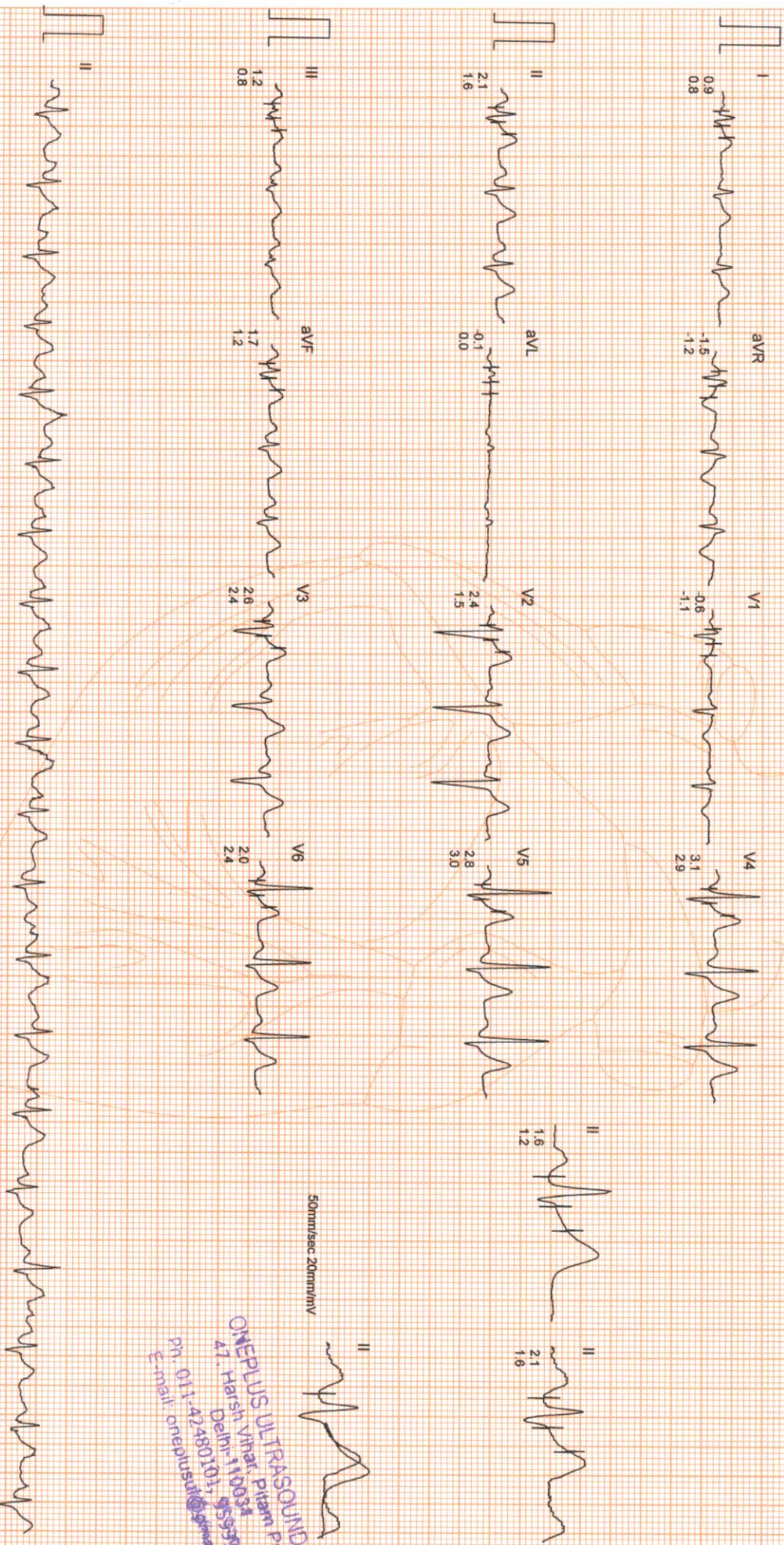
80ms PostI

SPEED : 4.0 Km/Hr

GRADE : 12.0 %

LINKED MEDIAN

RATE : 115 BPM
B.P. : 144/86 mmHg



50mm/sec 20mm/mV

ONEPLUS ULTRASOUND LAB
47, Harshi Vihar, P. H. Sector, Pura
Delhi, 110033
Ph: 011-42480101
E-mail: info@oneplusultrasound.com

ONEPLUS ULTRASOUND LAB

MR. VIJAY KUMAR RAISETIA

I.D. : 990

AGE/SEX : 34/M

RECORDED : 6-3-2023 9:30

RATE : 141 BPM

B.P. : 154/88 mmHg

BRUCE

EXERCISE 3

PHASE TIME : 8:59

STAGE TIME : 2:59

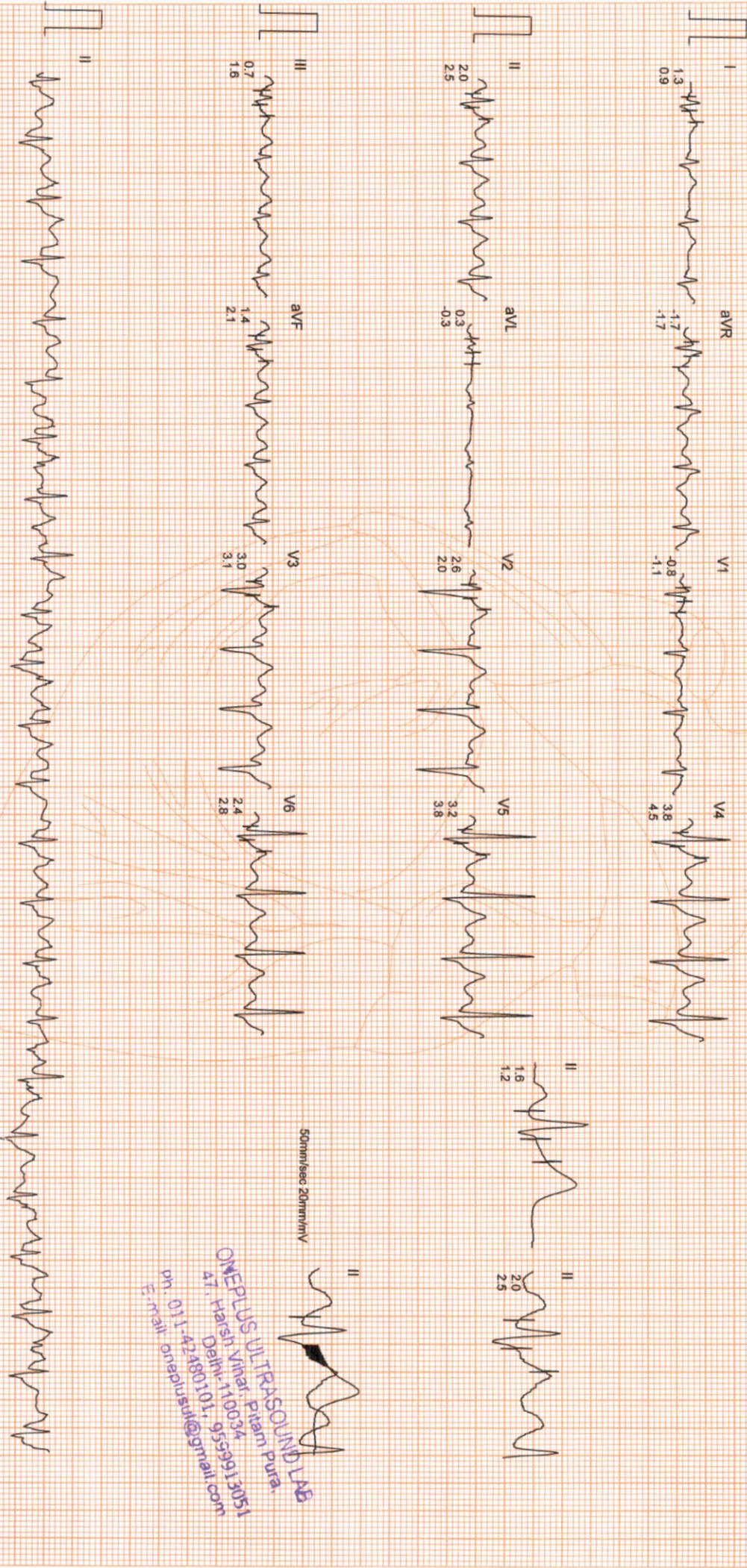
ST @ 10mm/mV

80ms PostJ

SPEED : 5.4 Km./Hr.

GRADE : 14.0 %

LINKED MEDIAN



Filtered Computer Corrected Baseline

25mm/sec 10mm/mV

GREEN INDIA

CardiCom, INDIA Ph.:091-731-2620740, TeleFax:091-731-2431214

ONEPLUS ULTRASOUND LAB
47, Hareli Vihar, Pitam Pura,
Delhi-110034
Ph. 011-4280101, 9559913051
E-mail: oneplusul@gmail.com

ONEPLUS ULTRASOUND LAB

Mr. VIJAY KUMAR RAISETTA

I.D. : 990

AGE/SEX : 34/M

RECORDED : 6-3-2023 9:30

RATE : 165 BPM

B.P. : 170/90 mmHg

BRUCE

EXERCISE 4

PHASE TIME : 9:29

STAGE TIME : 0:29

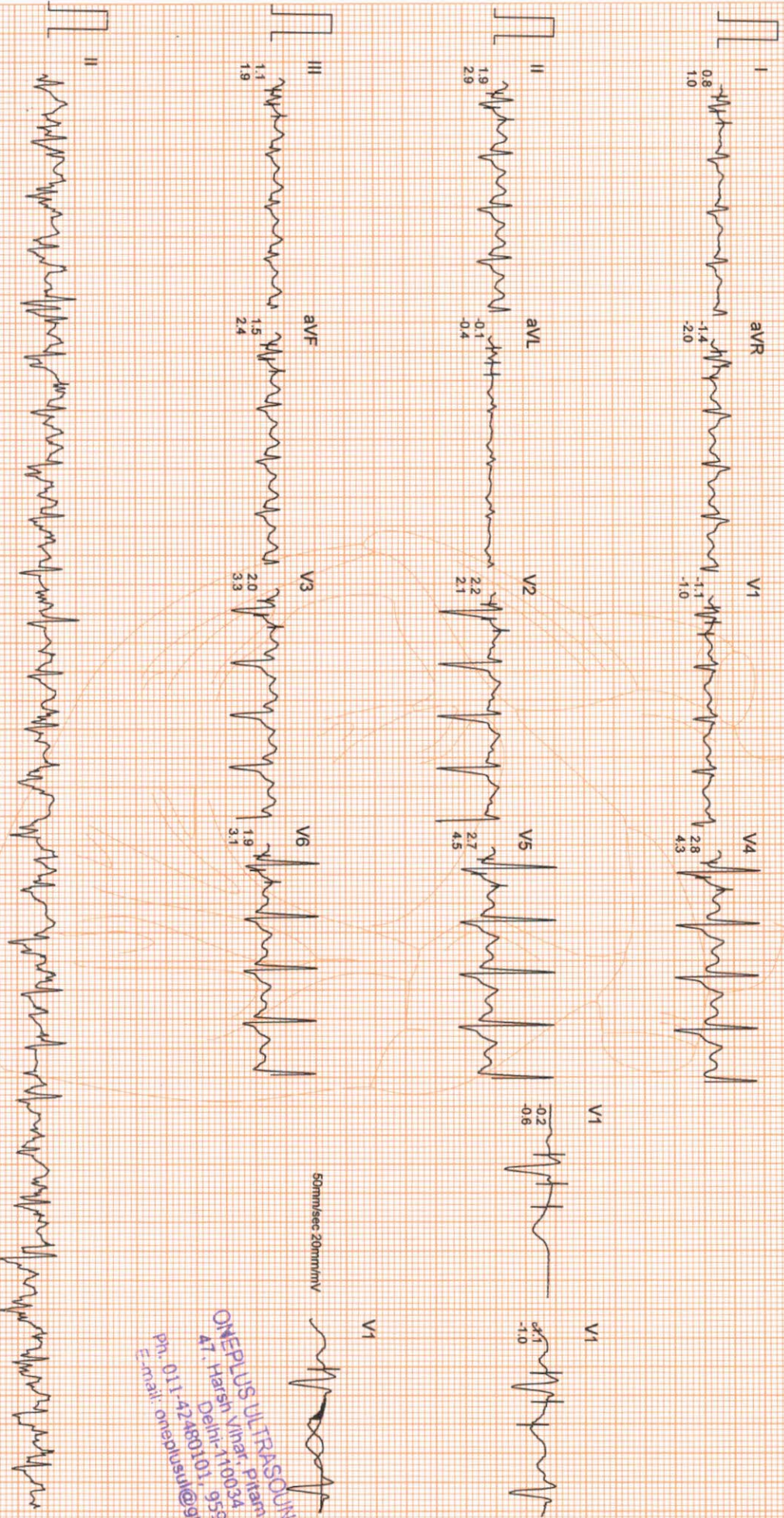
ST @ 10mm/mV

80ms PostJ

SPEED : 6.7 Km./Hr.

GRADE : 16.0 %

LINKED MEDIAN



50mm/sec 20mm/mV

ONEPLUS ULTRASOUND LAB
47, Harish Vihar, Pitam Pura,
Delhi-110034
Ph: 011-4240101, 9556691305
E-mail: oneplusul@gmail.com

ONEPLUS ULTRASOUND LAB

Mr. VIJAY KUMAR RAISETIA

I.D. : 990

AGE/SEX : 34/M

RECORDED : 6-3-2023 9:30

RATE : 166 BPM

B.P. : 170/90 mmHg

BRUCE

PEAK EXER

PHASE TIME : 9:30

STAGE TIME : 0:30

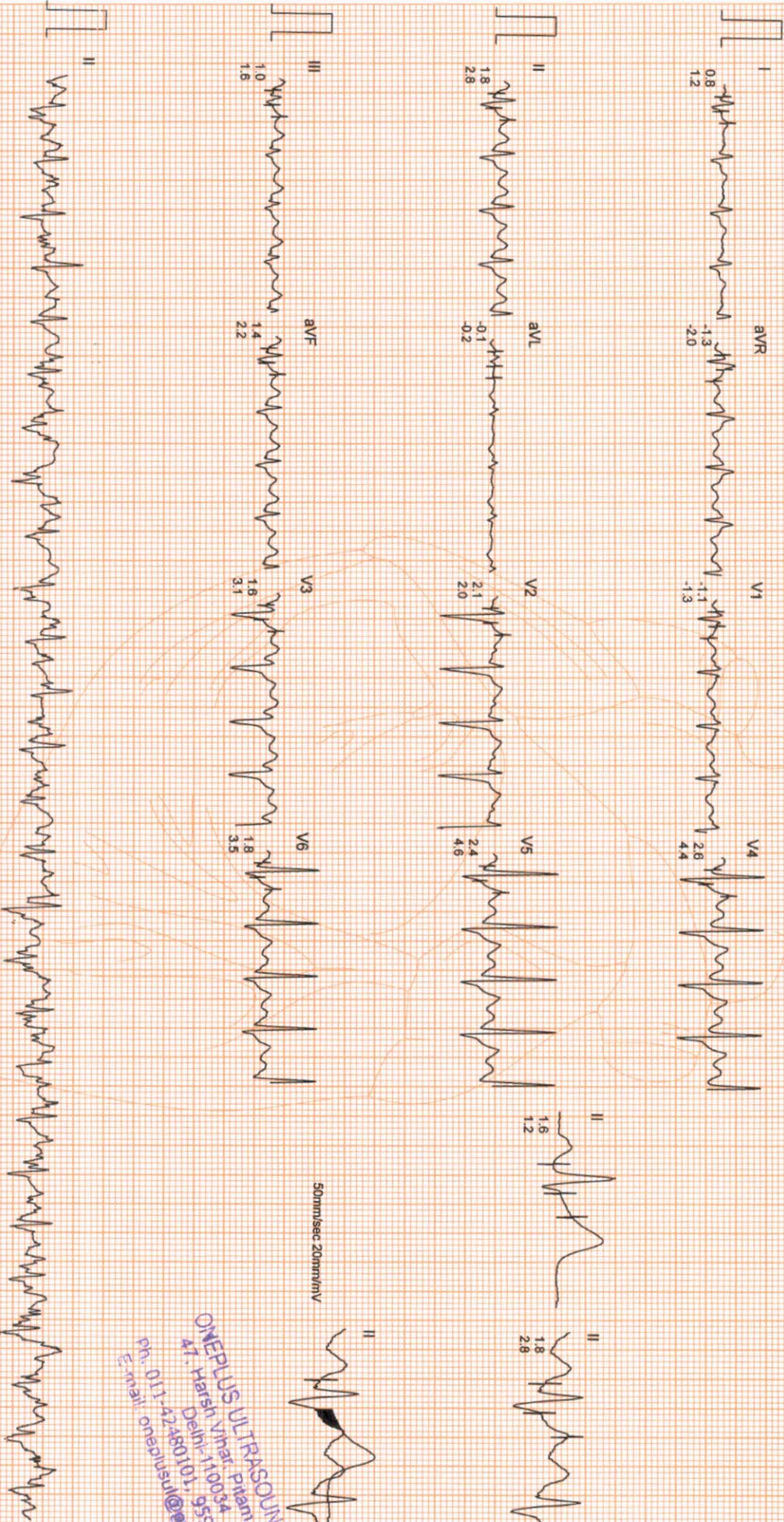
ST @ 10mm/mV

80ms PostJ

SPEED : 6.7 Km/HR.

GRADE : 16.0 %

LINKED MEDIAN



ONEPLUS ULTRASOUND LAB
47, Harsh Vihar, Pitam Pura,
Delhi-110034
Ph. 011-22480101, 9599913051
E-mail: onepusindia@gmail.com

ONEPLUS ULTRASOUND LAB

MR. VIJAY KUMAR RAISETTA
I.D. : 990

AGE/SEX : 34/M

RECORDED : 6-3-2023 9:30

RATE : 86 BPM

B.P. : 126/82 mmHg

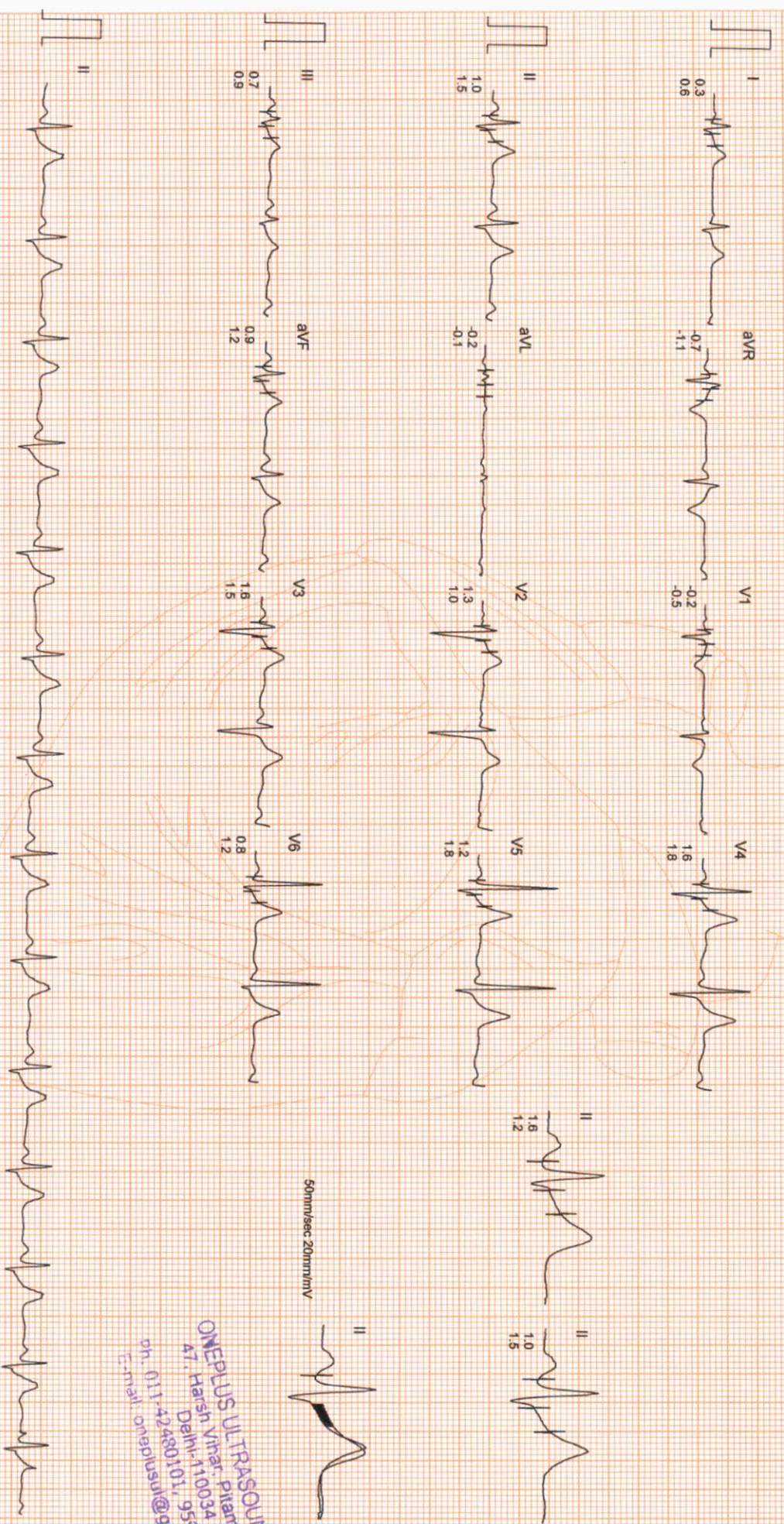
BRUCE
RECOVERY

PHASE TIME : 2:59

ST @ 10mm/mV
80ms PostJ

SPEED : 0.0 Km/Hr.
GRADE : 0.0 %

LINKED MEDIAN



50mm/sec 20mm/mV

ONEPLUS ULTRASOUND LAB
47, Harsh Vihar, Pitampura
Delhi-110034
Ph. 011-42280101, 95599915051
Email: oneplusnm@gmail.com

Filtered Computer Corrected Baseline

25mm/sec 10mm/mV

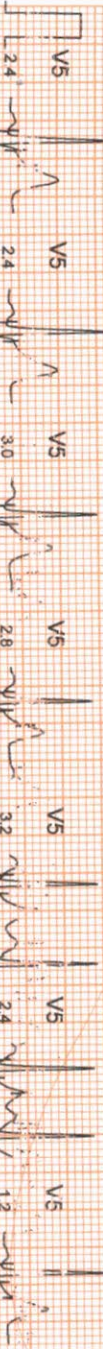
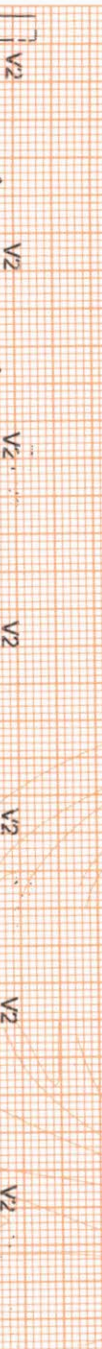

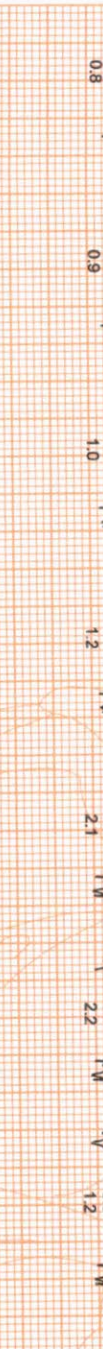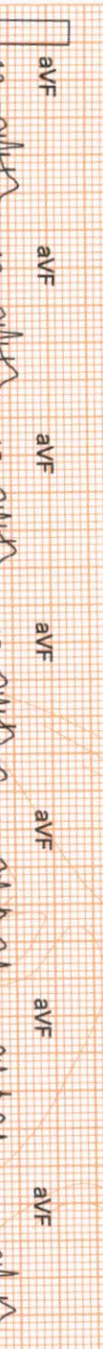
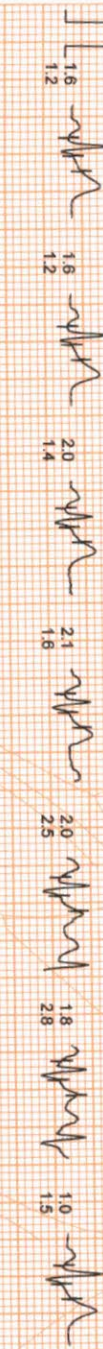
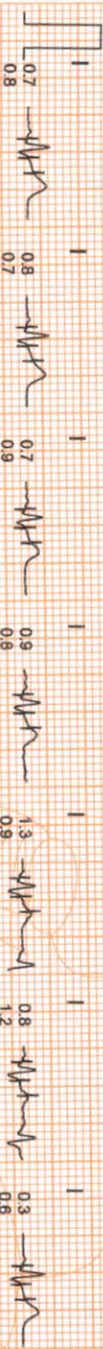
GREEN INDIA

CardiCom, INDIA Ph.:091-731-2620740, Tele/Fax:091-731-2431214

ONEPLUS ULTRASOUND LAB

AVG E.C.G.

STANDING	SUPINE	STAGE 1	STAGE 2	STAGE 3	PEAK EXERCISE	RECOVERY
0.0kmph 0.0% 80 bpm B.P. 122/82 80ms Postu	0.0kmph 0.0% 80 bpm B.P. 122/82 80ms Postu	2.39 2:39 2.7kmph 10.0% 108 bpm B.P. 132/84 80ms Postu	5:59 2:59 4.0kmph 12.0% 115 bpm B.P. 144/86 80ms Postu	8:59 2:59 5.4kmph 14.0% 141 bpm B.P. 164/88 80ms Postu	9:30 0:30 6.7kmph 16.0% 166 bpm B.P. 170/90 80ms Postu	2:59 0.0kmph 0.0% 86 bpm B.P. 128/82 80ms Postu



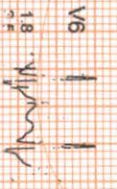
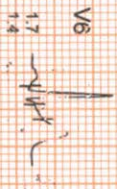
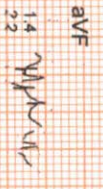
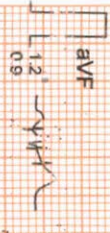
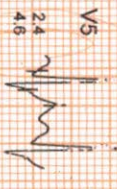
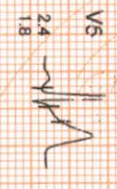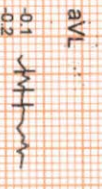

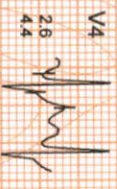

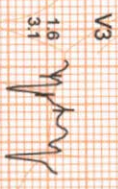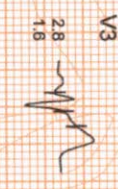
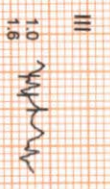
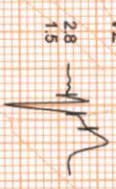
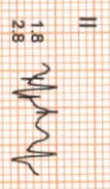
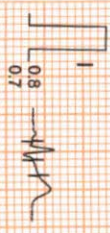
ONEPLUS ULTRASOUND LAB
 47, Harsh Vihar, Pitam Pur, Delhi-110034
 Ph. 011-42480101, 9539913053
 Email: onepusul@gmail.com

SUPINE
 0.0kmph
 0.0%
 80 bpm
 B.P. 122/82
 80ms PostJ

PEAK EXERCISE
 9:30
 0:30
 6.7kmph
 16.0%
 166 bpm
 B.P. 170/90
 80ms PostJ

SUPINE
 0.0kmph
 0.0%
 80 bpm
 B.P. 122/82
 80ms PostJ

PEAK EXERCISE
 9:30
 0:30
 6.7kmph
 16.0%
 166 bpm
 B.P. 170/90
 80ms PostJ



ONEPLUS ULTRASOUND LAB
 47 Harsh Vihar, Pitam Pura,
 Delhi-110034
 Ph. 011-42481101, 9559913051
 E-mail: oneplusul@gmail.com



OnePLUS
Ultrasound Lab
— QUALITY FIRST... ALWAYS! —

Dr. Nitin Agarwal
Pathologist & Director
Ex. Sr. Res. MAMC
& Lok Nayak Hospital
Ex. Chief of Lab Dr. Lal Path Labs.

Dr. Pooja (Garg) Agarwal
Radiologist & Director
MAMC & Lok Nayak Hospital

Name	: Mr. VIJAY KUMAR RAISETIA	Age/Sex	: 34 YRS/Male
Ref. By	: Dr. MEDIWHEEL	Lab No	: 012303060005
Date	: 06-Mar-2023	Patient ID	: LSHHI110219

ULTRASOUND EXAMINATION----WHOLE ABDOMEN

Liver is normal in size and outline with normal echopattern. No abscess or mass lesion seen. Hepatic veins, portal vein, IVC and aorta are normal. Intrahepatic biliary radicles are not dilated. CBD is normal in caliber (3.7 mm).

Gall bladder is well distended with anechoic lumen. Wall thickness is normal.

Both kidneys are normal in size, shape, position, outline and echopattern. Corticomedullary differentiation is maintained. No pelvicalyceal dilation or calculus or mass lesion is seen.

Spleen is normal in size and echotexture. No mass lesion seen.

Pancreas is normal in size, outline and echotexture.

Urinary bladder is normal in shape and position. No evidence of intravesical stone or mass seen.

Prostate is normal in size, shape and echopattern.

Prostate measures 3.5 x 3.5 x 3.0 cm. **Weight of prostate is 19.8 grams.**

No abnormal bowel wall thickening seen in right iliac fossa.

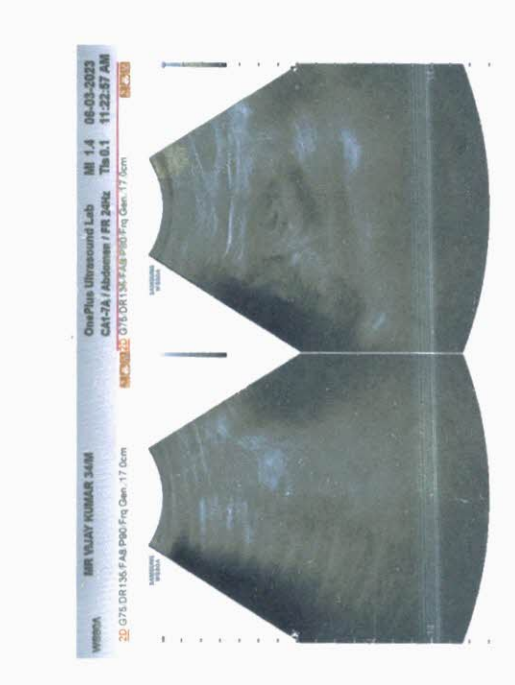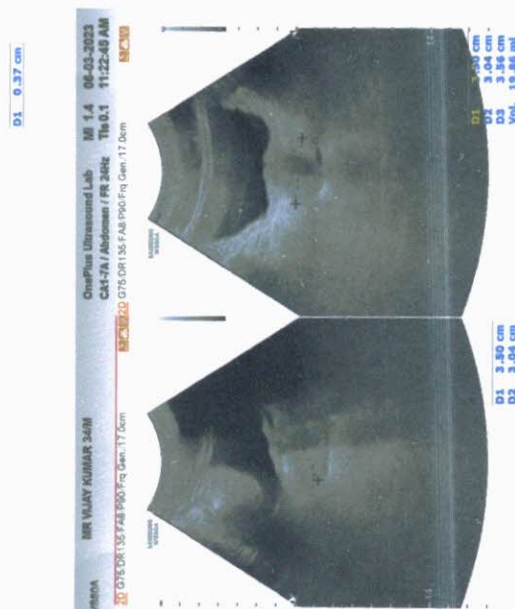
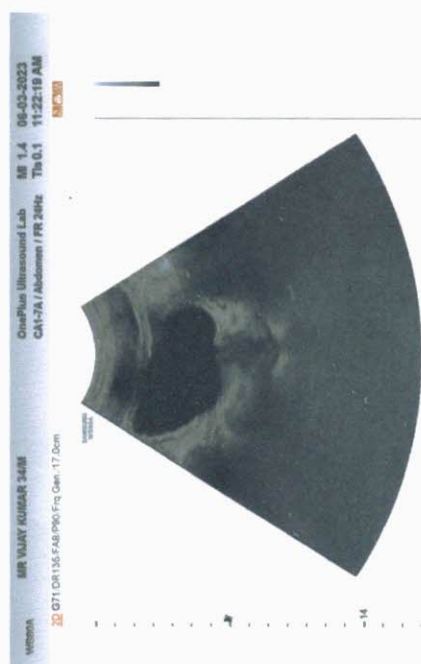

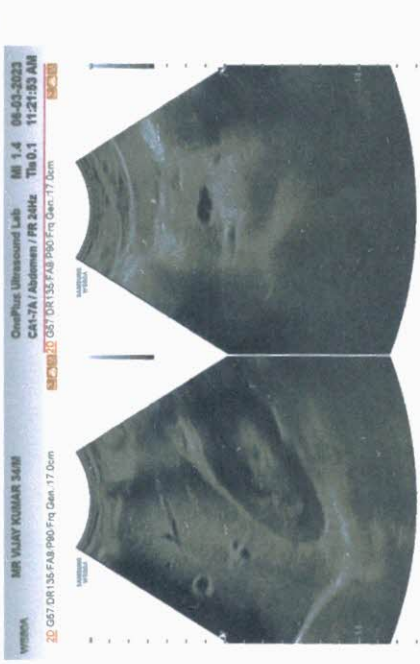
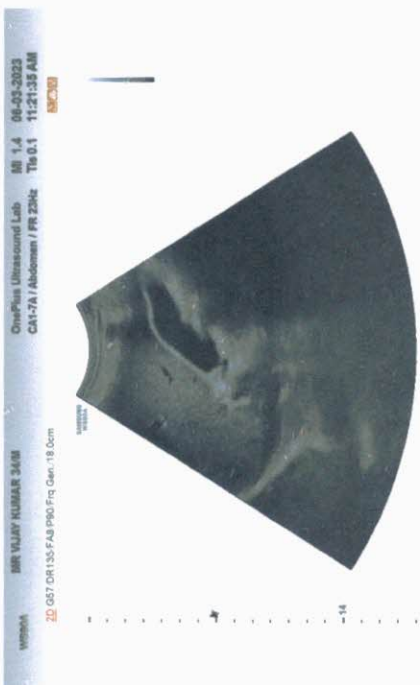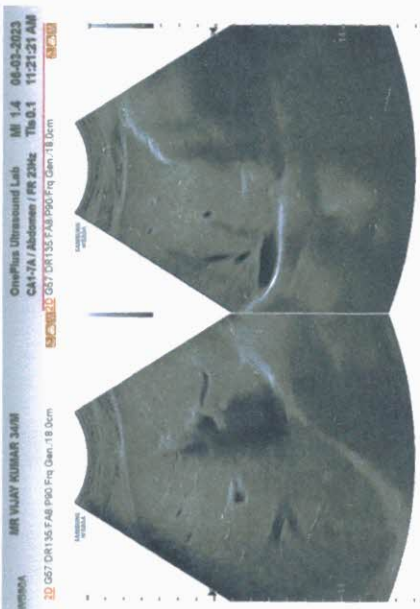No free fluid seen anywhere in abdomen.

IMPRESSION: Normal Study.

DR. POOJA GARG
RADIOLOGIST
M.B.B.S. (RADIOLOGY)
Reg No. DMC/R/03398
Radiologist

Type By : darshita

47, Harsh Vihar, Pitampura, New Delhi-110034 | Ph.: 011-42480101, 9599913051
E-mail: oneplusul@gmail.com | Web.: www.oneplusul.in







PO-020-2007-000000000000

PO-020-2007-000000000000

PO-020-2007-000000000000

PO-020-2007-000000000000





OnePLUS

Ultrasound Lab

— QUALITY FIRST... ALWAYS! —

Dr. Nitin Agarwal
Pathologist & Director
Ex. Sr. Res. MAMC
& Lok Nayak Hospital
Ex. Chief of Lab Dr. Lal Path Labs.

Dr. Pooja (Garg) Agarwal
Radiologist & Director
MAMC & Lok Nayak Hospital



NAME	:Mr. VIJAY KUMAR RAISETIA	Barcode No	:10139313
AGE/GENDER	:34 YRS/Male	SPECIMEN DATE	:06/Mar/2023 09:09AM
PATIENT ID	:110219	SPECIMEN RECEIVED	:06/Mar/2023 09:28AM
REFERRED BY	:Dr. MEDIWHEEL	REPORT DATE	:06/Mar/2023 11:26AM
CENTRE NAME	:ONEPLUS ULTRASOUND LAB	LAB NO.	:012303060005

Test Name	Result	Unit	Ref. Range
-----------	--------	------	------------

HAEMATOLOGY

Medi Wheel Health checkup < 40 Male

Glycosylated Hemoglobin (HbA1c)	5.2	%	Non Diabetic adults <5.7 Prediabetic (at risk) 5.7-6.4 Diabetes >6.4
--	-----	---	--

Estimated average blood glucose (eag)	103
--	-----

Reference range (mg/dl):

90 - 120:Excellent control, 121 - 150:Good Control, 151 - 180:Average Control, 181 - 210:Action Suggested

>211:Panic value

BLOOD GROUP (ABO)	B
Rh typing	POSITIVE

NOTE :

- * Apart from major A,B,H antigens which are used for ABO grouping and Rh typing, many minor blood group antigens exist. Agglutination may also vary according to titre of antigen and antibody.
- * So before transfusion, reconfirmation of blood group as well as cross-matching is needed.
- * Presence of maternal antibodies in newborns, may interfere with blood grouping.
- * Auto agglutination (due to cold antibody, falciparum malaria, sepsis, internal malignancy etc.) may also cause erroneous result.

CBC

Haemoglobin	14.2	g/dl	13.0-17.0
Total Leucocyte Count	6300	/cumm	4000-10000
Differential leucocyte count			
Neutrophils	61	%	40-80
Lymphocyte	31.40	%	20-40
Monocytes	5.00	%	2-10
Eosinophils	2.0	%	1-6
Basophils	0.6	%	0-2
RBC Count	5.50	million/cumm	4.5 - 5.5

Checked By.

DR. NITIN AGARWAL
MBBS, MD(PATHOLOGIST)
DMC/R/01436

47, Harsh Vihar, Pitampura, New Delhi-110034 | Ph.: 011-42480101, 9599913051

E-mail: oneplusul@gmail.com | Web.: www.oneplusul.in

Page 1 of 5



OnePLUS

Ultrasound Lab

— QUALITY FIRST... ALWAYS! —

Dr. Nitin Agarwal

Pathologist & Director
Ex. Sr. Res. MAMC
& Lok Nayak Hospital
Ex. Chief of Lab Dr. Lal Path Labs.

Dr. Pooja (Garg) Agarwal

Radiologist & Director
MAMC & Lok Nayak Hospital



NAME	:Mr. VIJAY KUMAR RAISETIA	Barcode No	:10139313
AGE/GENDER	:34 YRS/Male	SPECIMEN DATE	:06/Mar/2023 09:09AM
PATIENT ID	:110219	SPECIMEN RECEIVED	:06/Mar/2023 09:28AM
REFERRED BY	:Dr. MEDIWHEEL	REPORT DATE	:06/Mar/2023 11:26AM
CENTRE NAME	:ONEPLUS ULTRASOUND LAB	LAB NO.	:012303060005

Test Name	Result	Unit	Ref. Range
PCV(Hematocrit)	46.9	%	40-50
MCV	85.9	fL	83-101
MCH	26.1	Pg	27-32
MCHC	30.4	G/dL	32-35
Platelet count	282000	/cumm	150000-450000
RDW-CV	13.6	%	11.4-14.0
ESR(WESTGRENs METHOD)	12	mm in 1st hr	0-20

BIOCHEMISTRY

<u>Blood sugar fasting</u>	93	mg/dL	70-110
<u>Bun (blood urea nitrogen)</u>	12.60	mg/dl	8.9-21.6
<u>Uric acid, serum</u>	4.6	mg/dl	3.5-7.2
<u>Creatinine, serum</u>	0.6	mg/dl	0.60-1.2


LFT(LIVER FUNCTION TEST)

Bilirubin Total	0.68	mg/dl	0.1-1.2
Bilirubin Conjugated	0.25	mg/dl	0-0.4
Bilirubin Unconjugated	0.43	mg/dl	up to 0.7
SGOT (AST)	34	U/L	0-46
SGPT (ALT)	13	U/L	0-49
Alkaline phosphatase	106	U/L	40-129
Gamma glutamyl transpeptidase	28	U/L	10-45
Total Protein	6.8	gm/dl	6.60 - 8.70
Albumin serum	3.9	g/dL	3.0-5.2
Globulin	2.90	gm/dl	1.8-3.4
Albumin/Globulin Ratio	1.34		1.10 - 2.50

LIPID PROFILE

Cholesterol	219	mg/dl	50-200
Triglycerides	82	mg/dL	25-150
HDL Cholesterol	45	mg/dL	40 - 60

Checked By.


Dr. NITIN AGARWAL
MBBS, MD(PATHOLOGIST)
DMC/R/01436

47, Harsh Vihar, Pitampura, New Delhi-110034 | Ph.: 011-42480101, 9599913051

E-mail: onepusul@gmail.com | Web.: www.oneplusul.in

Page 2 of 5



OnePLUS

Ultrasound Lab

— QUALITY FIRST... ALWAYS! —

Dr. Nitin Agarwal
Pathologist & Director
Ex. Sr. Res. MAMC
& Lok Nayak Hospital
Ex. Chief of Lab Dr. Lal Path Labs.

Dr. Pooja (Garg) Agarwal
Radiologist & Director
MAMC & Lok Nayak Hospital



NAME	:Mr. VIJAY KUMAR RAISETIA	Barcode No	:10139313
AGE/GENDER	:34 YRS/Male	SPECIMEN DATE	:06/Mar/2023 09:09AM
PATIENT ID	:110219	SPECIMEN RECEIVED	:06/Mar/2023 09:28AM
REFERRED BY	:Dr. MEDIWHEEL	REPORT DATE	:06/Mar/2023 11:26AM
CENTRE NAME	:ONEPLUS ULTRASOUND LAB	LAB NO.	:012303060005

Test Name	Result	Unit	Ref. Range
LDL cholesterol	158	mg/dL	<130
VLDL cholesterol	16.4	mg/dL	5-40
Cholesterol/HDL Ratio	4.9		Low Risk 3.3-4.97 Average Risk 4.4-7.1 Moderate Risk 7.1-11.0 High Risk >11.0
LDL/HDL Ratio	3.5		0 - 3.55

According to ATP III and NCEP guidelines

Parameter	Normal	Desirable	Borderline	High
Total cholesterol	<200		200-239	240
Triglycerides	<150	150-199	200-499	500
LDL	Optimal <100 Near Optimal 100-129	130-159	160-180	190
HDL	<40 : LOW 60 : HIGH			

BUN/Creatinine ratio

Bun (blood urea nitrogen)	12.60	mg/dl	8.9-21.6
CREATININE	0.60	mg/dl	0.30-1.10
BUN/Creatinine ratio	21.00		10.0 - 20.0

ENDOCRINOLOGY

THYROID PROFILE(T3,T4,TSH)

Triiodothyronine total [t3]	0.86	ng/dl	0.52-1.9
Thyroxine total [t4]	8.50	µg/dl	4.4 - 10.8
TSH (Thyroid Stimulating Hormone)	1.14	µIU/ml	0.25-5.0

AGE WISE VARIATION IN TSH

AGE	TSH(µIU/ml)	AGE	TSH(µIU/ml)
-----	-------------	-----	-------------

Checked By.

Dr. NITIN AGARWAL
MBBS, MD (Path)
DMC/R/01436
MBBS, MD (PATHOLOGIST)

47, Harsh Vihar, Pitampura, New Delhi-110034 | Ph.: 011-42480101, 9599913051

E-mail: onepusul@gmail.com | Web.: www.oneplusul.in

Page 3 of 5



OnePLUS

Ultrasound Lab

— QUALITY FIRST... ALWAYS! —

Dr. Nitin Agarwal
Pathologist & Director
Ex. Sr. Res. MAMC
& Lok Nayak Hospital
Ex. Chief of Lab Dr. Lal Path Labs.

Dr. Pooja (Garg) Agarwal
Radiologist & Director
MAMC & Lok Nayak Hospital




NAME	:Mr. VIJAY KUMAR RAISETIA	Barcode No	:10139313
AGE/GENDER	:34 YRS/Male	SPECIMEN DATE	:06/Mar/2023 09:09AM
PATIENT ID	:110219	SPECIMEN RECEIVED	:06/Mar/2023 09:28AM
REFERRED BY	:Dr. MEDIWHEEL	REPORT DATE	:06/Mar/2023 11:26AM
CENTRE NAME	:ONEPLUS ULTRASOUND LAB	LAB NO.	:012303060005

Test Name	Result	Unit	Ref. Range
1-4 weeks	1.00 - 19.0	16-20 yrs	0.25 - 5.0
1-12 mths	1.70 - 9.1	21 - 80 yrs	0.25 - 5.0
1-5 yrs	0.80 - 8.2	I st trimester	0.25 - 5.0
6-10 yrs	0.25 - 5.0	II nd trimester	0.50 - 5.0
11-15 yrs	0.25 - 5.0	II rd trimester	0.4 - 6.0

Reference ranges - Interpretation of Diagnostic tests - (Jacques Wallach)

1. Primary hypothyroidism is accompanied by depressed serum T3 and T4 values and elevated serum TSH level.
2. Primary hyperthyroidism is accompanied by elevated serum T3 and T4 levels along with depressed TSH values.
3. Slightly elevated T3 levels may be found in pregnancy and estrogen therapy, while depressed levels may be encountered in severe illness, renal failure and during therapy with drugs like propranolol and propyl thiouracil.
4. Although elevated TSH levels are nearly always indicative of primary hypothyroidism, and may be seen in secondary thyrotoxicosis

Checked By.


Dr. NITIN AGARWAL
MBBS, MD (Path)
MBBS, MD (PATHOLOGIST)
DMC/R/01436

47, Harsh Vihar, Pitampura, New Delhi-110034 | Ph.: 011-42480101, 9599913051
E-mail: oneplusul@gmail.com | Web.: www.oneplusul.in

Page 4 of 5



OnePLUS

Ultrasound Lab

— QUALITY FIRST... ALWAYS! —

Dr. Nitin Agarwal
Pathologist & Director
Ex. Sr. Res. MAMC
& Lok Nayak Hospital
Ex. Chief of Lab Dr. Lal Path Labs.

Dr. Pooja (Garg) Agarwal
Radiologist & Director
MAMC & Lok Nayak Hospital



NAME	:Mr. VIJAY KUMAR RAISETIA	Barcode No	:10139313
AGE/GENDER	:34 YRS/Male	SPECIMEN DATE	:06/Mar/2023 09:09AM
PATIENT ID	:110219	SPECIMEN RECEIVED	:06/Mar/2023 09:28AM
REFERRED BY	:Dr. MEDIWHEEL	REPORT DATE	:06/Mar/2023 04:21PM
CENTRE NAME	:ONEPLUS ULTRASOUND LAB	LAB NO.	:012303060005

Test Name	Result	Unit	Ref. Range
CLINICAL PATHOLOGY			
URINE ROUTINE			
Physical examination			
Quantity	20		ML
Colour	PALE YELLOW		
Transparency	CLEAR		CLEAR
Sp.gravity	1.015		1.010-1.030
pH	6.00		
Reaction	ACIDIC		ACIDIC
Chemical examination			
Urine protein	NIL		NIL
Urine sugar	NIL		NIL
Bilirubin, urine	NEGATIVE		NEGATIVE
Urobilinogen	NORMAL		NORMAL
Ketones	NEGATIVE		NEGATIVE
Microscopic examination			
Pus cells.	1-2	/HPF	0-2
Epithelial cells	0-1	/HPF	NIL
R.B.C.	NIL	/HPF	NIL
Casts	NIL	/HPF	NIL
Crystals	NIL	/HPF	NIL
Bacteria	NIL	/HPF	NIL
Others.	NIL	NIL	NIL

*** End Of Report ***

Checked By.

Dr. NITIN AGARWAL
M B B S (MD (Path))
DR. NITIN AGARWAL
DMC/B/11438
MBBS, MD (PATHOLOGIST)

47, Harsh Vihar, Pitampura, New Delhi-110034 | Ph.: 011-42480101, 9599913051

E-mail: oneplusul@gmail.com | Web.: www.oneplusul.in

Page 5 of 5

Clinical correlation is essential for final diagnosis. • If test results are unsatisfactory please contact personally or on phone. • This report is for perusal of doctors only. • All disputes Subject to Delhi Jurisdiction only. • Not for medicolegal purposes. • All congenital anomalies in a foetus may not be diagnosed in routine obstetric ultrasound.



OnePLUS
Ultrasound Lab
— QUALITY FIRST... ALWAYS! —

Dr. Nitin Agarwal
Pathologist & Director
Ex. Sr. Res. MAMC
& Lok Nayak Hospital
Ex. Chief of Lab Dr. Lal Path Labs.


Dr. Pooja (Garg) Agarwal
Radiologist & Director
MAMC & Lok Nayak Hospital

Name	: Mr. VIJAY KUMAR RAISETIA	Age/Sex	: 34 YRS/Male
Ref. By	: Dr. MEDIWHEEL	Lab No	: 012303060005
Date	: 06-Mar-2023	Patient ID	: LSHHI110219

X-ray-Chest PA view

Bony cage and soft tissues are normal.
Cardiothoracic ratio is normal.
Mediastinum is normal.
Both hila are normal.
Both costophrenic angles are clear.
Both domes of diaphragm are normal.
Lung fields are clear. No parenchymal lesion seen.

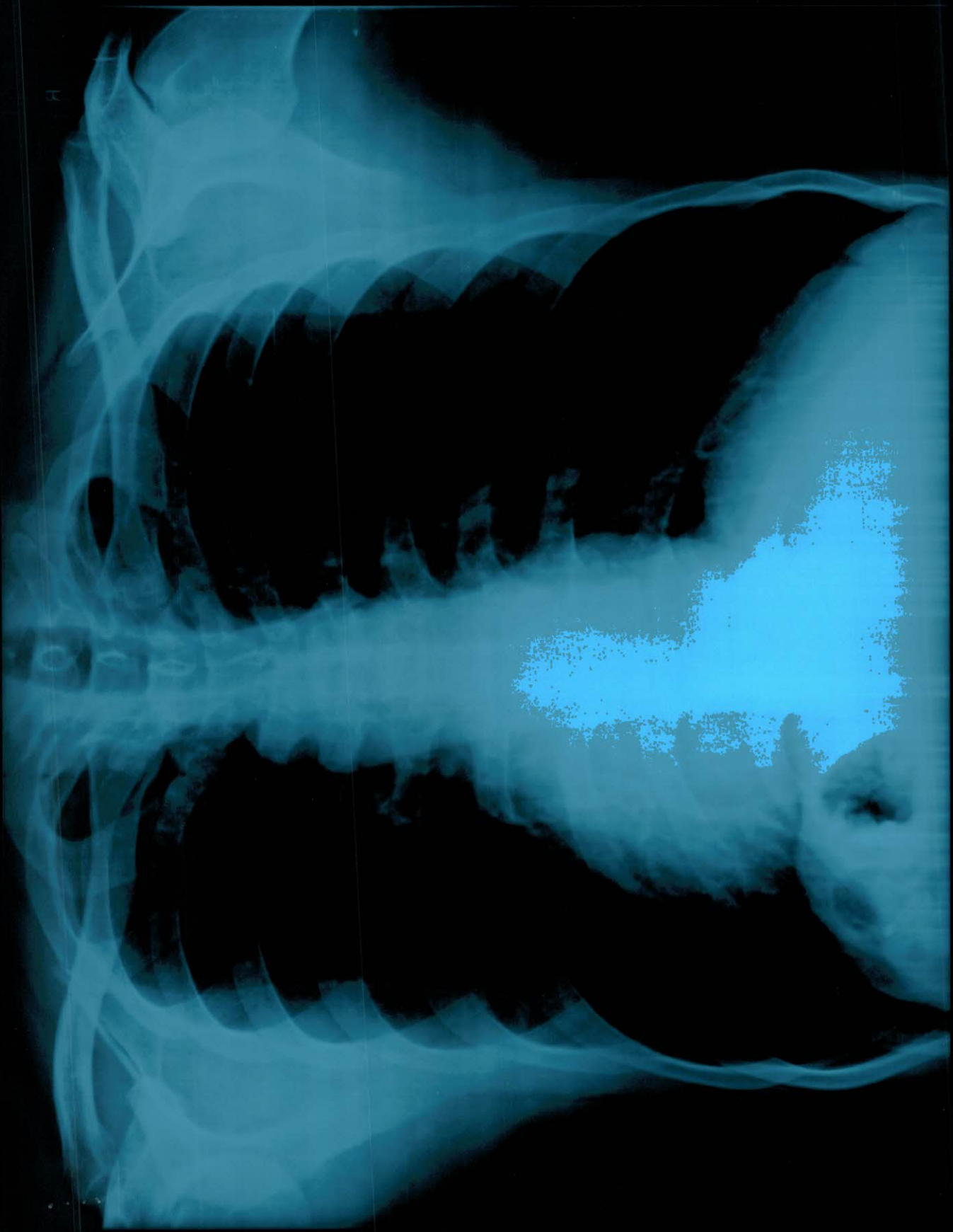
IMPRESSION: Normal Study.


Dr. POOJA GARG
RADIOLOGIST
M.B.B.S., D.M.R.D.
Reg No. DMC/R/03398
Radiologist

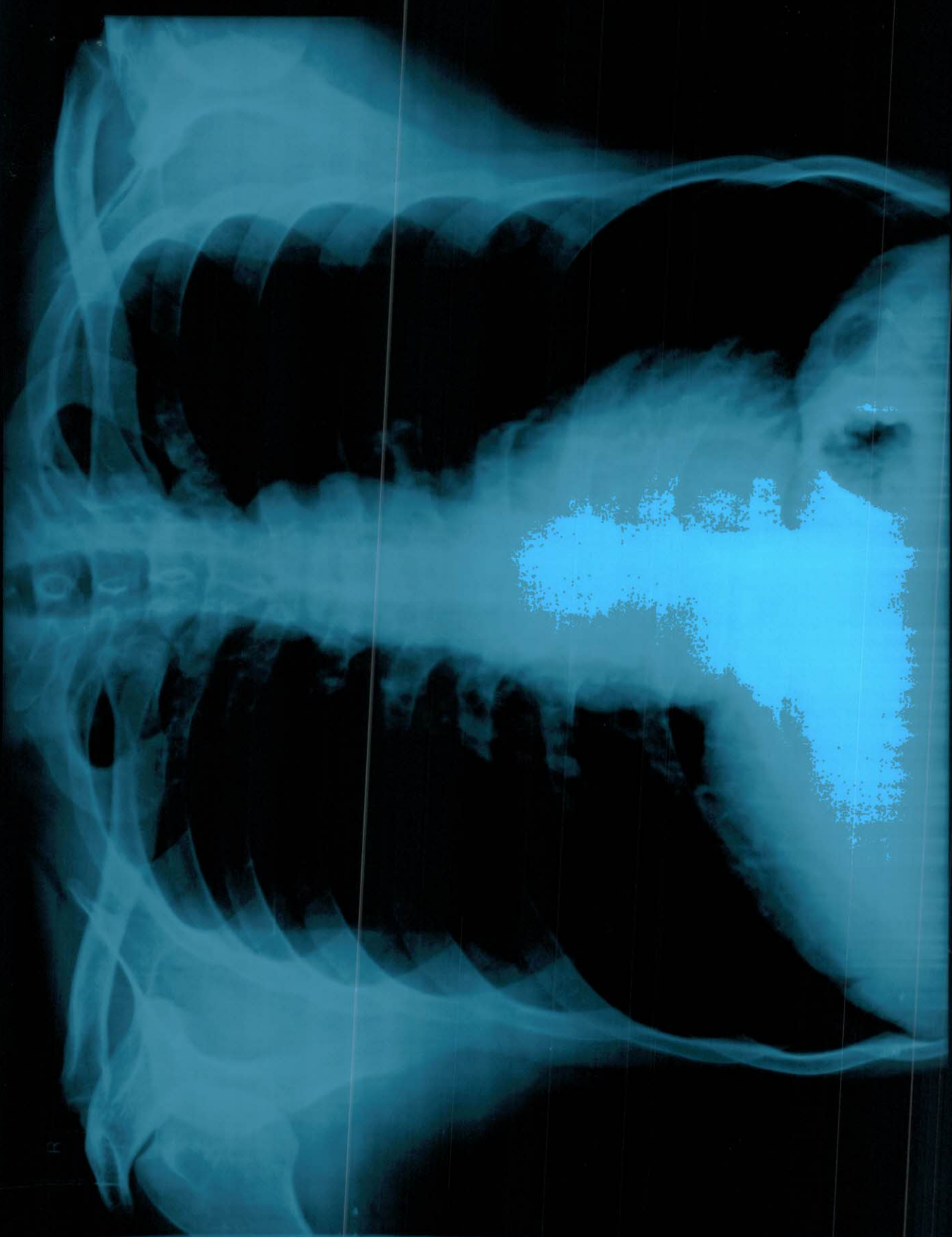
Type By : POOJA

47, Harsh Vihar, Pitampura, New Delhi-110034 | Ph.: 011-42480101, 9599913051
E-mail: oneplusul@gmail.com | Web.: www.oneplusul.in

ONE PLUS ULTRASOUND LAB & HARSH VIHAR PITAMPURA
MR. ANVA RAISELIA 34 YRS 03/5053 M CHEST PA VIEW 30/5053



R



R

MR VIJAY RAISETIA 34 YRS 6/3/2023 M CHEST PA VIEW 3/6/2023

ONEPLUS ULTRASOUND LAB.47 HARSH VIHAR PITAMPURA