


51


2

 **बैंक ऑफ बड़ोदा**  
**Bank of Baroda**


नाम  
Name: **AJIT KUMAR PATHAK**


कर्मचारी कूट क्र.  
E. C. No. **81761**


पद  
DSGN: **Chief Manager**



एनईडीआर प्राधिकारी, ई. ए. पूर्वी दिल्ली क्षेत्र  
Issuing Authority R.M. East Delhi Region







धारक के हस्ताक्षर  
Signature of Holder

**Malik Radix Health Care Pvt. Ltd.**  
C-217, C-218, Nirman Vihar  
Delhi-110092  
Ph. : 011-22011196, 22011192  
Regd. No. 607



# RADIX COSMO DENTAL

(UNIT OF MALIK RADIX HEALTHCARE PVT. LTD.)  
C-216, 217, 218, Nirman Vihar, Vikas Marg, Delhi - 110092  
Ph. : 011-22508272, 22520249 • M. : 9999254639  
E-mail : radixhealthcare@yahoo.co.in • www.radixhealthcare.org



- CONSULTANTS ON PANEL**
- PAEDIATRICS**  
Dr Ravi Malik (MBBS, MD)  
Dr Pawan Verma (MBBS, MD)  
Dr Harit Prasad (MBBS, MD, Prof)
- GYNAECOLOGY**  
Dr Renu Malik (MBBS, MD)  
Dr Meena Malhotra (MBBS, MD)  
Dr Rajni (MBBS, MD)  
Dr Manju Gupta (MBBS, MS)  
Dr Vaishali Saini (MBBS, DGO)  
Dr Rupam Arora (MBBS, MD)
- DENTAL**  
Dr Shruti Malik (BDS, MDS)  
Dr Annu Saini (BDS, MDS)  
Dr Rachit Thakral (BDS, MDS)  
Dr Mohit Mangla (BDS, MDS)  
Dr Tarun Mittal (BDS, MDS)  
Dr Geetika Sharma (BDS)  
Dr Shilpa Verma (BDS)
- MEDICINE**  
Dr A S Talwar (MBBS, MD)  
Dr Sunny Uppal (MBBS, MD)  
Dr Surendra Rajpal (MBBS, MD)  
Dr Amrit Singh Matharu (MBBS, DNB)
- RESPIRATORY MEDICINE / PULMONOLOGY**  
Dr Abhinav Bhanot (MBBS, DNB)
- LAPAROSCOPY SURGERY**  
Dr Ajay Jain (MBBS, MS)  
Dr V.K Jain (MBBS, MS)  
Dr Deepak Saran (MBBS, MS)  
Dr Pradeep Saini (MBBS, MS)  
Dr G. S Garg (MBBS, MS)
- ORTHOPAEDICS**  
Dr Vikas Bhardwaj (MBBS, MS ORTHO, DNB)  
Dr Prabhakar Aggarwal (MBBS, MS ORTHO)  
Dr KB Tiwari (MBBS, MS ORTHO)  
Dr Deepak Kumar Arora (MBBS, MS ORTHO)
- EYE/OPTHALMOLOGY**  
Dr Nidhi Gupta (MBBS, MS, DNB, PGDM)  
Dr Himanshu Singh Pundir (MBBS, MS)
- ENT**  
Dr Sharad Kumar Singhi (MBBS, MS)  
Dr Prateek Sharma (MBBS, MS)  
Dr Ashok Singh (MBBS, MS)  
Dr A K Lahiri (MBBS, MS)
- RADIOLOGY (ULTRASOUND)**  
Dr K K Sinha (MBBS DNRB)  
Dr T K Vohra (MBBS, MD)  
Dr Rajesh Malhotra (MBBS, MD)  
Dr Ashish Tomar (MBBS, MD)
- PATHOLOGY**  
Dr Reema Dahiya (MBBS, MD PATH)  
Dr Meenu Aggarwal (MBBS, MD PATH)
- ANAESTHESIA**  
Dr Rajesh Dhall (MBBS, MD)  
Dr Pakesh Atrey (MBBS, MD)  
Dr R K Arora (MBBS, MD)  
Dr Swaraj Garg (MBBS, MD)
- DERMATOLOGY**  
Dr Niharika Jain (MBBS, MD)  
Dr Nitish Singhal (MBBS, MD)
- PLASTIC & COSMETIC SURGERY**  
Dr Ayush Jain (MBBS, MS, MCh)
- PAEDIATRIC SURGERY**  
Dr Dharmendra Singh (MBBS, MS, M.Ch)  
Dr Satish Aggarwal (MBBS, MS, M.Ch)
- PAEDIATRIC NEPHROLOGY**  
Dr A S Vasudev (MD, Dip.in. Paed.)
- NEPHROLOGY**  
Dr Javed (MBBS, MD, Nephro)
- CARDIOLOGY**  
Dr Nishant Tyagi (MBBS, MD)
- NEUROLOGY**  
Dr Amit Batra (MBBS, MD)
- GASTROENTEROLOGY**  
Dr Deepak Lahoti (MBBS, MD)  
Dr Nareesh Aggarwal (MBBS, MD)
- UROLOGY**  
Dr Nikhil Sharma (MBBS, Mch)
- PSYCHIATRY**  
Dr Mohit Sharma (MBBS, MD)
- PHYSIOTHERAPY**  
Dr Kirti Dwivedi  
Dr Ravi Kumar
- NUTRITIONIST**  
Dr Deepika Kohli  
Dr Sakshi Rane
- CLINICAL PSYCHOLOGIST**  
Dr Sarika Singh

**Dr. Shruti Malik**  
BDS, MDS (Endodontics)  
(+91-9899561092)

Name : Ajit Kr. Patnak  
Age/Sex : 52y / M  
Date : 18/3/23

Timings : 9.00 am. to 1:30 pm.  
6:00 pm. to 8:30 pm.

**For Appointment**  
☎ 011-45152510  
+91-9999254639

**CLINICAL EXAMINATION:-**

Routine checkup

1. TMJ:-
2. DENTAL STATUS:
  - a. Caries Teeth : 0%
  - b. Fracture Teeth : 0%
  - c. Root Stumps :
  - d. Gingivitis :
  - e. Periodontitis :
  - f. Impacted Teeth : Calculus ++
  - g. Malaligned Teeth : Stains ++

missing 7  
Generalised Attrition.

3. ORAL LESIONS:-
4. DIAGNOSIS:- Adv  
-oral prophylaxis.
5. TREATMENT PLANNING: - P-kit
6. FOLLOW UP:-

Referral To Other Consultant: Yes/ No  
If Yes, please mention the Name: .....

Ann

Doctor's Signature .....

**Facilities Available :**

- ★ MULTI-SPECIALITY HOSPITAL ★ MODULAR FULLY EQUIPPED OT ★ NURSERY ★ LAPROSCOPIC SURGERY
- ★ 24X7 EMERGENCY ★ OPG ★ DENTAL ★ 24X7 DIAGNOSTICS ★ LABOUR ROOM ★ ECHO ★ EEG ★ DIGITAL X-RAY
- ★ ECG ★ ULTRASOUND ★ RICU/ICU ★ ALL SPECIALITY OPD ★ PLASTIC & COSMETIC SURGERY ★ DIALYSIS ★ PHARMACY

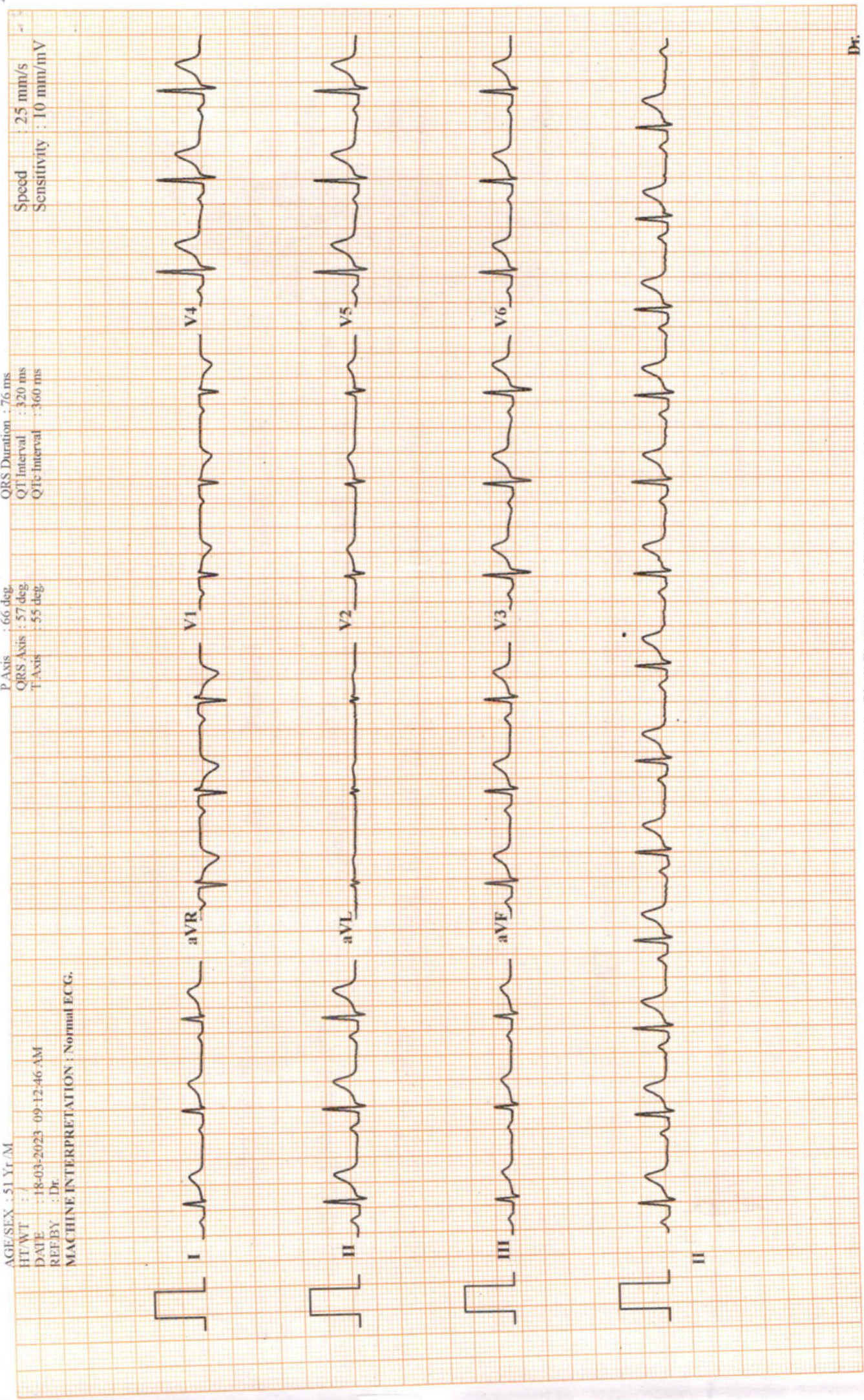


**AJIT KUMAR PATHAK**  
 I.D. : 1352  
 AGE/SEX : 51 Yr/M  
 HT/WT : /  
 DATE : 18-03-2023 09:12:46 AM  
 REF BY : Dr.  
 MACHINE INTERPRETATION : Normal ECG.

RATE : 83 bpm  
 BP : N/A  
 P.AXIS : 66 deg.  
 QRS AXIS : 57 deg.  
 T AXIS : 55 deg.

P Duration : 92 ms  
 PR Duration : 158 ms  
 QRS Duration : 76 ms  
 QT Interval : 320 ms  
 QTc Interval : 360 ms

Speed : 25 mm/s  
 Sensitivity : 10 mm/mV



Dr.



# Malik Radix HealthCare.

## ELECTROCARDIOGRAM

Name: MR. AJIT KUMAR PATHAK

Age & Sex: 51YR/MALE

Ref by: MEDI WHEEL

Date: 18/03/2023

### ECG FINDINGS:

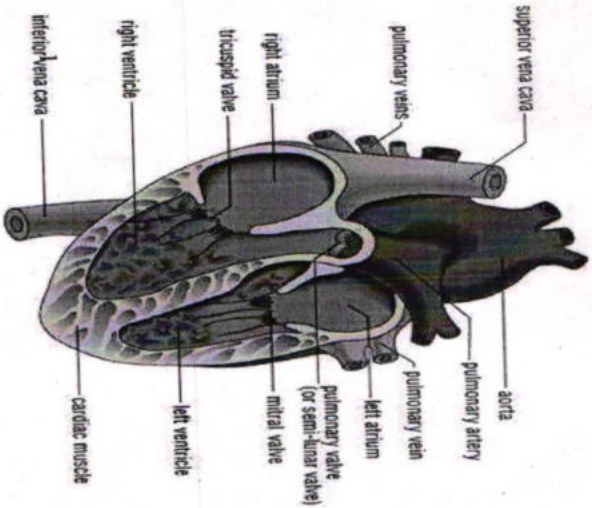
Rate 83bpm Rhythm Sinus Mechanism Normal

Axis Normal Wave Normal PR Interval 0.15/Sec

QRS Complex Normal QT Interval Normal Q Wave Normal

ST Segment Normal T Wave Normal

Conclusion Sinus Rhythm, Normal Axis, TWNL



Doctors Signature

Dr. SHEKHANAZIR AHMED

M.D. "Physician"

PGDCC

DMC-46499



## Echocardiogram Report

<b>Patient Name</b>	<b>MR. AJIT KUMAR PATHAK</b>
<b>Date of Test</b>	<b>18/03/2023</b>
<b>Age</b>	<b>51 YRS/ MALE</b>
<b>Ref. by</b>	<b>MEDI WHEEL</b>

<b>Dimensions</b>	<b>Result</b>	<b>Normal Range</b>
AO (ed)	2.6 cm	( 2.1 -3.7cm)
LA (es)	2.8 cm	(2.1 -3.7cm)
RVID (ed)	2.0 cm	(1.1-3.0cm)
LVID (ed)	4.0 cm	(3.6 – 5.5 cm)
LVID (es)	2.8 cm	(2.3-3.9cm)
IVS (ed)	1.2 cm	(0.6 – 1-2 cm)
LVPW (ed)	1.2 cm	(0.6 – 1-2 cm)
EF	58 %	
FS	30 %	(28 % - 42 %)

### Impression

NO REGIONAL WALL MOTION ABNORMALITY SEEN.

LVEF= 58 %

MILD CONCENTRIC LV HYPERTROPHY.

STAGE I LV DIASTOLIC DYSFUNCTION.

TRACE MITRAL REGURGITATION.

NO INTRA CARDIAC CLOT/MASS/ VEGETATION/PERICARDIAL EFFUSION SEEN.

**Dr. Nishant Tyagi**

(M.D. Medicine. DNB Cardiology)

(Senior Consultant, Cardiology)

**Dr. Sheikh Nazir Ahmed**

M.D. "Physician" PGDCC

(Consultant Non – Invasive Cardiologist)

### Facilities Available

- Multispeciality Hospital - 24 Hours Emergency - X-Ray/ ECG/ Ultrasound/ CT Scan - Dental - Fully Equipped Operation Theatre  
 - Fully Functional Lab - 24/7 Casualty/ ICU-Nursery 24/7 Pharmacy - Labour Room - All Speciality OPD - Laproscopic Surgery -  
 ECHO - Plastic Surgery





**LAB REPORT**

Reg. Date	18/03/2023	Patient Id	2303180006	DOB.	
Name	MR. AJIT KUMAR PATHAK	Gender	M	Perm. ID	
Age	51 Yrs.	Panel	MEDIWHEEL	Reported	18/03/2023 17:04:59
Ref. By	MEDIWHEEL				

Test Name	Result	Units	Ref. Range
-----------	--------	-------	------------

MEDIWHEEL M ABOVE 40

**HAEMATOLOGY**

**COMPLETE HAEMOGRAM**

HAEMOGLOBIN (HB%)	11.8	gm/dl	13 - 18
TOTAL LEUCOCYTE COUNT (TLC)	7,200	/cumm	4000 - 11000
<b><u>DIFFERENTIAL LEUCOCYTE COUNT (DLC)</u></b>			
NEUTROPHIL	49	%	40 - 80
LYMPHOCYTE	41	%	28 - 55
MONOCYTE	06	%	02 - 10
EOSINOPHIL	04	%	01 - 06
BASOPHIL	00	%	0 - 0
ESR (WESTEGREN'S METHOD)	12	mm/Ist hr.	0 - 10
R B C COUNT	4.56	Millions/cmm	4.247 - 5.4
P.C.V / HAEMATOCRIT	40.8	%	40 - 54
M C V	89.5	fl.	80 - 100
M C H	25.9	Picogram	27.0 - 31.0
M C H C	28.9	gm/dl	33 - 37
PLATELET COUNT	2.23	Lakh/cu mm	1.50 - 4.50

Urine Routine Examination

**PHYSICAL EXAMINATION**

QUANTITY	30	ml.	
COLOUR	Pale Yellow		Pale Yellow
TRANSPARENCY	Clear		
SPECIFIC GRAVITY	1.025		
PH	6.0		

Checked by : \_\_\_\_\_  
Page 1 Contd...2

If test results are alarming or unexpected, patient is advised to contact the laboratory immediately for possible remedial action.

**Facilities Available**

- Multispeciality Hospital - 24 Hours Emergency - X-Ray/ ECG/ Ultrasound/ CT Scan - Dental - Fully Equiped Operation Theatre  
- Fully Functional Lab - Casualty/ ICU-Nursery - Labour Room - All Speciality OPD - Laproscopic Surgery - ECHO - Plastic Surgery



**LAB REPORT**

Reg. Date	18/03/2023	Patient Id	2303180006	DOB.	
Name	MR. AJIT KUMAR PATHAK	Gender	M	Perm. ID	
Age	51 Yrs.	Panel	MEDIWHEEL	Reported	18/03/2023 17:04:59
Ref. By	MEDIWHEEL				

Test Name	Result	Units	Ref. Range
<b>CHEMICAL EXAMINATION</b>			
ALBUMIN	Nil		
SUGAR	Nil		
<b>MICROSCOPIC EXAMINATION</b>			
PUS CELLS	1-2	/HPF	
RBC'S	Nil	/HPF	
CASTS	Nil		
CRYSTALS	NIL		
EPITHELIAL CELLS	1-2	/HPF	
BACTERIA	Nil		
OTHERS	Nil		
Stool Examination Report			
BLOOD GROUP ABO	" O "		
RH TYPING	Positive		
BLOOD SUGAR FASTING	<b>129.09</b>	mg/dl	70 - 100
BLOOD SUGAR PP	<b>215.51</b>	mg/dl	90 - 140
HBA1C	8.35	%	

**Interpretation**

Non Diabetic	: 4-6%
Good Diabetic Control	: 6-8%
Fair Control	: 8-10%

Checked by : \_\_\_\_\_  
Page 2 Contd...3

If test results are alarming or unexpected, patient is advised to contact the laboratory immediately for possible remedial action.

**Facilities Available**

- Multispeciality Hospital - 24 Hours Emergency - X-Ray/ ECG/ Ultrasound/ CT Scan - Dental - Fully Equiped Operation Theatre
- Fully Functional Lab - Casualty/ ICU-Nursery - Labour Room - All Speciality OPD - Laproscopic Surgery - ECHO - Plastic Surgery





**LAB REPORT**

Reg. Date	18/03/2023	Patient Id	2303180006	DOB.	
Name	MR. AJIT KUMAR PATHAK	Gender	M	Perm. ID	
Age	51 Yrs.	Panel	MEDIWHEEL	Reported	18/03/2023 17:04:59
Ref. By	MEDIWHEEL				

Test Name	Result	Units	Ref. Range
Poor Control	: >10%		

The Glycosylated haemoglobin assay has been validated as a reliable indicator Of mean blood glucose levels for a period of 8-12 week period. ADA recommended the testing twice a year in patients with stable blood glucose and quarterly. If treatment change, or if blood glucose levels are unstable.

**TO BE CORRELATED CLINICALLY.**

**THYROID PROFILE**

Free T3 ELFA	2.78	ng/ml	02 - 04
Free T4 ELFA	1.09	ug/dl	0.8 - 2.7
TSH Serum/ELFA	3.230	uIU/ml	0.25 - 5.50 uIU/ml

**Interpretation**

**Clinical Use**

- Diagnose Hypothyroidism and Hyperthyroidism
- Monitor T4 replacement or T4 suppressive Therapy
- Quantify TSH levels in the subnormal range

Increased Levels : Primary Hypothyroidism Subclinical Hypothyroidism, TSH dependent, Thyroid Hormone Resistance.

Decreased Levels : Grave's Disease, Autonomous Thyroid Hormone Secretion, TSH Deficiency

**LIPID PROFILE**

TOTAL CHOLESTEROL	284.40	mg/dL	130.0 - 200.0 (<200)
-------------------	--------	-------	----------------------

Checked by : \_\_\_\_\_  
Page 3 Contd...4

If test results are alarming or unexpected, patient is advised to contact the laboratory immediately for possible remedial action.

**Facilities Available**

- Multispeciality Hospital - 24 Hours Emergency - X-Ray/ ECG/ Ultrasound/ CT Scan - Dental - Fully Equiped Operation Theatre
- Fully Functional Lab - Casualty/ ICU-Nursery - Labour Room - All Speciality OPD - Laproscopic Surgery - ECHO - Plastic Surgery



**LAB REPORT**

Reg. Date	18/03/2023	Patient Id	2303180006	DOB.
Name	MR. AJIT KUMAR PATHAK	Gender	M	Perm. ID
Age	51 Yrs.	Panel	MEDIWHEEL	Reported
Ref. By	MEDIWHEEL			18/03/2023 17:04:59

Test Name	Result	Units	Ref. Range
TRIGLYCERIDES	600.50	mg/dL	80.5 - 150.0 (<150)
H D L CHOLESTEROL DIRECT	23.73	mg/dL	35.0 - 60.0 (<40->59)
V L D L	120.1	mg/dL	4.0 - 30. (23-45)
L D L CHOLESTEROL	140.6	mg/dL	50.0 - 150.0 (50-150)
TOTAL CHOLESTEROL / HDL RATIO	12.0		3.3 - 5.1
LDL / HDL CHOLESTEROL RATIO	5.9		1.5 - 3.5
SERUM URIC ACID	4.60	mg/dl	3.4 - 7.0
BLOOD UREA NITROGEN (BUN)	7.20	mg/dl	6.0 - 21.0
SERUM CREATININE	0.51	mg/dl	0.7 - 1.4
BUN/CREAT RATIO	14.1	mg/dl	
<b><u>LIVER FUNCTION TEST (LFT)</u></b>			
BILIRUBIN TOTAL	0.69	mg/dl	0.2 - 1.2
CONJUGATED (D. BILIRUBIN)	0.17	mg/dl	0.00 - 0.3
UNCONJUGATED (I.D.BILIRUBIN)	0.52	mg/dl	0.2 - 0.9
SGOT / AST	27.63	IU/L	0 - 35
SGPT / ALT	42.82	IU/L	0 - 35
ALKALINE PHOSPHATASE	131.20	U/L	64 - 306
TOTAL PROTEIN	8.43	gm/dl	6.0 - 8.3
ALBUMIN	4.94	gm/dl	3.2 - 5.0
GLOBULIN	3.49	gm/dl	2.5 - 5.6
A/G RATIO	1.42		0.9 - 2.0
GAMMA GT	24.36	IU/L	0.0 - 45.0
TOTAL PSA	5.23	ng/ml	
Chemiluminescence			

10 - 20

Checked by : -----  
Page 4 Contd...5

If test results are alarming or unexpected, patient is advised to contact the laboratory immediately for possible remedial action.

**Facilities Available**

- Multispeciality Hospital - 24 Hours Emergency - X-Ray/ ECG/ Ultrasound/ CT Scan - Dental - Fully Equiped Operation Theatre  
- Fully Functional Lab - Casualty/ ICU-Nursery - Labour Room - All Speciality OPD - Laproscopic Surgery - ECHO - Plastic Surgery



## LAB REPORT

Reg. Date	18/03/2023	Patient Id	2303180006	DOB.	
Name	MR. AJIT KUMAR PATHAK	Gender	M	Perm. ID	
Age	51 Yrs.	Panel	MEDIWHEEL	Reported	18/03/2023 17:04:59
Ref. By	MEDIWHEEL				

**INTERPRETATION :****Expected Values :**

99%	:	of Healthy males	0.0-4.0 ng/ml
80%	:	of Benign prostatic hypertrophy	0.0-4.0 ng/ml
81%	:	of Prostatic Carcinomas	Above 4.0 ng/ml

**PSA** is reliable tumour marker for already diagnosed prostatic carcinomas. It is uniquely associated only with prostatic tissue, and therefore is specific for it. Baseline levels measured prior to therapeutic intervention and followed later by serial periodical measurements will predict the outcome of therapy. It also helps in early discovery of recurrences, relapses and metastases.

Dr. REEMADAHYA  
M.B.B.S, MD (Path.)  
Malik Radix Healthcare Pvt. Ltd.  
C-217, C-218, Nirman Vihar,  
Delhi-92

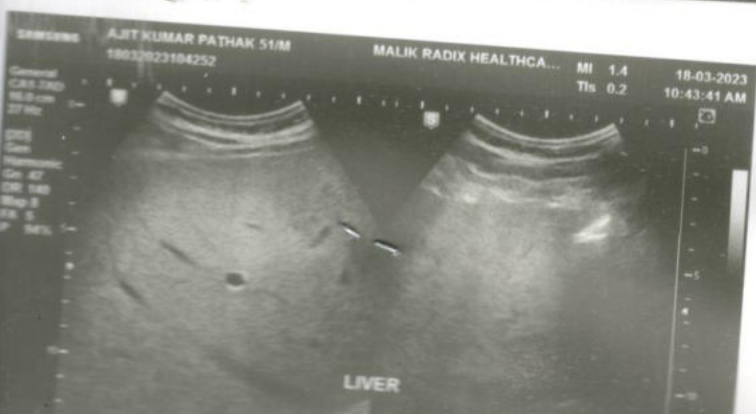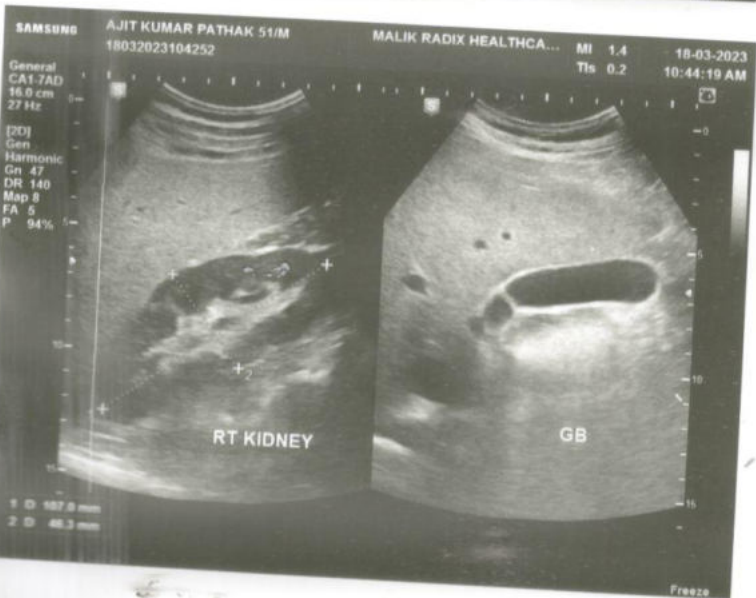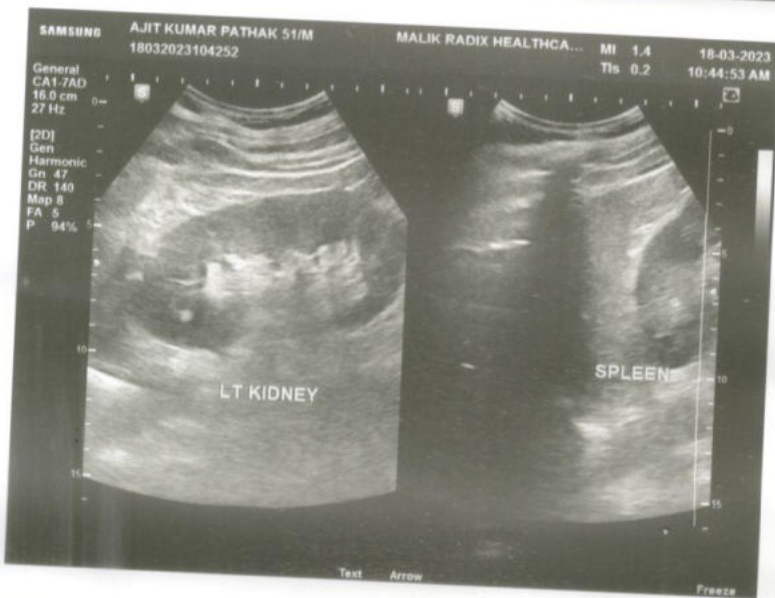
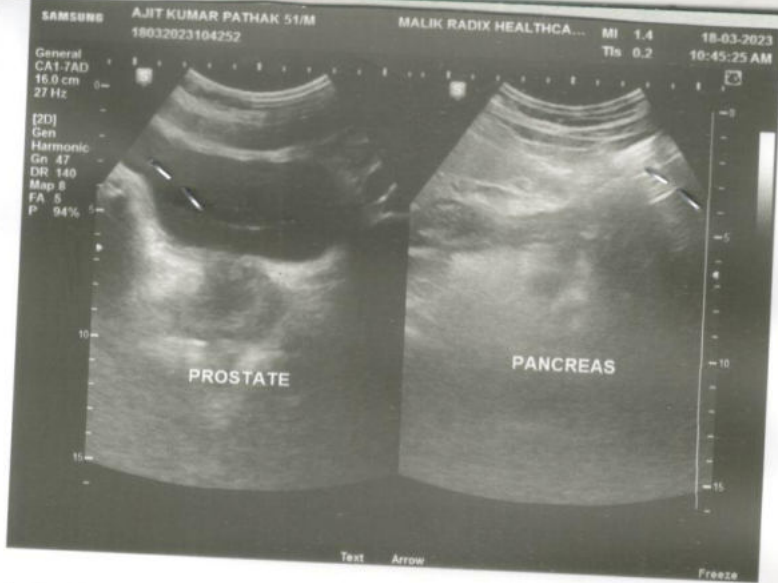DR. MEENU AGGARWAL  
M.B.B.S, MD (Path.)

If test results are alarming or unexpected, patient is advised to contact the laboratory immediately for possible remedial action.

## Facilities Available

- Multispeciality Hospital - 24 Hours Emergency - X-Ray/ ECG/ Ultrasound/ CT Scan - Dental - Fully Equiped Operation Theatre  
- Fully Functional Lab - Casualty/ ICU-Nursery - Labour Room - All Speciality OPD - Laproscopic Surgery - ECHO - Plastic Surgery





NAME	MR AJIT KUMAR PATHALK	AGE	51 YRS/M
REFD. BY.	HEALTH CHECK UP	DATE	18.03.23

**Ultrasound Examination of Whole Abdomen:**

**Liver:** Liver shows **grade 1 fatty change**. No focal SOL is seen in liver. IHBR & portal radicles are normal.

**Gallbladder:** Gallbladder shows normal anechoic pattern. No evidence of cholecystitis or cholelithiasis seen. Common bile duct is normal in course & caliber.

**Pancreas:** Pancreas shows normal size & echotexture.

**Spleen:** Spleen shows normal size, outline & echotexture.

**Kidneys:** Kidneys show normal size, shape, position & echotexture. No calculus, hydronephrosis or SOL is seen in kidneys. Cortico- medullary differentiation and cortical thickness is normal on both sides.

No supra- renal mass seen.

Great abdominal vessels are normal.

Domes of diaphragm are seen to move normally & synchronously in respiration. No infra- or supradiaphragmatic collection seen.

No ascites or pericardial effusion seen.

No para aortic lymph nodes seen.

**Urinary bladder:** Urinary bladder shows normal anechoic pattern. No calculus, SOL or diverticulum seen.

**Prostate:** Prostate enlarged in size 29 gms

Seminal vesicles are sonographically normal.

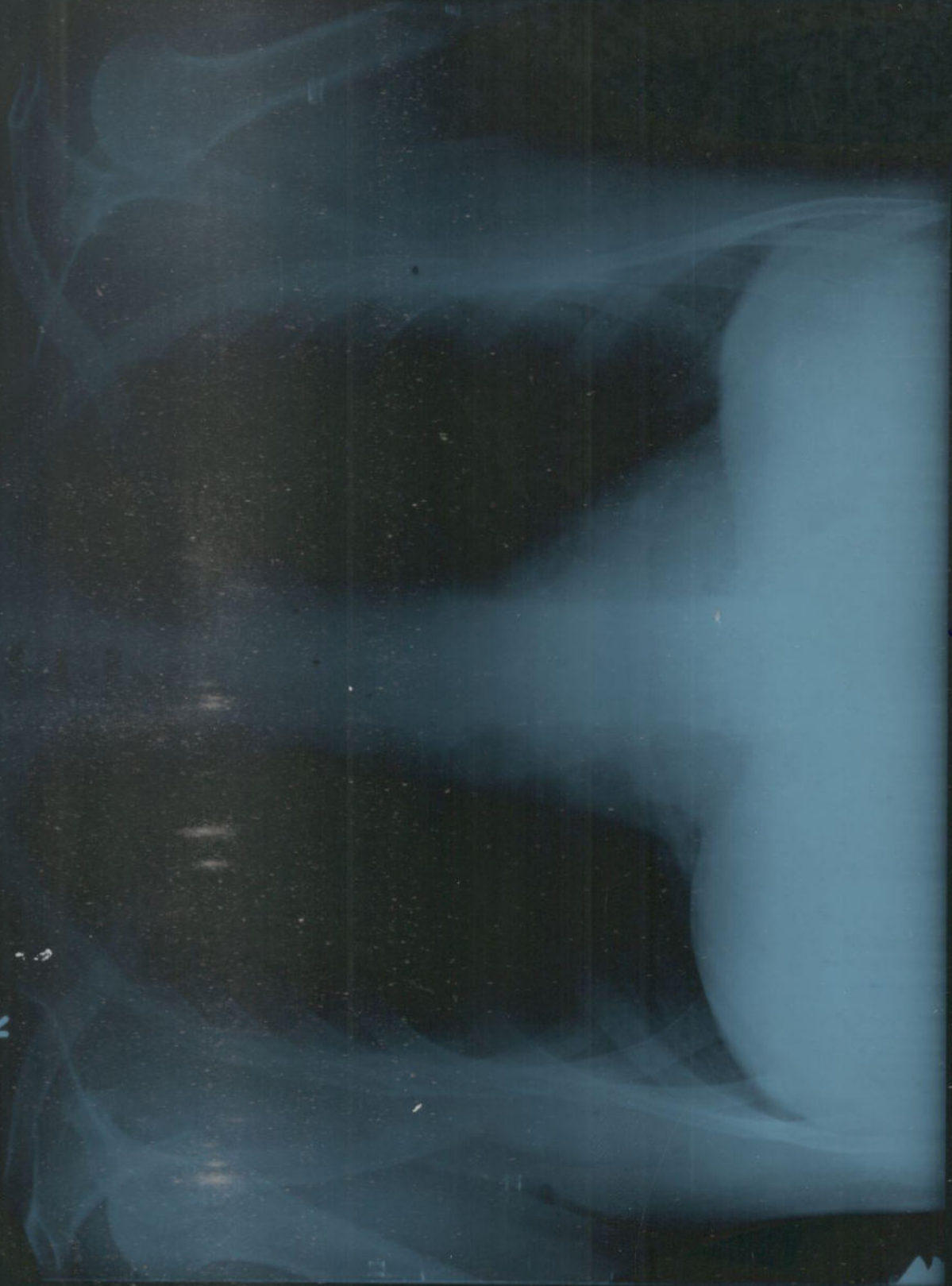IMP- 1) GRADE 1 FATTY LIVER  
2) PROSTATOMEGALY

Regards.

**Dr Mukesh Koshal MD ( Rad- diag)**  
Regn. No. DMC 10407




R



ARI KR PATHAK 51 Y/M PT183494 CHESTPA 18/09/2023 10:00  
RADIOLOGICAL DEPARTMENT

UHID	PT183494	LAB No.	XRY2210726
Name	Mr. AJIT KUMAR PATHAK	Regn. No.	GEN2242447
Age / Sex	51 Yrs / M	Receiving Dt/Time	18/Mar/2023 10:12
		Reporting Dt/Time	18/Mar/2023 10:58 AM



### XRAY

CHEST (PA)

Both lung fields are normal.

Cp angles are clear.

Hila are normal...


Heart size appears within normal limits.

Soft tissue shadows and bony thorax are normal.

IMP- NORMAL CHEST X-RAY

Advised....please correlate clinically.

\*\*\*\*\* END OF REPORT \*\*\*\*\*

  
DR. K.K. SINHA  
M.B.B.S. D.M.R.D.  
SENIOR CONSULTANT  
Reg. No. 25437 (DMC)

DR. RAJESH MALHOTRA  
MBBS, MD (RADIOLOGY)  
CONSULTANT RADIOLOGY  
Reg.No.DMC9299

DR. T. K VOHRA  
MD (RADIOLOGY)  
SENIOR CONSULTANT  
Reg. No. 3272 (DMC)

DR. MUKESH KOSHAL  
MBBS, MD (RADIOLOGY)  
CONSULTANT RADIOLOGY  
Reg.No.DMC10407